Article published online: 2021-12-15

Successful removal of a toothpick penetrating the sigmoid colon by low-pressure endoscopy using the gel immersion method

▶ **Fig. 1** Contrast-enhanced computed tomography scan demonstrated a 65-mm rod-shaped foreign body (i. e., toothpick) penetrating the sigmoid colon.

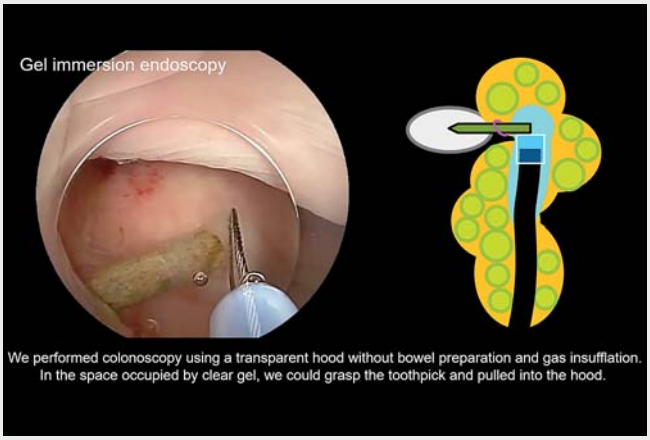

Video 1 Successful removal of a toothpick penetrating the sigmoid colon by low-pressure endoscopy using the gel immersion method.

Foreign bodies with sharp edges such as toothpicks in the gastrointestinal tract may cause injury [1]. Foreign bodies in the colon are preferably removed by colonoscopy, but bowel preparation should be avoided with suspected penetration. Gel immersion endoscopy can provide a clear view even without bowel preparation [2] while maintaining low intraluminal pressure [3, 4].

The patient was an 8-year-old boy who inserted a wooden toothpick into his anal canal. The patient developed abdominal pain within 12 hours. Laboratory tests showed an elevated white blood cell count and C-reactive protein level. Contrast-enhanced computed tomography scan demonstrated a 65-mm rod-shaped foreign body piercing the sigmoid colon with an extraluminal microabscess and panniculitis (▶ **Fig. 1**). Without bowel preparation, we performed a sigmoidoscopy using a transparent hood (▶ **Video 1**). After aspiration of the residual gas, VISCOCLEAR gel (Otsuka Pharmaceutical Factory, Tokushima, Japan) was injected through the accessory channel to secure the visual field without gas insufflation. The toothpick was found in the sigmoid colon (▶ **Fig. 2**). After grasping its end with a snare and retracting it into the transparent hood (▶ **Fig. 3**), we removed the endoscope (▶ **Fig. 4**). We reinserted the endoscope and found a small amount of pus in the lumen, which entered through a small pit (▶ **Fig. 5**). Endoscopic closure was not performed because the small pit provided drainage. We placed a clip to mark the pit. The patient recovered by maintaining non per os and antibiotic administration without surgical intervention.

▶ **Fig. 2** The toothpick was found in a clear endoscopic view by the gel immersion method even without bowel preparation or gas insufflation.

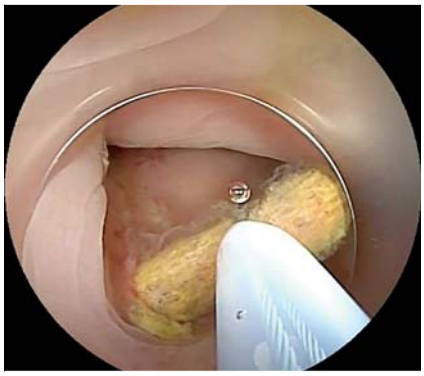

▶ **Fig. 3** The end of the toothpick was grasped with a snare to remove it.

The use of low intraluminal pressure during gel immersion endoscopy is supported by extraluminal pus that entered the lumen through the penetration site. Therefore, gel immersion endoscopy is suggested to be useful for retrieval of sharp foreign bodies after penetration of the colonic wall while securing the visual field without the need for increased intraluminal pressure that could aggravate the abscess.

This document was downloaded for personal use only. Unauthorized distribution is strictly prohibited.



▶ **Fig. 4** The entire toothpick was removed from the patient.

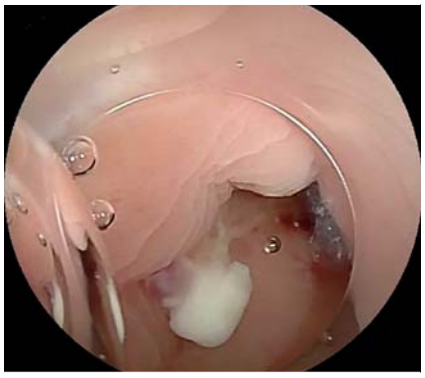

▶ **Fig. 5** A small amount of pus entered the lumen through a small penetration pit.

Endoscopy_UCTN_Code_CCL_1AG_2AZ

Competing interests

Tomonori Yano has patents for the dedicated electrolyte-free gel. No other authors have personal financial relationships with a commercial entity producing healthcare-related products and/or services relevant to this article.

The authors

Yohei Funayama[1], Tomonori Yano[1], Masafumi Kitamura[1], Hiroki Nagai[1], Shigeru Ono[2], Alan Kawarai Lefor[3], Hironori Yamamoto[1]

1 Department of Medicine, Division of Gastroenterology, Jichi Medical University, Tochigi, Japan
2 Department of Pediatric Surgery, Jichi Medical University, Tochigi, Japan
3 Department of Surgery, Jichi Medical University, Tochigi, Japan

Corresponding author

Tomonori Yano, MD
Department of Medicine, Division of Gastroenterology, Jichi Medical University, 3311-1 Yakushiji, Shimotsuke, Tochigi, 329-0498, Japan
Fax: 81-285-44-8297
tomonori@jichi.ac.jp

References

[1] Zouros E, Oikonomou D, Theoharis G et al. Perforation of the cecum by a toothpick: report of a case and review of the literature. J Emerg Med 2014; 47: e133–e137
[2] Yano T, Nemoto D, Ono K et al. Gel immersion endoscopy: a novel method to secure the visual field during endoscopy in bleeding patients (with videos). Gastrointest Endosc 2016; 83: 809–811
[3] Yano K, Yano T, Nagayama M et al. Hemostasis of an actively bleeding lesion at the ileocecal valve by low-pressure endoscopy using the gel immersion technique. Video-GIE 2021; 6: 184–186
[4] Sekiguchi H, Yano T, Tokoro S et al. Low-pressure endoscopy using the gel immersion method facilitates endoscopic variceal ligation of ruptured esophageal varices. Endoscopy 2021. doi:10.1055/a-1559-2120

Bibliography

Endoscopy 2022; 54: E571–E572
DOI 10.1055/a-1694-3931
ISSN 0013-726X
published online 15.12.2021
© 2021. Thieme. All rights reserved.
Georg Thieme Verlag KG, Rüdigerstraße 14, 70469 Stuttgart, Germany

ENDOSCOPY E-VIDEOS
https://eref.thieme.de/e-videos

Endoscopy E-Videos is an open access online section, reporting on interesting cases and new techniques in gastroenterological endoscopy. All papers include a high quality video and all contributions are freely accessible online. Processing charges apply (currently EUR 375), discounts and wavers acc. to HINARI are available.

This section has its own submission website at https://mc.manuscriptcentral.com/e-videos

This document was downloaded for personal use only. Unauthorized distribution is strictly prohibited.