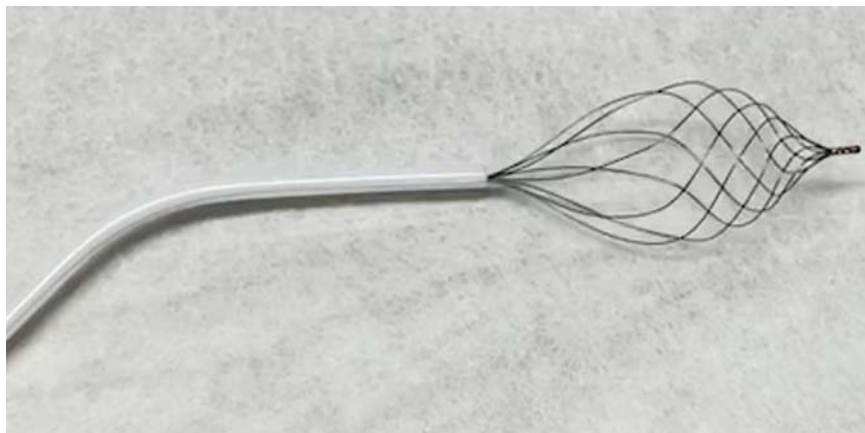

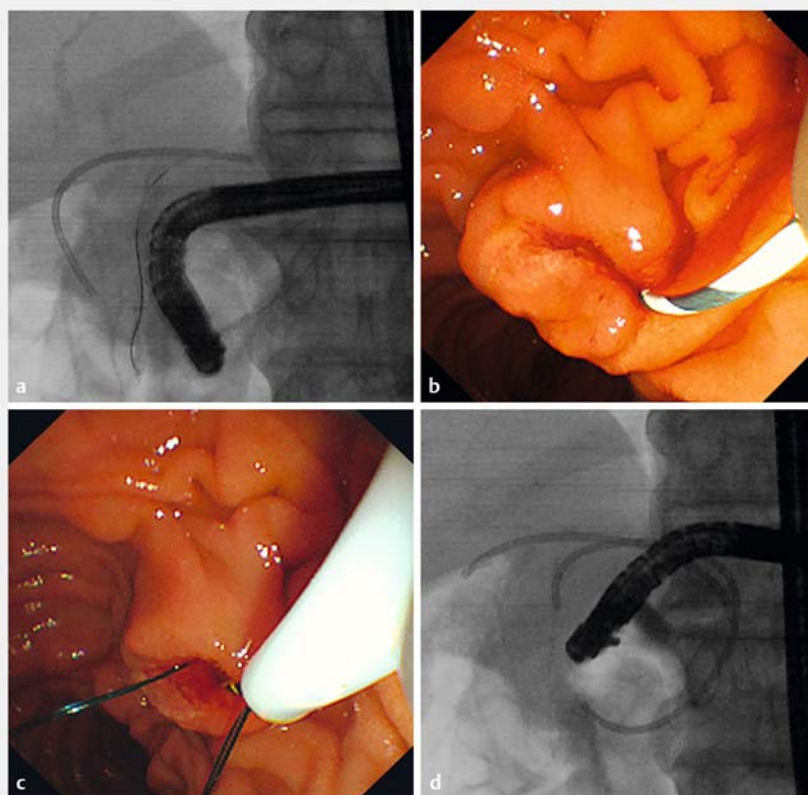
The novel basket catheter for retrieval of a migrated biliary inside stent

Many techniques have been reported for endoscopic retrieval of migrated biliary stents [1–4]. However, available devices such as forceps and snares are not suitable to grasp the migrated nylon thread attached to the biliary inside stent. The novel basket catheter (RASEN; Kaneka Medical, Osaka, Japan) with an 8-wire spiral structure is rotatable and effective in removing small biliary stones (► Fig. 1). We describe the technical tips for retrieval of a migrated inside-stent using the RASEN basket catheter.


A 69-year-old man with unresectable cholangiocarcinoma was admitted to our hospital owing to obstructive jaundice. At first, the inside stent was inserted in the anterior segmental branch for treatment of obstructive jaundice. However, he underwent endoscopic retrograde cholangiopancreatography 7 days later for additional biliary stent insertion in the posterior segmental branch owing to insufficient improvement in his jaundice symptoms. Although the posterior segmental branch was easily contrasted, the bile duct stricture was severe and required dilation using a thin balloon catheter (6-mm REN; Kaneka Medical). When insertion of the second biliary stent was attempted, the first stent migrated to the anterior segmental branch, and not only the distal end of the stent but also the nylon thread attached to the inside stent were not visible on the endoscopic image (► Fig. 2 a, b). We attempted to retrieve the migrated inside stent using the RASEN basket catheter. We inserted and opened the basket in the common bile duct and pulled it while slowly rotating it. Subsequently, we could easily grasp the nylon thread (► Fig. 2 c) and gently pull it. After returning the stent position without breaking the nylon thread, we released it in the duodenum. Finally, the second stent was inserted into the posterior segment branch without migration of the first stent (► Fig. 2 d, ► Video 1). The RASEN basket



► Fig. 1 Novel RASEN basket catheter. The tip of the basket has a dense structure. The basket is very effective for removing small biliary stones.



► Fig. 2 The biliary inside stent is migrated into the anterior segmental branch. a Fluoroscopic findings. b Endoscopic findings. c The nylon thread attached to the biliary inside stent is successfully caught using the RASEN basket catheter. d After the procedure, the two biliary stents are placed in fluoroscopic view.



Video 1 A migrated biliary inside stent was successfully removed using a novel basket catheter.

catheter might be useful for retrieval of a migrated biliary inside stent.

Endoscopy_UCTN_Code_TTT_1AR_2AZ

Competing interests

The authors declare that they have no conflict of interest.

The authors

Akihisa Ohno, **Nao Fujimori**, **Keisuke Hirahata**, **Takahiro Ueda**, **Yu Takamatsu**, **Takamasa Oono**

Department of Medicine and Bioregulatory Science, Graduate School of Medical Sciences, Kyushu University, Fukuoka, Japan

Corresponding author

Nao Fujimori, MD

Department of Medicine and Bioregulatory Science, Graduate School of Medical Sciences, Kyushu University, 3-1-1 Maidashi Higashi-ku, Fukuoka City, Fukuoka, Japan
Fax: +81-92-642-5287
fujimori.nao.239@m.kyushu-u.ac.jp

References

- [1] Fujimori N, Yasumori S, Oono T. Successful endoscopic retrieval of an embedded biliary stent using an intra-stent balloon inflation technique assisted by direct per-oral cholangioscopy. *Dig Endosc* 2021; 33: e97–e99
- [2] Kotha S, Berry P, Webster G et al. Cholangioscopic management of proximally migrated biliary stent using a novel through-

the-cholangioscope snare. *Endoscopy* 2020; 52: E5–E6

- [3] Jafri IH. A wire-loop technique for removal of embedded biliary stents. *Gastrointest Endosc* 2001; 53: 698
- [4] Vázquez Rey MT, González Conde B, Alonso Aguirre PA et al. Retrieval of proximally migrated plastic biliary stents using a metal stent. *Endoscopy* 2011; 43 (Suppl 2): E376

Bibliography

Endoscopy 2022; 54: E596–E597

DOI 10.1055/a-1711-4161

ISSN 0013-726X

published online 21.12.2021

© 2021. Thieme. All rights reserved.

Georg Thieme Verlag KG, Rüdigerstraße 14, 70469 Stuttgart, Germany

ENDOSCOPY E-VIDEOS

<https://eref.thieme.de/e-videos>



Endoscopy E-Videos is an open access online section, reporting on interesting cases and new techniques in gastroenterological endoscopy. All papers include a high quality video and all contributions are freely accessible online. Processing charges apply (currently EUR 375), discounts and waivers acc. to HINARI are available.

This section has its own submission website at <https://mc.manuscriptcentral.com/e-videos>