

# Interventional Treatment Options in Children with Extracranial Vascular Malformations

Vanessa F. Schmidt<sup>1</sup> Martin Olivieri<sup>2</sup> Beate Häberle<sup>3</sup> Max Masthoff<sup>4</sup> Sinan Deniz<sup>1</sup>  
Peter B. Sporns<sup>5,6</sup> Walter A. Wohlgemuth<sup>7</sup> Moritz Wildgruber<sup>1</sup>

<sup>1</sup>Department of Radiology, Ludwig Maximilian University Hospital, Munich, München, Germany

<sup>2</sup>Paediatric Thrombosis and Haemostasis Unit, Dr. von Hauner Children's Hospital Munich, Ludwig Maximilian University, Munich, Germany

<sup>3</sup>Department for Pediatric Surgery, Ludwig Maximilian University Hospital, Munich, München, Germany

<sup>4</sup>Clinic of Radiology, University Hospital Muenster, Muenster, Germany

<sup>5</sup>Department of Neuroradiology, Clinic for Radiology and Nuclear Medicine, University Hospital Basel, Basel, Switzerland

<sup>6</sup>Department of Diagnostic and Interventional Neuroradiology, University Medical Center Hamburg - Eppendorf, Hamburg, Germany

<sup>7</sup>Clinic and Policlinic of Diagnostic Radiology, Martin-Luther University Halle-Wittenberg, Halle (Saale), Germany

**Address for correspondence** Moritz Wildgruber, MD, PhD, Department for Radiology, University Hospital, LMU Munich, Marchioninistrasse 15, 81377, München (e-mail: moritz.wildgruber@med.uni-muenchen.de).

Hamostaseologie 2022;42:131–141.

## Abstract

Extracranial vascular malformations vary greatly and belong to the complex field of orphan diseases and can involve all segments of the vascular tree: arteries, capillaries, and veins, and similarly the lymphatic system. The classification according to the International Society for the Study of Vascular Anomalies (ISSVA) represents an important guidance for selecting appropriate therapy. Although many of the principles of endovascular treatment, including image-guided sclerotherapy and embolization, are similar in adult and pediatric practice, there are some distinct differences regarding the treatment of vascular malformations of children. Thus, it is crucial to involve longer-term plan about managing these chronic diseases and their impact on a growing child. This review provides a detailed overview over the clinical presentation of venous, lymphatic, and arteriovenous malformations in children and emphasizes the specifics of their interventional treatment options, including distinct pediatric dose limitations and procedure-related side effects.

## Keywords

- ▶ vascular malformation
- ▶ pediatric intervention
- ▶ endovascular treatment

## Zusammenfassung

### Schlüsselwörter

- ▶ Vaskuläre Malformationen
- ▶ pädiatrische Intervention
- ▶ interventionelle Behandlung

Extrakranielle vaskuläre Malformationen sind sehr variabel und gehören zum komplexen Feld der seltenen Erkrankungen. Sie können alle Segmente des Gefäßbaumes betreffen: Arterien, Kapillaren und Venen, sowie das Lymphgefäßsystem. Die Klassifizierung nach der International Society for the Study of Vascular Anomalies (ISSVA) stellt eine wichtige Orientierungshilfe für die adäquate Therapie dar. Obwohl viele der Prinzipien hinsichtlich der interventionellen Behandlung, wie der bildgesteuerten Sklerotherapie und Embolisation, im Grundsatz ähnlich zu denen erwachsener Patienten sind, gibt es einige deutliche Unterschiede bei der Behandlung von vaskulären

received

October 27, 2021

accepted after revision

December 23, 2021

© 2022. Thieme. All rights reserved.

Georg Thieme Verlag KG,

Rüdigerstraße 14,

70469 Stuttgart, Germany

DOI <https://doi.org/10.1055/a-1728-5686>.

ISSN 0720-9355.

ISSN 0720-9355.

Malformationen bei Kindern. Von entscheidender Bedeutung ist, die Behandlung dieser chronischen Erkrankungen und ihre Auswirkungen auf das heranwachsende Kind längerfristig zu betrachten. Diese Übersicht gibt einen detaillierten Überblick über die klinische Präsentation venöser, lymphatischer und arteriovenöser Malformationen bei Kindern und hebt die Besonderheiten der interventionellen Behandlungsoptionen hervor, einschließlich der spezifischen pädiatrischen Dosisbegrenzungen und therapieassoziiertes Nebenwirkungen.

## Introduction

Vascular malformations are part of the vascular anomalies spectrum, besides the second major entity of vascular tumors.<sup>1</sup> Both main groups represent disease patterns frequently becoming apparent in childhood.<sup>2</sup> While infantile hemangiomas, representing the most common group of vascular tumors, regularly demonstrate characteristic clinical features and a dedicated course during the first year of life, vascular malformations, according to their definition, are present from birth and may become clinically obvious during childhood or adolescence.<sup>3,4</sup> Consequently, a majority of patients suffering from extracranial vascular anomalies become symptomatic before adulthood and their clinical course may already be anticipated at this time.<sup>5</sup> Further difficulties may arise, such as to determine the most appropriate time point for therapy or balancing the patient's age against potential developmental impairment.<sup>2</sup> While the therapeutic spectrum for the treatment of infantile hemangiomas focuses on watch-and-wait or propranolol,<sup>6</sup> followed by the application of different laser therapies or conventional surgery for residual hemangioma tissue,<sup>7,8</sup> image-guided sclerotherapy or embolization are frequently the most appropriate therapy for different kinds of vascular malformations in children.<sup>9,10</sup> Specific genetic analyses are becoming increasingly important to look for underlying mutations while identifying potential syndromic diseases in patients with complex lesions.<sup>11,12</sup> Molecular-targeted therapy might become a possible therapeutic option in the future and is increasingly being applied in an off-label mode after identification of specific targets.<sup>13,14</sup>

Although the major principles of interventional treatment are similar in the adult and pediatric setting, there are some important differences in the approach for children, such as considering the impact of this chronic disease on a growing patient. Irrespective of the localization of the malformation, size reduction via interventional treatment in the form of sclerotherapy or embolization is usually aimed at reducing lesion extent, either as a sole treatment or prior to elective surgery additionally reducing the risk of perioperative complications, such as bleeding. In case of extensive vascular malformations, repeated procedures may be required; thus, this fact has to be conveyed to the children and their families in a patient-centered and positive manner.<sup>15,16</sup> Moreover, as vascular malformations rarely can be cured entirely, treatment goals have to be defined together with the child and family, to

avoid misunderstanding and disappointment in cases when parts of the lesion persist even after multiple treatments. Inter- and multidisciplinary treatment strategies in specialized vascular anomalies centers proved to achieve the best outcome results, where providing comprehensive care is in line with the current state of knowledge and experience.<sup>17</sup> As interventional radiology offers minimally invasive image-guided interventions besides a high diagnostic expertise, interventional radiologists can act as a coordinator within this interdisciplinary framework. In cooperation with the other clinical disciplines involved, as pediatrics, pediatric surgery, visceral surgery, ENT, plastic surgery, urology, and hemostaseology, an optimal and comprehensive treatment concept can be designed, in which each specialist contributes its relevant expertise.<sup>18</sup> This review aims to highlight the detailed clinical presentation of the different subtypes of venous (VM), lymphatic (LM), and arteriovenous malformations (AVM), as well as the corresponding interventional treatment options including radiation dose limitations and procedure-related side effects while considering the specificities related to pediatric patients.

## Interventional Treatment Options

As most vascular malformations involve multiple anatomic compartments, these cases are not suitable for superficial treatment or surgical resection alone. Regularly, interventional procedures consist as the first-choice therapy for children, particularly due to the adequate risk-benefit ratio, or they are combined with surgical resection. Although the malformation is not removed by the image-guided intervention, these options may lead to size reduction, functional improvement, and decreasing pain.<sup>19</sup>

Interventional treatment options include sclerotherapy, endoluminal ablation therapy, and embolization<sup>17</sup>; an overview is provided in [Table 1](#).

Sclerotherapy is used for treating symptomatic slow-flow vascular malformations, especially VMs and macrocystic LMs. The sclerosing agents introduced by direct puncture initially cause inflammation of the vessel wall, followed by fibrosis of the lesion.<sup>10</sup>

Endoluminal ablation procedures are mainly used in the management of embryonic dysplastic veins, such as the marginal vein (MV). In the case of connections to the draining deep vein system, their occlusion is essential for the prevention of thromboembolic complications.<sup>20</sup>

**Table 1** Overview of interventional treatment options in children

Interventional treatment option	Short description	Indication	Agents/Probes	Adverse events
Sclerotherapy	Vessel sclerosis by means of a sclerosing agent, insertion via direct puncture	VMs, macrocystic LMs	Ethanol (VM) Gelified ethanol (VM) Polidocanol (VM) OK-432 (LM) Doxycycline (LM) Bleomycin (LM)	- Local side effects such as necrosis and irreversible nerve injury, systemic complications such as central embolisms (ethanol as most aggressive agent with up to 20% major complications)
Endoluminal ablation	Endoluminal vessel sclerosis by means of laser or hyperthermia	Marginal veins	Laser/radiofrequency probes	
Embolization	Occluding vessels by means of embolization materials (embolization agents, plugs, coils), in most cases endoluminally via inserted angiographic catheters	AVMs, AVFs	Ethanol (AVM) N-butyl-2-cyanoacrylate (AVM) Ethylene-vinyl-alcohol-copolymer (AVM) Plugs/coils (AVF)	- Risk of accidental nontarget embolization via the venous outflow (due to high blood flow) - Biological aggressiveness of the underlying disease with risk of rapid recurrence after incomplete embolization

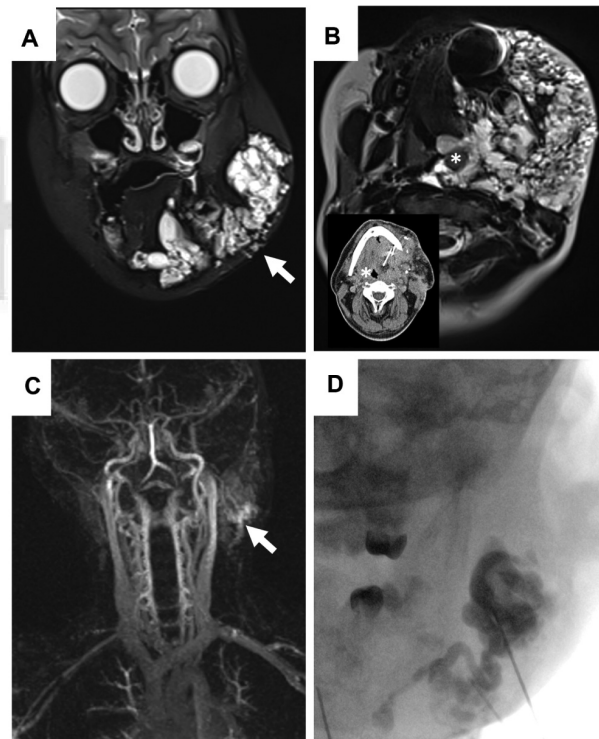
Abbreviations: AVM, arteriovenous malformation; AVF, arteriovenous fistula; LM, lymphatic malformation; VM, venous malformation.

Embolization aims at occlusion of blood vessels, in most cases endoluminally via inserted angiographic catheters. While predominantly used in the treatment of symptomatic fast-flow lesions such as AVMs and arteriovenous fistulas (AVFs) by various embolization agents, the aim is the complete occlusion of the arteriovenous shunt, the so-called nidus, and, if required, the venous outflow. The agents can be introduced under catheter guidance via artery, vein, or direct puncture. The risk of acute nontarget embolization due to dislocation via venous outflow has to be considered in fast-flow lesions.<sup>9</sup>

Currently, there is no consensus on anticoagulation following interventional treatments such as embolization and sclerotherapy; however, many people use anticoagulation with weight-adapted low-molecular-weight heparin for a period of 3 to 7 days. Recently, rivaroxaban has been approved as the first selective factor Xa inhibitor for use in children by the European Medical Association (EMA).

### Venous Malformations

VMs are the most frequent type of vascular malformations occurring with a prevalence of approximately 1% in the population. They appear mostly sporadic as common VMs presenting with focal, multifocal, or diffuse manifestations, as well as part of syndromic disorders (e.g., blue rubber bleb nevus [Bean] syndrome).<sup>21</sup> Errors during venous embryogenesis result in dilated and dysfunctional thin-walled veins and venules with scant smooth muscle cells, which can involve any organ and multiple tissue types<sup>22</sup> resulting in a range of morphologies, from well-defined, spongiform lesions to complex tangles of dysplastic veins<sup>23</sup> (see ▶Fig. 1). Clinically, VMs manifest as soft, nonpulsatile, and compressible lesions that usually show a bluish/purplish discoloration in case of superficial lesions. VMs can increase in volume due to increased hydrostatic pressure, extremes of temperature, or Valsalva.<sup>24</sup> Their growth can be stimulated following trauma or partial resection as well as during hormonal changes at puberty or pregnancy.<sup>25</sup> Symptoms of VMs include pain, swelling, disfigurement, functional im-



**Fig. 1** Venous malformation of the face and neck in a 1-year-old girl. (A) MR images of an extensive venous malformation. Coronal view demonstrates T2 hyperintense dysplastic venous cavities, beginning in the subcutaneous fat (arrow) infiltrating the masseter muscle and deeper tissues. (B) Transverse images reveal infiltration of all tissue layers extending into the paratracheal structures, imposing a high risk for tracheal stenosis (asterisk) or occlusion in case of volume increase of the lesion; lower left image shows CT-guided puncture of paratracheal malformation for sclerotherapy. (C) Dynamic MR angiography reveals only late filling of the malformation (arrow), corresponding to the slow-flow situation. (D) Fluoroscopy following percutaneous puncture and contrast injection reveals communicating dysplastic venous channels, infiltration of all tissue layers of the face and neck.

pairment, and localized intravascular coagulation (LIC) with raised fibrin degradation products, which may cause recurrent thrombosis and thrombophlebitis.<sup>26</sup> The latter, a unique chronic consumptive coagulopathy, occurs particularly in

larger VMs, while this ongoing consumption of clotting factors due to stasis in the lesion may result in severe systemic coagulopathy accompanied by low factor XIII, low fibrinogen levels, and increased D-dimers in extensive cases. These complications may significantly limit daily activities and the negative impact on a child's quality of life consecutively contributes to a family's decision to pursue rather aggressive therapeutic strategies. In addition, LIC increases the children's risk for intralesional thrombosis as well as the peri-interventional risk for hemorrhage.<sup>27–29</sup> VMs with LIC show all components of the Virchow's triad including abnormality of the vascular wall, stasis of blood flow, and activation of the coagulation cascade.<sup>30</sup> Here, a multidisciplinary approach and experienced hemostaseological management including extended coagulation function indexes, such as prothrombin time, thrombin time, activated partial thromboplastin time, international normalized ratio, fibrinogen, antithrombin, platelets, and D-dimers, as primary indicators of LIC are crucial.<sup>31</sup> Severe thrombogenic coagulopathies in children especially with large vascular malformations can be improved by anticoagulation.<sup>26</sup>

Similar to the therapeutic strategies in adults, treatment of pediatric VMs includes conservative (anticoagulation, compression garments), interventional (sclerotherapy), and surgical options. Depending on the clinical appearance of the lesion, conservative treatment can suffice, exemplarily reassuring that small pain-free malformations do not progress into more aggressive VMs. In case of mass effect or venous congestion, well-tailored compression garments may relieve symptoms in a simple and noninvasive manner.<sup>32</sup> If their wearing is accepted by the young patients, these are an effective tool, particularly in dependent lesions as well as in VMs presenting aggravated in activity.

In general, sclerotherapy is considered as the first-line intervention for VMs in both children and adults. Several pediatric studies could show that it is effective in shrinking small lesions while controlling symptoms in larger lesions.<sup>33–36</sup> Sclerotherapy has been proven to close and scar the dysfunctional veins and venules, and consequently to reduce venous congestion, mass effect, and thrombosis.<sup>37</sup> An important aspect in case of pediatric patients is an intra-articular lesion extension, presented frequently around the knee, as this may lead to recurrent hemarthroses with consecutive potential to cause destructive arthropathy.<sup>38</sup> Preventing this severe complication indicates early intervention even in asymptomatic joints of young children. While the choice of the sclerosing agent is rarely different between adults and children, it is essential to keep in mind that there are severe potential side effects and specific weight-dependent dose limitations.

For several years, ethanol has been the most frequently used sclerosant, but has recently lost its popularity due to high complication rates including nerve injury and skin necrosis, as well as dose limitations by the risk of respiratory depression, rhabdomyolysis, cardiac arrhythmia, or sudden death. These local and systemic side effects are described already using low doses,<sup>39,40</sup> which consecutively should be weighed against the high effectiveness of ethanol due to

direct vessel wall necrosis and disruption of erythrocytes, with subsequent thrombosis and fibrosis of the intima.<sup>41</sup>

Sodium tetradecyl sulfate (STS) is a commonly used agent with maximum effectivity owing to the detergent properties including its interference with cell surface lipids. STS is characterized by high endothelium damage while producing low thrombus formation with the result of fibrosis and consecutive shrinking of the lesion.<sup>37</sup> Because of hemoglobinuria, there may be observed oliguria and urine discoloration within a few hours after STS sclerotherapy in particular after the use of relatively high amounts of the sclerosant.<sup>42</sup> To avoid the risk of renal insufficiency, peri-interventional strategies as bladder catheterization and intravenous hydration have been proposed without being established as standard procedures. Although renal injury may mostly be temporary, it is advisable to remain within certain dose limits. Additionally, the amount of administered STS should be adjusted regarding the morphological characteristics of the lesion as well as the surrounding structures. Especially in restricted or anatomically sensitive areas (e.g., at distal extremities or the face), STS potentially causes relevant side effects as swelling, nerve injury, skin ulceration, or deep vein thrombosis.<sup>43</sup> In children, a maximum (STS 3%) dose per endovascular treatment of 0.5 mL/kg can be assumed, up to a maximum of approximately 20 mL.<sup>44</sup> The most frequent use of STS as foam is characterized by wide-ranging variations in its composition including the admixture of air, ethiodized oil, contrast medium, or albumin solution. The resulting foamed sclerosant slowly fills the dysplastic vessels while improving wall contact for efficient endothelial damage. Thus, pediatric patients benefit from an increased STS volume for the same agent dose.<sup>45</sup>

Polidocanol, a synthetic long-chain fatty alcohol applied as foam, is characterized by slightly less treatment efficiency with a correspondingly lower side effect profile.<sup>46</sup> Thus, polidocanol is a mild sclerotherapy option, but may show similarly good treatment results after repeated sessions.<sup>47,48</sup>

Bleomycin, a cytostatic agent belonging to the class of antibiotics, differs in its underlying sclerosing mechanism from the previously mentioned sclerosants. As dismantling the solid stroma of vascular structures,<sup>49</sup> it seems to be most efficient in comparatively spongiform VMs providing large stromal components. Bleomycin may not show neurotoxic effects; thus, it is reliably used near nerve structures. Additionally, postinterventional swelling or skin complications may be less common compared with other agents. Bleomycin can be admixed with ethiodized oil, albumin, or gelatin sponge slurry, to decrease the wash-out rate of the sclerosant from the lesion but potentially augmenting its efficiency.<sup>49</sup> In case of resistance to prior invasive treatment, the combination of injected bleomycin with reversible electroporation may improve therapy outcome.<sup>50</sup>

In case of relatively solid lesions presenting resistive to previous sclerotherapy, the evidence increases that percutaneous cryoablation may be a further feasible and safe treatment alternative.<sup>51–53</sup>

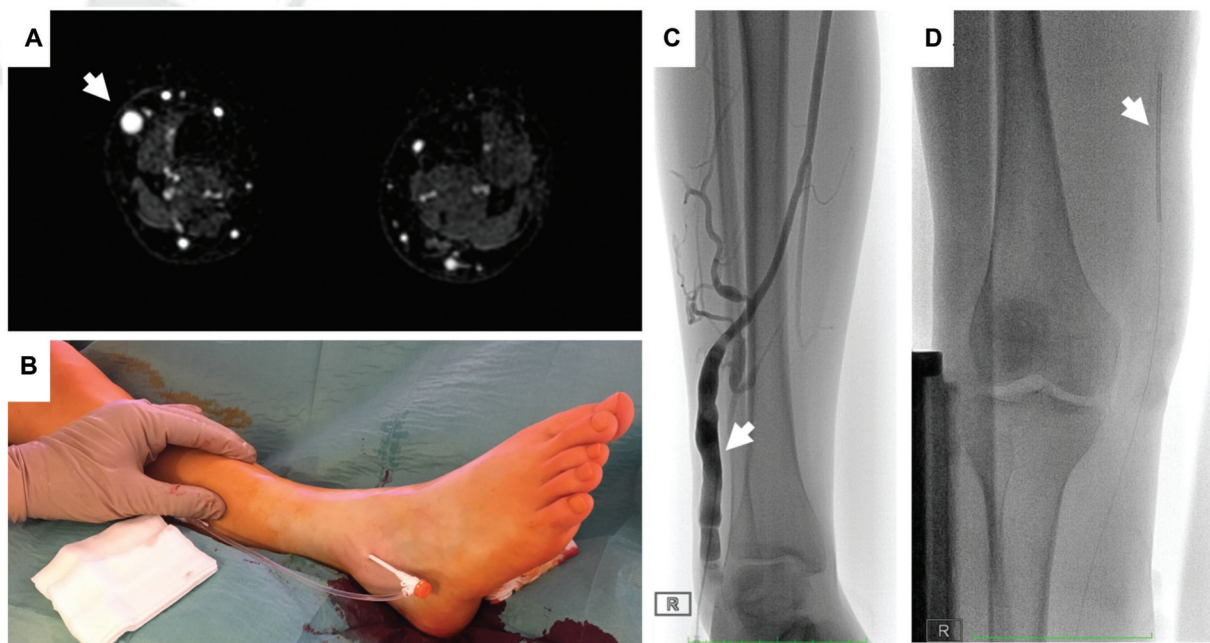
MVs are a special type of tubular VMs caused by defective development during the later stage of embryogenesis while

the vein trunk is already formed. Clinically, chronic venous insufficiency may occur due to a unique condition of avallulosis. Additionally, MVs increase the risk for venous thromboembolism owing to the structural defect with a lack of smooth muscle cells to form the media properly as a truncular VM infrequently resulting in fatal pulmonary embolism. Together with LM, MV is one of two clinically most important congenital vascular malformation components among Klippel-Trenaunay syndrome.<sup>54</sup> Beyond lateral MV excision,<sup>55</sup> interventional treatment may present as alternative: Radiofrequency ablation was shown effective as the treatment of the marginal venous system (see ▶ Fig. 2), while it should be treated early in life. MVs with large diameter, intrafascial courses, and residual tributaries frequently require additional coil embolization and sclerotherapy.<sup>20</sup>

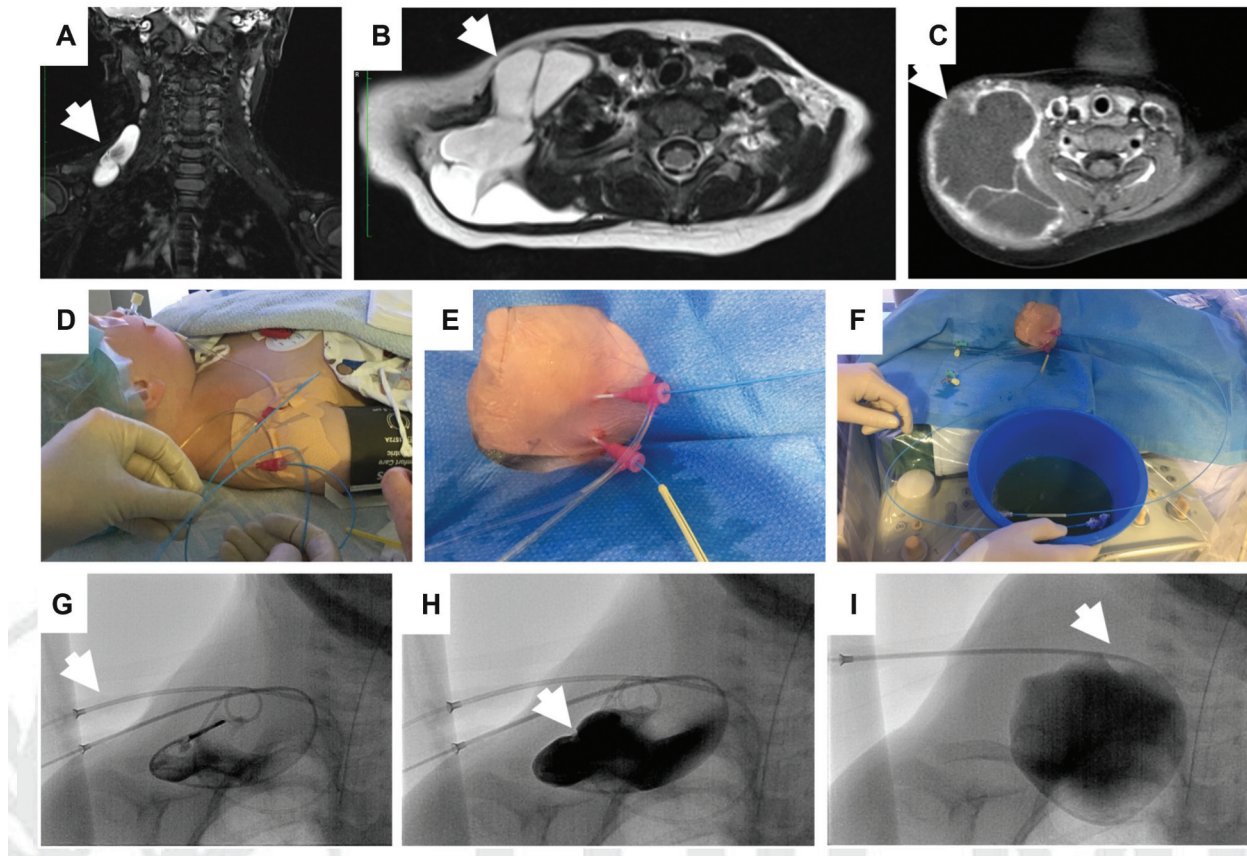
The categorization of VMs according to the Puig classification plays a crucial role as it may potentially predict the treatment response based on appearance and venous drainage.<sup>56</sup> Type I VMs present isolated without detectable drainage into surrounding veins, type II VMs drain into nondilated normal veins, and type III VMs reveal drainage into dilated and type IV VMs into dysplastic veins.<sup>23</sup> In the last two categories, both the success of minimally invasive treatment decreases and sclerotherapy has to be monitored carefully owing to potential agent dislocation into draining veins and consecutive systemic thromboembolism. This can be managed by using coils and/or glue to internally obstruct the outflow tract or simply by extrinsically placing pressure over the outflow vessels.<sup>57,58</sup>

### Lymphatic Malformations

LMs, found in 0.1 to 2% of the population, consist of circumscribed dilated, thin-walled channels and spaces containing lymphatic fluid, but without apparent connection to the lymphatic system.<sup>59</sup> These lesions can be present at birth or occur later in early childhood, classified as macrocystic (e.g., cyst size  $\geq 2$  cm), microcystic (e.g., cyst size  $< 2$  cm), and mixed type.<sup>60</sup> Of note, there is no clear consensus considering this categorization of macro- and microcystic LMs. They typically affect the cervicofacial and axillary areas; nevertheless, LMs can potentially appear at any part of the body. Characterized by the appearance in young childhood, in general, they are timely treated prior to the transition to adult practice. They may grow fast and swell during concomitant infectious illnesses. LMs appear as a flesh-colored soft mass as well as blue colored in case of intralesional hemorrhage or intermittent infections. The latter is particularly frequent if the lesion affects mucosa. Involvement of skin or mucosa is characterized by fine surface vesicles, commonly with punctate black or red markings due to admixture of blood. Functional impairment of adjacent structures can lead to pain and swelling, additionally disfigurement of affected areas including cellulitis may be presented frequently. Microcystic lesions can be accompanied by localized fat hypertrophy, which is crucial to recognize, as this may limit the amount of bulk reduction that can be realized, and the children's and parents' expectations should be managed correspondingly. Generalized LMs can be shown as generalized lymphatic anomaly (GLA) or as Gorham-Stout disease.<sup>61</sup> The latter mostly (and aggressively) affects the bones, while



**Fig. 2** Radiofrequency ablation (RFA) of marginal vein (MV) of the right leg in an adolescent girl. (A) Dynamic contrast-enhanced MRI shows MV (arrow) coursing along the lateral aspect of the right calf. (B) Peri-interventional setting with 7-F introducer sheath inserted in the distal aspect of the MV. (C) Phlebography showing the ectatic MV (arrow) in the lateral aspect of the lower limb before endovenous RFA. (D) RFA catheter (arrow) is placed in the proximal aspects of the MV.



**Fig. 3** Percutaneous image-guided sclerotherapy of a cervicothoracic lymphatic malformation in a 3-year-old child. (A) Coronal T2-weighted fat-saturated MR image reveals (arrow) fluid levels indicative of recent hemorrhage. (B) Axial T2-weighted MR images present macrocystic lesion type with septal thickening (arrow) involving the right cervicothoracic area. (C) Following contrast application, only septal structures reveal prominent enhancement, while central lymphatic spaces do not fill with gadolinium. (D–H) Fluoroscopy-guided imaging and drainage of macrocystic lesions before inserting the sclerosing agent. (I) Percutaneous needle assessment and sclerotherapy using fluoroscopy guidance.

GLA is described as multifocal cystic lesions involving numerous organ systems as well as the bones. Further clinical presentations of generalized LMs include splenic and hepatic cysts as well as pleural effusions.<sup>62</sup>

Indications for endovascular treatment of LMs are intermittent infections, intralesional hemorrhage, mass effect, or functional and aesthetic impairment. Percutaneous sclerotherapy of macrocystic lesions should be performed with the aim to drain them to near-total dryness (see ▶Fig. 3). For simple macrocystic LMs, one endovascular procedure may suffice, while complex LMs may require multiple treatment sessions. Usually, infants and young children will, of course, require general anesthesia (GA) for sclerotherapy, non-GA procedures can be desirable and adequate for older children. It has been described that GA in the first year of life may have long-term effects on a child's development; this may highlight the approach to delay endovascular treatment of asymptomatic LMs.<sup>63</sup> Sclerotherapy of challenging, extensive macrocysts (e.g., frequently seen in neonatal cervicofacial or in mesenteric lesions) can be performed in use of pigtail drains with multiple sideholes inserted during the first treatment, which allows serial procedures over subsequent days while the children are awake.<sup>18</sup> A small part of LMs shrink spontaneously in the first months after birth; in these asymptomatic, young babies, delay of intervention can be

adequate. In case of indications for treatment immediately after birth, the aim should be to shrink the LMs to enable the child to move head and feed to put on weight before elective surgery some months later. Even if the macrocystic components are often impressive, superficially visible findings, it has to be kept in mind that the deep components are responsible for causing functional impairment.<sup>64</sup> Regarding the head and neck lesions, as the most common localization, the possibility of swelling after sclerotherapy has to be considered, potentially requiring protective intubation for a few days.<sup>65</sup> However, this complication should be generally possible to avoid if the procedure is performed carefully and with consideration of distinct high-risk locations<sup>66,67</sup> (e.g., the tongue and the pharynx). The latter can pose even more clinical challenges: due to mucosal involvement, the tongue surface may be very susceptible to infection, bleeding, as well as irritation during feeding. If deeper tissue layers are affected, the children present with macroglossia.<sup>68</sup>

Sclerosing agents in LMs do not require to be foamed, as 360-degree wall contact is easy to achieve in collapsed macrocysts, compared with VMs. Doxycycline is one of the most chosen sclerosants, due to its good availability, the high safety profile, and the reliable data existing on doxycycline sclerotherapy outcomes.<sup>69–71</sup> The dose limits of doxycycline depend more on the children's size than on the volume of

fluid drained. The recently reported recommendations amount to approximately 100 to 200 mg doxycycline per endovascular treatment in infants, 300 to 500 mg in young children, and up to 1,200 mg in adolescents.<sup>72</sup> Based on systemic doxycycline absorption, postinterventional metabolic acidosis, transient hypoglycemia, and hemolytic anemia have been reported in babies.<sup>73</sup> In general, monitoring of blood glucose levels should be performed in pediatric patients up to the age of 1 year (until they begin to feed again).<sup>74</sup> To avoid stinging during injection, macrocysts can be pretreated with a small amount of local anesthesia.

STS may represent as alternative while demonstrating comparable complication rates. Mainly reported as just as effective as doxycycline,<sup>75</sup> inferior outcome results have also been described.<sup>76</sup>

OK-432 or Picibanil, a lyophilized form of group A streptococcus pyogenes, which is incubated with benzylpenicillin, is rarely used as sclerosant for lymphatic lesions currently, due to lack of availability,<sup>77</sup> although excellent long-term outcomes have been shown.<sup>78</sup> OK-432 may mediate its effect by stimulating inflammatory response of the endothelium via intercellular adhesion molecule 1 (ICAM-1) expression.<sup>41</sup> There are reported low minor-complication rates including postinterventional pyrexia and transient swelling, though the latter has led to intubation and subsequent tracheostomy described in one case of LM located at the tongue.<sup>79</sup>

Dual-agent approaches can be used in LMs not responding sufficiently to simple doxycycline sclerotherapy: Prior to intralésional administration of a standard dose of doxycycline, ethanol or STS can be instilled into the cyst while leaving it to dwell for approximately 5 minutes before aspirating it. Thereby, the first agent denudes the endothelial lining of the cysts enabling the second sclerosant to be more effective.<sup>80</sup>

Microcystic LMs are significantly more difficult to treat: In rather solid lesions, bleomycin may achieve the most sufficient bulk reduction.<sup>81,82</sup> Thereby, it is important to instill the entire lesion with bleomycin, involving the solid components or stromal tissue, as it may be even more effective in these areas. Similar to VMs, bleomycin can be mixed with further agents to increase viscosity, dwell time, and, consecutively, efficiency. In general, bleomycin as cytotoxic drug should be avoided under the age of 1 as well as the maximum dose should be restricted consequently in older children (15,000 IU per endovascular treatment from infancy: and a lifetime dose of 2–3,000 IU per kg up to 80–100,000 IU). When instilled in lymphatic lesions, it is very unlikely that bleomycin is absorbed systemically, though it may be good clinical practice to avoid additional oxygen if not clinically requested, as it potentially increases the risk of pulmonary fibrosis.<sup>83–85</sup> Furthermore, the use of adhesives should be avoided peri-interventional as well as the children should be informed not to scratch their skin for approximately 48 hours after treatment, as bleomycin is washed out of the dermal soft tissue and also to avoid hyperpigmentation.<sup>86</sup> Bleomycin can also induce stinging on injection, which can be reduced by prior mixing with a small dose of local anesthetic.

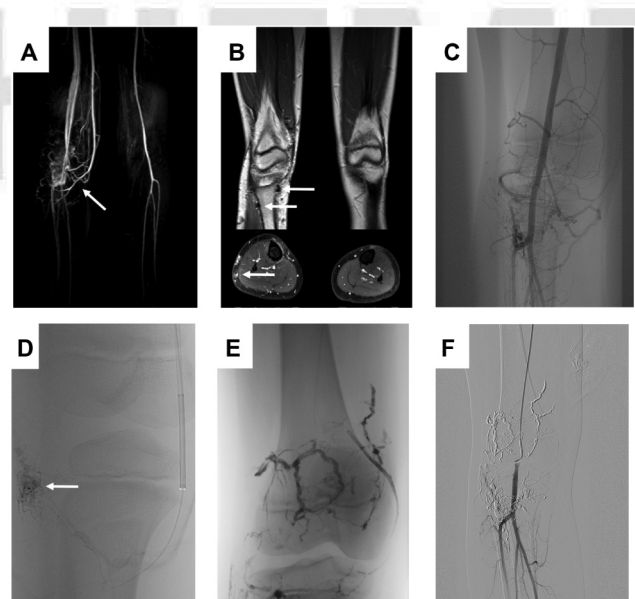
Surgical debulking of complex or large LMs can often result in the postoperative formation of seromas. As in

many cases predictable, this should not be seen as a treatment complication.<sup>87</sup> The interdisciplinary team members should be aware that these seromas can be managed by endovascular treatment as well; thus, sclerotherapy through the surgical drains can be conducted if necessary.

Sirolimus, an inhibitor of the mechanistic target of rapamycin (mTOR), is reported to be effective in treating some types of LMs,<sup>88,89</sup> as these lesions are result of somatic or mosaic PIK3CA mutations. Up to date, evidence is lacking on adequate dose regimens, or on which type of lesion may respond appropriately. Once sirolimus is stopped, there are high recurrence rates; additionally, the drug-related side effects may be significant.<sup>88</sup> Due to this, the use of sirolimus is limited to complex or extensive lesions, such as generalized LMs.<sup>90,91</sup> Furthermore, molecular-targeted therapy strategies are emerging and promising; for example, there is first evidence, which proposes direct inhibition of PIK3CA as therapeutic option providing clinical benefit in patients with PIK3CA-related overgrowth spectrum.<sup>92</sup>

### Arteriovenous Malformations

AVMs represent less than one-third of all types of vascular malformations. As fast-flow lesions, they may occur sporadic



**Fig. 4** Fast-flow arteriovenous malformation in a 10-year-old girl. (A) Typical MRI presentation of a fast-flow AVM, located around the right knee with multiple feeding arteries arising from the superficial femoral artery, popliteal artery, and anterior tibial artery, with early venous filling of the femoral vein due to AV shunting. (B) Flow-voids representative for fast-flow lesion could be detected around the knee (arrows) and additionally within draining veins (lower panel in B) in the subcutaneous fat (arrow), as sign of arterialized venous flow patterns. (C) Transarterial angiogram shows multiple dysplastic arteries feeding a central nidus from multiple sites. (D) Positioning of the microcatheter within the AVM nidus for subsequent transarterial embolization. (E) Following extensive embolization the dark EVOH cast can be seen with dysplastic AVM vessels. (F) Post-embolization angiogram reveals subtotal occlusion of the AVM with patent lower limb arteries. Of note, subsequent embolization sessions were required in this case to achieve a complete devascularization of the AVM.

or associated with syndromes (e.g., Parkes Weber syndrome, hereditary hemorrhagic telangiectasia, or CM-AVM).<sup>60</sup> While persisting since embryonic development, AVMs are the result of an atypical direct connection between arteries and veins without an interposed capillary bed (see **Fig. 4**). Characteristically, there is a low-resistance net-like nidus linked to multiple feeding arteries and draining veins, whereas the normally intermittent capillary bed is either entirely or partly lacking.<sup>93</sup> Histologically identified by thick-walled arteries and arterialized thick-walled veins, AVMs are most frequently located in the head and neck region. On clinical examination, superficial malformations may present relatively compressible and are accompanied by warmth, a pink-red cutaneous stain, and a palpable bruit or thrill. Owing to the fast-flow shunting, there is no gradual pressure decrease from the arterial pressure to the lower pressure on the venous side. This may have consecutive hemodynamic effects resulting in local hypervascularity, peripheral ischemia, steal phenomenon, and increased venous pressure with possible clinical features such as pain, tissue overgrowth, hyperemia, bleeding, ulceration, and gangrene up to high-output cardiac failure.<sup>94,95</sup> According to the Schobinger classification, the natural history is composed of four distinct stages: quiescent, growing, symptomatic, and decompensating.<sup>96</sup> As during childhood, the aforementioned symptoms are rarely observed in full or severe expression, children frequently do not have clinical problems initially (during lifetime AVMs tend to continually progress). Similar to AVMs in adults, treatment decisions may be extremely challenging: While it is reasonable to delay invasive therapy until the AVM presents symptomatically, waiting may result in a situation which is already accompanied by significantly more difficult treatment conditions. Some of the childhood AVMs may show episodes of rapid growth, typically around puberty. Though it is challenging to predict which lesions will present like this, it further complicates adequate therapy decisions. A significant and common long-term effect of an AVM located in direct proximity to a growth plate is caused by its impact on bone growth. In these lesions, treatment should be performed even if the young patients are asymptomatic.<sup>97</sup> Of note, embolization of these high-flow lesions may also result in asymmetric or impeded growth, requiring subsequent orthopaedic correction. The approach regarding embolization of extracranial high-flow lesions in children is in general similar to the one in adults.

In use of ethanol as embolic agent in children, cautious dose limits should be preserved. Based on its efficacy in damaging the endothelial tissue with consecutive eradication of angiogenic growth factors production, it may be highly effective in treating high-flow lesions.<sup>40</sup> Due to the potential aggressive character, maintaining a dose limit of 0.5 mL/kg per procedure is suggested.<sup>72</sup>

The nonadherent ethylene vinyl alcohol copolymer (EVOH)-based liquid embolic agents show a low tendency to migrate beyond the target sites, in comparison to ethanol.<sup>98</sup> Additionally, they result in low inflammatory reactions of the vessel wall, while remaining intravascular with decreased permanent reaction of the surrounding interstitial

tissue. Consecutively, fewer complications were described compared with pure ethanol, while EVOH offers distinct formulations with different degrees of viscosity and radioactivity.<sup>99,100</sup> The effectivity is high when used properly.<sup>101</sup> Nevertheless, these agents also may be used with caution: EVOH-based liquid embolic agents are typically suspended in dimethyl-sulfoxide (DMSO). On agent administration, DMSO diffuses out of the solution and into the blood circulation, thus allowing EVOH to polymerize. After injection, systemic DMSO is excreted via the lungs. There have been described some cases of DMSO toxicity, including life-threatening complications as hemolysis, pulmonary edema, and renal failure after AVM embolization using EVOH, which may be dose related.<sup>102</sup> Further complications reported after EVOH embolization are procedure-related embolic events,<sup>103</sup> skin necrosis, or local infections, the third may potentially induce consecutive EVOH extrusion.

Application of interstitial bleomycin has also been proposed as a further alternative of treating symptomatic high-flow lesions,<sup>104</sup> although the mechanism of action of bleomycin in this setting is not yet understood in detail.

## Conclusion

Vascular malformations are among the most challenging vascular diseases, especially in the pediatric setting. Defining the right timing of therapy is challenging, as lesion behavior and progression may not be predicted with certainty. Minimally invasive interventional treatments represent an important part of the multimodal therapy concepts in children and there are multiple sclerosing and embolic agents, each with specific characteristics. In addition to the already complex treatment decisions, there are specific features in children having to be considered during the procedures, including dose limitations and potential side effects. Beyond these interventions, also conservative options, surgery, and new treatment approaches such as molecular-targeted therapies should complement each other, individually used while adapted to the child's clinical presentation and malformation type. Surgical debulking after size reduction may improve functionality while reducing recurrence rates. Novel combined strategies of interventional treatment and supplemented targeted drugs may provide better therapy outcomes and patient satisfaction. All in all, a multidisciplinary concept in specialized pediatric centers for vascular anomalies should be aimed at, in which the cooperating disciplines present with wide-ranging experience in longer-term therapy concepts.

## Conflict of Interest

The authors declare that they have no conflict of interest.

## References

- 1 Mulliken JB, Glowacki J. Hemangiomas and vascular malformations in infants and children: a classification based on endothelial characteristics. *Plast Reconstr Surg* 1982;69(03):412–422
- 2 Greene AK, Liu AS, Mulliken JB, Chalache K, Fishman SJ. Vascular anomalies in 5,621 patients: guidelines for referral. *J Pediatr Surg* 2011;46(09):1784–1789



- 3 Greene AK, Rogers GF, Mulliken JB. Intraosseous “hemangiomas” are malformations and not tumors. *Plast Reconstr Surg* 2007;119(06):1949–1950
- 4 Cohen MM Jr. Vasculogenesis, angiogenesis, hemangiomas, and vascular malformations. *Am J Med Genet* 2002;108(04):265–274
- 5 Mulligan PR, Prajapati HJ, Martin LG, Patel TH. Vascular anomalies: classification, imaging characteristics and implications for interventional radiology treatment approaches. *Br J Radiol* 2014;87(1035):20130392
- 6 Léauté-Labrèze C, Hoeger P, Mazereeuw-Hautier J, et al. A randomized, controlled trial of oral propranolol in infantile hemangioma. *N Engl J Med* 2015;372(08):735–746
- 7 Chinnadurai S, Sathe NA, Surawicz T. Laser treatment of infantile hemangioma: a systematic review. *Lasers Surg Med* 2016;48(03):221–233
- 8 Satterfield KR, Chambers CB. Current treatment and management of infantile hemangiomas. *Surv Ophthalmol* 2019;64(05):608–618
- 9 Cantasdemir M, Gulsen F, Solak S, Gulsen GY, Kantarci F, Numan F. The use of Onyx for embolization of peripheral vascular malformations in pediatric patients. *Pediatr Surg Int* 2012;28(05):477–487
- 10 Markovic JN, Nag U, Shortell CK. Safety and efficacy of foam sclerotherapy for treatment of low-flow vascular malformations in children. *J Vasc Surg Venous Lymphat Disord* 2020;8(06):1074–1082
- 11 Al-Olabi L, Polubothu S, Dowsett K, et al. Mosaic RAS/MAPK variants cause sporadic vascular malformations which respond to targeted therapy. *J Clin Invest* 2018;128(04):1496–1508
- 12 Martinez-Lopez A, Salvador-Rodriguez L, Montero-Vilchez T, Molina-Leyva A, Tercedor-Sanchez J, Arias-Santiago S. Vascular malformations syndromes: an update. *Curr Opin Pediatr* 2019;31(06):747–753
- 13 Schmidt VF, Wieland I, Wohlgenuth WA, Ricke J, Wildgruber M, Zenker M. Mosaic RASopathy due to KRAS variant G12D with segmental overgrowth and associated peripheral vascular malformations. *Am J Med Genet A* 2021;185(10):3122–3128
- 14 Gross AM, Frone M, Gripp KW, et al. Advancing RAS/RASopathy therapies: An NCI-sponsored intramural and extramural collaboration for the study of RASopathies. *Am J Med Genet A* 2020;182(04):866–876
- 15 Patel PA, Barnacle AM. Re: Disorders of the lymphatic system of the abdomen. *Clin Radiol* 2017;72(01):91–92
- 16 Wildgruber M, Sadick M, Müller-Wille R, Wohlgenuth WA. Vascular tumors in infants and adolescents. *Insights Imaging* 2019;10(01):30
- 17 Müller-Wille R, Wildgruber M, Sadick M, Wohlgenuth WA. Vascular anomalies (Part II): interventional therapy of peripheral vascular malformations. *Rofo* 2018. Doi: 10.1055/s-0044-101266
- 18 Gibson CR, Barnacle AM. Vascular anomalies: special considerations in children. *CVIR Endovasc* 2020;3(01):60
- 19 Ali S, Mitchell SE. Outcomes of venous malformation sclerotherapy: a review of study methodology and long-term results. *Semin Intervent Radiol* 2017;34(03):288–293
- 20 Uller W, Hammer S, Wildgruber M, Müller-Wille R, Goessmann H, Wohlgenuth WA. Radiofrequency ablation of the marginal venous system in patients with venous malformations. *Cardiovasc Intervent Radiol* 2019;42(02):213–219
- 21 Dobru D, Seuchea N, Dorin M, Careianu V. Blue rubber bleb nevus syndrome: case report and literature review. *Rom J Gastroenterol* 2004;13(03):237–240
- 22 Dompmartin A, Vikkula M, Boon LM. Venous malformation: update on aetiopathogenesis, diagnosis and management. *Phlebology* 2010;25(05):224–235
- 23 Puig S, Casati B, Staudenherz A, Paya K. Vascular low-flow malformations in children: current concepts for classification, diagnosis and therapy. *Eur J Radiol* 2005;53(01):35–45
- 24 Hage AN, Chick JFB, Srinivasa RN, et al. Treatment of venous malformations: the data, where we are, and how it is done. *Tech Vasc Interv Radiol* 2018;21(02):45–54
- 25 Hassanein AH, Mulliken JB, Fishman SJ, Alomari AI, Zurakowski D, Greene AK. Venous malformation: risk of progression during childhood and adolescence. *Ann Plast Surg* 2012;68(02):198–201
- 26 Zhuo KY, Russell S, Wargon O, Adams S. Localised intravascular coagulation complicating venous malformations in children: associations and therapeutic options. *J Paediatr Child Health* 2017;53(08):737–741
- 27 Mazereeuw-Hautier J, Syed S, Leisner RI, Harper JJ. Extensive venous/lymphatic malformations causing life-threatening haematological complications. *Br J Dermatol* 2007;157(03):558–563
- 28 Budge EJ, Khalil Allam MA, Mechie I, Scully M, Agu O, Lim CS. Venous malformations: coagulopathy control and treatment methods. *Phlebology* 2021;36(05):361–374
- 29 Aronniemi J, Långström S, Mattila KA, et al. Venous malformations and blood coagulation in children. *Children (Basel)* 2021;8(04):312
- 30 Adams DM. Special considerations in vascular anomalies: hematologic management. *Clin Plast Surg* 2011;38(01):153–160
- 31 Han YY, Sun LM, Yuan SM. Localized intravascular coagulation in venous malformations: a system review. *Phlebology* 2021;36(01):38–42
- 32 Langbroek GB, Horbach SE, van der Vleuten CJ, Ubbink DT, van der Horst CM. Compression therapy for congenital low-flow vascular malformations of the extremities: a systematic review. *Phlebology* 2018;33(01):5–13
- 33 Hou F, Chen J, Xia M, Ding K, Zeng Q, Liu W. Percutaneous sclerotherapy with polidocanol under the guidance of ultrasound for venous malformations in children - a retrospective cohort study from a single tertiary medical center. *Medicine (Baltimore)* 2020;99(09):e18839
- 34 Stimpson P, Hewitt R, Barnacle A, Roebuck DJ, Hartley B. Sodium tetradecyl sulphate sclerotherapy for treating venous malformations of the oral and pharyngeal regions in children. *Int J Pediatr Otorhinolaryngol* 2012;76(04):569–573
- 35 Gulsen F, Cantasdemir M, Solak S, Gulsen G, Ozluk E, Numan F. Percutaneous sclerotherapy of peripheral venous malformations in pediatric patients. *Pediatr Surg Int* 2011;27(12):1283–1287
- 36 Uehara S, Osuga K, Yoneda A, Oue T, Yamanaka H, Fukuzawa M. Intralesional sclerotherapy for subcutaneous venous malformations in children. *Pediatr Surg Int* 2009;25(08):709–713
- 37 Clemens RK, Baumann F, Husmann M, et al. Percutaneous sclerotherapy for spongiform venous malformations - analysis of patient-evaluated outcome and satisfaction. *Vasa* 2017;46(06):477–483
- 38 Hu L, Chen H, Yang X, Liu M, Yan M, Lin X. Joint dysfunction associated with venous malformations of the limbs: Which patients are at high risk? *Phlebology* 2018;33(02):89–96
- 39 Qiu Y, Chen H, Lin X, Hu X, Jin Y, Ma G. Outcomes and complications of sclerotherapy for venous malformations. *Vasc Endovascular Surg* 2013;47(06):454–461
- 40 Yakes WF. Endovascular management of high-flow arteriovenous malformations. *Semin Intervent Radiol* 2004;21(01):49–58
- 41 Mol W, Furukawa H, Sasaki S, et al. Evaluation of the sclerotherapeutic efficacy of ethanol, polidocanol, and OK-432 using an in vitro model. *Dermatol Surg* 2007;33(12):1452–1459
- 42 Barranco-Pons R, Burrows PE, Landrigan-Ossar M, Trenor CC III, Alomari AI. Gross hemoglobinuria and oliguria are common transient complications of sclerotherapy for venous malformations: review of 475 procedures. *AJR Am J Roentgenol* 2012;199(03):691–694

- 43 Stuart S, Barnacle AM, Smith G, Pitt M, Roebuck DJ. Neuropathy after sodium tetradecyl sulfate sclerotherapy of venous malformations in children. *Radiology* 2015;274(03):897–905
- 44 Burrows PE, Mason KP. Percutaneous treatment of low flow vascular malformations. *J Vasc Interv Radiol* 2004;15(05):431–445
- 45 Rabe E, Pannier F. Sclerotherapy in venous malformation. *Phlebology* 2013;28(Suppl 1):188–191
- 46 McAree B, Ikponmwosa A, Brockbank K, Abbott C, Homer-Vanniasinkam S, Gough MJ. Comparative stability of sodium tetradecyl sulphate (STD) and polidocanol foam: impact on vein damage in an in-vitro model. *Eur J Vasc Endovasc Surg* 2012;43(06):721–725
- 47 Kumar S, Bhavana K, Kumar S, Kumar P. Ultrasound-guided polidocanol foam sclerotherapy for treating venous malformations. *J Clin Ultrasound* 2018;46(01):23–31
- 48 Schmidt VF, Masthoff M, Goldann C, et al. Percutaneous sclerotherapy of venous malformations of the hand: a multicenter analysis. *Cardiovasc Intervent Radiol* 2021;44(10):1543–1550
- 49 Chaudry G, Guevara CJ, Rialon KL, et al. Safety and efficacy of bleomycin sclerotherapy for microcystic lymphatic malformation. *Cardiovasc Intervent Radiol* 2014;37(06):1476–1481
- 50 Wohlgemuth WA, Müller-Wille R, Meyer L, et al. Bleomycin electroclerotherapy in therapy-resistant venous malformations of the body. *J Vasc Surg Venous Lymphat Disord* 2021;9(03):731–739
- 51 Cornelis FH, Labrèze C, Pinsolle V, et al. Percutaneous image-guided cryoablation as second-line therapy of soft-tissue venous vascular malformations of extremities: a prospective study of safety and 6-month efficacy. *Cardiovasc Intervent Radiol* 2017;40(09):1358–1366
- 52 Mahnken AH, König AM, Figiel JH. Current technique and application of percutaneous cryotherapy. *RoFo Fortschr Geb Rontgenstr Nuklearmed* 2018;190(09):836–846
- 53 Zhang DM, Wang YY, Lin ZY, Yang ZH, Chen WL. Liquid nitrogen cryotherapy for lip mucous membrane venous malformation in infants. *Pediatr Surg Int* 2015;31(03):283–285
- 54 Fereydooni A, Nassiri N. Evaluation and management of the lateral marginal vein in Klippel-Trénaunay and other PIK3CA-related overgrowth syndromes. *J Vasc Surg Venous Lymphat Disord* 2020;8(03):482–493
- 55 Kim YW, Lee BB, Cho JH, Do YS, Kim DI, Kim ES. Haemodynamic and clinical assessment of lateral marginal vein excision in patients with a predominantly venous malformation of the lower extremity. *Eur J Vasc Endovasc Surg* 2007;33(01):122–127
- 56 Puig S, Aref H, Chigot V, Bonin B, Brunelle F. Classification of venous malformations in children and implications for sclerotherapy. *Pediatr Radiol* 2003;33(02):99–103
- 57 Chewning RH, Monroe EJ, Lindberg A, et al. Combined glue embolization and excision for the treatment of venous malformations. *CVIR Endovasc* 2018;1(01):22
- 58 Legiehn GM. Sclerotherapy with adjunctive stasis of efflux (STASE) in venous malformations: techniques and strategies. *Tech Vasc Interv Radiol* 2019;22(04):100630
- 59 Kulungowski AM, Patel M. Lymphatic malformations. *Semin Pediatr Surg* 2020;29(05):150971
- 60 Wassef M, Blei F, Adams D, et al; ISSVA Board and Scientific Committee. Vascular anomalies classification: recommendations from the international society for the study of vascular anomalies. *Pediatrics* 2015;136(01):e203–e214
- 61 Lala S, Mulliken JB, Alomari AI, Fishman SJ, Kozakewich HP, Chaudry G. Gorham-Stout disease and generalized lymphatic anomaly—clinical, radiologic, and histologic differentiation. *Skeletal Radiol* 2013;42(07):917–924
- 62 Rasalkar DD, Chu WC. Generalized cystic lymphangiomas. *Pediatr Radiol* 2010;40(Suppl 1):S47
- 63 McCann ME, Soriano SG. Does general anesthesia affect neurodevelopment in infants and children? *BMJ* 2019;367:l6459
- 64 Balakrishnan K, Edwards TC, Perkins JA. Functional and symptom impacts of pediatric head and neck lymphatic malformations: developing a patient-derived instrument. *Otolaryngol Head Neck Surg* 2012;147(05):925–931
- 65 De Maria L, De Sanctis P, Balakrishnan K, Tollefson M, Brinjikji W. Sclerotherapy for lymphatic malformations of head and neck: systematic review and meta-analysis. *J Vasc Surg Venous Lymphat Disord* 2020;8(01):154–164
- 66 Lerat J, Mounayer C, Scomparin A, Orsel S, Bessede JP, Aubry K. Head and neck lymphatic malformation and treatment: clinical study of 23 cases. *Eur Ann Otorhinolaryngol Head Neck Dis* 2016;133(06):393–396
- 67 Cheng J, Bastidas N. Considerations for management of head and neck lymphatic malformations in children. *J Craniofac Surg* 2016;27(04):908–912
- 68 Laviv A, Maly A, Abu-Tair J. Large facial lymphatic malformation treatment using sclerosing agent followed by surgical resection: clinical and pathology report. *Oral Maxillofac Surg* 2017;21(03):363–369
- 69 Alomari A, Dubois J. Interventional management of vascular malformations. *Tech Vasc Interv Radiol* 2011;14(01):22–31
- 70 Shergill A, John P, Amaral JG. Doxycycline sclerotherapy in children with lymphatic malformations: outcomes, complications and clinical efficacy. *Pediatr Radiol* 2012;42(09):1080–1088
- 71 Jamal N, Ahmed S, Miller T, et al. Doxycycline sclerotherapy for pediatric head and neck macrocystic lymphatic malformations: a case series and review of the literature. *Int J Pediatr Otorhinolaryngol* 2012;76(08):1127–1131
- 72 Hawkins CM, Chewning RH. Diagnosis and management of extracranial vascular malformations in children: arteriovenous malformations, venous malformations, and lymphatic malformations. *Semin Roentgenol* 2019;54(04):337–348
- 73 Coughlin K, Flibotte J, Cahill AM, Osterhoudt K, Hedrick H, Vrecenak J. Methemoglobinemia in an infant after sclerotherapy with high-dose doxycycline. *Pediatrics* 2019;143(02):e20181642
- 74 Cahill AM, Nijs E, Ballah D, et al. Percutaneous sclerotherapy in neonatal and infant head and neck lymphatic malformations: a single center experience. *J Pediatr Surg* 2011;46(11):2083–2095
- 75 Farnoosh S, Don D, Koempel J, Panossian A, Anselmo D, Stanley P. Efficacy of doxycycline and sodium tetradecyl sulfate sclerotherapy in pediatric head and neck lymphatic malformations. *Int J Pediatr Otorhinolaryngol* 2015;79(06):883–887
- 76 Thomas DM, Wieck MM, Grant CN, et al. Doxycycline sclerotherapy is superior in the treatment of pediatric lymphatic malformations. *J Vasc Interv Radiol* 2016;27(12):1846–1856
- 77 Poldervaart MT, Breugem CC, Speleman L, Pasmans S. Treatment of lymphatic malformations with OK-432 (Picibanil): review of the literature. *J Craniofac Surg* 2009;20(04):1159–1162
- 78 Ghaffarpour N, Petrini B, Svensson LA, Boman K, Wester T, Claesson G. Patients with lymphatic malformations who receive the immunostimulant OK-432 experience excellent long-term outcomes. *Acta Paediatr* 2015;104(11):1169–1173
- 79 Peters DA, Courtemanche DJ, Heran MKS, Ludemann JP, Prendiville JS. Treatment of cystic lymphatic vascular malformations with OK-432 sclerotherapy. *Plast Reconstr Surg* 2006;118(06):1441–1446
- 80 Shiels WE II, Kang DR, Murakami JW, Hogan MJ, Wiet GJ. Percutaneous treatment of lymphatic malformations. *Otolaryngol Head Neck Surg* 2009;141(02):219–224
- 81 Nikolaev SI, Vetiska S, Bonilla X, et al. Somatic activating KRAS mutations in arteriovenous malformations of the brain. *N Engl J Med* 2018;378(03):250–261
- 82 Bouwman FCM, Kooijman SS, Verhoeven BH, et al. Lymphatic malformations in children: treatment outcomes of sclerotherapy in a large cohort. *Eur J Pediatr* 2021;180(03):959–966

- 83 Zorzi AP, Yang CL, Dell S, Nathan PC. Bleomycin-associated lung toxicity in childhood cancer survivors. *J Pediatr Hematol Oncol* 2015;37(08):e447–e452
- 84 Cho AL, Kiang SC, Lodenkamp J, Tritch WTH, Tomihama RT. Fatal lung toxicity after intralesional bleomycin sclerotherapy of a vascular malformation. *Cardiovasc Intervent Radiol* 2020;43(04):648–651
- 85 Winkelmann MT, Archid R, Gohla G, et al. MRI-guided percutaneous thermoablation in combination with hepatic resection as parenchyma-sparing approach in patients with primary and secondary hepatic malignancies: single center long-term experience. *Cancer Imaging* 2020;20(01):37
- 86 Mohan AT, Adams S, Adams K, Hudson DA. Intralesional bleomycin injection in management of low flow vascular malformations in children. *J Plast Surg Hand Surg* 2015;49(02):116–120
- 87 Bonilla-Velez J, Moore BP, Cleves MA, Buckmiller L, Richter GT. Surgical resection of macrocystic lymphatic malformations of the head and neck: short and long-term outcomes. *Int J Pediatr Otorhinolaryngol* 2020;134:110013
- 88 Wiegand S, Wichmann G, Dietz A. Treatment of lymphatic malformations with the mTOR inhibitor sirolimus: a systematic review. *Lymphat Res Biol* 2018;16(04):330–339
- 89 Castillo SD, Baselga E, Graupera M. PIK3CA mutations in vascular malformations. *Curr Opin Hematol* 2019;26(03):170–178
- 90 Tian R, Liang Y, Zhang W, et al. Effectiveness of sirolimus in the treatment of complex lymphatic malformations: Single center report of 56 cases. *J Pediatr Surg* 2020;55(11):2454–2458
- 91 Ricci KW, Hammill AM, Mobberley-Schuman P, et al. Efficacy of systemic sirolimus in the treatment of generalized lymphatic anomaly and Gorham-Stout disease. *Pediatr Blood Cancer* 2019;66(05):e27614
- 92 Venot Q, Blanc T, Rabia SH, et al. Targeted therapy in patients with PIK3CA-related overgrowth syndrome. *Nature* 2018;558(7711):540–546
- 93 Noshier JL, Murillo PG, Liszewski M, Gendel V, Gribbin CE. Vascular anomalies: a pictorial review of nomenclature, diagnosis and treatment. *World J Radiol* 2014;6(09):677–692
- 94 de Miguel R, López-Gutierrez JC, Boixeda P. Arteriovenous malformations: a diagnostic and therapeutic challenge. *Actas Dermosifiliogr* 2014;105(04):347–358
- 95 Greene AK, Orbach DB. Management of arteriovenous malformations. *Clin Plast Surg* 2011;38(01):95–106
- 96 Soulez G, Gilbert Md Frcpc P, Giroux Md Frcpc MF, Racicot Md Frcpc JN, Dubois J. Interventional management of arteriovenous malformations. *Tech Vasc Interv Radiol* 2019;22(04):100633
- 97 Richter GT, Suen JY. Pediatric extracranial arteriovenous malformations. *Curr Opin Otolaryngol Head Neck Surg* 2011;19(06):455–461
- 98 Do YS, Park KB, Park HS, et al. Extremity arteriovenous malformations involving the bone: therapeutic outcomes of ethanol embolotherapy. *J Vasc Interv Radiol* 2010;21(06):807–816
- 99 Gioppo A, Faragò G, Caldiera V, Caputi L, Cusin A, Ciceri E. Medial tentorial dural arteriovenous fistula embolization: single experience with embolic liquid polymer SQUID and review of the literature. *World Neurosurg* 2017;107:1050.e1–1050.e7
- 100 Pop R, Mertz L, Ilyes A, et al. Beam hardening artifacts of liquid embolic agents: comparison between Squid and Onyx. *J Neurointerv Surg* 2019;11(07):706–709
- 101 Brill RM, Guntau M, Wildgruber M, et al. Safety and effectiveness of ethylene-vinyl alcohol copolymer embolization of peripheral high flow arteriovenous malformations - results of a prospective study. *J Vasc Interv Radiol* 2021;32(12):1644–1653.e1
- 102 Ashour R, Aziz-Sultan MA, Soltanolkotabi M, et al. Safety and efficacy of onyx embolization for pediatric cranial and spinal vascular lesions and tumors. *Neurosurgery* 2012;71(04):773–784
- 103 Saeed Kilani M, Lepennec V, Petit P, et al. Embolization of peripheral high-flow arteriovenous malformations with Onyx. *Diagn Interv Imaging* 2017;98(03):217–226
- 104 Jin Y, Zou Y, Hua C, et al. Treatment of early-stage extracranial arteriovenous malformations with intralesional interstitial bleomycin injection: a pilot study. *Radiology* 2018;287(01):194–204