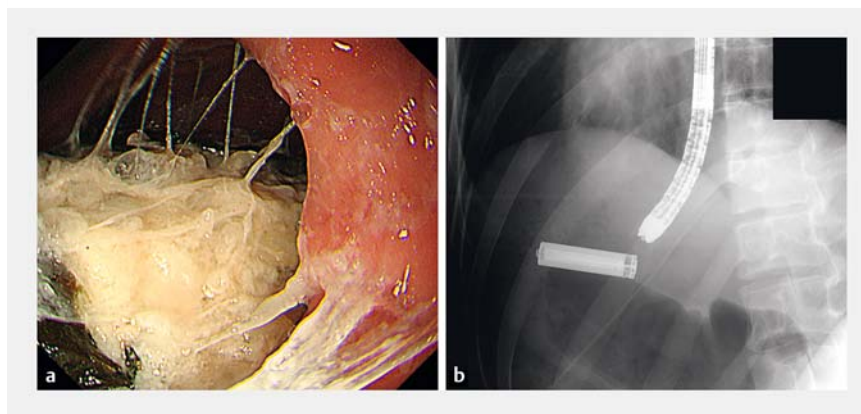


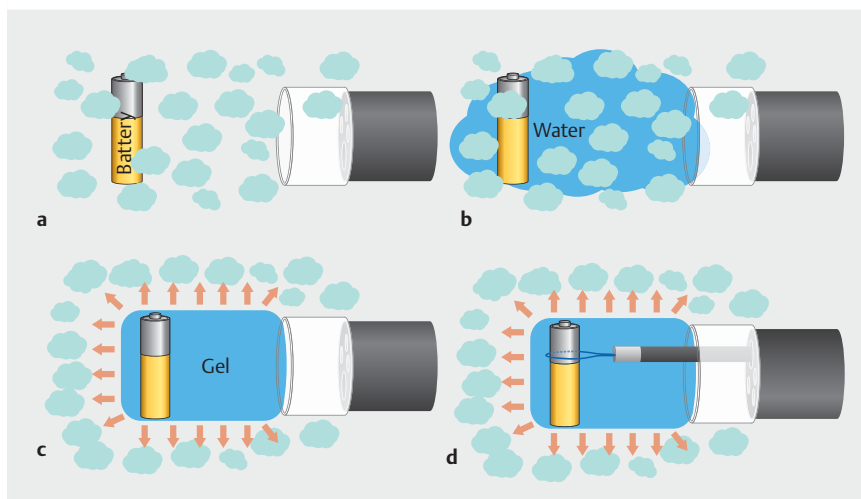
## Gel improves visibility despite post-prandial timing of endoscopy for accidental ingestion

Urgent therapeutic endoscopy is recommended for foreign bodies lodged in the upper gastrointestinal tract such as sharp and pointed objects, magnets, batteries, and large or long objects [1]. However, endoscopic foreign body extraction is sometimes difficult and time-consuming due to copious food residue. Gel immersion endoscopy is useful in securing the visual field from residue and bleeding [2, 3]. Here, we report the implementation of gel immersion endoscopy with enhanced visualization of a foreign body in the stomach, despite being filled with residue.

A 20-year-old woman suffering from an exacerbation of post-traumatic stress disorder and developmental delay was admitted to our hospital having intentionally ingested an AA battery after dinner. The battery was observed by abdominal radiography to have been retained in the stomach; urgent endoscopy was contemplated for battery extraction. However, large amounts of food residue hindered visualization because of the timing of foreign body ingestion, following a meal (► Fig. 1 a, ► Fig. 2 a, b). To enhance visibility, we attempted turning the patient's body and using endoscopic suctioning; however, the maneuvers were ineffective. Therefore, after confirming the position of the battery under fluoroscopy, a gel substance (OS-1 Jelly; Otsuka Pharmaceutical Factory, Tokushima, Japan) was injected through the forceps channel of the endoscope with an attachment (D-201-11804; Olympus, Tokyo, Japan) equipped at the tip (► Fig. 1 b). The gel displaced the residue and dramatically enhanced visualization, facilitating detection of the battery (► Fig. 2 c, ► Fig. 3 a). In the gel-filled field, ensnaring the battery was facilitated (SD-210L-15, Olympus) (► Fig. 2 d, ► Fig. 3 b, ► Video 1). A flexible overtube (MD-48519; Sumitomo Bakelite, Tokyo, Japan) was also used to protect the esophageal/pharyngeal mucosa from injury by the



► Fig. 1 a It was difficult to ensure good visualization to remove an AA battery because of copious food residue in the stomach. b The positions of the battery and the tip of the endoscope were confirmed under fluoroscopic guidance.



► Fig. 2 Technique of endoscopic removal with gel immersion endoscopy for accidental ingestion with large amounts of food residue. a Copious food residue in the stomach hindered good visualization. b The battery could not be located because of large amounts of residue. c The gel displaced the residue and dramatically enhanced visualization, facilitating detection of the battery. d In a gel-filled field, ensnaring the battery was facilitated.

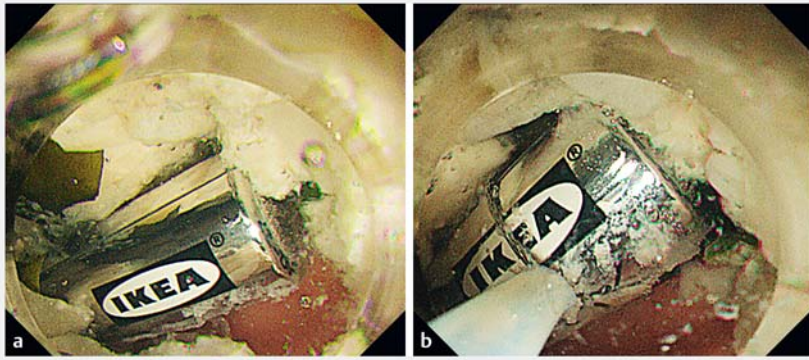
battery and prevent aspiration. The extracted battery was 5 cm in length and was found intact (► Fig. 4).

Endoscopic extraction with gel immersion endoscopy was implemented easily and is potentially useful for ingestion cases complicated by large amounts of food residue.


Endoscopy\_UCTN\_Code\_TTT\_1AQ\_2AH

### Competing interests

The authors declare that they have no conflict of interest.



► **Fig. 3** **a** The gel displaced the residue and dramatically enhanced visualization, making it easier to locate the battery. **b** The battery was ensnared upon filling the lumen with gel.



► **Fig. 4** The extracted battery from the stomach was 5 cm long and was found to be intact.



► **Video 1** Endoscopic extraction with gel immersion endoscopy for accidental ingestion with large amounts of food residue.

## Bibliography

Endoscopy 2022; 54: E660–E661  
**DOI** 10.1055/a-1735-2671  
**ISSN** 0013-726X  
**published online** 15.2.2022  
 © 2022. Thieme. All rights reserved.  
 Georg Thieme Verlag KG, Rüdigerstraße 14,  
 70469 Stuttgart, Germany

## ENDOSCOPY E-VIDEOS



<https://eref.thieme.de/e-videos>



*Endoscopy E-Videos* is an open access online section, reporting on interesting cases and new techniques in gastroenterological endoscopy. All papers include a high quality video and all contributions are freely accessible online. Processing charges apply (currently EUR 375), discounts and waivers acc. to HINARI are available.

This section has its own submission website at  
<https://mc.manuscriptcentral.com/e-videos>

## The authors

**Tadashi Ochiai, Masaki Ominami, Yasuaki Nagami** , **Taku Manabe, Mitsuhiro Kono** , **Shusei Fukunaga, Yasuhiro Fujiwara**  
 Department of Gastroenterology, Osaka City University Graduate School of Medicine, Osaka, Japan

## Corresponding author

**Yasuaki Nagami, MD**  
 Department of Gastroenterology, Osaka City University Graduate School of Medicine, 1-4-3, Asahimachi, Abeno-ku, Osaka, 545-8585, Japan  
 Fax: +81-6-6645-3813  
[yasuaki1975@hotmail.com](mailto:yasuaki1975@hotmail.com)

## References

- [1] Birk M, Bauerfeind P, Deprez PH et al. Removal of foreign bodies in the upper gastrointestinal tract in adults: European Society of Gastrointestinal Endoscopy (ESGE) Clinical Guideline. *Endoscopy* 2016; 48: 489–496. doi:10.1055/s-0042-100456
- [2] Yano T, Nemoto D, Ono K et al. Gel immersion endoscopy: a novel method to secure the visual field during endoscopy in bleeding patients (with videos). *Gastrointest Endosc* 2016; 83: 809–811. doi:10.1016/j.gie.2015.09.048
- [3] Miura Y, Yano T, Takezawa T et al. Gel immersion endoscopy simplifies hemostasis during endoscopic submucosal dissection using the pocket-creation method. *Endoscopy* 2018; 50: E294–E295. doi:10.1055/a-0651-0365