

Update for the Performance of CT Coronary Angiography

Evidence-Based Application and Technical Guidance According to Current Consensus Guidelines and Practical Advice from the Clinical Routine

Update zur Durchführung der CT-Koronarangiografie

Evidenzbasierter Einsatz und technische Anleitung entsprechend den aktuellen Empfehlungen sowie praktische Tipps aus der Routine am eigenen Standort

Authors

Martin Soschynski¹, Muhammad Taha Hagar¹, Jana Taron^{1,2}, Tobias Krauss¹, Philipp Ruile³, Manuel Hein³, Thomas Nührenberg³, Maximilian Frederik Russe¹, Fabian Bamberg¹, Christopher L Schlett¹

Affiliations

- 1 Department of Diagnostic and Interventional Radiology, Medical Center-University of Freiburg, Germany
- 2 Cardiac MR PET CT Program, Massachusetts General Hospital, Harvard Medical School, Boston, United States
- 3 Department of Cardiology & Angiology II, University Heart Center Freiburg-Bad Krozingen, Germany

Key words

coronary CT angiography, acquisition, technique, guidelines, cardiac CT, performance

received 31.05.2021

accepted 20.12.2021

published online 01.03.2022

Bibliography

Fortschr Röntgenstr 2022; 194: 613–624

DOI 10.1055/a-1747-3554

ISSN 1438-9029

© 2022, Thieme. All rights reserved.

Georg Thieme Verlag KG, Rüdigerstraße 14, 70469 Stuttgart, Germany

Correspondence

Herr Dr. Martin Soschynski
Radiology, University Hospital Freiburg, Hugstetter Straße 55,
79106 Freiburg, Germany
Tel.: +49/7 61/27 03 95 40
Fax: +49/7 61/27 03 95 00
martin.soschynski@uniklinik-freiburg.de

ABSTRACT

Background Coronary CT angiography (cCTA) is a class 1 recommendation in the current guidelines by the European Society of Cardiology (ESC) for excluding significant coronary artery stenosis. To achieve optimal image quality at a low radiation dose, the imaging physician may choose different acquisition modes. Therefore, the consensus guidelines by

the Society of Cardiovascular Computed Tomography (SCCT) provide helpful guidance for this procedure.

Method The article provides practical recommendations for the application and acquisition of cCTA based on the current literature and our own experience.

Results and Conclusion According to current ESC guidelines, cCTA is recommended in symptomatic patients with a low or intermediate clinical likelihood for coronary artery disease. We recommend premedication with beta blockers and nitrates prior to CT acquisition under certain conditions even with the latest CT scanner generations. The most current CT scanners offer three possible scan modes for cCTA acquisition. Heart rate is the main factor for selecting the scan mode. Other factors may be coronary calcifications and body mass index (BMI).

Key Points:

- CCTA is a valid method to exclude coronary artery disease in patients with a low to intermediate clinical likelihood.
- Even with the latest generation CT scanners, premedication with beta blockers and nitrates can improve image quality at low radiation exposure.
- Current CT scanners usually provide retrospective ECG gating and prospective ECG triggering. Dual-source scanners additionally provide a “high pitch” scan mode to scan the whole heart during one heartbeat, which may also be achieved using single-source scanners with broad detectors in some cases.
- Besides the available scanner technology, the choice of scan mode primarily depends on heart rate and heart rate variability (e. g., arrhythmia).

Citation Format

- Soschynski M, Hagar MT, Taron J et al. Update for the Performance of CT Coronary Angiography. *Fortschr Röntgenstr* 2022; 194: 613–624

ZUSAMMENFASSUNG

Hintergrund Die computertomografische Koronarangiografie (cCTA) hat in den aktuellen Leitlinien der European Society of Cardiology (ESC) einen hohen Stellenwert für den Ausschluss signifikanter Koronarstenosen. Für eine optimale Bildqualität bei niedriger Strahlenexposition stehen dem Untersucher verschiedene Scanverfahren zur Verfügung. Aktuelle Konsensempfehlungen der Society of Cardiovascular Computed Tomography (SCCT) geben Hinweise für die Durchführung.

Methode Der Artikel gibt praktische Empfehlungen zum leitliniengerechten Einsatz und zur Durchführung der cCTA

basierend auf der aktuellen Literatur und eigenen Erfahrungswerten.

Ergebnisse und Schlussfolgerung Gemäß den aktuellen Leitlinien der ESC wird die cCTA vor allem bei symptomatischen Patienten mit niedriger und intermediärer klinischer Wahrscheinlichkeit für eine koronare Herzkrankheit (KHK) empfohlen. Vor der Untersuchung empfehlen wir selbst an den modernsten Scannern weiterhin eine Prämedikation mit Beta-Blockern und Nitraten. Für die Akquisition stehen an aktuell verwendeten CT-Scannern 3 Scan-Modi zur Verfügung. Hauptfaktor für die Protokollauswahl ist die Herzfrequenz, Nebenfaktoren können Koronarkalk und Body-Mass-Index (BMI) sein.

Introduction

Coronary CT angiography (cCTA) is a recognized diagnostic method for excluding coronary stenosis with a high degree of scientific and clinical evidence. According to the current guidelines of the European Society of Cardiology (ESC), which were revised in 2019, cCTA already has a class 1 indication for the diagnosis of coronary artery disease [1]. In spite of a high degree of standardization, the diagnostic significance of cCTA is still highly dependent on optimal performance of the examination. Moreover, even when using the latest scanner generations, the applied dose depends on the imaging protocol that is used. This is particular to cCTA compared to many other CT examination protocols in radiology. The method requires a high degree of direct patient contact and personalization.

The goal of this article is to provide the examiner with an overview of the evidence-based use, examination procedure, and image acquisition techniques of cCTA. Recommendations are based on the current consensus recommendations of the professional societies, the relevant literature, current studies, and our own experience. Examination preparation and procedure do not differ significantly between various frequently used types of scanner. The discussion of technical implementation, particularly the scan modes, is primarily focused here on second and third-generation dual-source scanners with which we use in our own department. The described examination procedure is an example of an implementation of cCTA that we use at our own site. It is not intended to be binding or generally valid and is not a recommendation from a professional society. This article provides supplementary and updated information to an earlier overview of the coronary CT angiography examination technique published in *RöFo* [2].

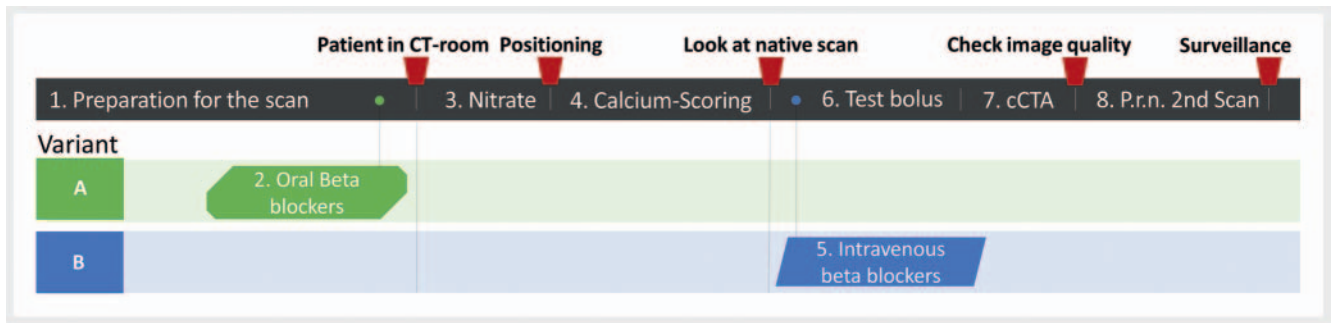
Current guidelines for using cCTA

In 2019, the European Society of Cardiology (ESC) published updated guidelines regarding the diagnosis and management of chronic symptomatic coronary syndrome [1]. These guidelines

recommend primary anatomical cCTA imaging or noninvasive functional imaging (myocardial ischemic test) to rule out coronary artery disease. cCTA is the preferred test in the case of low clinical probability of coronary artery disease, no preexisting coronary artery disease, and high probability of good image quality [1]. In the case of high probability of coronary artery disease or known coronary artery disease, a noninvasive functional ischemic test (e.g., stress MRI, SPECT, or stress echocardiography) is preferred. However, local expertise, availability, and patient-specific characteristics play a role in test selection (cCTA or functional ischemic test) [1]. In the case of intermediate clinical probability, both cCTA and functional tests are recommended equally. The guidelines are based on multiple large studies and meta-analyses. A meta-analysis including 5332 patients from 65 prospective studies examining the diagnostic accuracy of cCTA showed that cCTA achieved the best diagnostic accuracy in patients with stable angina pectoris and a clinical pretest probability between 7% and 67% [3]. The often cited “Prospective Multicenter Imaging Study for Evaluation of Chest Pain” (PROMISE study) showed that cCTA can be used as an equivalent alternative to stress tests for diagnosing coronary artery disease in patients with low to intermediate pretest probability.

Studies like the SCOT-HEART Trial showed that cCTA was able to lower the rate of future coronary events (heart attack, coronary cardiac death) in patients with stable angina pectoris compared to standard treatment alone without cCTA [4]. In the case of chronic symptomatic coronary syndrome, invasive coronary angiography is recommended only rarely as a primary diagnostic method without prior noninvasive imaging, e.g., in the case of a high probability of coronary artery disease with typical angina already under minimal stress, in the case of severe symptoms of coronary artery disease that do not respond to medications, and in the case of left ventricular dysfunction that is clinically probably associated with coronary artery disease [1].

A further area of application for cCTA according to the guidelines of the ESC is the detection of coronary bypass occlusion [1].



► **Fig. 1** The whole diagnostic procedure is shown as a timeline. Beta blockers may be given orally one hour prior to the examination in the 2nd step (Variant A) or in the 5th step intravenously directly before cCTA (Variant B) or in combination (performing both steps 2 and 5). Intermediate tasks between the main steps, for example checking image quality after cCTA, are marked in red.

cCTA imaging of non-contrast-enhanced coronary vessels is not indicated in the case of a bypass situation [5]. A diagnostic alternative for detecting ischemia after bypass surgery is a noninvasive stress test [5].

The use of cCTA to diagnose in-stent restenosis is not recommended in the current guidelines [1, 6] because the diagnostic accuracy even of modern CT scanners depends greatly on the width of the stent and the type of stent (material) [7, 8]. For stents with a diameter greater than 3 mm, cCTA had a high diagnostic accuracy regarding restenosis particularly in the left main coronary artery [8]. The updated guidelines of the ESC and the European Association for Cardio-Thoracic Surgery (EACTS) recommend cCTA as an alternative to invasive coronary angiography to rule out coronary artery disease prior to surgical valve replacement in patients with low pretest probability, thus creating an additional large field of application for the method [9]. For the sake of completeness, it must be mentioned that there are areas of use and indications for cCTA outside of chronic symptomatic coronary syndrome, for example, the exclusion of acute coronary syndrome in acute chest pain (in certain constellations with unremarkable ECG and normal cardiac enzymes [10]), the detection and classification of coronary anomalies, the detection of coronary aneurysms, and anatomical imaging in the case of complex malformations. The focus of this study is the diagnosis of chronic symptomatic coronary syndrome. The additionally mentioned indications are not further discussed.

Update of examination techniques

Examination procedure

To allow a routine examination procedure, the individual steps should be as standardized as possible, ideally in the form of a standard operating procedure (SOP). For orientation purposes, the SCCT published consensus recommendations for cCTA preparation and acquisition [11]. In concordance with the current recommendations, the examination can include the following steps:

Examination preparation (informed consent, peripheral venous catheter, blood pressure measurement (RR)), oral beta blockers

one hour prior to examination if applicable, isosorbide dinitrate (sublingual nitrate in tablet form), scout view, native calcium scoring scan, intravenous beta blockers, test bolus scan, cCTA, repeat scan if necessary. The timeline is schematically shown in ► **Fig. 1**.

Individual components can also be omitted or modified. For example, beta blockers can be administered orally, intravenously, or as a combination depending on the preference of the examiner and integration in the workflow. The administration of beta blockers can also be eliminated in the case of a low heart rate (<60/min). The calcium scoring scan can also be eliminated in very young patients (e. g., when investigating coronary anomalies). A calcium scoring scan is also not necessary in the case of bypass imaging. Alternatively to a test bolus, bolus tracking can be performed with a region of interest (ROI) in the ascending aorta.

Individual steps of the examination

Examination preparation

In addition to the risks of contrast agent administration, the informed consent discussion should include side effects and possible contraindications for beta blockers and nitrates according to the package insert. ► **Table 1** provides a summary of the constellations in which beta blockers and nitrates are not recommended or are only recommended with caution and monitoring [11–16]. One approach is to use intravenous beta blockers, e. g., Metoprolol (Beloc i. v. 5 ml = 5 mg) with oral immediate-release beta blockers (e. g., 50 mg tablets of Metoprolol Tartrate) as an alternative. In addition, isosorbide dinitrate (Isoket) is administered as a sublingual tablet (5 mg). Due to the beta-1 selectivity of Metoprolol, the effect on the bronchial system tends to be minimal. However, beta blockers should not be used in patients taking long-term medication to treat severe asthma or COPD.

Peripheral venous catheters with the largest possible diameter (ideally 18 gauge, often color-coded green) should be used for intravenous access preferably in the right elbow to allow high flow rates (5–6 ml/s). The patient's blood pressure and pulse should be measured prior to administration of beta blockers and nitrates.

It should be noted that there is currently no evidence that the administration of beta blockers improves the diagnostic accuracy of third-generation dual-source CT scanners in the case of signifi-

► **Table 1** Precautions/contraindications for drugs routinely used for cCTA. Furthermore, the package leaflet must be observed.

Precautions regarding beta blockers (Metoprolol)	Precautions regarding nitrates (isosorbide dinitrate)
Systolic BP < 110 mmHg	
Severe aortic valve stenosis	
Severe aortic valve insufficiency	
Decompensated heart failure	
Sinus bradycardia (HR < 45)	Hypertrophic obstructive cardiomyopathy (HOCM)
2nd or 3rd degree atrioventricular (AV) block	PDE-5 inhibitors: Sildenafil (Viagra), Tadalafil
Medication inducing AV block (e. g., Verapamil, Diltiazem)	
Asthma/COPD/bronchospasm (reduced risk due to Beta-1 selectivity of Metoprolol. However, should be avoided in case of severe asthma/COPD under long-term medication)	

cant coronary stenosis. One study comparing the image quality of 3rd-generation dual-source scanners for various heart rate ranges was able to show that a heart rate of up to 80/min did not result in a significant reduction of the image quality compared to a heart rate ≤ 60 /min [14]. A meta-analysis comparing the diagnostic accuracy of cCTA for the detection of significant coronary stenosis on dual-source scanners with and without heart rate monitoring did not show any significant difference in the diagnostic accuracy on the patient level but did show a significant difference in the specificity on the segment level and a significant difference in radiation dose [15]. Therefore, the current consensus recommendations of the Society of Cardiovascular Computed Tomography (SCCT) recommend the administration of beta blockers also in the case of scanners with improved temporal resolution [11]. In our opinion, the administration of beta blockers is no longer essential for all HR ranges on 3rd-generation dual-source scanners but is recommended to optimize image quality and particularly to reduce the radiation dose.

Oral beta blockers

The consensus recommendations of the SCCT specify 50–100 mg Metoprolol Tartrate one hour before examination as the typical dose used in practice [11]. However, an exact recommendation regarding dosage based on heart rate is not provided. Therefore, we created a possible simple dosing regimen as a function of heart rate (refer to ► **Table 2**). We implemented this regimen in our department, and it proved to be well tolerated by most patients. Alternatively, administration can be performed in a weight-adapted manner and/or in combination with intravenous administration of Metoprolol [17]. If Metoprolol is administered intravenously over the further course, oral administration can be dispensed with as described above or can be reduced in the case of a combination.

Nitrates

Nitrates for coronary artery dilation can be administered sublingually as a spray or a tablet prior to examination [11]. Studies showed slightly greater dilatation of the coronary arteries when using a sublingual spray compared to a tablet [18, 19]. For hygiene-

► **Table 2** Possible dosage regimen of oral beta blockers.

HR	Dosage
≤ 65 /min	No oral beta blockers. Alternatively, i. v. Metoprolol may be considered
65–69/min	50 mg oral Metoprolol
≥ 70 /min	100 mg oral Metoprolol

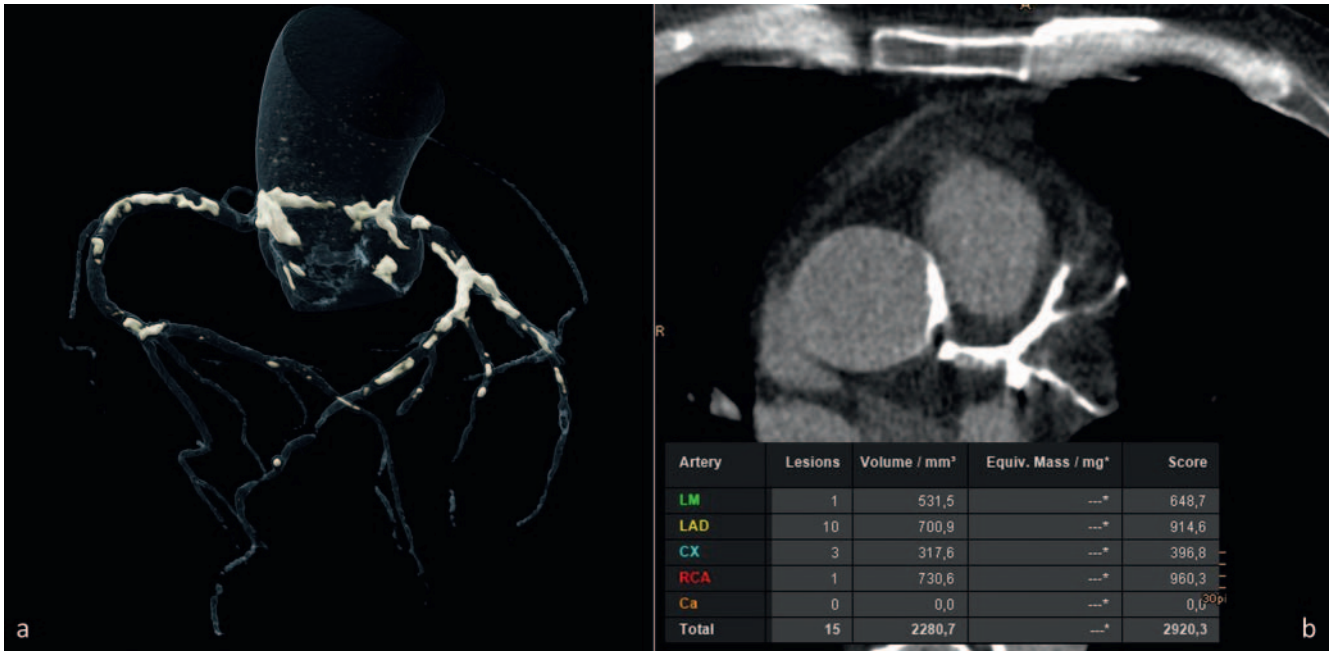
HR: heart rate.

nic reasons and in light of the current covid-19 pandemic, we are still using individually packaged isosorbide dinitrate sublingual tablets (5 mg Isoket, Aesica Pharmaceuticals GmbH). The time to maximum effect is approx. 8 minutes.

When using a sublingual spray, e. g. glyceryl trinitrate (2 sprays Nitrolingual N Spray, Pohl-Boskamp), the time to maximum coronary artery dilatation was 3–5 minutes in studies [16, 20, 21].

Scout view, calcium scoring

The scout view typically extends from the apex of the lungs to the costodiaphragmatic recess. It is almost always followed by a calcium scoring scan. Exceptions include very young patients (due to the additional radiation dose) and the examination of coronary bypasses (since the calcium scoring scan affects neither examination planning nor clinical management in the case of bypasses). At our hospital we always use a high-pitch coil with a low radiation dose for calcium scoring on second and third-generation dual-source scanners (Definition Flash and Force, Siemens Healthcare GmbH, Erlangen). A protocol with tin filtration can be used on third-generation DSCT scanners for further dose reduction and a virtual 120 kV reconstruction can be created to ensure that the Agatston score is comparable. An initial quick analysis of the calcium scoring scan is then performed. In the case of severe or very severe calcifications, not performing any contrast-enhanced examinations can be considered since the probability of relevant



► **Fig. 2** a Volume Rendering Technique (VRT) of coronary calcifications. b Axial image slice from native calcium scoring scan through the left main coronary artery and proximal left anterior descending (LAD, interventricular) artery. The table on the bottom displays the Agatston Score (total score 2920). In the case of such huge amounts of calcifications, the sensitivity and specificity of cCTA to exclude relevant stenosis are no longer high enough. Hence, an alternative diagnostic approach to exclude significant coronary stenosis should be considered (e. g., stress test).

coronary artery disease – particularly in the case of typical symptoms – increases significantly with a simultaneous significant decrease in sensitivity and specificity [22]. However, this is rarely the case when using modern dual-source scanners. An Agatston score of 400 was previously recommended as the upper limit for performing/evaluating cCTA [23, 24]. However, this is no longer valid for scanners of the latest generation (e. g., third-generation dual-source (DSCT) scanners) [25]. ► **Fig. 2** shows an exception, i. e., a case of very pronounced coronary calcifications. In such a case, coronary CT angiography with contrast agent can be dispensed with since reduced diagnostic accuracy can be expected.

Calcium scoring is of prognostic value here and can help when making decisions regarding medication for atherosclerosis prophylaxis. Therefore, multiple studies, e. g., the Multi-Ethnic Study of Atherosclerosis (MESA), were able to show that the Agatston score is highly correlated with the amount of coronary plaque and is an independent risk predictor for the occurrence of a future coronary event (heart attack, coronary cardiac death) and for overall mortality [26, 27]. A study with over 13 000 patients was able to show that the total Agatston score could identify with high accuracy patients who would benefit from statin therapy [28]. The new clinical guidelines of the American College of Cardiology, the American Heart Association, and other professional societies now recommend calcium scoring in certain patients to help determine if statin therapy should be initiated [29].

The scan field for the subsequent cCTA (in the z-direction) can be adjusted more precisely with the help of the calcium scoring scan than with the scout view. Upper scan limit: 1–2 cm cranial to the top coronary artery section in calcium scoring (LM or

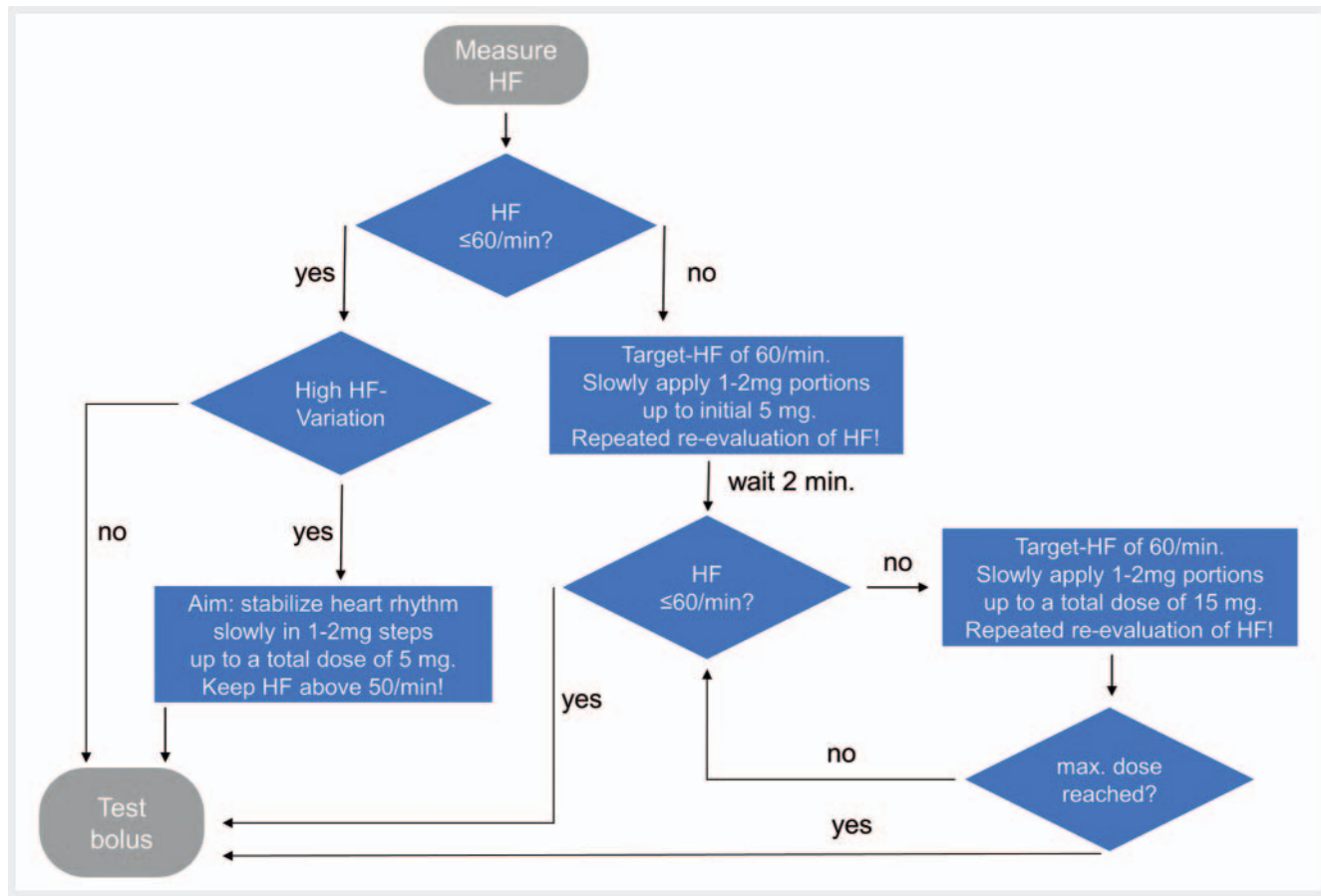
LAD). Lower scan limit: 1–2 cm caudal to the bottom apex section in calcium scoring.

Intravenous beta blockers

The intravenous administration of beta blockers is ideally performed before the test bolus to prevent differences in blood circulation velocity between the test bolus scan and cCTA. After a check for contraindications has been performed, Metoprolol can be administered intravenously (e. g., Beloc 5 mg/5 ml ampoules, Cenexi) slowly in small incremental doses of 1–2 mg under simultaneous ECG monitoring and heart rate monitoring until to a total dose of 15 mg is reached. The patient's heart rate is checked during inspiration after administration of each dose. The target rate is 60/min [11]. ► **Fig. 3** shows a possible administration regimen.

Test bolus or bolus tracking

There are two established methods for determining contrast agent delay: The test bolus method and the bolus tracking method. We primarily use the test bolus method in our department. For example, 10 ml contrast agent (e. g., 90% Imeron 400 or 100% Ultravist 370) are administered with a flow rate of 6 ml/s. A 60-ml saline bolus (NaCl chaser) is then administered with the same flow rate. After 9 seconds, sequential single slice images are acquired at 1-second intervals at the level of the ascending aorta. Using a region of interest (ROI), the HU values in the ascending aorta are measured over time and the time to maximum enhancement is derived (Tmax). The contrast delay from the start of injection for the actual cCTA examination is set to Tmax + 4 or + 5 seconds [11]. In the case of obesity class II (BMI ≥ 35 kg/m²), we



► Fig. 3 Algorithm for intravenous administration of metoprolol. HR: heart rate.

apply a 15-ml test bolus of contrast agent with a flow rate of 7–8 ml/s [30]. The contrast flow rate must be set to be identical to the main bolus of the subsequent cCTA.

In the case of the bolus tracking method, the enhancement in the form of an increase in HU values in an ROI of the ascending artery is first measured at the start of cCTA during contrast injection. As soon as a defined HU threshold (typically 100–500 HU) is reached, the patient is given breathing commands. The scan then begins automatically approximately 7–10 seconds after the threshold value is reached [11, 31, 32]. Both methods have advantages and disadvantages: An advantage of the test bolus method is that the test bolus can serve as a test run for the actual cCTA examination. Therefore, for example, the correct position of the peripheral venous catheter is confirmed. In addition, there are advantages of a very long or extremely short circulation time [11]. The bolus tracking method does not require the 10-ml test bolus of contrast agent, resulting in a time savings. Moreover, the bolus tracking method is typically easier for inexperienced examiners to use.

Coronary CT angiography

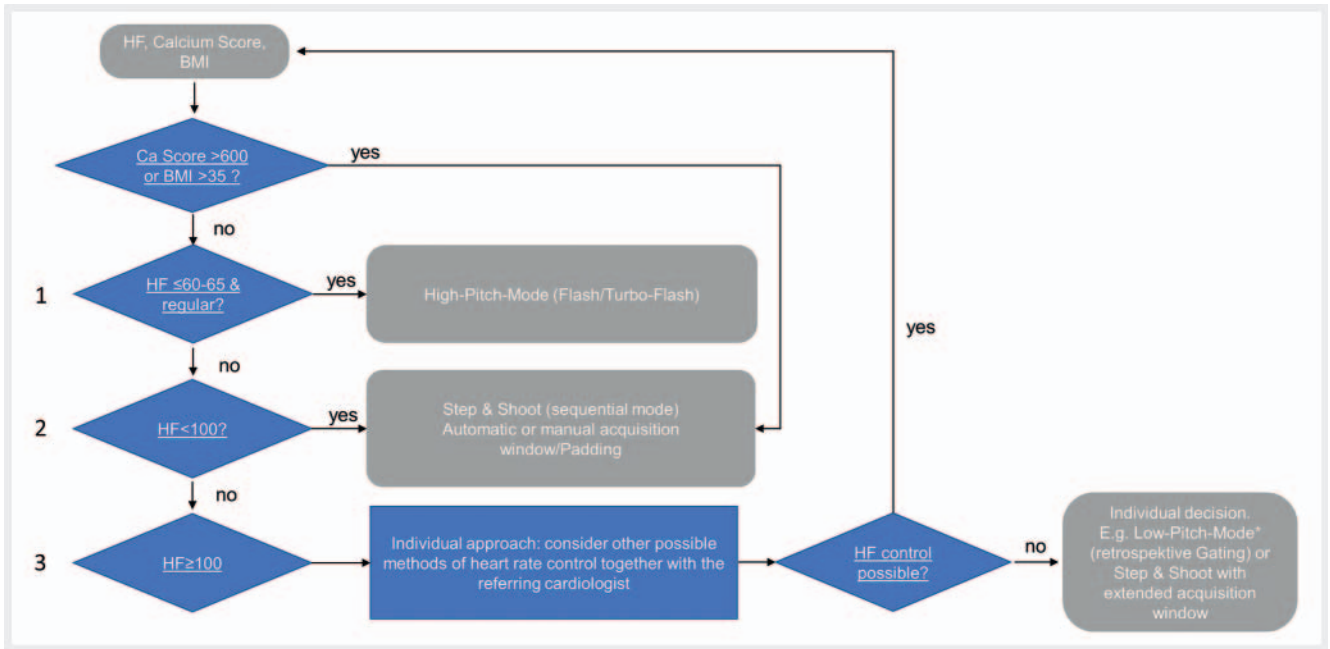
Essentially the following scan modes are available on modern scanners:

1. A helical “high-pitch” scan with acquisition of the entire heart within one cardiac cycle (RR interval) on dual-source devices of

the second generation or higher. A “single heartbeat” mode is possible on single-source scanners with a detector width of 16 cm, but the temporal resolution of dual-source scanners is currently higher [33]. Since the heart is only scanned at one point in time in the RR interval (usually during diastole), this mode has the lowest radiation dose.

2. A prospective ECG-triggered sequential scan (known as the “Step&Shoot” technique). In this method, a certain segment of the ECG cycle can be selectively scanned (“padding”), e. g., only the diastolic 66–74 % phase of the RR interval or a systolic + diastolic 30–80 % phase of the RR interval (acquisition window). The radiation dose of this scan mode is usually lower than that of the “low-pitch coil” but depends greatly on the acquisition window (“padding”) [33].
3. A “low-pitch” coil with retrospective ECG-synchronized image reconstruction. Today this is only still used in exceptional cases for cCTA. ECG-guided tube current modulation (known as “pulsing”) can be used to reduce the dose. In spite of this, this scan mode is usually associated with the highest radiation dose even on modern scanners [25].

The scan mode is selected here based primarily on heart rate and heart rate variability. In individual cases, BMI and the amount of coronary calcifications can additionally affect the selection of the scan protocol.



► **Fig. 4** Proposed algorithm to choose the scan protocol. HR: heart rate. HV: heart rate variability. **1** With 3rd-generation dual-source CT scanners (DSCTs), high-pitch mode (“Turbo-Flash”/“Flash”) can be used up to HR ≤ 65 /min and HV ≤ 2 /min. In the case of 2nd-generation DSCTs without hardware updates, we recommend a limit of HR ≤ 60 /min and HV ≤ 1 /min. **2** For acquisition window in % or ms of RR-interval, refer to the proposed padding scheme considering HR and HV in ► **Table 3**.

► **Fig. 4** shows a possible decision algorithm for the scan protocol on a second or third-generation dual-source scanner that can be effectively used for most patients. Exceptions to this rule include, for example, young patients for whom a protocol using the lowest possible dose depending on the particular medical issue (e. g., coronary anomaly) should be selected. The radiation dose values of the planned scan mode for every examination should be reviewed for suitability in terms of the ALARA principle.

1. “High-pitch” scan

This option is only available on dual-source scanners. At a heart rate ≤ 65 /min and a low heart rate variability ≤ 2 /min, numerous studies on third-generation dual-source scanners showed very good quality of cCTA in the case of acquisition in high-pitch mode (“Flash”/“Turbo-Flash” scan) during diastole (starting at approx. 65 % of the RR interval) [34–37]. In the case of second-generation dual-source scanners, we recommend more conservative selection of the high-pitch mode at a heart rate ≤ 60 /min and a heart rate variability ≤ 1 /min [38].

In the case of severe coronary calcifications with an Agatston score of 600 or higher, studies showed a significant decrease in image quality in high-pitch mode regardless of the heart rate [37], while studies on the same scanners showed consistently high image quality for the prospective sequential scan (“Step&Shoot”) at a significantly higher Agatston score [25]. One explanation for this could be the higher radiation dose used in sequential mode. Another explanation could be that sequential mode allows the reconstruction of multiple time points, while high-pitch mode only allows reconstruction of one time point. Therefore, we use

sequential mode (“Step&Shoot”) in the case of a high Agatston score regardless of heart rate.

In studies including patients with a high BMI, a conservative scan mode with the option of reconstructing multiple cardiac cycle phases was selected [25]. Based on this, we also typically use the sequential mode (“Step&Shoot”) instead of the high-pitch mode in patients with class II obesity (BMI ≥ 35 kg/m²).

2. Sequential scan (“Step&Shoot”)

In the case of modern dual-source scanners, the prospective ECG-triggered sequential scan (“Step&Shoot technique”) can be used without a significant loss of image quality even at a high heart rate (approx. 70–100/min) [14, 25]. At a heart rate of up to 70/min, a narrow acquisition window (“narrow padding”) limited exclusively to diastole (e. g., 60–80 % of the RR interval) is sufficient in this mode on second or third-generation dual-source scanners to achieve good image quality with high reliability. However, it must be taken into consideration here that the acquisition window is expanded at a high heart rate (“wide padding”) or should be shifted from diastolic to end-systolic cardiac phases (“systolic padding”). Studies on older [39–41] as well as modern scanners [14, 42] showed that end-systolic reconstructions (acquisition window approx. 30–50 % of the RR interval) have fewer motion artifacts at higher heart rates (> 70 –75/min) than diastolic reconstructions (acquisition window approx. 30–50 % of the RR interval). In the case of a greatly fluctuating heart rate < 70 /min, the acquisition window should also be expanded (e. g., to 30–80 % of the RR interval in the case of fluctuations of > 10 beats/min). In the case of an arrhythmia (at a heart rate 70–100/min), it is recommended to switch from percentage-based triggering of the

► **Table 3** Example of a simple padding scheme (acquisition window in Step&Shoot) which can be used for 2nd and 3rd generation dual-source CT scanners (DSCTs). Parameters are chosen conservatively to attain high-quality images with a high degree of certainty. On 3rd generation DSCT scanners, protocols with less coverage of the RR-cycle may be implemented with higher certitude, e. g., pure diastolic gating at regular HR < 70–75/min and pure systolic gating at regular HR > 70–75/min. This has a considerable effect on radiation dose which is particularly relevant for younger patients.

HR, HV	Start	End	Unit
HR ≤ 70/min, HV ≤ 10/min	60	80	%
HR ≤ 70/min, HV > 10/min	30	80	%
HR > 70/min, HV ≤ 10/min	30	80	%
HR > 70/min, HV > 10/min	120	600	ms

HR: heart rate; HV: heart rate variability.

RR interval (e. g., 35–55 %) to a fixed systolic window in milliseconds (ms) (e. g., 210–440 ms at an HR 75–100/min) [43] because the systolic phase remains largely constant at a high irregular heart rate while the duration of diastole changes greatly. Triggering based on a percentage of the RR interval thus results in highly fluctuating, unpredictable acquisition phases in the cardiac cycle, while triggering on an ms basis starting at the R wave results in a relatively predictable constant acquisition phase.

► **Table 3** shows a possible padding scheme for second and third-generation dual-source scanners.

3. “Low-pitch” coil with retrospective gating

In the case of pronounced tachycardia with arrhythmia (HR > 100/min) without an option for anti-arrhythmia treatment or medication to reduce HR, it is possible to use a “low-pitch” coil with retrospective ECG-synchronized image reconstruction. The relatively high radiation dose used in this scan mode can be reduced by ECG-synchronized tube current modulation (“pulsing”). The tube current can be reduced (e. g., to 20 % of the initial value) during segments of the ECG cycle that are presumably not diagnostic (e. g. 0–20 % and 80–100 % of the RR interval). An advantage of retrospective image reconstruction is that, in the case of poor identification of cardiac cycles, ECG synchronization points can be subsequently shifted or reset, thereby reducing artifacts due to arrhythmia.

Contrast agent

The amount of contrast agent is 60 ml for high-pitch mode and 70 ml for the other scan modes. The contrast flow rate is 6 ml/s (identical to the test bolus). In high-pitch mode, the amount of contrast agent can be significantly reduced on an individual basis in slender patients and in the case of a lower cardiac output [34, 35]. In one study the amount of contrast agent at 70 kV was able to be reduced to 30 ml (370 mg iodine/ml) in slender patients with a BMI < 25 kg/m² while maintaining diagnostic image quality [34]. In another study, the amount of contrast agent in patients with a BMI < 26 kg/m² was able to be reduced to 45 ml (400 mg iodine/ml).

In the case of class II obesity (BMI ≥ 35 kg/m²) and a correspondingly high cardiac output, the amount of contrast agent should be increased (e. g., 90 ml, contrast flow rate using a 16G/17G catheter (gray/white) 7–8 ml/s) [29, 32]. It is recommended to use a biphasic contrast protocol, i. e., to follow contrast administration directly with an identical volume of NaCl solution (chaser) to flush the contrast agent out of the peripheral veins into the right atrium.

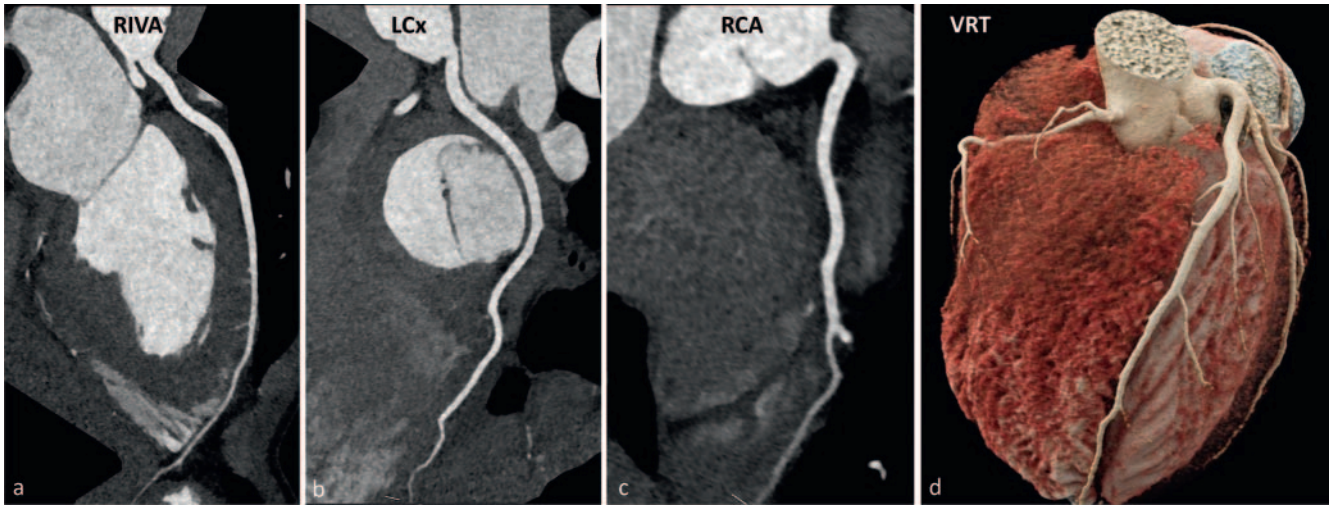
Reconstructions

The voxel size and thus the spatial resolution depends on the resolution in the Z-direction (through-plane resolution) and the pixel size in an axial slice plane (in-plane resolution) [44]. The latter corresponds (to a certain extent) to the quotient of the field of view (FOV) divided by the matrix size [44]. To achieve a high spatial resolution, it is therefore recommended to use a smaller slice thickness (< 1 mm) and to perform reconstruction in a smaller FOV focused on the heart and containing the coronary vessels instead of an FOV containing the entire thorax. However, the real maximum in-plane resolution is determined by the scanner that is used. Moreover, some scanners have the option of reconstructing a 1024 × 1024 matrix for higher resolution.

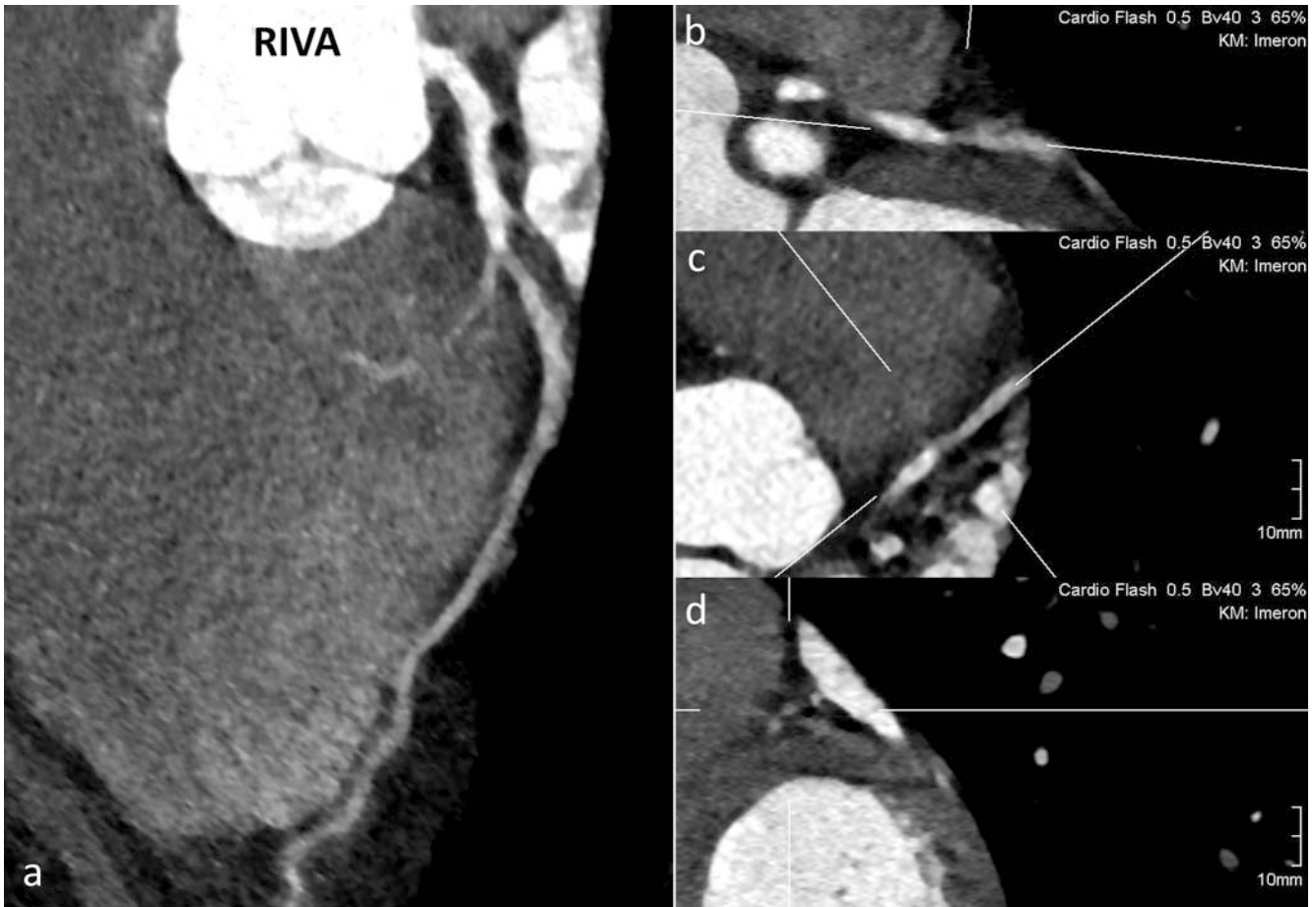
We recommend reconstructing the following cardiac phases:

For Step&Shoot (sequential):

1. Software-based, automatic detection of the diastolic cardiac phase with the fewest artifacts (e. g., “Best Diastole” from Siemens Healthcare).
2. Software-based, automatic detection of the systolic cardiac phase with the fewest artifacts (e. g., “Best Systole” from Siemens Healthcare).
3. Reconstruction of the entire acquired interval (multiphase) in 5 % increments. We recommend reconstruction without subsequent overlapping of the individual stacks so that artifacts caused by shifting between the stacks can be easily detected (“TrueStack from Siemens Healthcare”).

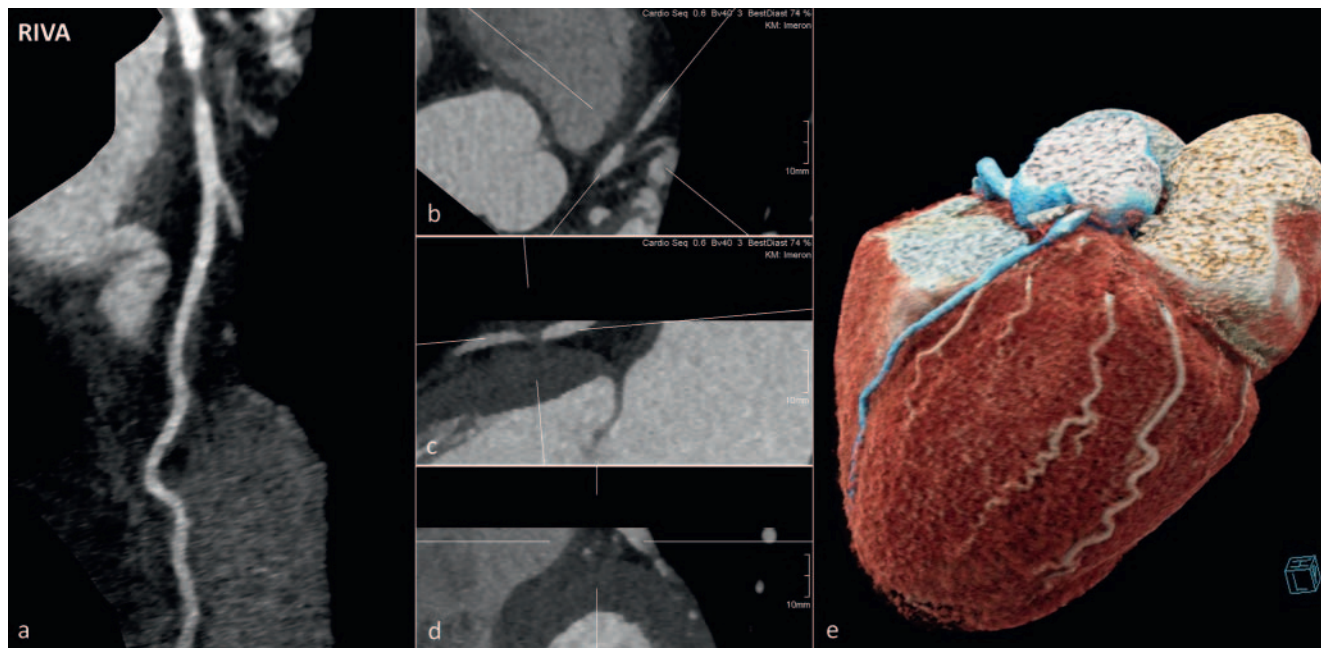


► **Fig. 5** Successful acquisition with good image quality using high-pitch mode (“Turbo-Flash”) on a 3rd-generation DSCT scanner. HR = 63/min, HV = 1/min. Amount of contrast = 60 ml. **a** Curved planar reconstruction (CPR) of left anterior descending (LAD) artery. **b** CPR of Ramus Circumflexus (LCx). **c** CPR of the right coronary artery (RCA). **d** Volume Rendering Technique (VRT) of the heart.



► **Fig. 6** High-pitch mode (“Turbo-Flash”) on a 3rd-generation DSCT scanner was used at HR = 67/min and HV = 5/min. Motion artifacts and an abrupt drop in contrast attenuation at the transition of proximal to mid LAD are visible. **a** CPR of LAD. **b–d** Multiplanar reconstruction (MPR) of LAD. Diagnostic image quality is reduced. Relevant coronary artery stenosis cannot be excluded with certainty.

This document was downloaded for personal use only. Unauthorized distribution is strictly prohibited.



► **Fig. 7** Same patient as in ► **Fig. 6**. Part of the CT scan that was affected by artifacts and was non-diagnostic/unclear was repeated. Therefore, Step&Shoot mode was chosen with a diastolic acquisition window of 60–80 % of the RR-interval according to ► **Table 3** at HR = 67/min and HV = 5/min. Repeated examination was successful with good image quality. Amount of contrast agent = 60 ml. High-grade stenosis of the LAD could be discerned. **a** CPR of LAD. **b–d** Multiplanar reconstruction (MPR) of LAD. **e** Volume Rendering Technique (VRT) of the heart. High-grade stenosis of the LAD is now clearly detectable.

For the low-pitch coil (retrospective):

1. Check synchronization points and shift, reset, or delete if necessary.
2. Software-based, automatic detection of the diastolic cardiac phase with the fewest artifacts (e. g., “Best Diastole” from Siemens Healthcare).
3. Software-based, automatic detection of the systolic cardiac phase with the fewest artifacts (e. g., “Best Systole” from Siemens Healthcare).
4. Reconstruction of the entire acquired interval (multiphase) in 5 % increments. We recommend reconstruction without subsequent overlapping of the individual stacks (“TrueStack” from Siemens Healthcare).
5. Reconstruction of the entire acquired interval (multiphase) in 50 ms increments. Reconstruction without subsequent overlapping of the individual stacks (“TrueStack” from Siemens Healthcare).

Checking image quality

At the end of the examination, the image quality is checked visually. Attention is given to the following:

- Has the heart including the coronary arteries been completely visualized?
- Is there good contrast enhancement of the target vessels?
- Is the examination free of significant motion artifacts (breathing artifacts or artifacts caused by arrhythmia) that limit the diagnostic image quality?

If one of these points is not satisfied, repeating the part of the examination that is limited by artifacts should be considered.

► **Fig. 5** shows an example of a cCTA examination with sufficient diagnostic image quality. An example of limited diagnostic image quality due to artifacts is shown in ► **Fig. 6**.

The Step&Shoot mode with expanded padding (e. g., 30–80 % of the RR interval) with a contrast volume of 50–60 ml (with 1–2 steps) is typically sufficient for repeating individual parts of the examination. It is usually not necessary to administer nitrates or beta blockers again. The scan with artifacts shown in ► **Fig. 6** was repeated to achieve good diagnostic image quality as shown in ► **Fig. 7**.

Discharge and reporting

If beta blockers or nitrates are administered, outpatients remain in the department for 20–30 minutes after the examination to monitor for any possible side effects. The physician provides an initial report of the relevant findings directly after the examination. If the patient requests a case discussion or in the event of acute relevant findings, the findings are presented to the patient and the referring physician. In our department, the further course of action is determined in interdisciplinary collaboration with the referring physician and/or colleagues in cardiology. The CAD-RADS criteria can provide guidance for determining coronary stenosis severity and further recommendations based on the CT findings [45]. However, the recommendations should always be considered on an individual basis in the clinical context [45].

KEY POINTS FOR CLINICAL PRACTICE

- cCTA is recommended in the current guidelines of the ESC primarily in the case of low and intermediate clinical probability of coronary artery disease.
- This study and the consensus recommendations of the Society of Cardiovascular Computed Tomography (SCCT) can be used as an orientation guide for the practical workflow for cCTA preparation and acquisition.
- Premedication with beta blockers and nitrates prior to examination can be helpful even when using the latest scanner generations.
- Image quality and radiation dose still depend on the examination preparation and the selection of the scan protocol.
- CT scanners currently in use typically allow retrospective ECG gating, a prospective ECG-triggered scan, and a high-pitch mode (dual-source scanners) or single heartbeat mode (single-source scanners).
- The scan mode is selected primarily based on heart rate and heart rate variability and only in individual cases on the amount of coronary calcification and BMI.
- High-pitch mode in dual-source scanners (“Flash”/“Turbo-Flash”) is used primarily in the case of low and regular heart rates and has the lowest dose exposure.
- The Step&Shoot mode can be used for a broad range of heart rates. The ECG-triggered acquisition window is to be set in % or ms of the RR interval (padding) based on heart rate and heart rate variability.
- The low-pitch coil (retrospective gating) is only used in individual cases, e. g., in absolute tachyarrhythmia. It typically has the highest radiation dose of the three scan modes.
- cCTA image quality should be checked prior to the end of the examination. In the case of limited diagnostic image quality, it is recommended to repeat the relevant examination segments.

Conflict of Interest

The authors declare that they have no conflict of interest.

References

- [1] Knuuti J, Wijns W, Saraste A et al. (2020) 2019 ESC Guidelines for the diagnosis and management of chronic coronary syndromes. *European Heart Journal* 41: 407–477
- [2] Dewey M, Hamm B. CT-Koronarangiografie: Untersuchungstechnik, klinische Ergebnisse und Ausblick in zukünftige Entwicklungen [CT coronary angiography: examination technique, clinical results, and outlook on future developments]. *Rofo* 2007; 179: 246–260
- [3] Haase R, Schlattmann P, Gueret P et al. COME-CCT Consortium. Diagnosis of obstructive coronary artery disease using computed tomography angiography in patients with stable chest pain depending on clinical probability and in clinically important subgroups: meta-analysis of individual patient data. *BMJ* 2019; 365: 11945
- [4] Newby DE, Adamson PD, Berry C. SCOT-HEART Investigators et al. Coronary CT Angiography and 5-Year Risk of Myocardial Infarction. *N Engl J Med* 2018; 379: 924–933
- [5] Achenbach S, Barkhausen J, Beer M et al. Konsensusempfehlungen der DRG/DGK/DGPK zum Einsatz der Herzbildgebung mit Computertomographie und Magnetresonanztomographie. *Kardiologie* 2012; 6: 105–125
- [6] Busse A, Cantré D, Beller E et al. Cardiac CT: why, when, and how. *Radiologe* 2019; 59: 1–9
- [7] Mahnken AH. Imaging of Coronary Stents by Coronary CT-Angiography: Current Status. *Curr Cardiovasc Imaging Rep* 2012; 5: 274–281
- [8] Andreini D, Pontone G, Mushtaq S et al. Diagnostic accuracy of coronary CT angiography performed in 100 consecutive patients with coronary stents using a whole-organ high-definition CT scanner. *International Journal of Cardiology* 2019; 274: 382–387
- [9] Baumgartner H, Falk V, Bax JJ et al. 2017 ESC/EACTS Guidelines for the management of valvular heart disease. *European Heart Journal* 2017; 38: 2739–2791
- [10] Collet JP, Thiele H, Barbato E. ESC Scientific Document Group. et al. 2020 ESC Guidelines for the management of acute coronary syndromes in patients presenting without persistent ST-segment elevation. *Eur Heart J* 2021; 42: 1289–1367. Erratum in: *Eur Heart J*. 2021 May 14;42(19):1908. Erratum in: *Eur Heart J*. 2021 May 14;42(19):1925. Erratum in: *Eur Heart J*. 2021 May 13;; PMID: 32860058 doi:10.1093/eurheartj/ehaa575
- [11] Abbara S, Blanke P, Maroules CD et al. SCCT guidelines for the performance and acquisition of coronary computed tomographic angiography: A report of the society of Cardiovascular Computed Tomography Guidelines Committee: Endorsed by the North American Society for Cardiovascular Imaging (NASCI). *J Cardiovasc Comput Tomogr* 2016; 10: 435–449
- [12] Pannu HK, Alvarez W Jr, Fishman EK. Beta-blockers for cardiac CT: a primer for the radiologist. *Am J Roentgenol* 2006; 186: S341–S345
- [13] Khan M, Cummings KW, Gutierrez FR et al. Contraindications and side effects of commonly used medications in coronary CT angiography. *Int J Cardiovasc Imaging* 2011; 27: 441–449
- [14] Miller RJH, Eisenberg E, Friedman J et al. Impact of heart rate on coronary computed tomographic angiography interpretability with a third-generation dual-source scanner. *Int J Cardiol* 2019; 295: 42–47
- [15] Li M, Zhang GM, Zhao JS et al. Diagnostic performance of dual-source CT coronary angiography with and without heart rate control: systematic review and meta-analysis. *Clin Radiol* 2014; 69: 163–171
- [16] Takx RA, Suchá D, Park J et al. Sublingual Nitroglycerin Administration in Coronary Computed Tomography Angiography: a Systematic Review. *Eur Radiol* 2015; 25: 3536–3542
- [17] Jiménez-Juan L, Nguyen ET, Wintersperger BJ et al. Failed heart rate control with oral metoprolol prior to coronary CT angiography: effect of additional intravenous metoprolol on heart rate, image quality and radiation dose. *Int J Cardiovasc Imaging* 2013; 29: 199–206
- [18] Kim C, Ha M, Kim W et al. Nitrates administered by spray versus tablet: comparison of coronary vasodilation on CT angiography. *Eur Radiol* 2021; 31: 515–524
- [19] Pfister M, Seiler C, Fleisch M et al. Nitrate induced coronary vasodilatation: differential effects of sub-lingual application by capsule or spray. *Heart* 1998; 80: 365–369
- [20] Sato K, Isobe S, Sugiura K et al. Optimal starting time of acquisition and feasibility of complementary administration of nitroglycerin with intravenous beta-blocker in multislice computed tomography. *J Comput Assist Tomogr* 2009; 33: 193–198
- [21] Dewey M, Hoffmann H, Hamm B. Multislice CT coronary angiography: effect of sublingual nitroglycerine on the diameter of coronary arteries. *Röfo* 2006; 178: 600–604

- [22] Akers SR, Panchal V, Ho VB. Expert Panel on Cardiac Imaging et al. ACR Appropriateness Criteria Chronic Chest Pain-High Probability of Coronary Artery Disease. *J Am Coll Radiol* 2017; 14: S71–S80
- [23] Brodoefel H, Burgstahler C, Tsiflikas I et al. Dual-source CT: effect of heart rate, heart rate variability, and calcification on image quality and diagnostic accuracy. *Radiology* 2008; 247: 346–355
- [24] Raff GL, Gallagher MJ, O'Neill WW et al. Diagnostic accuracy of noninvasive coronary angiography using 64-slice spiral computed tomography. *J Am Coll Cardiol* 2005; 46: 552–557
- [25] Ochs MM, Siepen FAD, Fritz T et al. Limits of the possible: diagnostic image quality in coronary angiography with third-generation dual-source CT. *Clin Res Cardiol* 2017; 106: 485–492
- [26] Busse A, Cantré D, Beller E et al. Cardiac CT: why, when, and how. *Radiologe* 2019; 59: 1–9
- [27] Osawa K, Nakanishi R, Budoff M. Coronary Artery Calcification. *Glob Heart* 2016; 11: 287–293. doi:10.1016/j.ghheart.2016.08.001
- [28] Mitchell JD, Fergestrom N, Gage BF et al. Impact of Statins on Cardiovascular Outcomes Following Coronary Artery Calcium Scoring. *Journal of the American College of Cardiology* 2018; 72: 3233–3242
- [29] Grundy SM, Stone NJ, Bailey AL et al. 2018 AHA/ACC/AACVPR/AAPA/ABC/ACPM/ADA/AGS/APhA/ASPC/NLA/PCNA Guideline on the Management of Blood Cholesterol: Executive Summary. *Journal of the American College of Cardiology* 2019; 73: 3168–3209
- [30] Muhl C, Kok M, Altintas S et al. Evaluation of individually body weight adapted contrast media injection in coronary CT-angiography. *Eur J Radiol* 2016; 85: 830–836
- [31] Scholtz JE, Ghoshhajra B. Advances in cardiac CT contrast injection and acquisition protocols. *Cardiovasc Diagn Ther* 2017; 7: 439–451
- [32] Ramos-Duran LR, Kalafut JF, Hanley M et al. Current contrast media delivery strategies for cardiac and pulmonary multidetector-row computed tomography angiography. *J Thoracic Imaging* 2010; 25: 270–277
- [33] Meyer M, Henzler T. Stellenwert der Herz-CT in der Diagnostik der koronaren Herzerkrankung: Update 2017. *Radiologe* 2017; 57: 577–590
- [34] Zhang LJ, Qi L, Wang J et al. Feasibility of prospectively ECG-triggered high-pitch coronary CT angiography with 30 mL iodinated contrast agent at 70 kVp: initial experience. *Eur Radiol* 2014; 24: 1537–1546
- [35] Meyer M, Haubenreisser H, Schoepf UJ et al. Closing in on the K edge: coronary CT angiography at 100, 80, and 70 kV-initial comparison of a second- versus a third-generation dual-source CT system. *Radiology* 2014; 273: 373–382
- [36] Gordic S, Husarik DB, Desbiolles L et al. High-pitch coronary CT angiography with third generation dual-source CT: limits of heart rate. *Int J Cardiovasc Imaging* 2014; 30. doi:10.1007/s10554-014-0445-5
- [37] Ochs MM, Andre F, Korosoglou G et al. Strengths and limitations of coronary angiography with turbo high-pitch third-generation dual-source CT. *Clin Radiol* 2017; 72: 739–744
- [38] Goetti R, Baumüller S, Feuchtner G et al. High-pitch dual-source CT angiography of the thoracic and abdominal aorta: is simultaneous coronary artery assessment possible? *Am J Roentgenol* 2010; 194: 938–944
- [39] Leschka S, Scheffel H, Desbiolles L et al. Image quality and reconstruction intervals of dual-source CT coronary angiography: recommendations for ECG-pulsing windowing. *Invest Radiol* 2007; 42: 543–549
- [40] Araoz PA, Kirsch J, Primak AN et al. Optimal image reconstruction phase at low and high heart rates in dual-source CT coronary angiography. *Int J Cardiovasc Imaging* 2009; 25: 837–845
- [41] Bamberg F, Sommer WH, Schenzle JC et al. Systolic acquisition of coronary dual-source computed tomography angiography: feasibility in an unselected patient population. *Eur Radiol* 2010; 20: 1331–1336
- [42] Secinara A, Curione D, Mortensen KH et al. Dual-source computed tomography coronary artery imaging in children. *Pediatr Radiol* 2019; 49: 1823–1839
- [43] Booij R, Dijkshoorn ML, van Straten M et al. Cardiovascular imaging in pediatric patients using dual source CT. *J Cardiovasc Comput Tomogr* 2016; 10: 13–21
- [44] Ghekiere O, Salgado R, Bult N et al. Image quality in coronary CT angiography: challenges and technical solutions. *Br J Radiol* 2017; 90: 20160567
- [45] Cury RC, Abbara S, Achenbach S et al. CAD-RADS(TM) Coronary Artery Disease – Reporting and Data System. An expert consensus document of the Society of Cardiovascular Computed Tomography (SCCT), the American College of Radiology (ACR) and the North American Society for Cardiovascular Imaging (NASCI). Endorsed by the American College of Cardiology. *J Cardiovasc Comput Tomogr* 2016; 10: 269–281