

Is endoscopic mucosal resection optimum for treating colonic angiodysplasia?

Colonic angiodysplasias are vascular malformations frequently responsible for recurrent bleeding, for which the gold standard endoscopic treatment is argon plasma coagulation (APC). However, APC can be risky, particularly in the right colon and in cases of large angiodysplasias. Indeed, secondary perforation caused by transmural necrosis due to the unpredictability of the destruction depth is a potentially life-threatening complication of APC in the right colon (prevalence 1%) [1]. Moreover, APC frequently induces immediate bleeding and clot formation, reducing its efficacy and leading to a high rebleeding rate. Finally, the cost of the procedure is not negligible and patients suffering from bleeding often require urgent transfer to a specialist center.

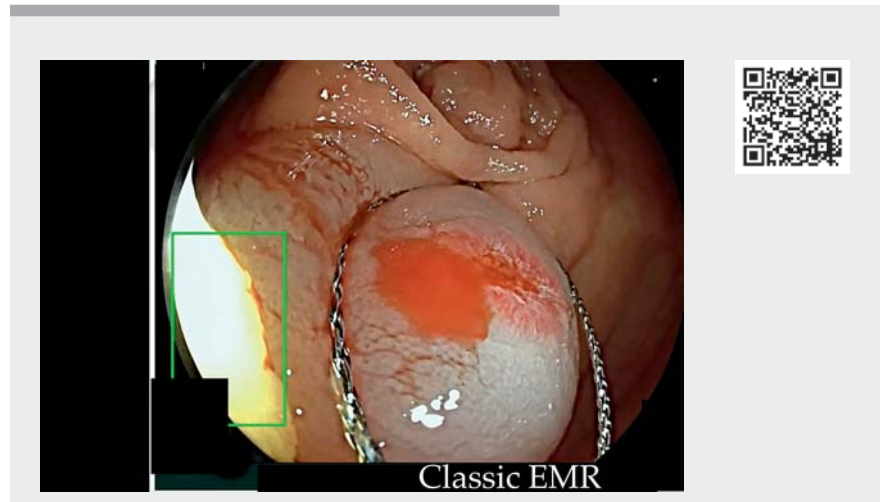
We report endoscopic mucosal resection (EMR) as an alternative for treating colonic angiodysplasia. After NaCl injection, EMR is performed using an Endocut current to remove angiodysplasia (▶ **Video 1**, ▶ **Fig. 1**, ▶ **Fig. 2**). Coagulation of the resection scar (▶ **Fig. 3**) is performed simultaneously with identification of the feeding vessel, which is coagulated using the tip of the snare. Finally, the scar is closed using classic hemoclips (▶ **Fig. 4**). An Australian team has reported that this method shows promise based on its broad availability, low cost, and rapidity [2].

Angiodysplasia is caused by vascular ramification in the mucosae originating from a feeding vessel. Targeting the feeding vessel by EMR could be the optimum treatment modality. A prospective comparative study is needed to confirm this hypothesis.

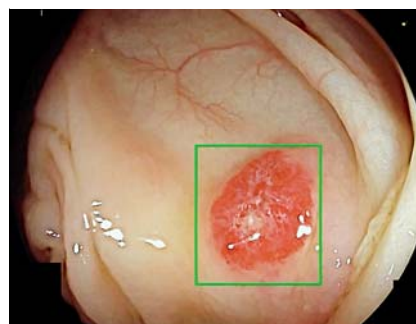
Endoscopy_UCTN_Code_TTT_1AQ_2AZ

Competing interests

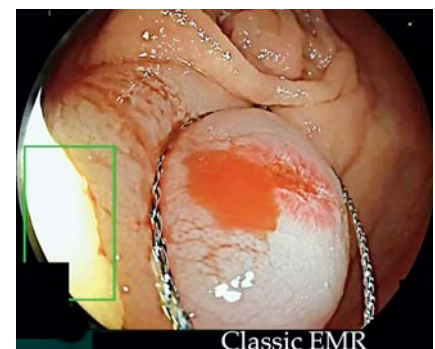The authors declare that they have no conflict of interest.



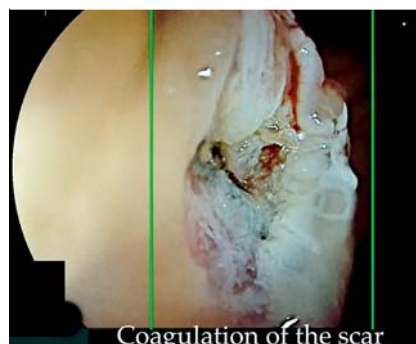▶ **Video 1** Endoscopic mucosal resection of a right colon angiodysplasia.



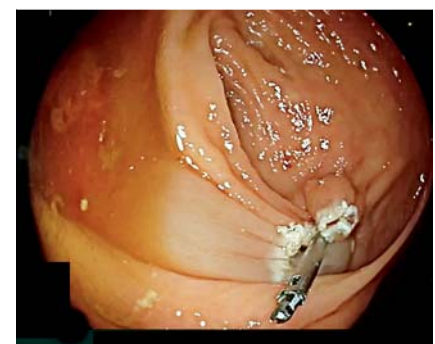▶ **Fig. 1** Angiodysplasia of the right colon.



▶ **Fig. 2** Endoscopic mucosal resection of the angiodysplasia.



▶ **Fig. 3** Scar after endoscopic mucosal resection.



▶ **Fig. 4** Closure of the scar.

The authors

Sophie Geyl¹, Jérémie Albouys¹, Marion Schaefer², Hugo Lepetit¹, Romain Legros¹, Mathieu Pioche³, Jérémie Jacques^{1,4}

- 1 Service d'Hépatogastro-entérologie, CHU Dupuytren, Limoges, France
- 2 Service d'Hépatogastro-entérologie, CHU de Poitiers, Poitiers, France
- 3 Service d'Hépatogastro-entérologie, Hôpital Edouard Herriot, CHU Lyon, France
- 4 BioEM, XLim, UMR 7252, CNRS, Limoges

Corresponding author

Jérémie Jacques, MD

Limoges University Hospital, 2 avenue Martin Luther King, 87042 Limoges, France
jeremiejacques@gmail.com

References

- [1] Olmos JA, Marcolongo M, Pogorelsky V et al. Long-term outcome of argon plasma ablation therapy for bleeding in 100 consecutive patients with colonic angiodysplasia. *Dis Colon Rectum* 2006; 49: 1507–1516. doi:10.1007/s10350-006-0684-1
- [2] Sriram N, Bar-Yishay I, Kumarasinghe P et al. Definitive therapy of colonic angioectasia by submucosal coagulation. *Endosc Int Open* 2019; 7: E1773–E1777. doi:10.1055/a-0965-6688

Bibliography

Endoscopy 2022; 54: 1233–1234

DOI 10.1055/a-1750-9105

ISSN 0013-726X

published online 18.2.2022

© 2022. Thieme. All rights reserved.

Georg Thieme Verlag KG, Rüdigerstraße 14, 70469 Stuttgart, Germany

ENDOSCOPY E-VIDEOS

<https://eref.thieme.de/e-videos>



Endoscopy E-Videos is an open access online section, reporting on interesting cases

and new techniques in gastroenterological endoscopy. All papers include a high quality video and all contributions are freely accessible online. Processing charges apply (currently EUR 375), discounts and waivers acc. to HINARI are available.

This section has its own submission website at

<https://mc.manuscriptcentral.com/e-videos>