

## Sequential double stent placement using the stent-pushing-stent technique over a single wire during double-balloon ERCP

Double-balloon enteroscopy (DBE)-assisted endoscopic retrograde cholangiopancreatography (ERCP) is now an established technique to perform various types of diagnostic and therapeutic interventions in patients with surgically altered upper gastrointestinal anatomy [1]. Herein, we present a novel and simple technique of dual stenting using the stent-pushing-stent technique.

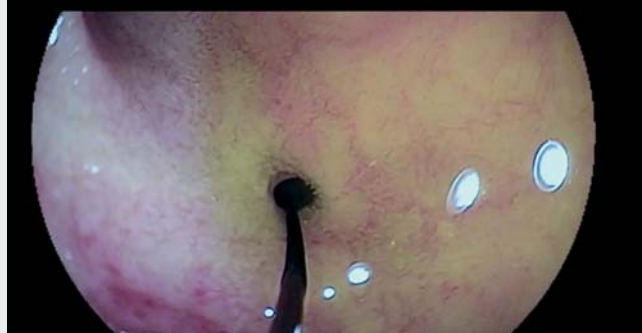A 45-year-old patient who had undergone liver transplant for cirrhosis due to primary sclerosing cholangitis 8 years previously presented with jaundice and cholestasis. Because of primary sclerosing cholangitis, the liver transplant was attached to a jejunal loop (hepaticojejunostomy). Therefore, ERCP had to be performed using DBE.

During DBE-ERCP, a tight hepaticojejunostomy stricture was found and classified as type A1 according to Mönkemüller-Jovanovic classification [2]. The stricture was dilated with a 6-mm-diam-

eter controlled radial expansion balloon (► **Video 1**). Insertion of plastic stents was indicated to keep the stenosis open

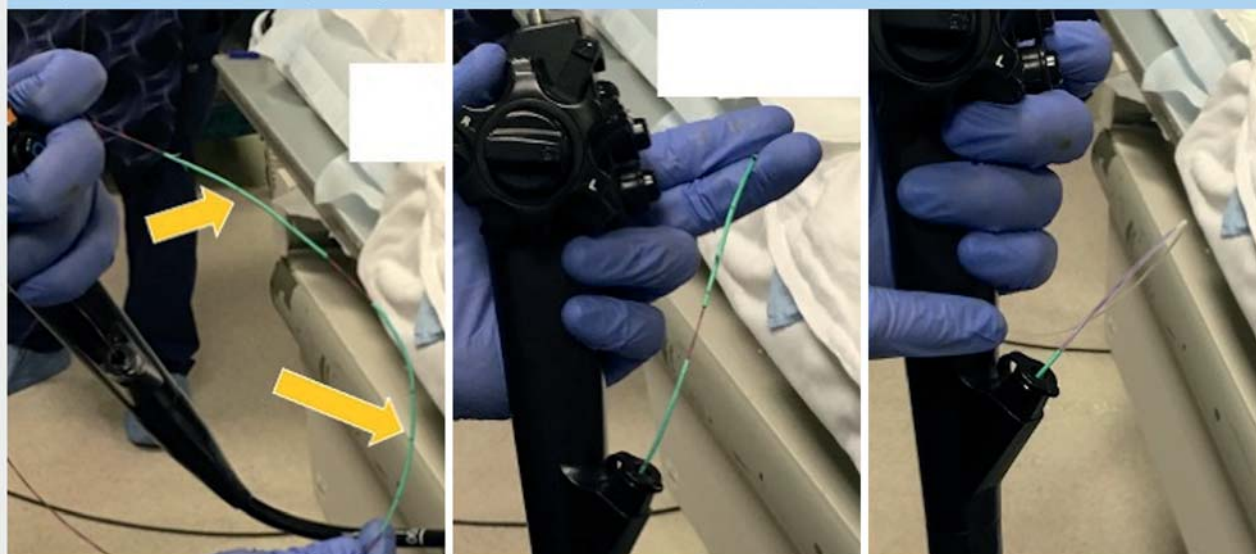
and allow for proper fibrotic remodeling around the hepaticojejunostomy, and thus reduce the chances of re-stenosis.

### Wire Placed Across of the Hepaticojejunal Anastomosis



► **Video 1** Sequential double stent placement using the stent-pushing-stent technique over a single wire during double-balloon enteroscopy-assisted endoscopic retrograde cholangiopancreatography.

### Sequential insertion of stent-pushing-stent with one-wire: The concept



► **Fig. 1** The stent-pushing-stent technique. The stents are advanced over the wire, one after the other. The long arrow shows the first stent and the short arrow shows the second, “pushing” stent. A pusher tube is used to push the proximal stent, which in turn pushes the distal stent.

We used a novel stent-pushing-stent technique (► **Fig. 1**, ► **Video 1**). The two plastic stents were placed using a single 0.035-inch biliary wire 450 cm in length. This technique shortens the procedure time and is useful when using device-assisted ERCP methods. The stents are advanced over the wire, one after the other; the pusher tube is used to push the proximal stent, which in turn pushes the distal stent. Once the first stent has been deployed, the wire is carefully retrieved, and then used to perform direct cannulation of the bile duct, next to the first stent. Once deep wire insertion is achieved, the second stent is deployed in the desired location.

This technique is ideal during ERCP with forward-viewing endoscopes, especially in the presence of hepaticojejunostomy and difficult postoperative anatomy, as it is practical and time saving.

Endoscopy\_UCTN\_Code\_CPL\_1AK\_2AD

## Acknowledgment

The stent-in-stent technique was developed by Prof. Klaus Mönkemüller, corresponding author.

## Competing interests

The authors declare that they have no conflict of interest.

## The authors

Álvaro Martínez-Alcalá<sup>1</sup>\*, Katarzyna M. Pawlak<sup>2</sup>\*, Ivan Jovanovic<sup>3</sup>, Klaus Mönkemüller<sup>3,4,5</sup>

- 1 Department of Gastroenterology, Hospital Universitario Infanta Leonor, Madrid, Spain
- 2 Department of Gastroenterology, Hospital of the Ministry of Internal Affairs in Szczecin, Poland
- 3 University of Belgrade, Belgrade, Serbia
- 4 Department of Gastroenterology, Aneos Teaching University Hospital (Otto-von-Guericke University – Magdeburg), Halberstadt, Germany
- 5 Department of Gastroenterology, Helios Frankenklinik, Kronach, Germany

## Corresponding author

**Klaus Mönkemüller, FJGES (Japan)**  
Division of Gastroenterology, University Teaching Hospital – Aneos Klinikum Halberstadt, Gleimstraße 5, 38820 Halberstadt, Germany  
moenkemueller@yahoo.com

## References

- [1] Skinner M, Popa D, Neumann H et al. ERCP with the overtube-assisted enteroscopy technique: a systematic review. *Endoscopy* 2014; 46: 560–572
- [2] Mönkemüller K, Jovanovic I. Endoscopic and retrograde cholangiographic appearance of hepaticojejunostomy strictures: a practical classification. *World J Gastrointest Endosc* 2011; 16: 213–219

## Bibliography

*Endoscopy* 2022; 54: E755–E756  
**DOI** 10.1055/a-1792-2601  
**ISSN** 0013-726X  
**published online** 11.4.2022  
© 2022. Thieme. All rights reserved.  
Georg Thieme Verlag KG, Rüdigerstraße 14,  
70469 Stuttgart, Germany

## ENDOSCOPY E-VIDEOS

<https://eref.thieme.de/e-videos>



*Endoscopy E-Videos* is an open access online section, reporting on interesting cases

and new techniques in gastroenterological endoscopy. All papers include a high quality video and all contributions are freely accessible online. Processing charges apply (currently EUR 375), discounts and waivers acc. to HINARI are available.

This section has its own submission website at  
<https://mc.manuscriptcentral.com/e-videos>

\* These authors contributed equally to this work.