Article published online: 2022-03-31

To-and-fro balloon technique for deployment of a lumen-apposing metal stent in highly solid walled-off necrosis of the pancreas

▶ **Fig. 1** Computed tomography delineating a large walled-off necrosis lesion.

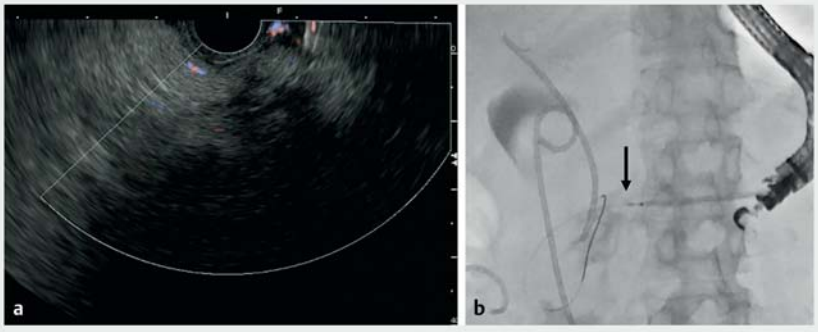

▶ **Fig. 2** Failed insertion of a lumen-apposing metal stent (LAMS) in a case with highly solid walled-off necrosis (WON). **a** Endosonographic view demonstrating few fluid components within the cavity of the WON. **b** Failed insertion of the LAMS delivery (arrow).

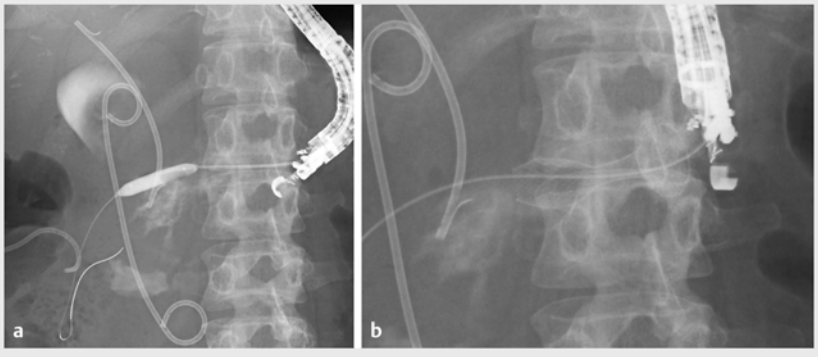

▶ **Fig. 3** The to-and-fro balloon technique opening up space for the lumen-apposing metal stent (LAMS). **a** Dilation balloon being moved to and fro within the cavity of the walled-off necrosis. **b** LAMS with fully expanded flanges due to the ballooned cavity.

Lumen-apposing metal stents (LAMSs) have revolutionized endoscopic treatment of walled-off necrosis (WON) by allowing for effective drainage and subsequent endoscopic necrosectomy [1, 2]. However, it may be technically challenging to deploy a LAMS for a WON with little fluid content [3], which potentially inhibits insertion of the delivery and expansion of the distal stent flange [4].

A 38-year-old woman was referred to our department for endoscopic management of an infected WON due to biliary pancreatitis (▶ **Fig. 1**). Although endoscopic ultrasound (EUS)-guided drainage was performed in the previous hospital, the infection did not subside owing to incomplete drainage; therefore, we decided to place a LAMS with a cautery-enhanced delivery system (HOT AXIOS; Boston Scientific Japan, Tokyo, Japan). EUS revealed a WON with few fluid components (▶ **Fig. 2 a**), and we decided to perform a wire-guided placement of the LAMS. We punctured the WON with a 19-gauge needle (EZshot3; Olympus Medical, Tokyo, Japan) via the transgastric approach and inserted the stent delivery over a 0.025-inch guidewire (VisiGlide2; Olympus). Owing to the limited space due to the highly solid cavity, the delivery could not be advanced (▶ **Fig. 2 b**). Therefore, we withdrew the delivery and inserted an 8-mm balloon dilator (REN; Kaneka Medix, Tokyo, Japan) into the WON cavity. We attempted to open up enough space for the LAMS by moving the dilated balloon to and fro (▶ **Fig. 3 a**). We successfully deployed the LAMS with adequate expansion of the flanges (▶ **Fig. 3 b**). On the second day of the procedure, radiograph delineated full expansion of the flanges. After subsequent sessions of endoscopic necrosectomy via the LAMS, complete resolution of the WON was achieved.

Inadequate expansion of the LAMS flanges may result in adverse events including stent migration and bleeding [5]. The to-and-fro balloon technique presented here (▶ **Video 1**) would further expand the indications of the LAMS for a symptomatic WON.

Endoscopy_UCTN_Code_TTT_1AS_2AG

Competing interests

Dr. Nakai declares research funding from Boston Scientific Japan, Century Medical, Fujifilm, Gadelius Medical, Hitachi Medical, Kaneka, and Medico's Hirata. This work was not supported by any of those companies.

This document was downloaded for personal use only. Unauthorized distribution is strictly prohibited.

Video 1 The to-and-fro balloon technique for deployment of a lumen-apposing metal stent in a highly solid walled-off necrosis.

Dr. Fujishiro received lecture honoraria from Olympus Co., and Fujifilm Co. and research grant from Olympus Co, and Fujifilm Co. outside the submitted work. The other authors declare no conflicts of interest related to this article.

The authors

Tatsuya Sato[1*], Tomotaka Saito[1*], Yousuke Nakai[1,2*], Mitsuhiro Fujishiro[1]

1 Department of Gastroenterology, Graduate School of Medicine, The University of Tokyo, Tokyo, Japan

2 Department of Endoscopy and Endoscopic Surgery, The University of Tokyo Hospital, Tokyo, Japan

Corresponding author

Yousuke Nakai, MD
Department of Endoscopy and Endoscopic Surgery, The University of Tokyo Hospital, 7-3-1 Hongo, Bunkyo-ku, Tokyo 113-8655, Japan
Fax: +81-3-3814-0021
ynakai-tky@umin.ac.jp

References

[1] Yasuda I, Takahashi K et al. Endoscopic management of walled-off pancreatic necrosis. Dig Endosc 2021; 33: 335–341

[2] Bang JY, Varadarajulu S et al. Lumen-apposing metal stents for endoscopic ultrasonography-guided interventions. Dig Endosc 2019; 31: 619–626

[3] Fabbri C, Baron T, Gibiino G et al. Endoscopic ultrasound features of pancreatic fluid collections and their impact on therapeutic decisions: an interobserver agreement study. Endoscopy 2021. doi:10.1055/a-1640-4365

[4] Mukai S, Itoi T, Tsuchiya T et al. New deployment techniques of the lumen-apposing metal stent in walled-off necrosis filled with necrotic tissue: Chick opening its mouth (with video). Dig Endosc 2021; 33: 985–989

[5] Fujimori N, Minoda Y, Murakami M et al. Endoscopic removal of a lumen-apposing metal stent that migrated into the walled-off necrosis during the first drainage procedure. Endoscopy 2020; 52: E51–E52

Bibliography

Endoscopy 2022; 54: E750–E751
DOI 10.1055/a-1795-6925
ISSN 0013-726X
published online 31.3.2022

© 2022. Thieme. All rights reserved.

Georg Thieme Verlag KG, Rüdigerstraße 14, 70469 Stuttgart, Germany

ENDOSCOPY E-VIDEOS
https://eref.thieme.de/e-videos

Endoscopy E-Videos is an open access online section, reporting on interesting cases and new techniques in gastroenterological endoscopy. All papers include a high quality video and all contributions are freely accessible online. Processing charges apply (currently EUR 375), discounts and wavers acc. to HINARI are available.

This section has its own submission website at https://mc.manuscriptcentral.com/e-videos

This document was downloaded for personal use only. Unauthorized distribution is strictly prohibited.

* These authors are members of the WONDERFUL (WON and peripancreatic fluid collection) study group in Japan.