

Use of Endoscopy in Keratoprostheses with Biological Haptics

Endoskopieinsatz bei Keratoprothesen mit biologischer Haptik

Authors

Jonas Philipp Korbmacher ¹, Maria Borrelli, Gerd Geerling

Affiliation

Augenklinik, Universitätsklinikum Düsseldorf, Deutschland

Key words

corneal blindness, keratoprosthesis, osteo-odonto-keratoprosthesis, OOKP, endoscopy

Schlüsselwörter

Hornhautblindheit, Keratoprothese, Osteo-Odonto-Keratoprothese, OOKP, Endoskopie

received 24.6.2021
 accepted 25.2.2022
 published online 27.7.2022

Bibliography

Klin Monatsbl Augenheilkd 2023; 240: 1004–1009

DOI 10.1055/a-1807-2197

ISSN 0023-2165

© 2022. Thieme. All rights reserved.

Georg Thieme Verlag KG, Rüdigerstraße 14,
 70469 Stuttgart, Germany

Correspondence

Dr. Jonas Philipp Korbmacher
 Augenklinik, Universitätsklinikum Düsseldorf
 Moorenstraße 5, 40225 Düsseldorf, Deutschland
 Phone: + 49 (0) 21 18 11 73 22, Fax: + 49 (0) 21 18 11 95 61
 jonas.korbmacher@med.uni-duesseldorf.de

ABSTRACT

Introduction In severe ocular surface disease where penetrating keratoplasty cannot be successfully performed, implantation of a keratoprosthesis can achieve visual rehabilitation. Osteo-odonto-keratoprosthesis offers good tissue integration due to its biological haptics, resulting in a better survival rate and lower extrusion rate. Due to corneal opacity, which is often complete, assessing the potential visual acuity is challenging. Also, during implantation of a keratoprosthesis or during later intraocular revision surgery, there is a limited field of view of the peripheral retina or ciliary body region. This is due to the small size and central location of the prosthesis optics and the geometric conditions of the prosthetic haptics. These factors can complicate surgery.

Methods Endoscopic video assistance was used in 7 eyes of 6 different patients (6 male, 2 female, mean age 66 ± 9 years). In 3 eyes the indication was for preoperative estimation of potential visual acuity during a 23 G vitrectomy. In 2 eyes it was used during implantation surgery itself, and in 2 eyes it was used during revision surgery and vitrectomy. An endoscope with semirigid optics and an image guidance system with 3,000 pixels and 70° field of view from PolyDiagnost was used, with a 23 G trocar system.

Results Endoscopy was successfully applied in all eyes examined. In 1 of 3 eyes where endoscopy was performed to estimate the visual acuity potential, a keratoprosthesis was subsequently planned. In the other two eyes, the visual acuity potential was rated insufficient for future keratoprosthesis surgery. Detailed assessment of the retina and optic disc was limited to gross pathologies because of low image resolution. During implantation, it was possible to visualize correct positioning of the posterior haptic behind the host cornea. Retroprosthetic membranes could successfully be removed by endoscopy-assisted vitrectomy.

Conclusion Endoscopy assistance offers advantages in visualization both for determining the indication for KPro surgery, during implantation, and in the management of complications after implantation of a keratoprosthesis. Low resolution of the imaging system places limits on assessment capabilities. Although technical improvements and miniaturization may enhance its future capabilities, endoscopy in its current form is already a valuable addition in the context of keratoprosthesis surgery.

ZUSAMMENFASSUNG

Hintergrund Bei schwerster Erkrankung der Augenoberfläche, bei der eine perforierende Keratoplastik nicht erfolgreich ist, kann die Implantation einer Keratoprothese eine Visusrehabilitation erreichen. Die Osteo-Odonto-Keratoprothese bietet durch die biologische Haptik eine gute Gewebe-Integration und damit eine bessere Überlebensrate und geringere Extrusionsrate. Aufgrund der häufig vollständigen Hornhautintransparenz stellt die Abschätzung des Visuspotenzials präoperativ eine besondere Herausforderung dar. Auch während der Implantation einer Keratoprothese oder bei notwendigen intraokularen Revisionseingriffen besteht aufgrund der kleinen zentralen Prothesenoptik und der geometrischen Bedin-

gungen der Prothesenhaptik ein eingeschränkter Einblick auf die periphere Netzhaut bzw. die Ziliarkörperregion und kann den Eingriff erschweren.

Methoden An 7 Augen von 6 verschiedenen Patienten (6 männlich, 2 weiblich, mittleres Alter 66 ± 9 Jahre) wurde die endoskopische Videoassistenz eingesetzt. Dies erfolgte an 3 Augen zur Indikationsprüfung und Abschätzung des Visuspotenzials im Rahmen einer 23-G-Vitrektomie, an 2 Augen während der Implantation und an 2 Augen bei erforderlichen Revisionseingriffen ebenfalls im Rahmen einer Vitrektomie. Es wurde ein Endoskop mit semirigider Optik und einem Bildleitsystem mit 3000 Pixeln und 70° -Blickfeld der Firma PolyDiagnost und 23-G-Trokarsysteme verwendet.

Ergebnisse Die Endoskopie konnte bei allen untersuchten Augen erfolgreich eingesetzt werden. Nur bei 1 von 3 Augen, bei denen sie zur Abschätzung des Visuspotenzials durchgeführt wurde, erfolgte im Weiteren die Planung der Kerato-

prothese, während das Visuspotenzial befundbedingt bei 2 Augen als unzureichend bewertet wurde. Die Beurteilung von Makula und Papille war jedoch durch die Bildauflösung auf den Ausschluss grober Pathologien limitiert. Bei der Implantation konnte die korrekte Positionierung der posterioren Haptik hinter der Wirtshornhaut visualisiert werden. Mittels endoskopieassistierter Vitrektomie konnten retroprothetische Membranen erfolgreich entfernt werden.

Schlussfolgerung Die Endoskopieassistenz bietet Vorteile in der Visualisierung sowohl bei der Indikationsstellung, während der Implantation als auch beim Management von Komplikationen nach der Implantation einer Keratoprothese. Die Auflösung des Bildsystems erlaubte jedoch nur eine eingeschränkte Beurteilung. Auch wenn technische Weiterentwicklungen wünschenswert sind, stellt die Endoskopie im Kontext der Keratoprothesenchirurgie schon heute eine wertvolle Ergänzung dar.

Introduction

Osteo-odonto-keratoprosthesis (OOKP) was first described by Strampelli in 1963 [1], and has undergone only minor modifications since then [2–4]. A keratoprosthesis (KPro) with biological haptics is indicated in the most severe corneal diseases where there is complete limbal stem cell insufficiency, intrastromal neovascularization, previous unsuccessful keratoplasty, and an unstable epithelium, e.g., in the presence of absolute dry eye or underlying autoimmune disease. Due to the invasive nature of the procedure, only one eye is treated with KPro in cases of bilateral blindness or severe visual impairment (visual acuity usually $< 1/20$ on the Snellen chart) [5–9].

Before opting for this complex surgical procedure, it is important to assess the visual acuity potential of the affected eye. In general, a comorbid, severe retinal pathology or optic nerve atrophy can make it pointless to perform KPro implantation, a complex procedure carried out over several sessions. If there is complete corneal opacification, it can be difficult to exclude even major retinal pathologies. B-scan ultrasound, VEP, or testing of color vision or entopic phenomena (e.g., vein pattern) can only provide a rough and uncertain indication of visual acuity potential. During implantation, the positioning of the conical part of the cylinder, measuring 6.8 mm, through the small 3–4 mm trephination in the cornea can only be roughly estimated due to the fact that the prosthesis optics are only 3–3.5 mm in size. Postimplantation revision procedures, such as the removal of a retroprothetic membrane (RPM), are also complicated by the geometry of the prosthesis. Ultrasound assessment of the retinal periphery is also limited by the echo dense tooth–bone haptics.

Since the initial description by Thorpe in 1934, in which a rigid monocular endoscope was used to remove an intraocular foreign body [10], the use of fiberoptics, improved light sources, and video technology have led to the development of high-resolution, flexible, and very small video endoscopes. Today, these have a minimum diameter of 0.45 mm for use in the eye and periocular region, and can thus be inserted through a 23 G trocar, which is

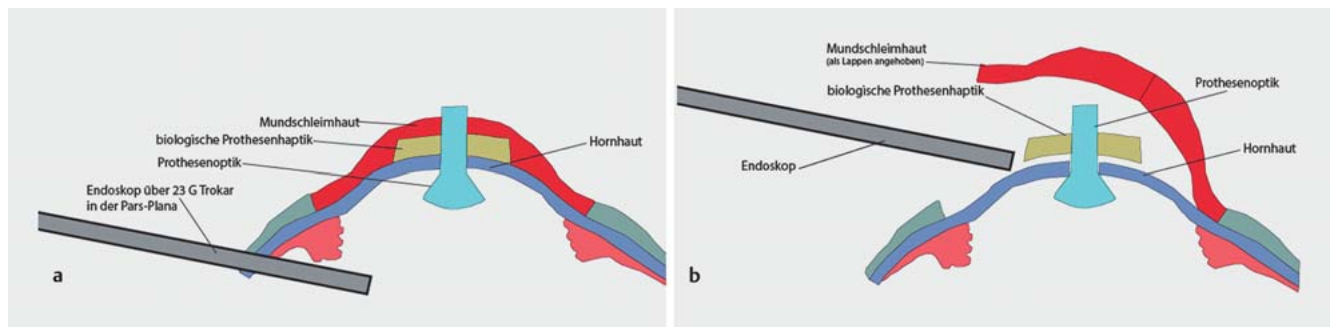
commercially available for vitrectomy. In this case series we analyzed the extent to which videoendoscopy imaging could be a useful adjunct in complex keratoprothetic surgery. In particular, we investigated whether endoscopy can be used for better preoperative assessment of the optic disc and retina (potential visual acuity) and to provide intraoperative guidance during implantation, and, if necessary, during later revision procedures.

Methods

Seven eyes from six patients (four men and two women) were examined from 2018 to 2020. The mean age was 66 ± 9 years. Endoscopy was performed either preoperatively for better assessment of the visual acuity prognosis, or after implantation of a keratoprosthesis with biological haptics and Hille optics (type 91 G, Morcher GmbH, Stuttgart, Germany).

A gas sterilizable endoscope with semirigid optics and a semirigid image guidance system with 3,000 pixels and a 70° field of view from PolyDiagnost (PD-DS-1086, PolyDiagnost GmbH, Hallbergmoos, Germany), with integrated fiberoptic illumination, was used in conjunction with a 21.5" monitor. The total diameter of the fiber was 0.45 mm. As part of a videoendoscopic fundus check to assess visual acuity potential, the endoscope was inserted into the eye via a 23 G trocar following core vitrectomy, and the optic disc and macula as well as the fundus were visualized as far as possible (► Fig. 1 a). For this purpose the surgeon used 23 G trocars (23 G Valved Entry System 1 CT, Alcon Deutschland GmbH, Freiburg im Breisgau, Germany) with a 0.5-mm-diameter lumen, which facilitated the uncomplicated insertion of the endoscope optics.

When endoscopy was performed in the context of KPro implantation [11], no trocar system was used, as these might have been disruptive during the procedure. After mobilization of the oral mucosa, trephination of the cornea and insertion of the conical optical component behind the cornea, the end of the fiber optic was guided into the gap between the cornea and the prosthesis to verify correct positioning of the KPro (► Fig. 1 b).



► **Fig. 1** **a** Diagram of the osteo-odonto-keratoprosthesis in situ and endoscopy via a 23 G trocar in the pars plana. **b** Immediately after implantation of the prosthesis, the correct positioning of the cylinder optics in the host cornea is checked. In this case, the oral mucosa and the haptics of the prosthesis obscure a direct top view of the corneal trephination opening through the surgical microscope. The endoscope can be used to make an assessment from a lateral viewpoint. Oral mucosa (red), biological haptics (yellow), cylinder optics with conical part nearest to the cornea (light blue), host cornea (dark blue), endoscope with light source (gray).

Following implantation of a keratoprosthesis, removal of an RPM was performed with a 23 G vitrectomy under visual control through the optical cylinder and via the videoendoscope in order to visualize the prosthesis optics from an intraocular perspective. To this end, the videoendoscope was inserted into the eye via a 23 G trocar (23 G Valved Entry System 1 CT, Alcon Deutschland GmbH, Freiburg im Breisgau, Germany). All procedures were performed by the same surgeon (GG).

Results

The underlying disease, intervention type, and outcomes of the six patients are summarized in ► **Table 1**. Videoendoscopy was performed in two patients (three eyes) to assess their visual acuity potential in order to confirm whether the KPro procedure was indicated. The first case was a 64-year-old man with bilateral complete limbal insufficiency having undergone multiple perforating keratoplasties following chemical burns from lime six years ago. Visual acuity was reduced to the perception of right and left hand movements. There was aphakia in the right eye and pseudophakia in the left eye. Despite a clinical suspicion of phthisis in the left eye, the patient was keen to proceed with keratoprosthesis. In accordance with the patient's wishes, funduscopy was performed by diagnostic endoscopy. In the right eye, the optic disc was pale and terminally excavated (► **Fig. 2**) and the macula showed extensive exudates. The left eye showed numerous traction folds and retinal hemorrhages under oil filling. Because of the oil filling and tractional retinal changes, the endoscopic evaluation was also uncertain. Neither the optic disc nor the macula could be visualized intraoperatively. Due to the low visual acuity potential, KPro implantation was not performed. The patient accepted this approach after a detailed explanation of the endoscopic findings.

Case 2 involved a 53-year-old man with second to third-degree chemical burns caused by drain cleaner 30 years ago. Owing to the severity of the burns and limbal insufficiency, bilateral oral mucosal transplantation had been carried out in a secondary care setting at another facility. Preoperatively, the oral mucosal layer was intact on the right side and clearly thinned on the left side with a completely keratinized cornea. Visual acuity was reduced

to perception of light in the right eye, with intact projection, and hand movements with color perception in the left eye; the patient was phakic in both eyes. The diagnostic vitrectomy and endoscopy performed on the right eye showed an optic disc with sharp margins, without conspicuous excavation, and regular macular and retinal findings; implantation of a KPro was therefore indicated. At the patient's request, implantation has not yet been performed.

In cases 3 and 4, endoscopy was used during implantation of a tibial keratoprosthesis (TKPro) and an OOKP, respectively. An 81-year-old woman had ocular mucous membrane pemphigoid with complete ankyloblepharon and visual acuity reduced to light perception on both sides. Correct positioning of the prosthesis, i.e., positioning of the conical optical element behind the host cornea, was confirmed intraoperatively by means of endoscopy. Case 4 involved a 62-year-old man with severe ocular graft-versus-host disease (GvHD) following stem cell transplantation due to mantle cell lymphoma, having previously undergone unsuccessful bilateral allogeneic limbal stem cell transplantation. Visual acuity was reduced to perception of right and left hand movements. Once again, the correct positioning of the prosthesis optics in the host cornea was confirmed by endoscopy (► **Fig. 3**). Postoperatively, case 4 showed a visual acuity of 1.0.

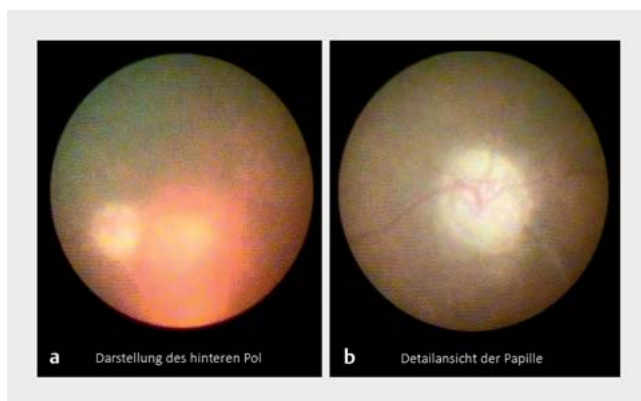
In cases 5 and 6, endoscopy was used as an adjunct to vitrectomy after implantation of an OOKP for the purpose of surgically removing a retroprosthetic membrane. The 77-year-old woman (case 5) had undergone OOKP three years earlier for bilateral blindness due to scarring mucous membrane pemphigoid with ocular involvement. Visual acuity before implantation was limited to light perception; this increased to 0.25 after implantation, and then decreased to counting fingers with the development of an RPM. Video endoscopy was used to check the fundus after removal of the membrane, and to check the prosthesis and the optical cylinder. This showed choroidal folds and an attached retina with known hypotony, an intact ciliary body, and the edge of the optical cylinder was intact and clearly visible (► **Fig. 4**). Postoperatively, the patient had a best-corrected visual acuity of 0.4.

Case 6 was a 67-year-old man (previous OOKP after bilateral burns) whose visual acuity increased from light perception to

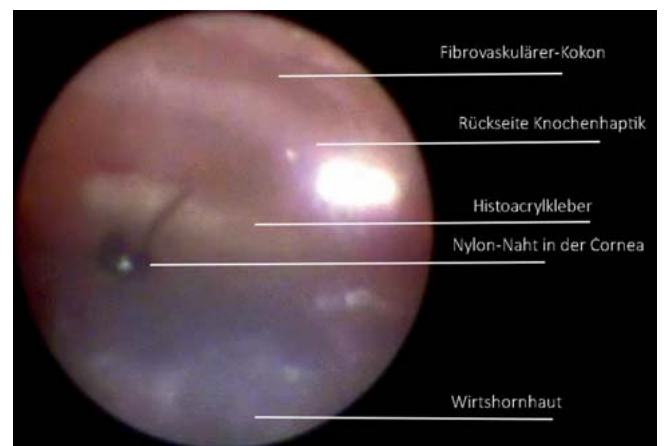► **Table 1** Scope of endoscopy, patient demographics and previous disease, outcome of endoscopy. Endoscopy was performed on seven eyes in six different patients. An endoscope with semirigid optics and a 3,000-pixel image guidance system with a 70° field of view from PolyDiagnost was used. Endoscopy was performed preoperatively in two patients to assess visual acuity potential before possible KPro implantation. Endoscopy was performed during implantation of a keratoprosthesis with biological haptics (osteo-odonto-keratoprosthesis, tibial keratoprosthesis) in two patients, and during a revision procedure for removal of a retroprosthetic membrane in two patients.

Case	Age/sex	Underlying disease	Visual acuity preOP (postOP)	Use of endoscopy	Result
1	64-year-old male	Bilateral limbal stem cell insufficiency, prior chemical burns	BL: HM (HM)	Both eyes: preoperative assessment of visual acuity potential	Bilaterally poor prognosis and no visual acuity potential, KPro implantation not planned
2	53-year-old male	Bilateral limbal stem cell insufficiency, prior chemical burns	LP (LP)	Right eye: preoperative assessment of visual acuity potential	Visual acuity potential identified, OOKP implantation planned
3	81-year-old female	Ocular mucous membrane pemphigoid	LP (LP)	Left eye: implantation	Successful implantation of a TKPro (poor dental status)
4	61-year-old male	Severe ocular GvHD after allogeneic stem cell transplantation	HM (1.0)	Left eye: implantation	Successful implantation of OOKP
5	74-year-old female	Previous OOKP in 2016 due to ocular mucous membrane pemphigoid	CF (0.4)	Left eye revision surgery: removal of an RPM	After removal of the membrane, endoscopic assessment showed: attached retina, intact ciliary body, and intact and clearly visible edge of cylinder optics
6	67-year-old male	Previous OOKP in 2015, prior chemical burns	HM (LP)	Left eye revision surgery: removal of an RPM	After removal of the membrane: endoscopic examination of the central fundus, visualization of the pale optic nerve

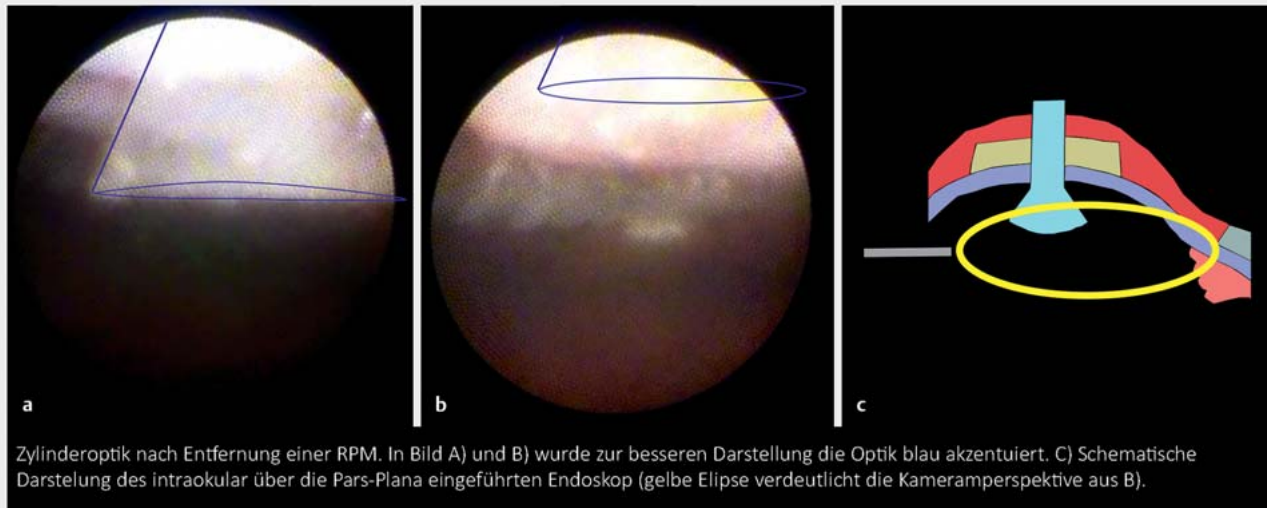
OOKP: osteo-odonto-keratoprosthesis; TKpro: tibial keratoprosthesis; RPM: retroprosthetic membrane; BL: bilateral; CF: counting fingers; HM: hand movements; LP: light perception; GvHD: Graft versus host disease



► **Fig. 2** Case 1: Illustration of the posterior pole (a) and detailed view of the optic disc (b) of a right eye. The optic disc appears pale and severely excavated. Microendoscopic assessment supported the clinical assessment of the eye's potential visual acuity. Due to the poor prognosis, OOKP implantation was not performed.



► **Fig. 3** Case 3: Illustration of correct prosthesis position during implantation of an OOKP. The endoscope was passed between the host cornea (appears blue in the lower half of the image) and the as yet unattached OOKP and surgically incised oral mucosa (see diagram in ► Fig. 1 b). The optical cylinder is not visible endoscopically, and is therefore completely and correctly embedded in the host cornea. Nylon sutures are visible in the foreground (black). (Labelled for clarity.)



► **Fig. 4** Case 5: Illustration of the optical cylinder after removal of a retroprosthetic membrane (RPM). Insertion of the endoscope via 23 G trocar in the pars plana and visualization of the optics from the intraocular perspective. **a** Optic cylinder in the foreground highlighted in blue, RPM successfully removed. **b** Optic cylinder in the upper edge of the image (highlighted in blue) and parts of the ciliary body visible in the background. **c** Diagram of endoscopy and camera perspective in image a and b.

0.05 after OOKP. After three years his visual acuity had progressively deteriorated on the Snellen chart, and removal of an RPM was attempted. In this patient, endoscopy enabled successful visualization of the central fundus with a pale optic disc and narrow vessels. Unfortunately, no functional improvement was achieved by removing the RPM.

Discussion

Optimum visualization is crucially important for the success of a surgical procedure. Despite technological advances in the viewing systems of modern surgical microscopes, including complementary technologies such as intraoperative OCT [12], certain structures remain inaccessible due to cloudy or opaque media, configuration, or anatomical location. In keratoprosthesis surgery, this is especially true in several respects.

When determining the indication prior to KPro implantation, severe corneal pathologies will prevent a clear view, thus preventing adequate fundoscopic assessment of visual acuity potential. During implantation of a prosthesis with biological haptics of a tooth/bone complex with oral mucosa coverage, the configuration of the prosthesis (with large haptics and small, centrally located prosthetic optics) prevents visualization of the correct positioning of the prosthetic optics in the host cornea. The consequences of incorrect positioning may include decentered optics or incomplete wound closure, and are potentially associated with significant functional and morphologic consequences, such as reduced visual acuity and retinal detachment. After successful implantation, the prosthetic optics restrict the intraocular view to the central 60–80° for any revision surgery that may be required.

Endoscopic assistance makes it possible to bypass opacities in the anterior segment during a diagnostic vitrectomy and make a

general assessment of the situation at the posterior pole. It also facilitates surgical procedures such as positioning of the prosthesis or removal of a retroprosthetic membrane. It is therefore superior to ultrasound in enabling an evaluation of the retinal morphology and in providing an impression of the retinal vessels, optic disc and macular status, thus enabling assessment of potential visual acuity. Accordingly, endoscopy can help to distinguish between situations where surgery is indicated and those where the prognosis is unfavorable.

In 2014, Farias et al. described the first use of videoendoscopy for preoperative assessment and assessment of potential visual acuity prior to keratoprosthesis surgery [13]. However, the endoscope used, an E4 Microprobe (Endo-Optiks, NJ USA), required a 20 G sclerotomy. After diagnostic endoscopy, only 3 out of 10 eyes were deemed suitable for KPro surgery. In all three cases, implantation of a Boston keratoprosthesis resulted in a significant improvement in visual acuity (from counting fingers to 0.1, from hand movements to 0.4, and from light perception to 0.25). Moreover, Pappuru et al. report on the use of diagnostic endoscopy in eyes with advanced corneal opacification [14]. In 62 out of 64 eyes examined endoscopically, diagnostic endoscopy was found to be helpful in planning the definitive treatment. Endoscopy enabled the identification of glaucomatous papillary excavation in 10 cases and glaucomatous optic nerve atrophy in 7 eyes. In eyes with known retinal detachment identified by ultrasound, for example, endoscopy was able to detect a severe PVR reaction (PVR: proliferative vitreoretinopathy) in 11 cases. Endoscopic evaluation made it possible to determine a poor visual prognosis and avoid complex surgery in almost half of the eyes (30/64 eyes; 46.8%). This makes endoscopy an important adjunct to the preoperative decision-making algorithm, especially prior to

complex KPro surgery and in cases where visual acuity potential is questionable.

The use of diagnostic endoscopy during implantation of a KPro with biological haptics or in the context of removing a retroprosthetic membrane has not previously been described. During implantation, the conical part of the posterior cylinder must be correctly positioned behind the cornea. In this case, the oral mucosa and the haptics of the prosthesis obscure a direct top view of the trephination opening through the surgical microscope. Lateral visualization via an endoscope (► **Fig. 3**) ensured correct positioning during the operation. In future, it is conceivable that further intraocular visualization could be achieved using trocars inserted at the beginning of the procedure, when the eye is still well toned.

According to Liu et al., retroprosthetic membranes are observed in 16.7% of eyes following implantation of prostheses with biological haptics. They are not always relevant to visual acuity and can in some cases be treated by Nd:YAG laser [15]. Very coarse and/or vascularized RPMs require surgical membranectomy. During this procedure, the surgeon's field of view is severely restricted by the diameter of the KPro's optical cylinder. Again, endoscopic visualization proved helpful in our experience. Using the 23 G trocars, it was possible to visualize the cylinder optics endoscopically and thus check from an interocular perspective that the RPM had been successfully removed (► **Fig. 4**).

As with all technical assistance systems, a number of shortcomings still need to be addressed. Endoscopy currently only provides low resolution images in two dimensions (2D) without stereopsis. Handling the semirigid optics and the dissociation between the surgeon's hand movement and the intraoperative view requires some practice. The side view obtained with the endoscope also provides an unusual perspective compared to the otherwise familiar bird's-eye view through the microscope. Last but not least, the cost of such a system must also be considered. However, with diagnostic and therapeutic lacrimal duct endoscopy [16] and endoscopically controlled cyclophotocoagulation [17], there are also other useful indications for this technology in ophthalmic surgery. Intraocular endoscopy is an exciting technique that is still evolving. Technical improvements (3D, higher resolution) and miniaturization are anticipated in the future. In its current form, intraocular endoscopy is already a valuable adjunct in complex surgical procedures, such as keratoprosthesis surgery.

Conflict of Interest

The authors declare that they have no conflict of interest.

References

- [1] Strampelli B. Osteo-odontokeratoprosthesis. *Ann Di Ottalmologia E Clin Ocul* 1963; 89: 1039–1044
- [2] Falcinelli G, Falsini B, Taloni M et al. Modified Osteo-odonto-keratoprosthesis for Treatment of Corneal Blindness: Long-term Anatomical and Functional Outcomes in 181 Cases. *Arch Ophthalmol* 2005; 123: 1319–1329. doi:10.1001/archophth.123.10.1319
- [3] Temprano J. Keratoprosthesis with tibial autograft. *Refract Corneal Surg* 1993; 9: 192–193
- [4] Hille K, Landau H, Ruprecht KW. Improvement of the Osteo-odonto-keratoprosthesis according to Strampelli: influence of diameter of PMMA cylinder on visual field. *Graefes Arch Clin Exp Ophthalmol* 1999; 237: 308–312. doi:10.1007/s004170050238
- [5] Geerling G, Liu CSC, Dart JKG et al. Sight and comfort: complex procedures in end-stage Stevens-Johnson syndrome. *Eye (Lond)* 2003; 17: 89–91. doi:10.1038/sj.eye.6700264
- [6] Schmidt E, Benoit S, Kampik D et al. Tibial bone keratoprosthesis: reversing blindness in mucous membrane pemphigoid. *J Dtsch Dermatol Ges* 2017; 15: 1024–1026. doi:10.1111/ddg.13317
- [7] Frings A, Schrader S, Hille K et al. Gesundheitsbezogene Lebensqualität nach Implantation einer Keratoprothese mit biologischer Haptik. *Ophthalmologie* 2018; 115: 34–39. doi:10.1007/s00347-017-0576-x
- [8] Geerling G, Liu CSC, Collin JRO et al. Costs and gains of complex procedures to rehabilitate end stage ocular surface disease. *Br J Ophthalmol* 2002; 86: 1220–1221. doi:10.1136/bjo.86.11.1220
- [9] Geerling G, Hille K. Zum Stand der Keratoprothesen mit biologischer Haptik – Die Düsseldorf-Offenburger-Erfahrungen mit Osteo-Odonto- und Tibia-Keratoprothese. *Klin Monbl Augenheilkd* 2017; 234: 763–769. doi:10.1055/s-0043-111086
- [10] Thorpe EH. Ocular endoscope: instrument for removal of intravitreal non magnetic foreign bodies. *Trans Am Acad Ophthalmol Otolaryngol* 1934; 39: 422–424
- [11] Hille K, Grabner G, Liu C et al. Standards for Modified Osteo-odontokeratoprosthesis (OOKP) Surgery According to Strampelli and Falcinelli. *Cornea* 2005; 24: 895–908. doi:10.1097/01.icc.0000157401.81408.62
- [12] Juergens L, Michiels S, Borrelli M et al. Das intraoperative OCT – eine Real-World-basierte Nutzerevaluation im operativen Alltag. *Klin Monbl Augenheilkd* 2021; 238: 693–699. doi:10.1055/a-1389-5815
- [13] Farias CC, Ozturk HE, Albini TA et al. Use of intraocular videoendoscopic examination in the preoperative evaluation of keratoprosthesis surgery to assess visual potential. *Am J Ophthalmol* 2014; 158: 80–86.e2. doi:10.1016/j.ajo.2014.02.043
- [14] Pappuru RRR, Tyagi M, Paulose RM et al. Role of Diagnostic Endoscopy in Posterior Segment Evaluation for Definitive Prognostication in Eyes With Corneal Opacification. *Am J Ophthalmol* 2017; 176: 9–14. doi:10.1016/j.ajo.2016.12.018
- [15] Liu C, Okera S, Tandon R et al. Visual rehabilitation in end-stage inflammatory ocular surface disease with the osteo-odonto-keratoprosthesis: results from the UK. *Br J Ophthalmol* 2008; 92: 1211–1217. doi:10.1136/bjo.2007.130567
- [16] Emmerich K-H, Amin S, Meyer-Rüsenberg H-W et al. Mikroendoskopische, minimalinvasive Techniken in der Tränenwegschirurgie. *Ophthalmologie* 2017; 114: 409–415. doi:10.1007/s00347-017-0481-3
- [17] Cohen A, Wong SH, Patel S et al. Endoscopic cyclophotocoagulation for the treatment of glaucoma. *Surv Ophthalmol* 2017; 62: 357–365. doi:10.1016/j.survophthal.2016.09.004