

Endoscopic submucosal dissection for superficial gastrointestinal lesions: European Society of Gastrointestinal Endoscopy (ESGE) Guideline – Update 2022



Authors

Pedro Pimentel-Nunes^{1,2,*}, Diogo Libânio^{1,3,*}, Barbara A. J. Bastiaansen⁴, Pradeep Bhandari⁵, Raf Bisschops⁶, Michael J. Bourke⁷, Gianluca Esposito⁸, Arnaud Lemmers⁹, Roberta Maselli^{10,11}, Helmut Messmann¹², Oliver Pech¹³, Mathieu Pioche¹⁴, Michael Vieth¹⁵, Bas L. A. M. Weusten¹⁶, Jeanin E. van Hooft¹⁷, Pierre H. Deprez¹⁸, Mario Dinis-Ribeiro^{1,3}

Institutions

- 1 Department of Gastroenterology, Porto Comprehensive Cancer Center, and RISE@CI-IPOP (Health Research Network), Porto, Portugal
- 2 Department of Surgery and Physiology, Porto Faculty of Medicine, Portugal
- 3 MEDCIDS, Faculty of Medicine, University of Porto, Porto, Portugal
- 4 Department of Gastroenterology and Hepatology, Amsterdam Gastroenterology & Metabolism, Amsterdam University Medical Center, The Netherlands
- 5 Department of Gastroenterology, Queen Alexandra Hospital, Portsmouth, UK
- 6 Department of Gastroenterology and Hepatology, University Hospitals Leuven, TARGID, Leuven, Belgium
- 7 Department of Gastroenterology, Westmead Hospital, Sydney, Australia and Western Clinical School, University of Sydney, Sydney, Australia
- 8 Department of Medical-Surgical Sciences and Translational Medicine, Sant' Andrea Hospital, Sapienza University of Rome, Italy
- 9 Department of Gastroenterology, Hepatopancreatology and Digestive Oncology, CUB Erasme Hospital, Université Libre de Bruxelles, Brussels, Belgium.
- 10 Department of Biomedical Sciences, Humanitas University, Pieve Emanuele, Milan, Italy
- 11 IRCCS Humanitas Research Hospital, Rozzano, Milan, Italy
- 12 Department of Gastroenterology, Universitätsklinikum Augsburg, Augsburg, Bayern, Germany
- 13 Department of Gastroenterology and Interventional Endoscopy, St. John of God Hospital, Regensburg, Germany
- 14 Endoscopy and Gastroenterology Unit, Edouard Herriot Hospital, Hospices Civils de Lyon, Lyon, France
- 15 Institute of Pathology, Friedrich-Alexander University Erlangen-Nuremberg, Klinikum Bayreuth, Bayreuth, Germany
- 16 Department of Gastroenterology and Hepatology, St. Antonius Hospital Nieuwegein and University Medical Center Utrecht, Utrecht University, The Netherlands.
- 17 Department of Gastroenterology and Hepatology, Leiden University Medical Center, Leiden, The Netherlands
- 18 Department of Hepatogastroenterology, Cliniques Universitaires Saint-Luc, Université Catholique de Louvain, Brussels, Belgium

published online 6.5.2022

Bibliography

Endoscopy 2022; 54: 591–622

DOI 10.1055/a-1811-7025

ISSN 0013-726X

© 2022. European Society of Gastrointestinal Endoscopy

All rights reserved.

This article is published by Thieme.

Georg Thieme Verlag KG, Rüdigerstraße 14,

70469 Stuttgart, Germany

 Supplementary material

Supplementary material is available under

<https://doi.org/10.1055/a-1811-7025>

* Joint first authors

Corresponding author

Pedro Pimentel-Nunes, MD PhD, Gastroenterology Department, Instituto Português de Oncologia, Rua Dr. Bernardino de Almeida, 4200-072 Porto, Portugal
pedronunesml@gmail.com

MAIN RECOMMENDATIONS

ESGE recommends that the evaluation of superficial gastrointestinal (GI) lesions should be made by an experienced endoscopist, using high definition white-light and chromoendoscopy (virtual or dye-based).

ESGE does not recommend routine performance of endoscopic ultrasonography (EUS), computed tomography (CT), magnetic resonance imaging (MRI), or positron emission tomography (PET)-CT prior to endoscopic resection.

ESGE recommends endoscopic submucosal dissection (ESD) as the treatment of choice for most superficial esophageal squamous cell and superficial gastric lesions.

For Barrett's esophagus (BE)-associated lesions, ESGE suggests the use of ESD for lesions suspicious of submucosal invasion (Paris type 0-Is, 0-IIc), for malignant lesions >20 mm, and for lesions in scarred/fibrotic areas.

ESGE does not recommend routine use of ESD for duodenal or small-bowel lesions.

ESGE suggests that ESD should be considered for en bloc resection of colorectal (but particularly rectal) lesions with suspicion of limited submucosal invasion (demarcated depressed area with irregular surface pattern or a large protruding or bulky component, particularly if the lesions are larger than 20 mm) or for lesions that otherwise cannot be completely removed by snare-based techniques.

ESGE recommends that an en bloc R0 resection of a superficial GI lesion with histology no more advanced than intramucosal cancer (no more than m2 in esophageal squamous cell carcinoma), well to moderately differentiated, with no

lymphovascular invasion or ulceration, should be considered a very low risk (curative) resection, and no further staging procedure or treatment is generally recommended.

ESGE recommends that the following should be considered to be a low risk (curative) resection and no further treatment is generally recommended: an en bloc R0 resection of a superficial GI lesion with superficial submucosal invasion (sm1), that is well to moderately differentiated, with no lymphovascular invasion, of size ≤ 20 mm for an esophageal squamous cell carcinoma or ≤ 30 mm for a stomach lesion or of any size for a BE-related or colorectal lesion, and with no lymphovascular invasion, and no budding grade 2 or 3 for colorectal lesions.

ESGE recommends that, after an endoscopically complete resection, if there is a positive horizontal margin or if resection is piecemeal, but there is no submucosal invasion and no other high risk criteria are met, this should be considered a local-risk resection and endoscopic surveillance or re-treatment is recommended rather than surgery or other additional treatment.

ESGE recommends that when there is a diagnosis of lymphovascular invasion, or deeper infiltration than sm1, or positive vertical margins, or undifferentiated tumor, or, for colorectal lesions, budding grade 2 or 3, this should be considered a high risk (noncurative) resection, and complete staging and strong consideration for additional treatments should be considered on an individual basis in a multidisciplinary discussion.

ESGE recommends scheduled endoscopic surveillance with high definition white-light and chromoendoscopy (virtual or dye-based) with biopsies of only the suspicious areas after a curative ESD.

SOURCE AND SCOPE

This Guideline is an official statement of the European Society of Gastrointestinal Endoscopy (ESGE). It is an update of the previous 2015 Guideline addressing the role of endoscopic submucosal dissection (ESD) for superficial gastrointestinal lesions.

1 Introduction

This Guideline represents an update of the Guideline on the role of endoscopic submucosal dissection (ESD) for superficial gastrointestinal (GI) lesions, published by the European Society of Gastrointestinal Endoscopy (ESGE) in 2015 [1].

This evidence-based Guideline was commissioned by ESGE. It addresses major issues concerning ESD, that is, evaluation before ESD, comparison with other therapeutic strategies, namely endoscopic mucosal resection (EMR) and surgery, and management after ESD, to inform and underpin the use of this fundamental technique for the treatment of superficial GI lesions.

ABBREVIATIONS

AE	adverse event
BE	Barrett's esophagus
BLI	blue-light imaging
CE	chromoendoscopy
CI	confidence interval
CRC	colorectal cancer
CRD	complete remission of dysplasia
CRIM	complete remission of intestinal metaplasia
CRT	chemoradiotherapy
CT	computed tomography
DSS	disease-specific survival
EAC	esophageal adenocarcinoma
EGC	early gastric cancer
EMR	endoscopic mucosal resection
ER	endoscopic resection
ESD	endoscopic submucosal dissection
ESGE	European Society of Gastrointestinal Endoscopy
EUS	endoscopic ultrasonography
GI	gastrointestinal
GRADE	Grading of Recommendations Assessment, Development and Evaluation
HGD	high grade dysplasia
HM	horizontal margin
JES	Japan Esophageal Society
JNET	Japan NBI Expert Team
JGES	Japan Gastroenterological Endoscopy Society
LCE	Lugol chromoendoscopy
LNM	lymph node metastasis
LST	laterally spreading tumor
ME	magnification endoscopy
MRI	magnetic resonance imaging
NBI	narrow-band imaging
NICE	NBI International Colorectal Endoscopic [classification]
NPV	negative predictive value
OR	odds ratio
OS	overall survival
OTS	over-the-scope
P-CAB	potassium-competitive acid-blocker
PEECS	post-ESD electrocoagulation syndrome
PET	positron emission tomography
PICO	patients, interventions, controls, outcomes
PPI	proton pump inhibitors
PPV	positive predictive value
RFA	radiofrequency ablation
SCC	squamous cell carcinoma
USD	United States dollar
VM	vertical margin
TEM	transanal endoscopic microsurgery
WLE	white-light endoscopy

This Guideline does not address the skills and knowledge that the endoscopist should have to perform ESD, or the specific

management of antithrombotic or other medications in the periprocedural setting, or quality measurements, as these are addressed in separate guidelines [2, 3]. A companion Technical Review will be published separately, that will cover prevention strategies regarding ESD complications and detailed technical issues.

2 Methods

ESGE commissioned this Guideline and appointed a guideline leader (P.P.N.) who invited the listed authors to participate in its development. The key PICO (patients, interventions, controls, outcomes) questions were prepared by the coordinating team (P.P.N., J.v.H., M.D.R.) and then approved by the other members. The coordinating team formed organ-based task force subgroups, each with its own leader, and divided the key topics (pretreatment evaluation, treatment, management after treatment) among these task forces (see **Appendix 1 s**, available online-only in Supplementary Material).

Each task force performed a systematic literature search to prepare evidence-based and well-balanced statements on their assigned key questions, with a focus on articles published from January 2015 until January 2021, after the literature review of the previous ESD guideline. Searches were performed in PubMed. Articles were first selected by title; their relevance was then confirmed by review of the corresponding manuscripts, and articles with content that was considered irrelevant were excluded. All selected important articles were individually assessed and graded by the level of evidence and strength of recommendation, according to the GRADE system [4, 5].

Each task force proposed statements on their assigned key questions which were discussed and voted on at a virtual meeting in February 2021. In August 2021, new relevant articles published up till that date were considered and reviewed, and a draft prepared by the leaders and coordinating team was sent to all group members. Statements were only approved when the consensus was greater than 80%. ► **Table 1** gives a complete list of statements.

The manuscript was also reviewed by two members of the ESGE Governing Board and sent for further comments to the national societies and individual members. After agreement on a final version, the manuscript was submitted to the journal *Endoscopy* for publication. All authors agreed on the final revised manuscript.

Evidence tables created from the literature review are presented in the Supplementary Material of this Guideline (**Table 1 s**, Esophageal squamous cell carcinoma (SCC); **Table 2 s**, Barrett's esophagus (BE); **Table 3 s**, Stomach; **Table 4 s**, Duodenum; **Table 5 s**, Colorectum).

Organ-specific decision algorithms are presented in ► **Figs. 1–4**.

This Guideline was issued in 2022 and will be considered for review and update in 2027 or sooner if new and relevant evidence becomes available. Any updates to the Guideline in the interim will be noted on the ESGE website: <http://www.esge.com/esge-guidelines.html>.

► **Table 1** Endoscopic submucosal dissection (ESD) for superficial gastrointestinal lesions: European Society of Gastrointestinal Endoscopy (ESGE) Guideline – Update 2022. Complete list of statements.

Pretreatment evaluation

1 ESGE recommends that the evaluation of superficial gastrointestinal lesions should be made by an experienced endoscopist, using high definition white-light and chromoendoscopy (virtual or dye-based), and validated classifications when available.
Strong recommendation, high quality evidence.

2 ESGE does not recommend routine performance of endoscopic ultrasonography (EUS), computed tomography (CT), magnetic resonance imaging (MRI), or positron emission tomography CT (PET-CT) prior to endoscopic resection (ER).
Strong recommendation, moderate quality evidence.

3 ESGE suggests that when suspicious features for deep submucosal invasion are present, complete staging should be considered in order to exclude stage T2/T3 or lymph node metastasis (LNM).
Weak recommendation, low quality evidence.

Therapeutic options

4 ESGE recommends ESD as the treatment of choice for most esophageal squamous cell and gastric (or junctional non-Barrett's) superficial lesions, mainly to provide an en bloc potentially curative resection with accurate pathologic staging.
Strong recommendation, moderate quality evidence.

5 ESGE suggests that ESD might also be considered for en bloc resection of noncircumferential clinically staged T1a-m3/T1b-sm1 or circumferential clinically staged T1a-m1/m2 esophageal squamous cell carcinoma (SCC)
Weak recommendation, moderate quality evidence.

6 For Barrett's esophagus (BE)-associated lesions, ESGE recommends to use endoscopic mucosal resection (EMR) for ≤ 20 mm visible lesions with low probability of submucosal invasion (Paris type 0-Ia, 0-IIb) and for larger or multifocal benign (dysplastic) lesions.
Strong recommendation, high quality evidence.

7 For BE-associated lesions, ESGE suggests to use ESD for lesions suspicious for submucosal invasion (Paris type 0-Is, 0-IIc), for malignant lesions > 20 mm, and for lesions in scarred/fibrotic areas.
Weak recommendation, low quality evidence.

8 ESGE recommends ESD for differentiated gastric lesions clinically staged as dysplastic or as intramucosal carcinomas (of any size if not ulcerated and ≤ 30 mm if ulcerated), with EMR being an alternative for Paris 0-IIa lesions of size ≤ 10 mm with low likelihood of malignancy.
Strong recommendation, moderate quality evidence.

9 ESGE suggests that gastric adenocarcinomas that are ≤ 30 mm, superficial, submucosal (sm1), and well-differentiated, or ≤ 20 mm, intramucosal, and poorly differentiated type, both without ulcerative findings, can be considered for ESD, although the decision should be individualized.
Weak recommendation, low quality evidence.

10 ESGE does not recommend routine use of ESD for duodenal or small-bowel lesions, with its use being reserved for selected cases in expert centers.
Strong recommendation, moderate quality evidence.

11 ESGE recommends polypectomy and/or EMR (en bloc or piecemeal) as the treatment of choice for most duodenal and small-bowel superficial lesions.
Strong recommendation, moderate quality evidence.

12 ESGE recommends polypectomy and/or EMR (en bloc or piecemeal) as the treatment of choice for most superficial colorectal lesions.
Strong recommendation, high quality evidence.

13 ESGE suggests that ESD should be considered for en bloc resection of colorectal (but particularly rectal) lesions with suspicion of limited submucosal invasion (demarcated depressed area with irregular surface pattern or a large protruding or bulky component, particularly if the lesions are larger than 20 mm), or for lesions that otherwise cannot be completely removed by snare-based techniques.
Weak recommendation, moderate quality evidence.

Management after ER

Esophageal SCCs

14 ESGE recommends that an en bloc R0 resection of a superficial esophageal squamous cell lesion with histology no more advanced than intramucosal m2 cancer, well to moderately differentiated, with no lymphovascular invasion, should be considered a very low risk (curative) resection and no further staging procedure or treatment is recommended.
Strong recommendation, moderate quality evidence.

15 ESGE suggests that an en bloc R0 resection of an esophageal m3 or sm1 SCC that is well to moderately differentiated and with no lymphovascular invasion, should be considered a low risk (curative) resection and no further treatment is generally recommended.
Weak recommendation, moderate quality evidence.
However, in these cases, particularly if the lesion is bigger than 20 mm, there is a real (albeit low) risk of lymph node metastasis (LNM) and complete staging is recommended with the risk from further therapy being balanced against the risk of LNM, in a multidisciplinary discussion.
Weak recommendation, low quality evidence.

16 ESGE suggests that complementary radiotherapy or chemoradiotherapy (CRT) may be considered in a multidisciplinary discussion after a curative resection of esophageal m3/sm1 SCC (particularly if > 20 mm in size).
Weak recommendation, moderate quality evidence.

BE-associated lesions

17 ESGE recommends that an en bloc R0 resection of a BE-associated superficial lesion with histology no more advanced than intramucosal cancer, well to moderately differentiated, with no lymphovascular invasion, should be considered a very low risk (curative) resection and no further staging procedure is generally recommended.
Strong recommendation, moderate quality evidence.

18 ESGE suggests that an en bloc R0 resection of a BE-associated superficial lesion with superficial submucosal invasion (sm1), and that is well to moderately differentiated, and with no lymphovascular invasion, should be considered a low risk (curative) resection and no further treatment (except for ablation of BE tissue) is generally recommended.
Weak recommendation, moderate quality evidence.
However, in these cases, there is a real (albeit low) risk of LNM, and complete staging is recommended with the risk from further therapy (surgery) being balanced against the risk of LNM, in a multidisciplinary discussion.
Weak recommendation, low quality evidence.

19 ESGE recommends ablation of all of the Barrett's mucosa after a curative or local-risk resection.
Strong recommendation, high quality evidence.

Gastric lesions

20 ESGE recommends that an en bloc R0 resection of a superficial gastric lesion with histology no more advanced than intramucosal cancer, well to moderately differentiated, with no lymphovascular invasion, should be considered a very low risk (curative) resection, independently of size if without ulceration or of lesions ≤ 30 mm if ulcerated, and no further staging procedure or treatment is generally recommended.
Strong recommendation, moderate quality evidence.

21 ESGE suggests that an en bloc R0 resection of a ≤ 30 mm gastric adenocarcinoma, with superficial submucosal invasion (sm1), that is well to moderately differentiated and with no lymphovascular invasion and no ulcer, should be considered a low risk (curative) resection and no further treatment is generally recommended.
Weak recommendation, moderate quality evidence.
However, in these cases there is a real (albeit low) risk of LNM and complete staging is recommended with the risk from further therapy (surgery) being balanced against the risk of LNM, in a multidisciplinary discussion.
Weak recommendation, moderate quality evidence.

22 ESGE suggests that an en bloc R0 resection of a ≤ 20 mm gastric intramucosal poorly differentiated carcinoma, with no lymphovascular invasion or ulcer, should be considered a low risk (curative) resection and no further treatment is generally recommended.
Weak recommendation, moderate quality evidence.
However, in these cases there is a real (albeit low) risk of LNM and complete staging is recommended with the risk from further therapy (surgery) being balanced against the risk of LNM, in a multidisciplinary discussion.
Weak recommendation, moderate quality evidence.

23 ESGE recommends that a resection of a > 30 mm gastric adenocarcinoma with superficial submucosal invasion (sm1) or with ulceration should be considered a high risk (noncurative) resection and complete staging should be done and strong consideration for additional treatments (surgery) should be given on an individual basis in a multidisciplinary discussion.
Strong recommendation, moderate quality evidence.

Duodenal/small-bowel lesions

24 ESGE suggests that, given the lack of evidence, the same post-resection criteria as in the colon should apply to the management of duodenal and small-bowel lesions, on an individual basis and with a multidisciplinary approach.
Weak recommendation, very low quality evidence.

Colorectal lesions

25 ESGE recommends that an en bloc R0 resection of a colorectal lesion with histology no more advanced than intramucosal adenocarcinoma, well to moderately differentiated, with no lymphovascular invasion, should be considered a very low risk (curative) resection and no further staging procedure or treatment is generally recommended.
Strong recommendation, high quality evidence.

26 ESGE recommends that an en bloc R0 resection of a colorectal lesion with superficial submucosal invasion (sm1), that is well to moderately differentiated and with no lymphovascular invasion and no grade 2 or 3 budding, should be considered a low risk (curative) resection, and no further treatment is generally recommended.
Strong recommendation, high quality evidence.

27 ESGE suggests that after an en bloc R0 resection of a rectal lesion meeting the single high risk criterion of submucosal invasion deeper than sm1 (well to moderately differentiated with no lymphovascular invasion and no grade 2 or 3 budding), CRT and/or surveillance might be preferred over surgery on an individual basis in a multidisciplinary approach.
Weak recommendation, very low quality evidence.

All organs

28 ESGE recommends that after an endoscopic complete resection, if there is a positive horizontal margin or if resection is piecemeal, but there is no submucosal invasion and no other high risk criteria are met, this should be considered a local-risk resection and endoscopic surveillance/re-treatment is recommended rather than surgery or other additional treatment.
Strong recommendation, moderate quality evidence.

29 ESGE recommends that when there is a diagnosis of lymphovascular invasion or deeper infiltration than sm1 or positive vertical margins or undifferentiated tumor or, for colorectal lesions, grade 2 or 3 budding, that the resection should be considered a high risk (noncurative) resection; complete staging should be done and strong consideration for additional treatments (chemoradiotherapy and/or surgery) should be given, on an individual basis in a multidisciplinary discussion.
Strong recommendation, moderate quality evidence.

Surveillance after endoscopic resection

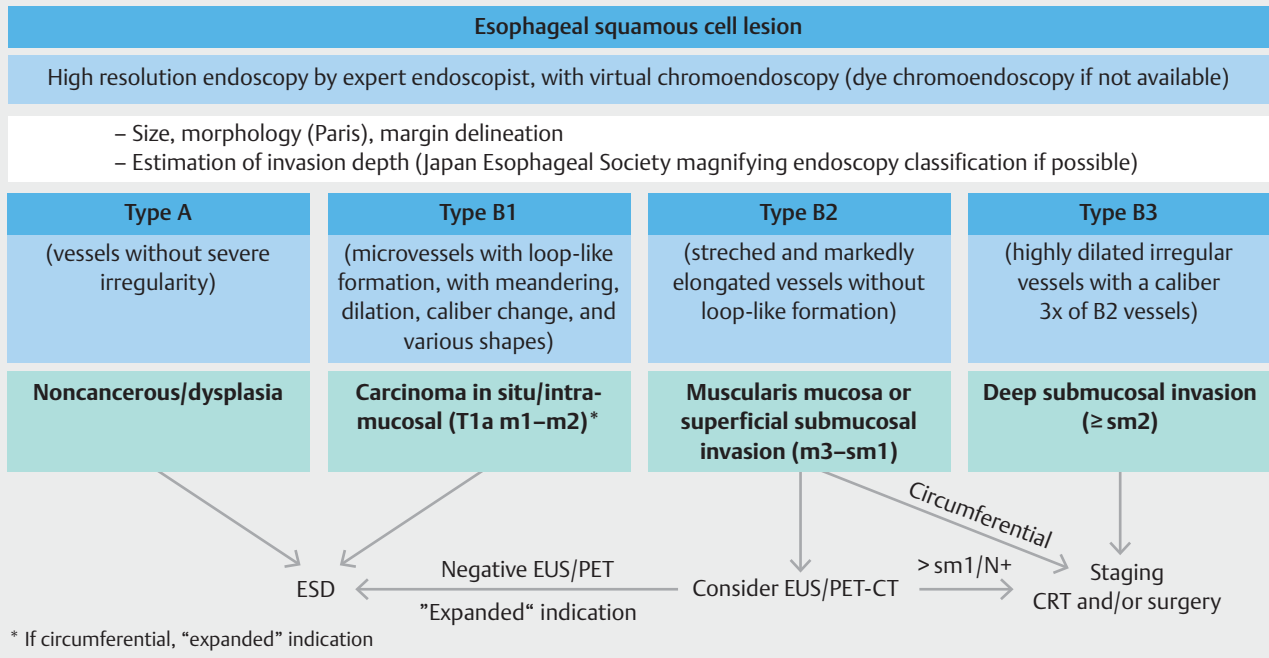
30 ESGE recommends scheduled endoscopic surveillance with high definition white-light and chromoendoscopy (virtual or dye-based) with biopsies of only the suspicious areas after a curative ESD.
Strong recommendation, moderate quality evidence.

31 ESGE recommends that after piecemeal resection or in the presence of positive lateral margins when criteria for additional treatment are not met, a high definition chromoendoscopy (virtual and/or dye-based) with biopsies is recommended at 3–6 months.
Weak recommendation, low quality evidence.

32 For upper GI superficial lesions, ESGE suggests endoscopy at 3–6 months and then annually after a curative ESD resection or after a local-risk ESD resection without recurrence.
Weak recommendation, low quality evidence.

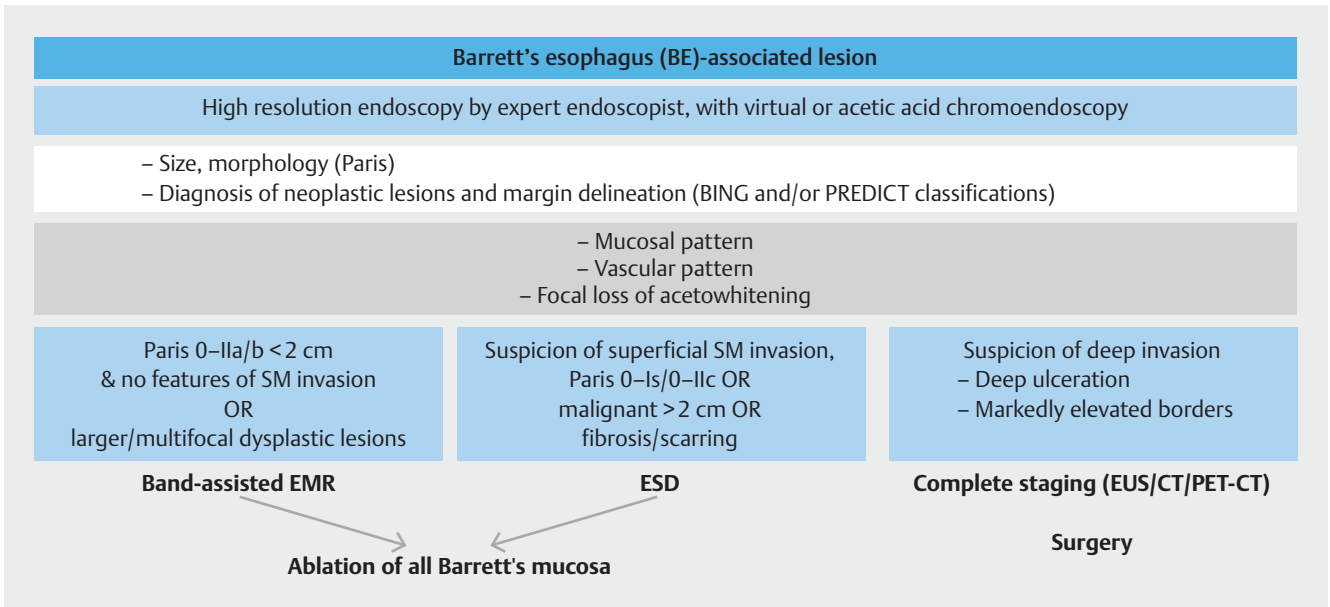
33 ESGE suggests colonoscopy at 12 months and then further surveillance in accordance with polypectomy and colorectal cancer guidelines, after a local-risk ESD resection without recurrence or after a low or very low risk (curative) ESD of a colorectal malignant lesion.
Weak recommendation, low quality evidence.

34 ESGE does not suggest routine use of EUS, MRI, CT, or PET in the follow-up after a very low or low risk (curative) endoscopic resection, but this might be considered in the cases of T1a-m3/T1b-sm1 esophageal SCC particularly if no additional treatment has been decided.
Weak recommendation, low quality evidence.

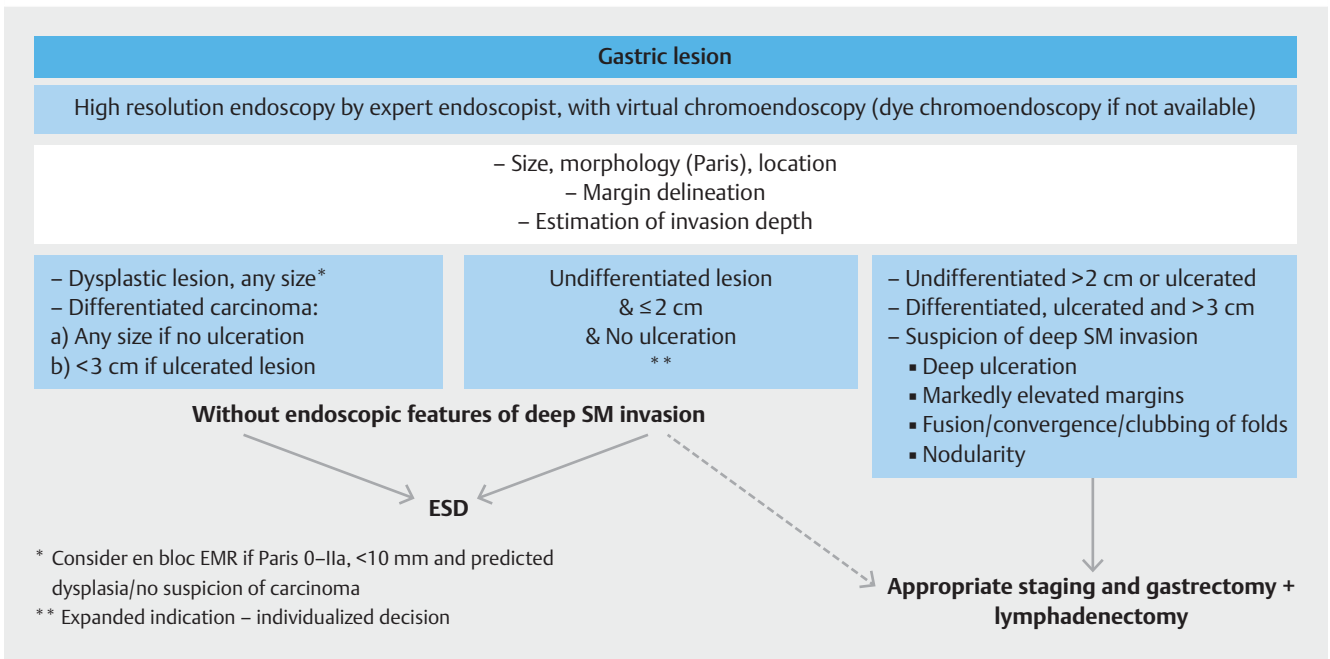


▶ Fig. 1 Endoscopic submucosal dissection (ESD) for superficial esophageal squamous cell cancers (SCCs): a decision algorithm. CRT, chemoradiotherapy, CT, computed tomography; EUS, endoscopic ultrasonography; PET, positron emission tomography.

This document was downloaded for personal use only. Unauthorized distribution is strictly prohibited.



► **Fig. 2** Endoscopic submucosal dissection (ESD) for Barrett's esophagus (BE)-related lesions: a decision algorithm. BING, Barrett's International NBI Group; CT, computed tomography; EMR, endoscopic mucosal resection; EUS, endoscopic ultrasonography; PET, positron emission tomography; PREDICT, Portsmouth acetic acid classification; SM, submucosal.



► **Fig. 3** Endoscopic submucosal dissection (ESD) for superficial gastric lesions: a decision algorithm. SM, submucosal.

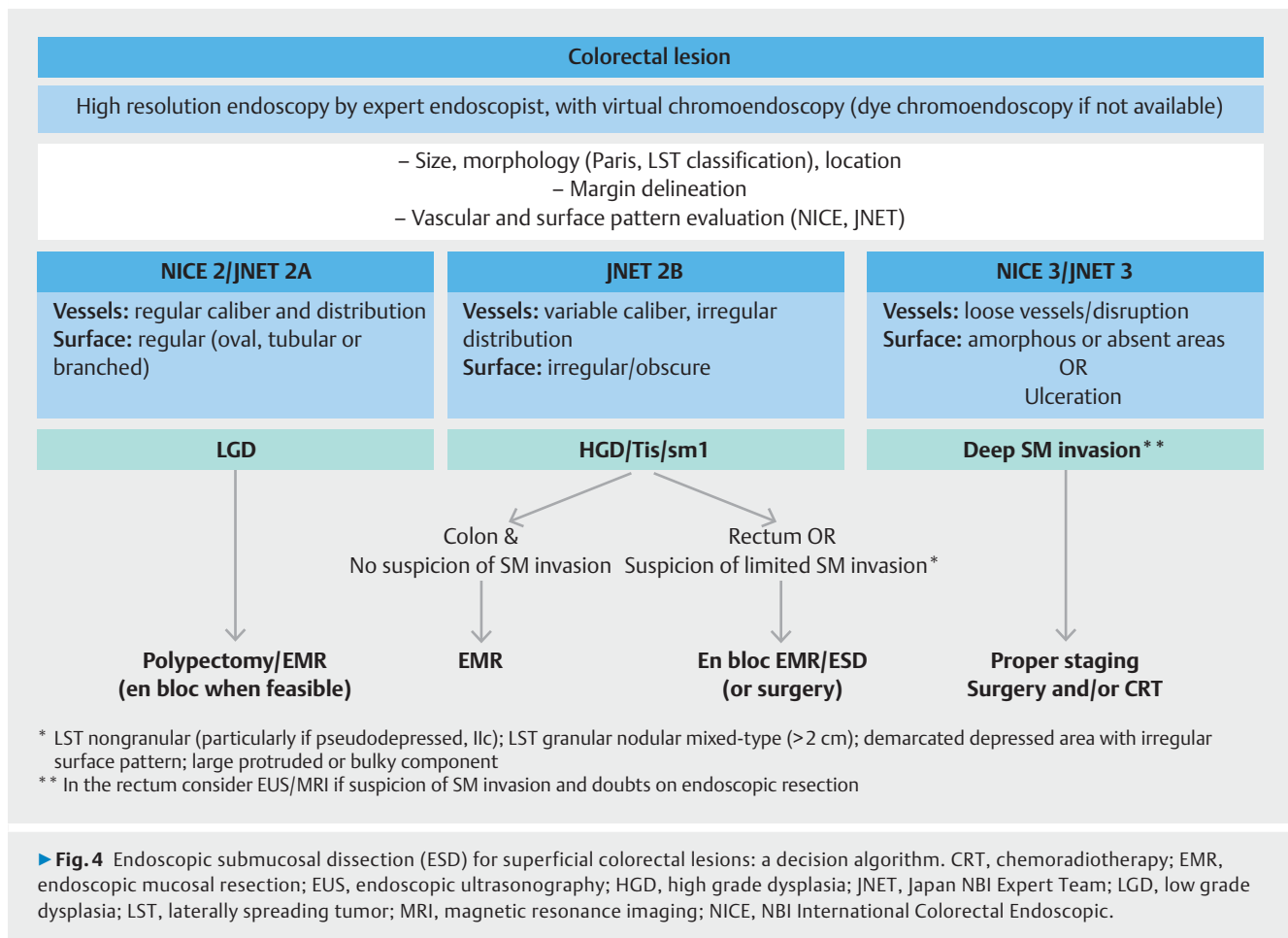
3 Pretreatment evaluation

3.1 Endoscopic evaluation

Successful curative resection of a superficial GI lesion can only be achieved by precise characterization of the lesion, optimal delineation of tumor margins, and estimation of depth of invasion, and this can only be correctly assessed by experienced endoscopists. The morphology of all visible lesions should be

RECOMMENDATION

1 ESGE recommends that the evaluation of superficial gastrointestinal lesions should be done by an experienced endoscopist, using high definition white-light and chromoendoscopy (virtual or dye-based), and validated classifications when available.
 Strong recommendation, high quality evidence.



described using the Paris classification since this gives an indication of the likelihood of invasive cancer [6].

Considering the increased availability of virtual chromoendoscopy (CE) techniques, the absence of side effects, shorter duration of the procedure, and similar or better accuracy in detecting and delineating the resection margins of lesions, as compared to dye-based CE, virtual CE (complementing high resolution white-light endoscopy [WLE]) should be the standard of care for pretreatment evaluation of superficial GI lesions [7].

3.1.1 Esophageal squamous cell carcinoma (SCC) lesions

The 2015 ESGE guideline recommended virtual CE (narrow-band imaging [NBI], blue-light imaging [BLI]) as an alternative to Lugol CE (LCE) for the detection of superficial esophageal SCC. Both methods have been proven to be more accurate than WLE alone [1]. CE provides a high diagnostic rate in evaluating the esophagus to diagnose SCC. A meta-analysis showed that NBI has comparable sensitivity to that of LCE (88% vs. 92%), but superior specificity (88% vs. 82%, $P < 0.001$) [8]. The higher specificity was confirmed in a prospective randomized trial, even when the technique was used by nonexperts [9]. A recent study compared LCE with NBI for delineation of tumor mucosal margins before endoscopic resection of SCC, and found no difference in the complete lateral resection rate [10]. Thus, virtual CE appears to be the optimal method for detection and

delineation of esophageal SCC, with the more cumbersome LCE remaining as an option.

For determining depth of invasion also, WLE appears to be suboptimal when compared to virtual CE [11]. The Japan Esophageal Society (JES) proposed a new simplified magnifying endoscopy (ME)-CE classification for estimating the depth of invasion of superficial esophageal SCC [12]. The JES classification categorized the lesions according to the type of microvessels: type A microvessels without severe irregularity correspond to noncancerous/low grade dysplastic lesions; type B microvessels with severe irregularity are suggestive of cancerous lesions. Type B is further divided into three categories: B1 corresponds to high grade intraepithelial neoplasia or intramucosal carcinoma m1 or m2; B2 to carcinoma invading the muscularis mucosae/m3 or sm1; and B3 to at least sm2 tumors. The overall accuracy of type B microvessels for predicting tumor invasion depth was 90.5% [12]. Most studies using this classification show an overall accuracy exceeding 80%–90%, and excellent interobserver agreement (over 0.85). Performance is excellent with type B1 tumors (88.6%; sensitivity 71.4%, specificity of 100%), and type B3 tumors (90.0%; sensitivity 75%, specificity 97.8%) [13, 14]. All these studies used ME-NBI, but a recent trial reported similar accuracies with ME-blue-light imaging (BLI) with concordance between ME-NBI and ME-BLI of 91.2% [15]. Based on these studies we propose that the newly developed

JES classification is useful in estimating the invasion depth of superficial SCC and, even though no study has been reported in the West, it can be considered in clinical practice.

3.1.2 Barrett's esophagus (BE)-associated lesions

Although early esophageal neoplasia in BE generally presents as subtle flat lesions that may be difficult to detect, most procedures performed with high resolution endoscopes do reveal these abnormalities to the experienced eye [16, 17]. Both virtual CE and acetic acid dye-based CE are easy to learn and interpret. Criteria have been developed in the new PREDICT classification to diagnose Barrett's neoplasia according to focal loss of acetowhitening and surface patterns of Barrett's mucosa [18]. Concerning acetic acid, a recent meta-analysis showed that pooled sensitivity, specificity, and positive and negative likelihood ratios (with 95% confidence intervals [95% CIs] shown in parentheses), for the diagnosis of high grade dysplasia (HGD) and Barrett's adenocarcinoma for all the included studies (9 studies, 1379 patients) were 0.92 (0.83–0.97), 0.96 (0.85–0.99), 25.0 (5.9–105.3), and 0.08 (0.04–0.18), respectively [19].

The BING working group developed a simple, internally validated system to identify dysplasia and esophageal adenocarcinoma (EAC) in patients with BE, based on NBI results. When images are assessed with a high degree of confidence, the system can classify neoplasia within Barrett's with >90% accuracy and a high level of interobserver agreement [20]. However, a recent study showed that its sensitivity and positive predictive value for the diagnosis of dysplasia may be low in daily practice [21].

These studies suggest that both CE methods are valuable tools with excellent performance when used by experienced observers and should be used for evaluation of Barrett's dysplasia, alone or simultaneously.

3.1.3 Stomach lesions

Diagnosis and evaluation of early gastric cancer (EGC) lesions is clearly improved by CE when compared to WLE [22]. Virtual CE with ME has high accuracy in delineating horizontal margins before ESD and performs equally well as or better than dye-based CE [23–25]. CE has also the potential for predicting EGC differentiation [26, 27]. Several studies also suggest that CE can be used for prediction of depth of invasion, with a blurry mucosal and irregular mesh pattern suggesting submucosal invasion, with a global accuracy superior to 80% [27–30]. However, no validated classification exists nor is there any study suggesting that CE is better than standard high resolution WLE for this purpose, and the decision not to endoscopically resect the lesion is still based mainly on macroscopic features of the lesion (► Fig. 3).

3.1.4 Duodenal lesions

Data are scarce on the pretherapeutic evaluation of duodenal neoplasia. In a single-center trial the ability of virtual CE to distinguish adenoma from intramucosal cancers was evaluated, with a mixed or absent pattern having 72% accuracy with moderate interobserver agreement (κ 0.59) [31]. Endoscopic

prediction of invasion depth of early duodenal neoplasia has never been compared with that of EUS, CT, or other imaging modalities, and therefore pre-ESD staging is still based on endoscopic evaluation [32].

3.1.5 Colorectal lesions

In patients with large colorectal laterally spreading tumors (LSTs) resected endoscopically, the risk of pathological T1 cancer can be predicted on the basis of the laterally spreading tumor (LST) subclassification and tumor diameter [33]. To determine the indication for ESD or EMR, overall judgment based on the subclassification of LST, vessel, surface, and pit pattern diagnosed by means of CE observation is useful. Distinction between adenoma and adenocarcinoma can be achieved with high accuracy using high resolution endoscopy and CE observation [34, 35]. For this purpose, NICE (NBI International Colorectal Endoscopic) and JNET (Japan NBI Expert Team) classifications have been associated with high accuracy in determining the histology of the lesion [36, 37]. Thus, the indication for EMR, ESD or surgery will be made on macroscopic morphological features and on more detailed features assessed by advanced imaging techniques (see ► Fig. 4) [38, 39]. The latter were recently addressed in an ESGE guideline [40].

3.2 Endoscopic ultrasonography and other modalities

RECOMMENDATION

2 ESGE does not recommend routine performance of endoscopic ultrasonography (EUS), computed tomography (CT), magnetic resonance imaging (MRI), or positron emission tomography CT (PET-CT) prior to endoscopic resection (ER).

Strong recommendation, moderate quality evidence.

RECOMMENDATION

3 ESGE suggests that when suspicious features for deep submucosal invasion are present, complete staging should be considered in order to exclude stage T2/T3 or lymph node metastasis (LNM).

Weak recommendation, low quality evidence.

3.2.1 Esophageal SCC lesions

Given the results shown with endoscopy, particularly when complemented with virtual magnifying endoscopy with chromoendoscopy (ME-CE), the role of other staging modalities, including EUS, CT, MRI, or PET-CT, is doubtful in lesions with estimated depth of invasion of T1 m3–sm1 or less.

A meta-analysis performed in 2016 confirmed the limitations of EUS in detecting submucosal invasion, with pooled sensitivity and specificity for T1 versus T2–4 tumors of 77% (95% CI 73%–80%) and 95% (95% CI 94%–96%), respectively. Among the T1 tumors, EUS had a pooled sensitivity in distinguishing between T1a and T1b of 83%–84% (95% CI 80%–88%), and a

specificity of 89% (95%CI 86%–92%) [41]. In the largest retrospective study focusing on EUS overstaging, the rate of overstaged pTis–T1a was 39.5% [42].

Several reports and a meta-analysis compared accuracy outcomes between EUS and ME-NBI, showing comparable results [43, 44]. In one of these reports, the sensitivity and accuracy of ME-NBI in distinguishing m1–m2 from m3/sm1 and from more deeply invasive SCCs was significantly higher than that of EUS ($P=0.048$ and $P=0.017$, respectively) [44]. Recent studies have emphasized the relevance of MRI and PET-CT with regard to T1 lesions, showing a high accuracy of MRI compared to EUS and CT [45,46], and a possible role for PET-CT in identifying T1a lesions when no uptake can be seen in the esophageal wall [47], but these studies need further validation. Nevertheless, since PET-CT is a standard staging method for advanced SCC, the combined use of PET-CT and high resolution CE, especially with microvascular findings of types B2 and B3, may be useful to determine whether ER is indicated for the lesion [48]. When the lesion is visible on PET, a therapeutic modality other than ER should be considered [47].

In summary, ME-CE is superior to WLE alone in estimating depth of invasion for esophageal SCC, and has at least a similar overall staging accuracy compared with EUS, without the limitations of EUS such as the risk of overstaging early endoscopically curable disease. JES type B2–B3 lesions or lesions with distinct features, such as nodular protrusion, ulceration, and depressed areas, should be considered to have the risk of submucosal invasion and are most likely to benefit from additional staging procedures such as EUS and PET-CT.

3.2.2 Barrett's esophagus (BE)-associated lesions

A meta-analysis of EUS staging of superficial esophageal adenocarcinoma (EAC) showed favorable pooled values for mucosal cancer staging, but unsatisfactory diagnostic results for EAC at the esophagogastric junction [49]. Even in lesions suspicious for malignancy (nodular or depressed lesions), resection of the lesion with histological examination had greater utility than staging by EUS [50]. Hence, EUS appears to be of limited utility in accurate staging of BE patients with high grade dysplasia (HGD) or early EAC [51]. Nevertheless, if deep submucosal invasion is suspected endoscopically, then complete staging should be performed with EUS, CT, and/or PET-CT.

3.2.3 Stomach lesions

The use of abdominal CT or PET-CT in the staging of endoscopically resectable early gastric cancer (EGC) does not have an established role because of the very low risk of distant metastasis. Moreover, perigastric adenopathy may be a nonpathological finding that can jeopardize ER. Regarding the use of these techniques in order to assess the feasibility of ESD in EGC, in recent years only a few studies have tried to use CT or PET-CT to predict the curability of EGC by ER; they have shown differing results, with an accuracy for CT scan of 60% [52] whilst PET-CT showed sensitivity, specificity, PPV, and NPV of 79%, 91%, 81%, and 89%, respectively [53].

The role of EUS in the staging of EGC is also debatable. In a recent meta-analysis, for invasion depth EUS showed sensitivity

and specificity of 0.87 (95%CI 0.86–0.88) and 0.67 (95%CI 0.65–0.70), respectively. The overall overstaging rates for m1–3 and sm1 tumors by EUS were 13.3% and 32.8%, respectively, while the overall understaging rate for sm tumors was 29.7%. The total misdiagnosis rates for EUS were 30.4% for lesions ≥ 2 cm and 20.9% for lesions < 2 cm, 27.7% for ulcerative lesions and 21.4% for nonulcerative lesions, and 22% for differentiated lesions and 26.9% for undifferentiated lesions [54]. Globally, the overall accuracy varied from 71.5% [55] to 95% [56].

It should be noted that endoscopy alone (even without CE) has almost 80% accuracy in determining curability by ER, with several prediction models described to decide between ESD or surgery, with good results published in the literature [57–59]. Moreover, ESD does not preclude the possibility of subsequent surgery and should be seen as the most definitive T-staging modality.

To conclude, EUS, CT, or PET do not add to endoscopic evaluation alone, they have significant rates of over- and understaging, and cannot be recommended routinely, particularly for lesions that are considered endoscopically resectable.

3.2.4 Colorectal lesions

A subset analysis of a multicenter randomized controlled trial (RCT) comparing CE with EUS for staging of early colorectal cancer (CRC) showed no advantage of EUS over CE, with a global accuracy of 78% for both techniques [60]. Since the 2015 guideline, four new meta-analyses have been published that address the diagnostic accuracy of EUS, CT, and MRI. Overall, with indirect comparison, no significant differences in T or N staging could be found between CT, MRI, or EUS, in the setting of a newly diagnosed rectal lesion that is being considered for endoscopic therapy. Accuracy in distinguishing T1 from T2 cancers is limited for both EUS and MRI, with a serious risk for overstaging [61–64].

Based on those studies we recommend that all colorectal lesions should be described according to laterally spreading tumor (LST) type, CE features, and location, in order to predict the risk of submucosal invasion and, hence, choose the best therapeutic option. EUS and/or MRI may have a role in the rectum when suspicious features of submucosal invasion are present. As ER might create inflammatory lymph nodes around the rectum, in these cases staging should preferably be done before any eventual resection; however, in cases with T-stage discrepancy between optical evaluation and EUS/MRI, the endoscopic evaluation should carry greater weight. Complete staging is recommended in lesions with optical features for deep submucosal invasion.

4 Therapeutic options

4.1 Esophageal SCC lesions

RECOMMENDATION

4 ESGE recommends ESD as the treatment of choice for most esophageal squamous cell and gastric (or junctional non-Barrett's) superficial lesions, mainly to provide an en bloc potentially curative resection with accurate pathologic staging.

Strong recommendation, moderate quality evidence.

RECOMMENDATION

5 ESGE suggests that ESD might also be considered for en bloc resection of noncircumferential clinically staged T1a-m3/T1b-sm1 or for circumferential clinically staged T1a-m1/m2 esophageal squamous cell carcinoma (SCC).

Weak recommendation, moderate quality evidence.

Numerous studies evaluating long-term outcomes after ESD for superficial esophageal cancer have been published since the 2015 guideline [65–67]. Following ESD for lesions limited to the epithelium (m1) or the lamina propria (m2), the 5-year disease-specific survival (DSS) and 5-year overall survival (OS) rates were reported to be 98%–100%, and 85%–95%, respectively. Thus such lesions represent an absolute indication for ER [66].

Two issues are still debated regarding T1 tumors. The first concerns the role of ER as first-line treatment for noncircumferential esophageal SCC that has preoperatively been clinically staged as cT1a-m3/T1b-sm1 (N0M0). The second concerns ESD for superficial SCC involving the entire circumference of the esophagus.

There are no available European data covering these two topics, but the most recent Japan Gastroenterological Endoscopy Society (JGES) guideline suggests that ESD is weakly recommended as first-line treatment for preoperatively clinically diagnosed cT1a-m3/T1b-sm1 noncircumferential esophageal SCC. It is also weakly recommended for clinically diagnosed cT1a superficial SCC with a major axis length ≤ 50 mm and involving the entire circumference of the esophagus, upon implementation of preventive measures for stenosis [68]. A recent study adds evidence to these recommendations, showing that almost 60% of endoscopically predicted T1a-m3/T1b-sm1 tumors involving less than three-quarters of the circumference can be cured by ER alone but if the lesion is circumferential then the ESD curability rate drops to less than 20% [69].

4.1.1 Comparison with endoscopic mucosal resection (EMR)

There is no randomized study comparing EMR with ESD for SCC, but several new European reports have confirmed the efficacy and the superiority of ESD compared to EMR already stated in the previous 2015 guideline [10, 67, 70, 71]. In a French trial, the complete resection rates for the ESD group and the EMR

group were, respectively, 97.1% versus 85% ($P < 0.01$), and the 5-year disease-free survival rates were, respectively, 95.2% versus 73.4% ($P < 0.01$) [71]. In an older meta-analysis of retrospective studies, ESD had higher en bloc and curative resection rates than EMR regardless of lesion size [72]. Thus ESD seems superior to EMR in the treatment of SCC as evidenced by significantly higher en bloc and curative resection rates and by a notably lower local recurrence rate [73].

4.1.2 Comparison with surgery

Three recent articles compared the outcomes of ESD and surgical resection for pT1 esophageal SCC, all of which were single-center, retrospective studies. A report from Shanghai [74] found fewer treatment-related deaths in patients in the ESD compared with the surgery group, although the difference was not significant (0.3% vs. 1.5%, $P < 0.186$). Furthermore, there were significantly fewer severe complications in the ESD group than in the surgical resection group (15.2% vs. 27.7%, $P < 0.001$). Post-treatment stenosis was more common in the ESD group but the difference was not significant (13.4% vs. 9.9%, $P < 0.203$). However, in the ESD compared with the surgical resection group, treatment duration and length of hospital stay were significantly shorter (49 min vs. 240 min, $P < 0.001$, and 3 days vs. 11 days, $P < 0.001$, respectively) and the cost of hospitalization was significantly lower (median 2813 US dollars [USD] vs. 10 001 USD, $P < 0.001$). There was no significant difference between the two groups in terms of all deaths, disease-specific death rates, or metastasis rates, over a median observation period of 21 months, including in the patients with T1b tumors. Similarly, a report from Korea [75] found no difference between the ESD and surgical resection groups after mean observation periods of 43 and 63 months, respectively, in terms of OS, DSS, or recurrence-free survival. Another report from Shanghai [76] that specifically addressed outcomes according to invasion depths concluded that ESD oncologic outcomes were comparable to those achieved with esophagectomy, but were associated with minimal invasion, lower cost, and lower incidence of serious adverse events. However, in sm2/sm3 tumor patients, the ESD R0 resection rates were lower than those of esophagectomy [76].

Long-term outcomes were recently analyzed in a systematic review and meta-analysis that included 3796 patients and 5 comparative studies [77]. In terms of the comparison between ESD and esophagectomy, there was no difference in the OS (86.4% vs. 81.8%; hazard ratio 0.66, 95%CI 0.39–1.11) as well as in DSS and recurrence-free survival. In addition, ESD was associated with fewer adverse events (19.8% vs. 44.0%; odds ratio 0.3, 95%CI 0.23–0.39).

ER is, therefore, considered safer and less invasive than surgical resection in patients with pT1 cancers, as well as being superior in terms of medical economics. Furthermore, patients are likely to prefer ER over surgical resection. Hence, balancing the benefits of organ preservation and the harm of postoperative complications, ESD should be recommended as first-line therapy for selected lesions (if a tumor classification no more severe than T1b-sm1 is expected).

4.1.3 Comparison with chemoradiotherapy (CRT)

In a phase II trial (JCOG9708) [78] of CRT including 72 patients with cT1N0M0 esophageal SCC, over 90% of patients achieved a complete response, with a 4-year OS rate of 80.5%. However, local recurrences were observed in 31% of patients, with a 4-year DSS rate of only 52.8%. More recently, a retrospective study of definitive CRT in 36 patients with T1bN0M0 esophageal SCC found that local and metastatic recurrences were common, with a 5-year OS rate of 86% and a 5-year DSS rate of 59% [79].

Data from the JCOG9708 trial [78] showed that adverse events of grade ≥ 2 included dyspnea in 11.1%, esophagitis in 2.7%, ischemic heart disease in 2.7%, myocarditis in 2.7%, and arrhythmia in 1.4% of patients. The abovementioned recent report found grade ≥ 2 adverse events that included esophageal stenosis in 11% and pleural effusion in 14% of patients, with grade 4 pericardial effusion in 3% and grade 5 pneumonia in 3% of patients [79]. The benefit and harm profiles of ESD and CRT therefore differ.

However, the benefit–harm balance of ESD limited to patients with superficial cancers appears superior to that of CRT, reflecting the minimal invasiveness of ESD. Thus, if either ESD or CRT is indicated, we recommend ESD as the first-line treatment and CRT as a possible after-treatment option. Nevertheless, ESD is also technically feasible in patients with local failure after CRT, especially as an initial salvage treatment and as treatment for second primary lesions within the irradiation field [80].

4.2 Barrett's esophagus (BE)-associated lesions

RECOMMENDATION

6 For BE-associated lesions, ESGE recommends to use EMR for ≤ 20 mm visible lesions with low probability of submucosal invasion (Paris type 0-IIa, 0-IIb) and for larger or multifocal benign (dysplastic) lesions. Strong recommendation, high quality evidence.

RECOMMENDATION

7 For BE-associated lesions, ESGE suggests to use ESD for lesions suspicious for submucosal invasion (Paris type 0-I, 0-IIc), for malignant lesions > 20 mm, and for lesions in scarred/fibrotic areas. Weak recommendation, low quality evidence.

The efficacy of ESD in Barrett's-associated neoplasia is well established both in the East and the West, with en bloc resection rates varying around 90%. It remains, however, very difficult to delineate Barrett's lesions since most series show a lower R0 resection for cancer (ranging between 70% and 88%) [70].

4.2.1 Comparison with EMR

In comparison with EMR, ESD results more frequently in R0 resection. This has been demonstrated in a Japanese retrospective study involving 13 centers that assessed long-term outcomes of EMR and ESD of lesions at the gastroesophageal junction [81]. Although potentially comparable in nature, it is however not clear how this finding translates to BE-associated neoplasia, for which the treatment mostly is a combination of resection and ablation of residual columnar epithelium at risk for recurrence, regardless of whether EMR or ESD is used [70, 82].

Since the 2015 guideline, three meta-analyses have been published that assess outcomes of ESD and compare ESD with EMR for Barrett's-associated neoplasia. Yang et al. published a meta-analysis assessing safety and efficacy of ESD for early BE neoplasia. It included 11 studies and 501 patients, with a mean lesion size of 27 mm. The en bloc resection rate was 92.9% (95%CI 90.3%–95.2%), R0 resection was however lower at 74.5% (95%CI 66.3%–81.9%), and the curative resection rate was 64.9% (95%CI 55.7%–73.6%). Perforation occurred in 1.5% (95%CI 0.4%–3.0%), bleeding in 1.7% (95%CI 0.6%–3.4%), and the reported stricture rate was 11.6% (95%CI .9%–29.6%). Recurrence was found in 0.17% (95%CI 0%–0.3%) after a mean follow-up of 22.9 months [83].

A more recent meta-analysis on comparison of esophageal ESD versus EMR included 8 studies with BE neoplasia and 3 studies combining SCC and BE [84]. Only for lesions > 20 mm, the authors found higher en bloc resection rates for ESD (OR [odds ratio] 47.25, 95%CI 23.86–93.57; $P < 0.001$), higher curative resection rates for ESD (OR 6.16, 95%CI 2.5–15.19; $P < 0.001$), and lower local recurrence for ESD (OR 0.19, 95%CI 0.05–0.81; $P = 0.025$). Complication rates for perforation, bleeding, and stricture were not different between EMR and ESD. The authors suggested that lesion size should be one of the determining factors to select resection technique. Indeed, since procedure time is significantly longer for ESD, it is more cost-effective to perform EMR in most of the lesions [84].

Finally, the most recent JGES guideline for ESD/EMR for esophageal cancer included a systematic literature search and systematic review comparing ESD to EMR for BE neoplasia (with 26 studies included). The en bloc resection rate for EMR was 50% versus 96.4% for ESD with corresponding R0 resection rates of 39.7% and 81.9%. The local recurrence rate for EMR was 12.4% and for ESD it was 2.5%. Overall complication rates were not different between ESD and EMR. The JGES guideline concluded that, because of the higher rates of en bloc and R0 resections and a lower rate of local recurrence, ESD was recommended over EMR for the treatment of lesions that were amenable for ER [68].

However, there is most likely to be selection bias in the ESD groups and a significant length time bias. In addition, in view of the currently available ablation techniques, recurrence of 12.5% after a combination of EMR and radiofrequency ablation (RFA) is very unlikely. In fact, multimodality endotherapy with ER and RFA has been associated with only 4% recurrence, with all recurrences amenable to endoscopic therapy [82].

A recent study suggested a higher rate of complete remission of dysplasia (CRD) after 2 years in patients treated with ESD and subsequent ablation (85.6%) compared with patients treated with EMR and subsequent ablation (75.8%; $P < 0.01$) [85]. This was a retrospective analysis of a prospective database that included 537 patients, with 456 undergoing cap-assisted EMR and 81 ESD, followed by different ablation techniques. The data in this study are, however, confusing. The main conclusion was based on the Kaplan–Meier curve showing a higher cumulative probability at 2 years of obtaining CRD for the ESD group; however, in absolute numbers 420/537 patients (78%) in the cap-EMR group obtained CRD over a median follow-up of 11.2 years and 48/81 (59%) of the ESD group obtained CRD over a median follow-up of 1.4 years. The follow-up terms at least suggest a significant length time bias. Also the study is probably somewhat underpowered for accurate comparison: complete remission of intestinal metaplasia (CRIM) was 78.5% for cap-assisted EMR and only 40.7% for ESD but this was statistically not significant.

It is clear from the previous trial [85] that ESD does not compromise subsequent ablation. This was further illustrated by a retrospective study by Subramaniam et al. that compared the success of RFA after ESD ($n = 27$) or after EMR ($n = 43$) or RFA alone ($n = 21$), and showed no significant difference regarding CRD or CRIM [86].

A well-conducted randomized controlled trial (RCT) indicated that when lesions are amenable for both EMR and ESD, there is no clinical benefit in performing ESD. Terheggen et al. included 40 patients with single lesions that should have been amenable for either technique, including types 0-Is, 0-IIa, 0-IIc or their combinations, limited in horizontal extent to a diameter of ≤ 3 cm in the longitudinal direction or less than half of the esophageal circumference in the lateral direction, and without any endoscopic suspicion of deep infiltration into the submucosal layer. Although R0 resection rate was higher for ESD (10/17 vs. 2/17 for EMR), CRD at 3 months was not different [87]. Therefore, this trial provided evidence that ESD has little role for lesions that are clearly amenable for both EMR and ESD.

However, different situations exist with lesions that are bulkier and may be difficult to resect. If a lesion is suspicious for submucosal invasion (Paris 0-Is, 0-IIc lesions) and a deep R0 resection for accurate staging is desirable, ESD may also be indicated. Especially in elderly patients who are unfit for surgery or CRT, a radical resection may in fact still be curative albeit with a higher chance for metastasis. As indicated by the study from Terheggen et al. [87], and the meta-analysis by Yang et al. [83], ESD could be considered, particularly for larger lesions (> 2 – 3 cm). Some studies also indicate that ESD is successful in more challenging cases with nodular lesions, lesions larger than 2 cm, or with scarring (poor lifting) [88–91].

Therefore, in conclusion, in terms of need for surgery, neoplasia remission and recurrence, ESD and EMR are both highly effective for ER of early Barrett's neoplasia. ESD achieves a higher R0 resection rate, but for most patients this bears little clinical relevance, as it is more time-consuming and has the potential to cause severe adverse events [87, 92].

4.2.2 Comparison with surgery

For the 2015 ESGE guideline only three studies were found showing that for T1a EAC, ER was as effective as surgery and had a better safety profile [93–95]. Recent studies confirmed that for early BE-related EAC, ER is associated with similar DSS but with shorter hospital stays, fewer readmissions and lower 90-day mortality [96–98]. Moreover, a recent study analyzing quality of life after these two options shows that multiple measures of symptom status are better following ER when compared to surgery [99].

Hence, based on ER efficacy and its fewer and more manageable complications, ER (when combined with ablation) appears to be a viable alternative to surgery even for lesions with superficial submucosal invasion.

4.3 Stomach lesions

RECOMMENDATION

8 ESGE recommends ESD for differentiated gastric lesions clinically staged as dysplastic or as intramucosal carcinomas (of any size if not ulcerated and ≤ 30 mm if ulcerated), with EMR being an alternative for Paris 0-IIa lesions of size ≤ 10 mm with low likelihood of malignancy. Strong recommendation, moderate quality evidence.

RECOMMENDATION

9 ESGE suggests that gastric adenocarcinomas that are ≤ 30 mm, submucosal (sm1), and well-differentiated, or ≤ 20 mm, intramucosal, and poorly differentiated type, both without ulcerative findings, can be considered for ESD, although the decision should be individualized. Weak recommendation, low quality evidence.

4.3.1 Comparison with EMR

Since the publication of the first ESD guidelines, two meta-analyses including > 6000 patients and a large prospective cohort have compared efficacy and safety outcomes of EMR and ESD [100, 101, 102]. Compared with EMR, ESD is associated with significantly higher rates of en bloc and complete resection (including in lesions < 10 mm), lower recurrence, and similar post-procedural bleeding; on the other hand, it is associated with a slightly higher perforation risk and increased procedural duration. Several real-world ESD series confirm its high rates of en bloc and R0 resection ($> 90\%$), curative resection (75%–80%), low local recurrence ($< 5\%$) and acceptable rates of adverse events (post-procedural bleeding 5%–10%, perforation $< 3\%$) [102, 103]. It also seems that gastric ESD is being successfully implemented in Europe, and although published studies generally include a low number of patients, the outcomes of European series are generally comparable to those from Eastern countries [3]. Short- and long-term outcomes of ESD in cardia/esophagogastric lesions are also comparable to

those for other gastric locations although there is a trend to lower R0 and curative resection rates [81].

ESD is thus recommended as the first-line endoscopic treatment for gastric superficial lesions with a null/very low risk of LNM. These are, namely:

- a) dysplastic lesions of any size;
- b) differentiated-type adenocarcinomas, clinically staged as intramucosal (that is, without signs of deep submucosal invasion), of any size in the absence of ulceration and ≤ 3 cm in the presence of ulceration.

EMR should be considered as an alternative for elevated (0-IIa) lesions, < 10 mm, and with low likelihood of advanced histology, and provided that the endoscopist feels that en bloc R0 resection can be achieved. For undifferentiated-type adenocarcinomas clinically staged as intramucosal, ER can be considered if the lesion is < 2 cm and without ulcerative findings, although the decision should be individualized, balancing surgical risks and patient preferences (in the expanded indication for ER) [104].

4.3.2 Comparison with surgery

Several studies have also directly compared short- and long-term outcomes of ESD and gastrectomy in the treatment of gastric superficial lesions, as summarized in four meta-analyses [105–108]. Although the majority of studies are retrospective and performed in Eastern countries, these meta-analyses have found that ESD is associated with significantly lower procedural time, length of stay, and adverse events. A significantly lower procedure-related mortality was also found in one meta-analysis [106]. Two prospective studies not included in that meta-analysis also directly compared short-term ESD and gastrectomy outcomes, with similar results [109, 110]. Concerning long-term outcomes, in the meta-analyses no differences were found in OS or DSS (DSS $> 99\%$ for both treatment groups), although ESD was associated with a significantly higher recurrence risk and lower disease-free survival. Metachronous lesions were also significantly more frequent in ESD arms (5.2%–6.0% vs. 0.4%–0.5% in gastrectomy studies), which accounts for most of the events during follow-up. However, ESD was found to have a positive impact on health-related quality of life when compared with gastrectomy [109, 111–113].

Based on these data, when the lesion appears endoscopically resectable with a predictable high curability potential, ESD appears a better option than surgery.

4.4 Duodenal and small-bowel lesions

RECOMMENDATION

10 ESGE does not recommend routine use of ESD for duodenal or small-bowel lesions, with its use being reserved for selected cases in expert centers.
Strong recommendation, moderate quality evidence.

RECOMMENDATION

11 ESGE recommends polypectomy and/or EMR (en bloc or piecemeal) as the treatment of choice for most duodenal and small-bowel superficial lesions.
Strong recommendation, moderate quality evidence.

Rates of R0 resection for duodenal ESD are highly variable, between 19.4% in a European study [114] to 93.9% in China [115]. In all studies analyzed it seems clear that R0 resection rates are lower in the duodenum compared with other organs particularly for less experienced endoscopists [116].

Regarding safety, perforation rates are high with an incidence $> 10\%$ in different studies including in expert centers [115, 117], and reaching 15% [118] to 37.5% [119] in some of those studies. The major risk factor for delayed perforation, a dreadful complication that occurs mainly with ESD (and less with EMR), was lesion location that was distal to the ampulla of Vater [120].

4.4.1 Comparison with EMR

Available comparative data available are scarce and retrospective, but demonstrate a higher rate of R0 resection with ESD compared to EMR [114–116]. In retrospective studies whose data were compiled in a meta-analysis, ESD demonstrated a higher rate of complete resection than EMR with an OR of 1.63 but without any difference in the risk of local recurrence [116]. On the other hand, the risk of per-procedure and delayed perforation with duodenal ESD was higher than for EMR, and there was a higher risk of surgery for delayed perforation [116, 120]. Similar results were reported in Japan, although the rate of R0 resection was higher in Asian than in European studies (OR 2.16) [116]. Hybrid techniques did not show higher R0 resection rates than EMR [121].

Finally, EMR seems to remain the better therapeutic option for duodenal neoplasia because of its efficacy and safety profile, even for complex lesions, and its favorable comparison with surgery [122–124]. Moreover, the clinical benefit for the patient of achieving R0 resection has never been demonstrated for duodenal lesions, in particular because of the low incidence of invasive submucosal cancer. ESD has been proposed as an alternative when EMR is not technically feasible because of strong fibrosis after local recurrence [125].

Thus, for the moment, there are no clear indications for the use of ESD for nonampullary duodenal lesions. EMR remains the first option strategy for duodenal neoplasia since ESD is not as effective and safe as in other organs, with lower R0 resection rates than in other organs, a high perforation rate, and with no proven advantage in recurrence when compared to EMR.

4.5 Colorectal lesions

RECOMMENDATION

12 ESGE recommends polypectomy and/or EMR (en bloc or piecemeal) as the treatment of choice for most superficial colorectal lesions.

Strong recommendation, high quality evidence.

RECOMMENDATION

13 ESGE suggests that ESD should be considered for en bloc resection of colorectal (but particularly rectal) lesions with suspicion of limited submucosal invasion (demarcated depressed area with irregular surface pattern or a large protruding or bulky component, particularly if the lesions are larger than 20 mm), or for lesions that otherwise cannot be completely removed by snare-based techniques.

Weak recommendation, moderate quality evidence.

Colorectal ESD is common practice in Eastern countries, with good results and established indications [35, 126, 127]. In experienced hands en bloc and R0 resection rates can be higher than 90% [128]. In the West initial studies were disappointing even for rectal lesions, with an en bloc resection rate of only 61% and a perforation rate of 18% [129]. However, more recent studies have shown better results with 80% en bloc and 69% R0 resection rates, and an 8% complication rate (with 2% requiring emergent surgery) [130]. A recent systematic review of 109 studies on 19484 colorectal lesions treated by ESD showed rates of en bloc resection of 91%, R0 resection of 82.9%, and 2% recurrence; the rate of bleeding was 2.7% and of perforation 5.2%, and 1.1% needed surgery because of adverse events [131]. However, these results were worse in non-Asian countries.

Therefore, even though ESD is the endoscopic technique that allows a greater chance of en bloc R0 resection in the colon, its safety profile looks worse than in the esophagus and in the stomach, particularly in Western countries.

4.5.1 Comparison with EMR

Several studies and meta-analyses compared EMR versus ESD for colorectal lesions, with similar conclusions: en bloc and R0 resection rates are higher and recurrence lower with ESD, but in the ESD group the procedure is longer, and the rates of perforation, complications, and additional surgery because of complications are higher [128, 132–134]. Moreover, to our knowledge, no comparative study has addressed the difference in adenoma recurrence between ESD and piecemeal EMR (pEMR) using thermal coagulation at the end of resection, a technique that has been proven in a large randomized controlled trial (RCT) to reduce recurrence after pEMR from 21% to 5% ($P < 0.001$) with no adverse events [135]. The effectiveness of this technique in clinical practice has now been

confirmed with recurrence rates of only 1.4% in those receiving complete margin thermal ablation [136].

Thus, the question is when we should use ESD instead of EMR? A recent systematic review including 11260 colorectal ESDs showed that even in selected lesions there was only a low prevalence of the sm1 lesions that would justify the attempt at en bloc ESD resection: 15.7% of the specimens disclosed submucosal invasion with only 8% overall infiltrating less than 1000 microns and only 6% of resections being curative. The number needed to treat for avoiding one surgery was 12.5 to 16.7. The authors concluded that ESD should not be used indiscriminately in the resection of colorectal neoplasia [137].

A cost-effectiveness study comparing ESD and wide-field EMR for removing large sessile and laterally spreading lesions >20 mm showed that even for these lesions universal ESD could not be justified (the exception being high risk rectal lesions), and the best strategy would be selective ESD for the lesions suspicious for submucosal cancer [138]. The lesions at risk of submucosal invasion are: nongranular LSTs (LST-NGs), particularly if pseudodepressed 0-IIc; granular nodular mixed LSTs, particularly if more than 2 cm in size; especially lesions in the recto-sigmoid area; and those showing an irregular pattern with CE. These lesions should be considered for ESD and/or surgery [33–35, 39].

4.5.2 Comparison with surgery

Although surgery is a more definitive treatment for large and malignant polyps, and also allows lymph node resection, it is associated with a considerable burden of AEs and even mortality. In a retrospective cohort for complex nonmalignant polyps, surgery was associated with rates of 17% for significant adverse events, 3% for additional surgery, and 1% for 12-month mortality; compared with ER, length of stay and costs were greater [139]. Another study from the tertiary Veterans Affairs Medical Centers showed that a strategy of a prior attempt at ER reduced morbidity compared to laparoscopic surgery, particularly for polyps <4 cm [140]. A case-matched comparison of ESD versus laparoscopic surgery for complex polyps showed that ESD is more cost-effective than conventional segmental resection, suggesting that ESD can be offered as a colon-preserving procedure [141]. Furthermore, quality of life has been evaluated to be better after ESD compared to laparoscopy-assisted surgery [142] in one study, and costs are higher for transanal endoscopic microsurgery compared to ESD [142, 143]. Moreover, for patients with T1 CRC, prior ESD with histological en bloc resection did not adversely affect their oncologic prognosis after additional surgery [144].

However, specifically analyzing only malignant T1 polyps (and excluding benign polyps), a study using the US National Cancer Database, that was one of the largest population-based analyses of patients with T1N0M0 malignant colon polyps, showed that OS was higher in patients who underwent surgery compared with polypectomy. This finding was consistent even after adjustments between the two groups for multiple patient and tumor factors [145]. This study contradicted a systematic review and meta-analysis that found that ER should be considered as the first-line treatment for endoscopically resectable T1

colorectal cancers, and that in cases of noncurative resection, additional surgery can have comparable outcomes to primary surgery [146]. Another study showed that for colonic neoplasms, laparoscopic surgery should be considered when ESD is technically difficult, but that for rectal neoplasms, ESD is desirable even for large-sized lesions [147].

Taking all this into account, if a lesion is clearly benign, ER should be the first-line therapy, though as we have seen EMR might be a better option than ESD for these lesions. For lesions suspicious for malignancy, then ESD and/or surgery are comparable options and the decision will depend on several factors (location, size, complexity of ESD, patient preferences, center experience). The exception appears to be the rectum where ESD could have an advantage over EMR for complex high risk benign lesions and over surgery for suspicious T1 lesions.

5 Management after endoscopic resection

In this Guideline an adjustment of risk categories and terminology was deemed necessary, to reflect the different probabilities of LNM risks that depended upon the pathological characteristics of the resected tumor (see the section on **Pathological aspects**, and also ► **Table 2**).

5.1 Esophageal SCC lesions

RECOMMENDATION

14 ESGE recommends that an en bloc R0 resection of a superficial esophageal squamous cell lesion with histology no more advanced than intramucosal m2 cancer, well to moderately differentiated, with no lymphovascular invasion, should be considered a very low risk (curative) resection and no further staging procedure or treatment is recommended.

Strong recommendation, moderate quality evidence.

RECOMMENDATION

15 ESGE suggests that an en bloc R0 resection of an esophageal m3 or sm1 SCC that is well to moderately differentiated and with no lymphovascular invasion, should be considered a low risk (curative) resection and no further treatment is generally recommended.

Weak recommendation, moderate quality evidence.

However, in these cases, particularly if the lesion is bigger than 20 mm, there is a real (albeit low) risk of LNM and complete staging is recommended, with the risk from further therapy being balanced against the risk of LNM, in a multidisciplinary discussion.

Weak recommendation, low quality evidence.

RECOMMENDATION

16 ESGE suggests that complementary radiotherapy or CRT may be considered in a multidisciplinary discussion after a curative resection of esophageal m3/sm1 SCC (particularly if >20 mm in size).

Weak recommendation, moderate quality evidence.

Among lesions in which the depth of invasion does not extend beyond the mucosal layer (T1a), those confined within m1–m2 layers are only extremely rarely associated with LNM; therefore, ER is considered curative [148, 149]. A recent meta-analysis suggests that after full evaluation, ER can be recommended as a curative treatment for patients with superficial SCC if the following conditions are met: (i) tumor size ≤20 mm; (ii) Paris 0-II macroscopic type of tumor; (iii) possible confinement of lesion to mucosa; and (iv) absence of lymphovascular invasion [150]. Lesions extending up to the muscularis mucosae or slightly infiltrating the submucosa (up to 200 μm) are also amenable to ER; however, as a whole they are associated with a greater risk of LNM. Nevertheless, if some criteria are met, ER of these lesions might also be highly likely to be curative. In fact, in a recent study no single patient with m3/sm1 cancer, high tumor differentiation, no lymphovascular invasion, and tumor length <2 cm had LNM, and none of these patients experienced recurrence [151].

About 50% of the lesions that show deeper (>200 μm) invasion into the submucosa (T1b) are associated with metastasis, and in such cases ER should be considered to be a high risk resection and patients should be treated in the same manner as those with advanced carcinomas [148, 149].

ER plus adjuvant therapy appears to be a new combination treatment for SCC invading to deep mucosa (pT1a-m3) or submucosa (pT1b). Adjuvant therapy can take the form of esophagectomy, radiotherapy, or CRT. At present, there is no clear recommendation for or against the administration of additional treatments in patients with pT1a-m3 SCC. A recent randomized trial from China studied the combination of ESD with additional radiotherapy (59.4 Gy within 2 months after ESD) in T1a SCC. In the nonradiotherapy group 3/70 patients experienced intraluminal mucosal recurrence compared with none in the radiotherapy group. No local LNM or distant metastasis occurred in either group. The 3-year cumulative recurrence-free survival was 100% in the radiotherapy group and 85.3% in the nonradiotherapy group ($P=0.04$). No severe radiation toxicities were recorded [152]. Another earlier study showed the benefit of additional radiotherapy in patients with T1a-m3/T1-sm1 tumors [153].

Is additional treatment recommended in patients with pT1b-sm1 SCC, based on histological findings following ER? Again, if no other high risk criteria are met and the tumor size is <2 cm, the risk of LNM appears low [151]. Nevertheless, the efficacy of adding CRT after ER of SCC with submucosal invasion has been reported in several retrospective trials, with a better safety profile in comparison with surgery [154–157]. The

ECOG0508 trial was a prospective nonrandomized study to confirm the efficacy of selective CRT based on findings from ER in patients with T1b sm1–2 tumors [158]. Depending on the ER findings, patients received the following: no additional treatment for patients with pT1a tumors with a negative resection margin and no lymphovascular invasion (group A); prophylactic CRT for patients with pT1b tumors with a negative resection margin or pT1a tumors with lymphovascular invasion (group B); or definitive CRT for patients with a positive vertical resection margin (group C). The 3-year overall survival rates were similar among the groups (90.7% for group B and 92.6% in all patients). Efficacy was comparable to that of surgery. The JES guidelines conclude that there is strong evidence to recommend additional treatment (mainly CRT) after ER in patients identified as meeting high risk criteria (poorly differentiated tumor, lymphovascular invasion, deep submucosal invasion), taking into account the benefit–risk balance, strength of evidence, and patient preferences [159].

Based on these studies, the present authors consider that after a low risk (curative) ER of a T1a-m3 or T1b-sm1 tumor, surveillance and/or additional radiotherapy might be considered as a preferred less aggressive additional treatment, as compared to surgery or CRT, depending on the patient's clinical status. Nevertheless, CRT might be preferred over radiotherapy alone in young and fit patients. Surgery is an option for young fit patients meeting high risk criteria (noncurative ER), particularly if there is deep submucosal invasion and lymphovascular invasion, since in these cases overall survival could be better with surgery [160, 161].

5.2 BE-associated lesions

RECOMMENDATION

17 ESGE recommends that an en bloc R0 resection of a BE-associated superficial lesion with histology no more advanced than intramucosal cancer, well to moderately differentiated, with no lymphovascular invasion, should be considered a very low risk (curative) resection and no further staging procedure is generally recommended. Strong recommendation, moderate quality evidence.

RECOMMENDATION

18 ESGE suggests that an en bloc R0 resection of a BE-associated superficial lesion with superficial submucosal invasion (sm1), and that is well to moderately differentiated, and with no lymphovascular invasion, should be considered a low risk (curative) resection and no further treatment (except for ablation of BE tissue) is generally recommended.

Weak recommendation, moderate quality evidence.

However, in these cases, there is a real (albeit low) risk of LNM, and complete staging is recommended with the risk from further therapy (surgery) being balanced against the risk of LNM, in a multidisciplinary discussion.

Weak recommendation, low quality evidence.

RECOMMENDATION

19 ESGE recommends ablation of all of the Barrett's mucosa after a curative or local-risk resection. Strong recommendation, high quality evidence.

The risk of LNM in BE-associated esophageal adenocarcinoma (EAC) appears to be lower than in SCC. For BE-associated adenocarcinomas, according to reports that analyzed the rate of LNM relative to the depth of tumor infiltration, ER appears to be curative for intramucosal carcinomas that are well or moderately differentiated and without lymphovascular invasion [72, 162–165]. Based on limited data these criteria might be extended to lesions with invasion into the submucosa ($\leq 500 \mu\text{m}$, sm1), namely to low risk tumors (well or moderately differentiated, without lymphovascular invasion), because such lesions harbor a low risk of LNM (1.4%–1.9%) that appears to be lower than the risk of surgery for most patients [165–167]. Nevertheless, for sm1 tumors, this risk should be balanced against the risk of surgery for a particular patient. For sm2/sm3 EACs, surgery is recommended since the rate of LNM appears higher than the mortality risk of surgery, although a recent retrospective study reported a very low risk of LNM with less than $1000 \mu\text{m}$ of submucosal invasion [168, 169].

When remaining Barrett's mucosa is left untreated, case series have reported recurrence of neoplasia, with rates varying from 11% to 30% [170–172]. The multicenter EURO-II study demonstrated that complete eradication of neoplasia and Barrett's mucosa can be achieved with the combination of ER and RFA in 98% and 93%, respectively (in a per-protocol analysis). The recurrence rate for neoplasia was 4% and for intestinal metaplasia it was 8% [82]. According to a recent systematic review and meta-analysis the risk for recurrence of neoplasia is significantly higher in those patients who have residual Barrett's mucosa after completion of endoscopic therapy compared with those in whom CRIM has been achieved (risk ratio [RR] 2.8, 95%CI 1.7–4.6). The pooled cumulative incidence rate of dysplasia and Barrett's adenocarcinoma recurrence was 3%

► **Table 2** Types of endoscopic resection according to endoscopic and pathological criteria (post-resection), and proposed subsequent management.

	Endoscopic	Pathological	Notes	Management
<p>Very low risk (curative) resection Lymph node metastasis (LNM) risk < 1 %</p>	Complete AND En bloc	<ul style="list-style-type: none"> ▪ Only dysplasia ▪ If cancer: <ul style="list-style-type: none"> – Only intramucosal cancer – Differentiated – V0 – L0 – HM0 and VM0 (R0) – UL0 ▪ UL1 gastric intramucosal cancer and: <ul style="list-style-type: none"> – Differentiated – L0 – HM0 and VM0 (R0) – ≤ 3 cm 	Esophageal SCC T1a-m3 has a higher risk of LNM and should not be considered as a very low risk resection (instead it should be a low risk resection)	<ul style="list-style-type: none"> ▪ Only endoscopic surveillance recommended ▪ No need for further radiological staging or surveillance
<p>Low risk (curative) resection LNM risk < 3 %</p>	Complete AND En bloc	<ul style="list-style-type: none"> ▪ sm1 cancer¹ and: <ul style="list-style-type: none"> – Differentiated – V0 – L0 – HM0 and VM0 (R0) – UL0 – Budding 0/1 (colon) ▪ Poorly differentiated gastric intramucosal cancer and²: <ul style="list-style-type: none"> – V0 – L0 – HM0 and VM0 (R0) – UL0 – ≤ 2 cm 	<p>If m3/sm1 esophageal SCC, lesion should ideally be ≤ 2 cm</p> <p>If sm1 gastric cancer, lesion should be ≤ 3 cm</p>	<ul style="list-style-type: none"> ▪ Complete staging is recommended ▪ Further therapy generally not recommended ▪ Adjuvant therapy might be considered in esophageal SCC m3/sm1 (CRT) and in poorly differentiated intramucosal gastric cancer (surgery) ▪ Only endoscopic surveillance recommended (radiological surveillance might be considered in esophageal SCC and poorly differentiated gastric intramucosal cancer)
<p>Local-risk resection LNM risk < 3 % Local recurrence risk 10%–30 %</p>	Complete AND Piece-meal	<ul style="list-style-type: none"> ▪ HM1 and VM0 (RX) and: <ul style="list-style-type: none"> – Only dysplasia or intramucosal cancer – Differentiated – V0 – L0 – UL0 	<p>If SM cancer present in the margins, it should be considered a high risk resection</p> <p>If only intramucosal cancer in the margins, decision should be individualized</p> <p>If SM cancer area not in the margins (allowing full evaluation of the SM cancer area) decision should be individualized</p>	<ul style="list-style-type: none"> ▪ Complete staging is recommended (if malignant) ▪ Endoscopy and biopsies 3–6 months after ESD and until no recurrence confirmed ▪ If recurrence and if possible, endoscopic re-treatment preferred over other treatments

► **Table 2** (Continuation)

	Endoscopic	Pathological	Notes	Management
High risk (noncurative) resection LNM risk > 3 %	Incomplete ER If complete at least one of pathological criteria must apply	<ul style="list-style-type: none"> ▪ Cancer and at least one of these criteria must apply: <ul style="list-style-type: none"> – sm2/sm3 invasion – Undifferentiated – V1 – L1 – VM1 (R1) – Budding 2/3 (colorectal) ▪ sm1 or UL1 gastric cancer and: <ul style="list-style-type: none"> – > 3 cm 	If complete ER most patients will, nevertheless, be cured	<ul style="list-style-type: none"> ▪ Complete staging is mandatory ▪ Multidisciplinary team decision recommended ▪ Strong consideration for adjuvant treatments (surgery and/or CRT in esophageal SCC and rectum) recommended
			LV1 is the most important risk factor for LNM (20%–30% risk) and the strongest indication for adjuvant treatment	
			If sm2 is the only high risk criterion present then in some scenarios (old and unfit patients; rectal location) the risk of further therapy might be higher than that of surveillance alone	

CRT, chemoradiotherapy; ER, endoscopic resection; ESD, endoscopic submucosal dissection; HM, horizontal margin; L, lymphatic invasion; LNM, lymph node metastasis; LV1, lymphovascular invasion; SCC, squamous cell cancer; SM, submucosal; UL, ulcerated; V, vascular invasion; VM, vertical margin.

¹ sm1 cancer: tumor invasion ≤ 200 μm (SCC), ≤ 500 μm (Barrett's and gastric), and ≤ 1000 μm (colon); all other criteria must apply to consider ER as a low risk resection.

² Expanded indication, individualized decision; all other criteria must apply to consider ER as a low risk resection.

(95%CI 2%–4%) after achieving CRIM and 6% (95%CI 0%–16%) after achieving CRD only [173]. Based on these studies ESGE suggests complete ablation of all of the Barrett's mucosa after ER.

5.3 Stomach lesions

RECOMMENDATION

20 ESGE recommends that an en bloc R0 resection of a superficial gastric lesion with histology no more advanced than intramucosal cancer, well to moderately differentiated, with no lymphovascular invasion, should be considered a very low risk (curative) resection, independently of size if without ulceration or of lesions ≤ 30 mm if ulcerated; and no further staging procedure or treatment is generally recommended.

Strong recommendation, moderate quality evidence.

RECOMMENDATION

21 ESGE suggests that an en bloc R0 resection of a ≤ 30 mm gastric adenocarcinoma, with superficial submucosal invasion (sm1), that is well to moderately differentiated and with no lymphovascular invasion and no ulcer, should be considered a low risk (curative) resection, and no further treatment is generally recommended.

Weak recommendation, moderate quality evidence.

However, in these cases there is a real (albeit low) risk of LNM and complete staging is recommended with the risk from further therapy (surgery) being balanced against the risk of LNM, in a multidisciplinary discussion.

Weak recommendation, moderate quality evidence.

RECOMMENDATION

22 ESGE suggests that an en bloc R0 resection of a ≤ 20 mm gastric intramucosal poorly differentiated carcinoma, with no lymphovascular invasion or ulcer, should be considered a low risk (curative) resection and no further treatment is generally recommended.

Weak recommendation, moderate quality evidence.

However, in these cases there is a real (albeit low) risk of LNM and complete staging is recommended with the risk from further therapy (surgery) being balanced against the risk of LNM, in a multidisciplinary discussion.

Weak recommendation, moderate quality evidence.

RECOMMENDATION

23 ESGE recommends that a resection of a > 30 mm gastric adenocarcinoma with superficial submucosal invasion (sm1) or with ulceration should be considered a high risk (noncurative) resection, and complete staging should be done and strong consideration for additional treatments (surgery) should be given, on an individual basis in a multidisciplinary discussion.

Strong recommendation, moderate quality evidence.

Overall, intramucosal adenocarcinomas (pT1a) have a 2%–5% incidence of LNM, while in submucosally invasive adenocarcinoma (pT1b) this risk increases to 10%–25%. However, if certain histological characteristics are met, the risk of LNM is null or minimal. This led to the proposal of criteria for curative ER,

based on three landmark studies that correlated lesion characteristics with the presence of LNM in gastrectomy specimens [174–176]. Since the publication of the first edition of this guideline, several studies have evaluated the oncological safety of endoscopic treatment. Studies have also compared the outcomes of endoscopic and surgical treatment in lesions meeting curative criteria, confirming that 5-year OS and DSS are similar between the two treatment approaches [105].

Extensive research conducted in recent years confirms that deep submucosal invasion, undifferentiated histology, size ≥ 30 mm, and lymphovascular invasion are independent risk factors for LNM, reinforcing the value of the proposed criteria for curative resection. However, some recent studies also show LNM rates for expanded criteria resections that are higher than previously reported. Of note, although the risk of LNM is almost null in Japanese studies, in studies outside of Japan this risk is higher (though still less than 4%), which may be related to differences in specimen handling [177]. It is also important to note that to date there is no convincing evidence that other independent risk factors can be used to better stratify LNM risk and refine curativeness criteria. Nevertheless, single studies have found some factors independently associated with LNM, namely: mucinous adenocarcinoma [178], muscularis mucosae invasion [179] and perineural invasion in pT1a lesions [180], submucosal invasion width >4 mm [181], and the ratio of submucosal invasion width to superficial tumor size being greater than 0.04 [182]. A meta-analysis also did not find differences in LNM rates if a submucosal invasion depth of ≤ 300 μ m was used as a cutoff as opposed to ≤ 500 μ m [177].

Taking all the above into account, the following criteria for curativeness of resection should guide management:

- a) **Curative/very low risk resection (LNM risk $<0.5\%$ – 1%):** En bloc R0 resection; dysplastic/pT1a, differentiated lesion, no lymphovascular invasion, independent of size if no ulceration and ≤ 3 cm if ulcerated.
- b) **Curative/low risk resection (LNM risk $<3\%$):** En bloc R0 resection; lesion with no lymphovascular invasion and:
 - pT1a, predominant type is poorly differentiated or undifferentiated, size ≤ 2 cm, no ulceration; and
 - pT1b, invasion ≤ 500 μ m, differentiated, size ≤ 3 cm.
- c) **Local-risk resection (very low risk of LNM but increased risk of persistence/recurrence):**
 - Piecemeal resection or tumor-positive horizontal margin of a lesion otherwise meeting curative/very low risk criteria;
 - Provided that there is no submucosally invasive tumor at the resection margin: piecemeal resection or tumor-positive horizontal margin; pT1b; invasion ≤ 500 μ m; well-differentiated; size ≤ 3 cm; VM0.
- d) **High risk resection (noncurative):** Any lesion with any of the following:
 - positive vertical margin;
 - lymphovascular invasion;
 - deep submucosal invasion (>500 μ m from the muscularis mucosae);
 - ulceration or size >2 cm, in poorly differentiated lesions;

- size >3 cm in pT1b differentiated lesions with submucosal invasion <500 μ m, or in intramucosal ulcerative lesions.

It is also important to note that some other factors may also influence LNM risk, namely a papillary component, perineural invasion, and budding. Papillary adenocarcinoma is associated with worse short-term outcomes – higher rates of incomplete resection, submucosal invasion, and lymphovascular invasion, and thus lower rates of curative resection – but it does not have a proven independent prognostic value in lesions that meet curative criteria [183,184]. Perineural invasion is very rare in the absence of lymphatic or vascular involvement. But at present there is no convincing evidence that these three features should be included in risk stratification and management strategies.

There is also some debate on how to handle mixed-type adenocarcinomas since some studies with gastrectomy specimens found a higher risk of LNM in tumors with histological heterogeneity, even when compared with undifferentiated-type tumors [185–188]. However the prognostic value of this feature does not seem to apply in intramucosal lesions that meet curability criteria [189], and thus definitive conclusions cannot be drawn. Thus, we recommend classifying tumors according to the quantitatively predominant component ($>50\%$) into differentiated-type (which includes papillary and tubular adenocarcinoma) or undifferentiated-type (which includes poorly differentiated, signet ring cell, and mucinous adenocarcinoma if T1b). However the issue of the prognostic significance of histological heterogeneity, specifically in lesions meeting curability criteria deserves further evaluation.

It should be noted that after a high risk ER, even though surgery should always be an option, some patients who refuse surgery may have a similar prognosis to those who proceed to surgery, and this has been shown in both Eastern [190,191] and Western countries [192].

It is clear that the risk of LNM differs according to histopathological features, and that surveillance can be a better option if surgical risk exceeds LNM risk. In this context, the e-Cura scoring system has been proposed. Patients are assigned into three risk categories depending on histopathological features. The score gives 3 points for lymphatic invasion, and 1 point each for tumor size >30 mm, sm2 status, venous invasion, and positive vertical margin, and has been validated as an important decision tool after noncurative ER [193,194]. However, it is important to stress that if LNM or distant metastasis occurs, the prognosis is generally dismal, with palliative chemotherapy or best supportive care being the treatment in the majority of the cases [190]. Thus in a multidisciplinary discussion patients considering surveillance instead of surgery should be informed that, even though the absolute risk of LNM or distant metastasis is low, if it should occur, the prognosis is poor.

Regarding the issue of resection with nonevaluable or positive horizontal margins (HMx/HM1), a meta-analysis showed that the risk of persistent disease was, respectively, 10% or 36%, with no increased risk of LNM [195]. A study showed that the risk of recurrence after resection with a positive horizontal margin, which was 30% with observation only, could be

reduced to 11% when another endoscopic treatment was done as soon as 3 months after resection even when no clear lesion was seen [196].

Taking all this into account, an individualized decision for one of the following options, that balances recurrence and surgical risk, can be considered adequate: close observation, with scar biopsies taken at least in the first follow-up endoscopy; or for coagulation/ablation or re-ESD, namely resection of the ESD scar and/or coagulation of the scar before recurrence occurs; or for surgery. Given the poorer safety profile of surgery, it seems reasonable to reserve that option to endoscopically nontreatable recurrence. In the other cases, close endoscopic observation or an early endoscopic re-treatment (beginning within 3–6 months of the index ER) appear safe strategies. This scenario is considered an eCura C-1 resection in the Japanese Gastric Cancer Association guideline, and this suggested management is similar to the one recommended in that guideline [197].

5.4 Duodenal and small-bowel lesions

RECOMMENDATION

24 ESGE suggests that, given the lack of evidence, the same post-resection criteria as in the colon should apply to the management of duodenal and small-bowel lesions, on an individual basis and with a multidisciplinary approach.

Weak recommendation, very low quality evidence.

Low and high risk resections are not defined in the case of duodenal or small-bowel lesions. For nonampullary duodenal neoplasia, the risk of LNM in the case of intramucosal carcinoma seems negligible [198], and the risk remains unknown in the case of submucosal invasion [199] with few cases reported. The rare cases of duodenal adenocarcinoma with submucosal invasion have been sent to surgery but the LNM status found at those surgeries is not known [122]. In the case of tumor-free margins, the recurrence rate has been 0% in most series [122]. In the case of non-free margins (with data from piecemeal resections), the risk of recurrence is not null, with studies showing large discrepancies from 1.2% [200] to 20.4% in a recent prospective study [201], and with most recurrences allowing further endoscopic treatment. Data on submucosal invasion with lymphovascular invasion, budding, or undifferentiated types are not reported in the literature. In fact, we do not know the risk of distant metastasis and LNM in the case of T1 duodenal adenocarcinoma with submucosal invasion.

Given this absence of data, and the morbidity and mortality of duodenal surgery, ESGE suggests that a decision for surgery should be based on the same criteria as in the colon, in a multidisciplinary team discussion.

5.5 Colorectal lesions

RECOMMENDATION

25 ESGE recommends that an en bloc R0 resection of a colorectal lesion with histology no more advanced than intramucosal adenocarcinoma, well to moderately differentiated with no lymphovascular invasion, should be considered a very low risk (curative) resection and no further staging procedure or treatment is generally recommended.

Strong recommendation, high quality evidence.

RECOMMENDATION

26 ESGE recommends that an en bloc R0 resection of a colorectal lesion with superficial submucosal invasion (sm1), that is well to moderately differentiated and with no lymphovascular invasion and no grade 2 or 3 budding, should be considered a low risk (curative) resection, and no further treatment is generally recommended.

Strong recommendation, high quality evidence.

RECOMMENDATION

27 ESGE suggests that after an en bloc R0 resection of a rectal lesion meeting the single high risk criterion of submucosal invasion deeper than sm1 (well to moderately differentiated with no lymphovascular invasion and no grade 2 or 3 budding), CRT and/or surveillance might be preferred over surgery on an individual basis in a multidisciplinary approach.

Weak recommendation, very low quality evidence.

Several studies and meta-analyses investigated risk factors for LNM. A meta-analysis that included 13 cohort studies with 7066 patients who only underwent radical surgery, showed that there is a significant risk of LNM with the following: submucosal invasion, that is $\geq sm2$ or $\geq 1000\mu m$ (OR 3.00, 95%CI 1.36–6.62; $P=0.007$); vascular invasion (OR 2.70, 95%CI 1.95–3.74; $P<0.001$); lymphatic invasion (OR 6.91, 95%CI 5.40–8.85; $P<0.001$); poorly differentiated carcinoma (OR 8.27, 95%CI 4.67–14.66; $P<0.001$); or tumor budding (OR 4.59, 95%CI 3.44–6.13; $P<0.001$) [202]. This study confirmed the results of a previous meta-analysis [203]. However, the risks of each of these factors may not be equivalent.

Isolated depth of invasion of $>1000\mu m$ in the submucosa is not a consistent independent risk factor in several studies. By itself it is probably not a strong risk factor for LNM, and how much weight to give it in decision-making about further revision surgery after ER is debatable [204]. However, it should be noted that even though in this last-mentioned study submucosal invasion was not considered an independent risk factor ($P=0.075$), the risk of LNM was 6% in the absence of the independent risk factors; a risk that might be considered higher than

the surgical risk. In fact, another study evaluating ER specimens does show by multivariate analysis that a depth of submucosal invasion $\geq 1000\ \mu\text{m}$ is an independent risk factor for LNM (OR 5.56, 95%CI 2.14–19.10) [205]. This is contradicted by a recent study that suggests that when no other risk factors are present choosing a cutoff depth of submucosal invasion of $>1900\ \mu\text{m}$ may help to reduce the incidence of unnecessary surgery after ER [206]. However, a recently published meta-analysis including 16 observational studies and 10181 patients confirmed submucosal invasion of at least $1000\ \mu\text{m}$ as a risk factor for LNM (OR 3.53, $P < 0.001$) [207].

A positive vertical margin after ER has also been associated with local recurrence, LNM, and rescue surgery. In a recent study evaluating risk factors for an adverse prognosis after ER of T1 tumors, the variables related to surgical rescue were piecemeal resection (OR 4.48, 95%CI 1.48–13.6), infiltrated/nonevaluable resection border (OR 7.44, 95%CI 2.12–26.0), not well-differentiated histology (OR 4.76, 95%CI 1.07–20.0), vascular infiltration (OR 8.24, 95%CI 2.72–25.0), and Haggitt 4 infiltration of the submucosa (OR 5.68, 95%CI 2.62–12.3). Residual disease after ER was associated with infiltrated/nonevaluable resection border (OR 34.9, 95%CI 4.08–298), not well-differentiated histology (OR 6.67, 95%CI 1.05–50.0), and vascular infiltration of the submucosa (OR 7.61, 95%CI 1.55–37.4) [208]. So, clearly a positive vertical margin is a risk factor for residual disease and need for additional surgery and potential for LNM, as suggested by the study of Boenicke et al. This showed that in patients who underwent ER of malignant polyps followed by surgery, even though 63% of resection margins were positive (a free margin was not defined as a tumor-free extent of more than 1 mm), subsequent surgical specimens showed residual carcinoma in only 2.8% but LNM in 7.6% [209]. What should be considered a positive vertical margin is, however, a matter of discussion (see section on **Pathological aspects**).

Perineural invasion was also demonstrated to be a risk factor of LNM in T1 colorectal cancer. However, there is not sufficient evidence to conclude that it has an independent role or to make any recommendation regarding perineural invasion per se [204].

Similarly to the other organs the importance of positive horizontal margins seems low in the colon, with recurrence rates after en bloc ER being as low as 2.2% when the size of the positive invaded margins is small ($< 8\ \text{mm}$) [210]. In contrast, piecemeal resection at ESD is associated with a higher risk of recurrence, reaching 15.2% compared with 5.1% for en bloc resections with positive margins or 2.2% in the case of indeterminate margins [211]. Those recurrence rates are significantly higher than the risk of recurrence after R0 resection with free margins, evaluated to be null [212]. In all these studies a positive horizontal margin was not associated with LNM risk and so, in the absence of histological high risk factors, a “wait-and-see” policy is justified [213].

With all the above in mind, it is the present authors' opinion that a more extensive resection accompanied by a lymph node dissection is necessary in most patients with resected T1 colorectal cancer with nonpedunculated $\geq \text{sm}2$ (submucosal

$\geq 1000\ \mu\text{m}$) invasion, lymphovascular invasion, poorly differentiated carcinoma, grade 2 or 3 tumor budding, or positive vertical margin. Nevertheless, we recognize that for some patients, if the only high risk criterion is $\geq \text{sm}2$ tumor, particularly in the rectum, the risk of surgery may be similar to the risk of LNM, and surveillance could be an option. Even though, as shown in a recently published meta-analysis [207], rectal location may be a risk factor for LNM (OR 1.36, $P = 0.003$), the surgical options are also more aggressive than in the colon (and may imply abdominoperineal amputation) with mortality and severe morbidity rates as high as 3% and 15%, respectively [214, 215]. Moreover, in patients with high risk pT1 rectal cancer after local excision, CRT has been shown to be a safe and effective treatment alternative to revision radical resection [216, 217]. Therefore, even though based on a low level of evidence, it is the present authors' opinion that after an en bloc R0 resection of a rectal lesion, when the single high risk criterion is submucosal invasion deeper than $\text{sm}1$ (i.e., the lesion is well to moderately differentiated with no lymphovascular invasion and no grade 2 or 3 budding), surveillance and/or CRT might be preferred over surgery on an individual basis in a multidisciplinary discussion.

5.6 All organs

RECOMMENDATION

28 ESGE recommends that after an endoscopic complete resection, if there is a positive horizontal margin or if resection is piecemeal but there is no submucosal invasion and no other high risk criteria are met, this should be considered a local-risk resection and endoscopic surveillance/re-treatment is recommended rather than surgery or other additional treatment.
Strong recommendation, moderate quality evidence.

As we have seen, independently of the organ (see above evidence for each organ), when complete, a resection that is piecemeal or with positive/nonevaluable horizontal margins (Rx resection), with no other poor prognosis features (including with no submucosal invasion at the margins), does not per se have an increased risk of LNM or distant metastasis [195, 201, 213]. However, in these cases, the risk of local persistence/recurrence may be as high as 30% and for this reason, such a resection should be considered a local-risk resection. Since many of these recurrences are amenable to further endoscopic treatment, it is the present authors' opinion that endoscopic surveillance or re-treatment are better initial options than surgery or other additional treatment (with these being considered if endoscopic re-treatment is not possible or fails) [196, 201].

RECOMMENDATION

29 ESGE recommends that when there is a diagnosis of lymphovascular invasion or deeper infiltration than sm1 or positive vertical margins or undifferentiated tumor or, for colorectal lesions, grade 2 or 3 budding, that the resection should be considered a high risk (noncurative) resection; complete staging should be done and strong consideration for additional treatments (chemoradiotherapy and/or surgery) should be given, on an individual basis in a multidisciplinary discussion.
Strong recommendation, moderate quality evidence.

Again, independently of the organ (see above), the poor prognostic features are the same: undifferentiated tumor, lymphovascular invasion, deep submucosal invasion, tumor budding in the colon, or a positive vertical margin, when carcinoma is present [148, 149, 168, 169, 197, 202]. In these cases, even though many patients will have no residual disease, the global LNM risk is potentially higher than the risk of further treatment. So, when one of these features is present, the ER should be considered a high risk (noncurative) resection. Complete staging should be done and strong consideration for additional treatments should be given on an individual basis, in a multidisciplinary discussion. Nevertheless, it should be noted that all these poor prognostic features do not carry the same weight, and the risk for LNM increases with the number of risk factors (with lymphovascular invasion being the strongest and deep submucosal invasion the weakest predictor for LNM). This should be taken into account in the multidisciplinary decision-making, recognizing that surveillance may be an option in some scenarios, particularly in old and unfit patients.

6 Surveillance after endoscopic resection

6.1 Endoscopic surveillance

RECOMMENDATION

30 ESGE recommends scheduled endoscopic surveillance with high definition white-light and chromoendoscopy (virtual or dye-based) with biopsies of only the suspicious areas after a curative ESD.
Strong recommendation, moderate quality evidence.

In general, close surveillance after ER is needed to detect local recurrences and metachronous lesions, since ER leaves a larger area of mucosa than does surgery and the risk of new lesions may be as high as 1%–5% per year, justifying scheduled endoscopic surveillance in every organ. As we have seen, CE increases detection, allows better characterization of lesions, can guide biopsies of irregular areas, and should be used routinely after ESD [218]. Since after a curative/R0 resection the risk of

recurrence is consistently lower than 1%–2%, routine biopsies of the ESD scar are not recommended.

The question of when to stop endoscopic surveillance has not been answered, since the majority of studies show a steady increase of metachronous lesions over time (older patients being especially at higher risk), and so the benefit of discovering or treating an early lesion should be balanced against age, comorbidities, and life-expectancy. In conclusion, the decision to stop surveillance should be individualized.

RECOMMENDATION

31 ESGE recommends that after piecemeal resection or in the presence of positive lateral margins when criteria for additional treatment are not met, a high definition chromoendoscopy (virtual and/or dye-based) with biopsies is recommended at 3–6 months.
Weak recommendation, low quality evidence.

As we have seen, in all cases and organs, the presence of horizontal margins that are positive or nonevaluable (HM1/HMx) increases local recurrence rates, with the recurrences most of the time being amenable to further endoscopic treatment if diagnosed early. In these cases, we suggest at least two endoscopies/colonoscopies with biopsies in the first 12–18 months (the first in the first 3–6 months after ER and the second depending on the organ and on the result of the first). After the first endoscopy without histologically confirmed recurrence, we then recommend the same surveillance protocol as for curative resections.

RECOMMENDATION

32 For upper GI superficial lesions, ESGE suggests endoscopy at 3–6 months and then annually after a curative ESD resection or after a local-risk ESD resection without recurrence.
Weak recommendation, low quality evidence.

6.1.1 Esophageal SCC lesions

In a recent Western report on long term follow-up after ER, the recurrence rate was 23.7% (19/80) in the endoscopic mucosal resection (EMR) group and 2.9% (2/68) in the ESD group ($P=0.002$). The median follow-up time before recurrence was 4 months (range 2–23 months), suggesting early follow-ups (at 3–6 months) and then annually [71]. Some new studies confirmed the need for close surveillance stated in the previous ESGE guideline of 2015. Even though some risk factors for recurrence have been described, such as male sex, alcohol consumption, smoking, and others, there is insufficient evidence to suggest different follow-up in these cases [219–222]. A large trial in 886 specimens found 5% had positive/nonevaluable horizontal tumor margins (HM1/HMx), with a 26.7% recurrence

rate. HM1/HMx lesions with less than 1 mm between the cancer and specimen edge were associated with substantial risk of local recurrence, and strict follow-up is recommended in these cases [223].

6.1.2 BE-associated lesions

Recurrence of intestinal metaplasia (IM) and dysplasia occurs even after complete ablation of the entire BE segment and therefore surveillance should be performed after therapy [82, 173]. It is recommended that biopsies should be taken during surveillance endoscopy at the esophagogastric junction (EGJ) and within the extent of the previous BE.

In a recent publication Cotton and co-workers built and validated a model to predict the incidence of neoplasia recurrence after initially successful RFA [224]. They used data from the United States Radiofrequency Ablation Registry and the United Kingdom National Halo Registry. According to this model, surveillance endoscopies for patients with high grade dysplasia or intramucosal adenocarcinoma should be performed at 3, 6, and 12 months and then annually, resulting in detection of unresectable cancers during surveillance at rates of less than 1/1000 endoscopies.

6.1.3 Stomach

After a curative ER, the risk of LNM is low or very low, but there is a very low risk of recurrence and a moderate risk of metachronous lesions during follow-up (10%–20%) [192, 225–231]. There is evidence that *Helicobacter pylori* eradication decreases the risk of metachronous lesions and thus eradication is recommended if the patient has active *H. pylori* infection [232]. No other strategies showed benefit in decreasing risk of metachronous lesions, but there is consistent evidence that older patients and patients with synchronous or multiple lesions at diagnosis and/or with extensive preneoplastic conditions are at higher risk [192, 225–231]. However, to date there are no data showing that these risk factors should influence surveillance intervals. Most centers perform an endoscopy 3–6 months after ESD and then annually for at least 5 years. Indeed, a study found that a surveillance interval > 12 months was associated with significantly larger and more advanced metachronous lesions, and a significantly higher proportion needed surgical treatment when compared with metachronous lesions in patients with surveillance intervals ≤ 12 months [233].

6.1.4 Colorectal lesions

RECOMMENDATION

33 ESGE suggests colonoscopy at 12 months and then further surveillance in accordance with polypectomy and colorectal cancer guidelines, after a local-risk ESD resection without recurrence or after a low or very low risk (curative) ESD of a colorectal malignant lesion. Weak recommendation, low quality evidence.

After a curative resection for T1 colorectal carcinoma, the risk of local and distant recurrences seems negligible [234, 235]. Local recurrences were found to be 0.7% at 2 years after curative treatment in 3278 patients with CRC who warranted adjuvant treatment (the majority because of N+ disease) [236]. However, the same study showed that the incidence of a second primary CRC was as high as 1.5% at 5 years [236]. From these results, Hassan et al. showed that 1-year surveillance colonoscopy was then cost-effective, allowing lesions to be found at an earlier stage than the previously recommended colonoscopy at 3 years [237].

Hence, there is no clear evidence to inform decisions on optimal post-ESD surveillance. If ESD had been performed for a good indication then it is predictable that the resected lesion will be high risk or malignant. Most authors recommend follow-up endoscopy in the first year after resection in order to verify complete removal and exclude synchronous/metachronous lesions. If technical success is confirmed, ESGE then recommends further surveillance in accordance with polypectomy and colorectal cancer surveillance guidelines [238, 239].

6.2 Other surveillance methods

RECOMMENDATION

34 ESGE does not suggest routine use of EUS, MRI, CT, or PET in the follow-up after a very low or low risk (curative) endoscopic resection, but this might be considered in the cases of T1a-m3/T1b-sm1 esophageal SCC particularly if no additional treatment has been decided. Weak recommendation, very low quality evidence.

Since the risk of LNM after a curative resection is very low (in most cases and organs < 1%–3%), there is no evidence to suggest routine radiological surveillance in these cases. The exception might be after ER of T1a-m3/T1b-sm1 esophageal SCCs since, as we have seen, the natural history of these tumors is not clearly defined.

7 Pathological aspects

A complete discussion of pathological issues and the definitions are provided in **Appendix 2s** (Pathology and definitions). ESGE recommends that patients who undergo ESD because of malignant lesions are treated by multidisciplinary teams, with the following recommendations for management, based on endoscopic and pathology reports as detailed in ► **Table 2**.

In this update of the ESD guideline, we considered four levels of risk related to ER, including two levels of “curative” ER based on different levels of LNM risk.

a) **Very low risk resection.** In this case the risk of LNM is almost null and lower than 0.5% (global LNM risk should not be higher than 1%). In general, this applies to en bloc, R0 resection of dysplasia/pT1a cancers, that are differentiated with no lymphatic and no vascular invasion (L0 and V0). In

these cases, the risk of local or distant recurrence is almost nonexistent, and only endoscopic surveillance is recommended with no further staging method or treatment.

- b) **Low risk resection.** In these cases the risk of LNM is generally very low and lower than 2% (global LNM risk should be lower than 3%). In general, this applies to en bloc, R0 resection of T1b-sm1 cancers that are differentiated, L0 and V0, and with other organ-specific characteristics. The risk of distant recurrence is low, and lower than the risks of further therapy. Although additional treatments are generally not recommended they can be considered in specific patients and scenarios, to further decrease the risk of LNM. However in all these cases, even though ER is considered “curative,” complete staging is recommended since these lesions represent true malignant disease.
- c) **Local risk resection.** This category includes piecemeal resection or where the horizontal margin is positive or unassessable (HM1 or HMx; thus Rx resection) and with no poor prognostic features for distant metastasis (including no submucosal invasion at the margins). In these cases, the risk of LNM is almost null, but the risk of local persistence/recurrence may be as high as 30% and a stricter endoscopic surveillance (and/or treatment) is recommended.
- d) **High risk resection (“noncurative”).** This includes R0 or Rx ERs but with at least one poor prognostic feature (poor differentiation, lymphovascular invasion, deep submucosal invasion, tumor budding in the colon); or R1 resection (implying a positive vertical margin [VM1]), when carcinoma is present. In these cases, even though most patients will have no residual disease, the global LNM risk is higher than 3% and in general this risk is higher than the risk of further treatment. Complete staging and additional nonendoscopic treatments are recommended in these cases (although surveillance may be an option in old and unfit patients).

It is important to note that most of this evidence comes from retrospective studies based on surgical specimens that may not have been pathologically handled and analyzed in the same manner as ER specimens. Furthermore, organ-specific considerations should be taken into account when deciding the type of ER and further decisions (see above).

Regarding what should be considered a safe VM (for more details, see **Appendix 2s**), this issue is highly controversial, particularly as regards the colon since in the other organs this is rarely reported. For the colon most Western societies recommend that a safe margin should be ≥ 1 mm [239,240]. But in fact, no validated data are available on the size of the safety margin after ER, which is why it is not mentioned in Asian guidelines [35]. In the largest meta-analysis that evaluated pathologic factors for LNM in early colorectal cancer, no increased risk was observed for a positive margin (OR 1.44, 95%CI 0.52–4.03) [202]. Moreover, in the study that most societies use to justify the 1 mm margin, residual invasive disease in the colon wall was noted in 16% with < 1 mm polypectomy margin, in 21% with an indeterminate margin, and in 0% with a margin ≥ 1 mm ($P=0.009$), but this was not a risk factor for LNM [241]. Another study showed that although 63% of resection margins were

not deemed tumor-free, subsequent surgical specimens showed residual carcinoma in only 2.8% of all patients but LNM in 7.6%. However, in this study a free margin was not defined as a tumor-free extent of more than 1 mm; instead the resected specimen was only considered positive if there was lesion at the margin (R1) or limited assessability due to coagulation artefacts (Rx) [209].

Therefore, we believe that there is no evidence supporting the concept that a tumor-free margin of extent less than 1 mm should be considered a positive margin and, consequently, an indication for surgery. However, we recognize that smaller margins may increase the risk of persistent local disease (that can be recognized in the surveillance endoscopies). Therefore, in the present Guideline ESGE recommends the use of the term “preferably 1 mm,” but if the margin is smaller than 1 mm but free of tumor this should have no consequences for the clinical routine other than a stricter follow-up.

Disclaimer

The legal disclaimer for ESGE guidelines [5] applies to this Guideline.

Acknowledgments

The authors are grateful to Dr. Cesare Hassan, Humanitas University, Rozzano, Milan, Italy, and Dr. Enrique Rodriguez de Santiago, Hospital Univesitario Ramón y Cajal, Madrid, Spain, for their review of the Guideline.

Competing interests

P. Bhandari provides consultancy to Boston Scientific (2018–2022); his department has received research grants from Olympus UK (2019–2022), Fujifilm Europe (2019–2022), 3-D Matrix (2019–2022), and NEC Japan (2018–2022). M.J. Bourke has received research support from Boston Scientific, Olympus, and Cook Medical (2016 to 2022, ongoing). P.H. Deprez has received lecture fees from Olympus (2010–2021) and Erbe (2010–2020). M. Dinis Ribeiro is Co-Editor-in-Chief of *Endoscopy*; he has provided consultancy to Medtronic (2021) and Roche (2022); his department has received a research grant (loan) from Fujifilm (2021–2022). A. Lemmers has received consultancy fees from Cook Endoscopy (2021); his department receives a research grant from Boston Scientific (2021–2023). R. Maselli has provided consultancy to Erbe Medical (2018 to present); her department has received consultancy from Fujifilm (2018 to present). O. Pech has received speaker’s honoraria from Medtronic, Boston Scientific, Fujifilm, and Olympus (over 5 years). M. Pioche has provided consultancy and training for Olympus, Pentax, Cook, and Norgine (2017–2022). J.E. van Hooft’s department has received research grants from Cook Medical (2014–2019) and Abbott (2014–2017); she has received lecture fees from Medtronics (2014–2015, 2019), Cook Medical (2019), and Abbvie (2021), and consultancy fees from Boston Scientific (2014–2017) and Olympus (2021). B.L.A.M. Weusten has received financial support for IRB-approved studies from Pentax Medical (2017–2022), and financial research support from Aqua Medical (2020–2022), and has provided consultancy to Pentax Medical (2021–2022). D. Libânio, B.A.J. Bastiaansen, R. Bisschops, G. Espósito, H. Messman, P. Pimentel-Nunes, and M. Vieth have no competing interests.

References

- [1] Pimentel-Nunes P, Dinis-Ribeiro M, Ponchon T et al. Endoscopic submucosal dissection: European Society of Gastrointestinal Endoscopy (ESGE) Guideline. *Endoscopy* 2015; 47: 829–854
- [2] Veitch AM, Vanbiervliet G, Gershlick AH et al. Endoscopy in patients on antiplatelet or anticoagulant therapy, including direct oral anti-coagulants: British Society of Gastroenterology (BSG) and European Society of Gastrointestinal Endoscopy (ESGE) guidelines. *Endoscopy* 2016; 48: 385–402
- [3] Pimentel-Nunes P, Pioche M, Albeniz E et al. Curriculum for endoscopic submucosal dissection training in Europe: European Society of Gastrointestinal Endoscopy (ESGE) Position Statement. *Endoscopy* 2019; 51: 980–992
- [4] Atkins D, Eccles M, Flottorp S et al. Systems for grading the quality of evidence and the strength of recommendations I: critical appraisal of existing approaches The GRADE Working Group. *BMC Health Serv Res* 2004; 4: 38
- [5] Hassan C, Ponchon T, Bisschops R et al. European Society of Gastrointestinal Endoscopy (ESGE) Publications Policy – Update 2020. *Endoscopy* 2020; 52: 123–126
- [6] Endoscopic Classification Review Group. Update on the Paris classification of superficial neoplastic lesions in the digestive tract. *Endoscopy* 2005; 37: 570–578
- [7] Dekker E, Houwen B, Puig I et al. Curriculum for optical diagnosis training in Europe: European Society of Gastrointestinal Endoscopy (ESGE) Position Statement. *Endoscopy* 2020; 52: 899–923
- [8] Morita FH, Bernardo WM, Ide E et al. Narrow band imaging versus lugol chromoendoscopy to diagnose squamous cell carcinoma of the esophagus: a systematic review and meta-analysis. *BMC Cancer* 2017; 17: 54
- [9] Gruner M, Denis A, Masliah C et al. Narrow-band imaging versus Lugol chromoendoscopy for esophageal squamous cell cancer screening in normal endoscopic practice: randomized controlled trial. *Endoscopy* 2021; 53: 674–682
- [10] Costa-Santos MP, Ferreira AO, Mouradides C et al. Is Lugol necessary for endoscopic resection of esophageal squamous cell neoplasia? *Endosc Int Open* 2020; 8: E1471–E1477
- [11] Yu T, Geng J, Song W et al. Diagnostic accuracy of magnifying endoscopy with narrow band imaging and its diagnostic value for invasion depth staging in esophageal squamous cell carcinoma: a systematic review and meta-analysis. *Biomed Res Int* 2018; 2018: 8591387
- [12] Oyama T, Inoue H, Arima M et al. Prediction of the invasion depth of superficial squamous cell carcinoma based on microvessel morphology: magnifying endoscopic classification of the Japan Esophageal Society. *Esophagus* 2017; 14: 105–112
- [13] Fujiyoshi T, Tajika M, Tanaka T et al. Comparative evaluation of new and conventional classifications of magnifying endoscopy with narrow band imaging for invasion depth of superficial esophageal squamous cell carcinoma. *Dis Esophagus* 2017; 30: 1–8
- [14] Katada C, Tanabe S, Wada T et al. Retrospective assessment of the diagnostic accuracy of the depth of invasion by narrow band imaging magnifying endoscopy in patients with superficial esophageal squamous cell carcinoma. *J Gastrointest Cancer* 2019; 50: 292–297
- [15] Ueda T, Dohi O, Naito Y et al. Diagnostic performance of magnifying blue laser imaging versus magnifying narrow-band imaging for identifying the depth of invasion of superficial esophageal squamous cell carcinoma. *Dis Esophagus* 2020; doi:10.1093/dote/daaa078
- [16] Pech O, Gossner L, Manner H et al. Prospective evaluation of the macroscopic types and location of early Barrett's neoplasia in 380 lesions. *Endoscopy* 2007; 39: 588–593
- [17] Thomas T, Gilbert D, Kaye PV et al. High-resolution endoscopy and endoscopic ultrasound for evaluation of early neoplasia in Barrett's esophagus. *Surg Endosc* 2010; 24: 1110–1116
- [18] Kandiah K, Chedgy FJQ, Subramaniam S et al. International development and validation of a classification system for the identification of Barrett's neoplasia using acetic acid chromoendoscopy: the Portsmouth acetic acid classification (PREDICT). *Gut* 2018; 67: 2085–2091
- [19] Coletta M, Sami SS, Nachiappan A et al. Acetic acid chromoendoscopy for the diagnosis of early neoplasia and specialized intestinal metaplasia in Barrett's esophagus: a meta-analysis. *Gastrointest Endosc* 2016; 83: 57–67.e51
- [20] Sharma P, Bergman JJ, Goda K et al. Development and validation of a classification system to identify high-grade dysplasia and esophageal adenocarcinoma in Barrett's esophagus using narrow-band imaging. *Gastroenterology* 2016; 150: 591–598
- [21] Nogales O, Caballero-Marcos A, Clemente-Sanchez A et al. Usefulness of non-magnifying narrow band imaging in EVIS EXERA III video systems and high-definition endoscopes to diagnose dysplasia in Barrett's esophagus using the Barrett International NBI Group (BING) classification. *Dig Dis Sci* 2017; 62: 2840–2846
- [22] Muto M, Yao K, Kaise M et al. Magnifying endoscopy simple diagnostic algorithm for early gastric cancer (MESDA-G). *Dig Endosc* 2016; 28: 379–393
- [23] Uchida K, Yao K, Uedo N et al. Highest power magnification with narrow-band imaging is useful for improving diagnostic performance for endoscopic delineation of early gastric cancers. *BMC Gastroenterol* 2015; 15: 155
- [24] Makazu M, Hirasawa K, Sato C et al. Histological verification of the usefulness of magnifying endoscopy with narrow-band imaging for horizontal margin diagnosis of differentiated-type early gastric cancers. *Gastric Cancer* 2018; 21: 258–266
- [25] Horii Y, Dohi O, Naito Y et al. Efficacy of magnifying narrow band imaging for delineating horizontal margins of early gastric cancer. *Digestion* 2019; 100: 93–99
- [26] Nakayoshi T, Tajiri H, Matsuda K et al. Magnifying endoscopy combined with narrow band imaging system for early gastric cancer: correlation of vascular pattern with histopathology (including video). *Endoscopy* 2004; 36: 1080–1084
- [27] Ok KS, Kim GH, Park doY et al. Magnifying endoscopy with narrow band imaging of early gastric cancer: Correlation with histopathology and mucin phenotype. *Gut Liver* 2016; 10: 532–541
- [28] Yagi K, Saka A, Nozawa Y et al. Prediction of submucosal gastric cancer by narrow-band imaging magnifying endoscopy. *Dig Liver Dis* 2014; 46: 187–190
- [29] Kikuchi D, Iizuka T, Hoteya S et al. Usefulness of magnifying endoscopy with narrow-band imaging for determining tumor invasion depth in early gastric cancer. *Gastroenterol Res Pract* 2013; 2013: 217695
- [30] Kobara H, Mori H, Fujihara S et al. Prediction of invasion depth for submucosal differentiated gastric cancer by magnifying endoscopy with narrow-band imaging. *Oncol Rep* 2012; 28: 841–847
- [31] Kakushima N, Yoshida M, Yamaguchi Y et al. Magnified endoscopy with narrow-band imaging for the differential diagnosis of superficial non-ampullary duodenal epithelial tumors. *Scand J Gastroenterol* 2019; 54: 128–134
- [32] Takahashi T, Ando T, Kabeshima Y et al. Borderline cases between benignancy and malignancy of the duodenum diagnosed successfully by endoscopic submucosal dissection. *Scand J Gastroenterol* 2009; 44: 1377–1383
- [33] Kobayashi K, Tanaka S, Murakami Y et al. Predictors of invasive cancer of large laterally spreading colorectal tumors: A multicenter study in Japan. *JGH Open* 2020; 4: 83–89

- [34] Bogie RMM, Veldman MHJ, Snijders L et al. Endoscopic subtypes of colorectal laterally spreading tumors (LSTs) and the risk of submucosal invasion: a meta-analysis. *Endoscopy* 2018; 50: 263–282
- [35] Tanaka S, Kashida H, Saito Y et al. Japan Gastroenterological Endoscopy Society guidelines for colorectal endoscopic submucosal dissection/endoscopic mucosal resection. *Dig Endosc* 2020; 32: 219–239
- [36] Hayashi N, Tanaka S, Hewett DG et al. Endoscopic prediction of deep submucosal invasive carcinoma: validation of the narrow-band imaging international colorectal endoscopic (NICE) classification. *Gastrointest Endosc* 2013; 78: 625–632
- [37] Sumimoto K, Tanaka S, Shigita K et al. Clinical impact and characteristics of the narrow-band imaging magnifying endoscopic classification of colorectal tumors proposed by the Japan NBI Expert Team. *Gastrointest Endosc* 2017; 85: 816–821
- [38] Vosko S, Shahidi N, Sidhu M et al. Optical evaluation for predicting cancer in large nonpedunculated colorectal polyps is accurate for flat lesions. *Clin Gastroenterol Hepatol* 2021: doi:10.1016/j.cgh.2021.05.017
- [39] Burgess NG, Hourigan LF, Zanati SA et al. Risk stratification for covert invasive cancer among patients referred for colonic endoscopic mucosal resection: A large multicenter cohort. *Gastroenterology* 2017; 153: 732–742 e731
- [40] Bisschops R, East JE, Hassan C et al. Advanced imaging for detection and differentiation of colorectal neoplasia: European Society of Gastrointestinal Endoscopy (ESGE) Guideline – Update 2019. *Endoscopy* 2019; 51: 1155–1179
- [41] Luo LN, He LJ, Gao XY et al. Endoscopic ultrasound for preoperative esophageal squamous cell carcinoma: A meta-analysis. *PLoS One* 2016; 11: e0158373
- [42] Choi J, Chung H, Lee A et al. Role of endoscopic ultrasound in selecting superficial esophageal cancers for endoscopic resection. *Ann Thorac Surg* 2020; 111: 1689–1695
- [43] Tao Z, Yan C, Zhao H et al. Comparison of endoscopic ultrasonography and magnifying endoscopy for assessment of the invasion depth of shallow gastrointestinal neoplasms: a systematic review and meta-analysis. *Surg Endosc* 2017; 31: 4923–4933
- [44] Mizumoto T, Hiyama T, Oka S et al. Diagnosis of superficial esophageal squamous cell carcinoma invasion depth before endoscopic submucosal dissection. *Dis Esophagus* 2018; 31: doi:10.1093/dote/dox142
- [45] Guo J, Wang Z, Qin J et al. A prospective analysis of the diagnostic accuracy of 3 T MRI, CT and endoscopic ultrasound for preoperative T staging of potentially resectable esophageal cancer. *Cancer Imaging* 2020; 20: 64
- [46] Qu J, Zhang H, Wang Z et al. Comparison between free-breathing radial VIBE on 3-T MRI and endoscopic ultrasound for preoperative T staging of resectable oesophageal cancer, with histopathological correlation. *Eur Radiol* 2018; 28: 780–787
- [47] Nakajima M, Muroi H, Yokoyama H et al. (18)-F-Fluorodeoxyglucose positron emission tomography can be used to determine the indication for endoscopic resection of superficial esophageal cancer. *Cancer Med* 2018; 7: 3604–3610
- [48] Toriyama K, Tajika M, Tanaka T et al. Clinical relevance of fluorodeoxyglucose positron emission tomography/computed tomography and magnifying endoscopy with narrow band imaging in decision-making regarding the treatment strategy for esophageal squamous cell carcinoma. *World J Gastroenterol* 2019; 25: 6767–6780
- [49] Ishihara R, Goda K, Oyama T. Endoscopic diagnosis and treatment of esophageal adenocarcinoma: Introduction of Japan Esophageal Society classification of Barrett's esophagus. *J Gastroenterol* 2019; 54: 1–9
- [50] Bulsiewicz WJ, Dellon ES, Rogers AJ et al. The impact of endoscopic ultrasound findings on clinical decision making in Barrett's esophagus with high-grade dysplasia or early esophageal adenocarcinoma. *Dis Esophagus* 2014; 27: 409–417
- [51] Thota PN, Sada A, Sanaka MR et al. Correlation between endoscopic forceps biopsies and endoscopic mucosal resection with endoscopic ultrasound in patients with Barrett's esophagus with high-grade dysplasia and early cancer. *Surg Endosc* 2017; 31: 1336–1341
- [52] Fairweather M, Jajoo K, Sainani N et al. Accuracy of EUS and CT imaging in preoperative gastric cancer staging. *J Surg Oncol* 2015; 111: 1016–1020
- [53] Chung HW, Kim JH, Sung IK et al. FDG PET/CT to predict the curability of endoscopic resection for early gastric cancer. *J Cancer Res Clin Oncol* 2019; 145: 759–764
- [54] Shi D, Xi XX. Factors affecting the accuracy of endoscopic ultrasonography in the diagnosis of early gastric cancer invasion depth: a meta-analysis. *Gastroenterol Res Pract* 2019; 2019: 8241381
- [55] Lee JY, Choi IJ, Kim CG et al. Therapeutic decision-making using endoscopic ultrasonography in endoscopic treatment of early gastric cancer. *Gut Liver* 2016; 10: 42–50
- [56] Kuroki K, Oka S, Tanaka S et al. Clinical significance of endoscopic ultrasonography in diagnosing invasion depth of early gastric cancer prior to endoscopic submucosal dissection. *Gastric Cancer* 2020: doi:10.1007/s10120-020-01100-5
- [57] Kim EH, Park JC, Song IJ et al. Prediction model for non-curative resection of endoscopic submucosal dissection in patients with early gastric cancer. *Gastrointest Endosc* 2017; 85: 976–983
- [58] Libanio D, Dinis-Ribeiro M, Pimentel-Nunes P et al. Predicting outcomes of gastric endoscopic submucosal dissection using a Bayesian approach: a step for individualized risk assessment. *Endosc Int Open* 2017; 5: E563–E572
- [59] Ma X, Zhang Q, Zhu S et al. Risk factors and prediction model for non-curative resection of early gastric cancer with endoscopic resection and the evaluation. *Front Med (Lausanne)* 2021; 8: 637875
- [60] Yamada T, Shimura T, Ebi M et al. Subset analysis of a multicenter, randomized controlled trial to compare magnifying chromoendoscopy with endoscopic ultrasonography for stage diagnosis of early stage colorectal cancer. *PLoS One* 2015; 10: e0134942
- [61] Chan BPH, Patel R, Mbuagbaw L et al. EUS versus magnetic resonance imaging in staging rectal adenocarcinoma: a diagnostic test accuracy meta-analysis. *Gastrointest Endosc* 2019; 90: 196–203. e191
- [62] Gao Y, Li J, Ma X et al. The value of four imaging modalities in diagnosing lymph node involvement in rectal cancer: an overview and adjusted indirect comparison. *Clin Exp Med* 2019; 19: 225–234
- [63] Li XT, Sun YS, Tang L et al. Evaluating local lymph node metastasis with magnetic resonance imaging, endoluminal ultrasound and computed tomography in rectal cancer: a meta-analysis. *Colorectal Dis* 2015; 17: O129–135
- [64] Li XT, Zhang XY, Sun YS et al. Evaluating rectal tumor staging with magnetic resonance imaging, computed tomography, and endoluminal ultrasound: A meta-analysis. *Medicine (Baltimore)* 2016; 95: e5333
- [65] Nagami Y, Ominami M, Shiba M et al. The five-year survival rate after endoscopic submucosal dissection for superficial esophageal squamous cell neoplasia. *Dig Liver Dis* 2017; 49: 427–433
- [66] Nishizawa T, Suzuki H. Long-term outcomes of endoscopic submucosal dissection for superficial esophageal squamous cell carcinoma. *Cancers (Basel)* 2020; 12: doi:10.3390/cancers12102849
- [67] Oda I, Shimizu Y, Yoshio T et al. Long-term outcome of endoscopic resection for intramucosal esophageal squamous cell cancer: a secondary analysis of the Japan Esophageal Cohort study. *Endoscopy* 2020; 52: 967–975

- [68] Ishihara R, Arima M, Iizuka T et al. Endoscopic submucosal dissection/endoscopic mucosal resection guidelines for esophageal cancer. *Dig Endosc* 2020; 32: 452–493
- [69] Matsueda K, Matsuura N, Kanesaka T et al. Validity of endoscopic resection for clinically diagnosed T1a-MM/T1b-SM1 N0 M0 esophageal squamous cell carcinoma. *Esophagus* 2021; doi:10.1007/s10388-021-00814-4
- [70] Probst A, Aust D, Markl B et al. Early esophageal cancer in Europe: endoscopic treatment by endoscopic submucosal dissection. *Endoscopy* 2015; 47: 113–121
- [71] Berger A, Rahmi G, Perrod G et al. Long-term follow-up after endoscopic resection for superficial esophageal squamous cell carcinoma: a multicenter Western study. *Endoscopy* 2019; 51: 298–306
- [72] Cao Y, Liao C, Tan A et al. Meta-analysis of endoscopic submucosal dissection versus endoscopic mucosal resection for tumors of the gastrointestinal tract. *Endoscopy* 2009; 41: 751–757
- [73] Guo HM, Zhang XQ, Chen M et al. Endoscopic submucosal dissection vs endoscopic mucosal resection for superficial esophageal cancer. *World J Gastroenterol* 2014; 20: 5540–5547
- [74] Zhang Y, Ding H, Chen T et al. Outcomes of endoscopic submucosal dissection vs esophagectomy for T1 esophageal squamous cell carcinoma in a real-world cohort. *Clin Gastroenterol Hepatol* 2019; 17: 73–81.e73
- [75] Min YW, Lee H, Song BG et al. Comparison of endoscopic submucosal dissection and surgery for superficial esophageal squamous cell carcinoma: a propensity score-matched analysis. *Gastrointest Endosc* 2018; 88: 624–633
- [76] An W, Liu MY, Zhang J et al. Endoscopic submucosal dissection versus esophagectomy for early esophageal squamous cell carcinoma with tumor invasion to different depths. *Am J Cancer Res* 2020; 10: 2977–2992
- [77] Yeh JH, Huang RY, Lee CT et al. Long-term outcomes of endoscopic submucosal dissection and comparison to surgery for superficial esophageal squamous cancer: a systematic review and meta-analysis. *Therap Adv Gastroenterol* 2020; 13: 1756284820964316
- [78] Kato H, Sato A, Fukuda H et al. A phase II trial of chemoradiotherapy for stage I esophageal squamous cell carcinoma: Japan Clinical Oncology Group Study (JCOG9708). *Jpn J Clin Oncol* 2009; 39: 638–643
- [79] Murakami Y, Takahashi I, Nishibuchi I et al. Long-term results of definitive concurrent chemoradiotherapy for patients with esophageal submucosal cancer (T1bN0M0). *Int J Clin Oncol* 2015; 20: 897–904
- [80] Nakajo K, Yoda Y, Hori K et al. Technical feasibility of endoscopic submucosal dissection for local failure after chemoradiotherapy or radiotherapy for esophageal squamous cell carcinoma. *Gastrointest Endosc* 2018; 88: 637–646
- [81] Abe S, Ishihara R, Takahashi H et al. Long-term outcomes of endoscopic resection and metachronous cancer after endoscopic resection for adenocarcinoma of the esophagogastric junction in Japan. *Gastrointest Endosc* 2019; 89: 1120–1128
- [82] Phoa KN, Pouw RE, Bisschops R et al. Multimodality endoscopic eradication for neoplastic Barrett oesophagus: results of an European multicentre study (EURO-III). *Gut* 2016; 65: 555–562
- [83] Yang D, Zou F, Xiong S et al. Endoscopic submucosal dissection for early Barrett's neoplasia: a meta-analysis. *Gastrointest Endosc* 2018; 87: 1383–1393
- [84] Han C, Sun Y. Efficacy and safety of endoscopic submucosal dissection versus endoscopic mucosal resection for superficial esophageal carcinoma: a systematic review and meta-analysis. *Dis Esophagus* 2020; doi:10.1093/dote/daaa081
- [85] Codipilly DC, Dhaliwal L, Oberoi M et al. Comparative outcomes of cap assisted endoscopic resection and endoscopic submucosal dissection in dysplastic Barrett's esophagus. *Clin Gastroenterol Hepatol* 2020; doi:10.1016/j.cgh.2020.11.017
- [86] Subramaniam S, Kandiah K, Chedgy F et al. The safety and efficacy of radiofrequency ablation following endoscopic submucosal dissection for Barrett's neoplasia. *Dis Esophagus* 2018; 31: doi:10.1093/dote/dox133
- [87] Terheggen G, Horn EM, Vieth M et al. A randomised trial of endoscopic submucosal dissection versus endoscopic mucosal resection for early Barrett's neoplasia. *Gut* 2017; 66: 783–793
- [88] Coman RM, Gotoda T, Forsmark CE et al. Prospective evaluation of the clinical utility of endoscopic submucosal dissection (ESD) in patients with Barrett's esophagus: a Western center experience. *Endosc Int Open* 2016; 4: E715–721
- [89] Subramaniam S, Chedgy F, Longcroft-Wheaton G et al. Complex early Barrett's neoplasia at 3 Western centers: European Barrett's Endoscopic Submucosal Dissection Trial (E-BEST). *Gastrointest Endosc* 2017; 86: 608–618
- [90] Yang D, Coman RM, Kahaleh M et al. Endoscopic submucosal dissection for Barrett's early neoplasia: a multicenter study in the United States. *Gastrointest Endosc* 2017; 86: 600–607
- [91] Chevaux JB, Piesseaux H, Jouret-Mourin A et al. Clinical outcome in patients treated with endoscopic submucosal dissection for superficial Barrett's neoplasia. *Endoscopy* 2015; 47: 103–112
- [92] Barret M, Cao DT, Beuvon F et al. Endoscopic submucosal dissection for early Barrett's neoplasia. *United European Gastroenterol J* 2016; 4: 207–215
- [93] Prasad GA, Wu TT, Wigle DA et al. Endoscopic and surgical treatment of mucosal (T1a) esophageal adenocarcinoma in Barrett's esophagus. *Gastroenterology* 2009; 137: 815–823
- [94] Pech O, Bollschweiler E, Manner H et al. Comparison between endoscopic and surgical resection of mucosal esophageal adenocarcinoma in Barrett's esophagus at two high-volume centers. *Ann Surg* 2011; 254: 67–72
- [95] Das A, Singh V, Fleischer DE et al. A comparison of endoscopic treatment and surgery in early esophageal cancer: an analysis of surveillance epidemiology and end results data. *Am J Gastroenterol* 2008; 103: 1340–1345
- [96] Marino KA, Sullivan JL, Weksler B. Esophagectomy versus endoscopic resection for patients with early-stage esophageal adenocarcinoma: A National Cancer Database propensity-matched study. *J Thorac Cardiovasc Surg* 2018; 155: 2211–2218.e1
- [97] Raman V, Jawitz OK, Voigt SL et al. The effect of age on survival after endoscopic resection versus surgery for T1a esophageal cancer. *J Thorac Cardiovasc Surg* 2020; 160: 295–302.e293
- [98] Smith I, Kahaleh M. Endoscopic versus surgical therapy for Barrett's esophagus neoplasia. *Expert Rev Gastroenterol Hepatol* 2015; 9: 31–35
- [99] Reddy CA, Tavakkoli A, Chen VL et al. Long-term quality of life following endoscopic therapy compared to esophagectomy for neoplastic Barrett's esophagus. *Dig Dis Sci* 2020; doi:10.1007/s10620-020-06377-1
- [100] Tao M, Zhou X, Hu M et al. Endoscopic submucosal dissection versus endoscopic mucosal resection for patients with early gastric cancer: a meta-analysis. *BMJ Open* 2019; 9: e025803
- [101] Zhao Y, Wang C. Long-term clinical efficacy and perioperative safety of endoscopic submucosal dissection versus endoscopic mucosal resection for early gastric cancer: an updated meta-analysis. *Biomed Res Int* 2018; 2018: 3152346
- [102] Suzuki H, Takizawa K, Hirasawa T et al. Short-term outcomes of multicenter prospective cohort study of gastric endoscopic resection: "Real-world evidence" in Japan. *Dig Endosc* 2019; 31: 30–39
- [103] Tanabe S, Ishido K, Matsumoto T et al. Long-term outcomes of endoscopic submucosal dissection for early gastric cancer: a multicenter collaborative study. *Gastric Cancer* 2017; 20: 45–52

- [104] Gotoda T, Iwasaki M, Kusano C et al. Endoscopic resection of early gastric cancer treated by guideline and expanded National Cancer Centre criteria. *Br J Surg* 2010; 97: 868–871
- [105] Abdelfatah MM, Barakat M, Ahmad D et al. Long-term outcomes of endoscopic submucosal dissection versus surgery in early gastric cancer: a systematic review and meta-analysis. *Eur J Gastroenterol Hepatol* 2019; 31: 418–424
- [106] Liu Q, Ding L, Qiu X et al. Updated evaluation of endoscopic submucosal dissection versus surgery for early gastric cancer: A systematic review and meta-analysis. *Int J Surg* 2020; 73: 28–41
- [107] Gu L, Khadaroo PA, Chen L et al. Comparison of long-term outcomes of endoscopic submucosal dissection and surgery for early gastric cancer: a systematic review and meta-analysis. *J Gastrointest Surg* 2019; 23: 1493–1501
- [108] Li H, Feng LQ, Bian YY et al. Comparison of endoscopic submucosal dissection with surgical gastrectomy for early gastric cancer: An updated meta-analysis. *World J Gastrointest Oncol* 2019; 11: 161–171
- [109] Libânio D, Braga V, Ferraz S et al. Prospective comparative study of endoscopic submucosal dissection and gastrectomy for early neoplastic lesions including patients' perspectives. *Endoscopy* 2019; 51: 30–39
- [110] Najmeh S, Cools-Lartigue J, Mueller C et al. Comparing laparoscopic to endoscopic resections for early gastric cancer in a high volume North American center. *J Gastrointest Surg* 2016; 20: 1547–1553
- [111] Kim YI, Kim YA, Kim CG et al. Serial intermediate-term quality of life comparison after endoscopic submucosal dissection versus surgery in early gastric cancer patients. *Surg Endosc* 2018; 32: 2114–2122
- [112] Kim SG, Ji SM, Lee NR et al. Quality of life after endoscopic submucosal dissection for early gastric cancer: a prospective multicenter cohort study. *Gut Liver* 2017; 11: 87–92
- [113] Choi JH, Kim ES, Lee YJ et al. Comparison of quality of life and worry of cancer recurrence between endoscopic and surgical treatment for early gastric cancer. *Gastrointest Endosc* 2015; 82: 299–307
- [114] Perez-Cuadrado-Robles E, Queneherve L, Margos W et al. Comparative analysis of ESD versus EMR in a large European series of non-ampullary superficial duodenal tumors. *Endosc Int Open* 2018; 6: E1008–E1014
- [115] Zou J, Chai N, Linghu E et al. Clinical outcomes of endoscopic resection for non-ampullary duodenal laterally spreading tumors. *Surg Endosc* 2019; 33: 4048–4056
- [116] Perez-Cuadrado-Robles E, Queneherve L, Margos W et al. ESD versus EMR in non-ampullary superficial duodenal tumors: a systematic review and meta-analysis. *Endosc Int Open* 2018; 6: E998–E1007
- [117] Hoteya S, Yahagi N, Iizuka T et al. Endoscopic submucosal dissection for nonampullary large superficial adenocarcinoma/adenoma of the duodenum: feasibility and long-term outcomes. *Endosc Int Open* 2013; 1: 2–7
- [118] Yahagi N, Kato M, Ochiai Y et al. Outcomes of endoscopic resection for superficial duodenal epithelial neoplasia. *Gastrointest Endosc* 2018; 88: 676–682
- [119] Nonaka S, Oda I, Tada K et al. Clinical outcome of endoscopic resection for nonampullary duodenal tumors. *Endoscopy* 2015; 47: 129–135
- [120] Inoue T, Uedo N, Yamashina T et al. Delayed perforation: a hazardous complication of endoscopic resection for non-ampullary duodenal neoplasm. *Dig Endosc* 2014; 26: 220–227
- [121] Basford PJ, George R, Nixon E et al. Endoscopic resection of sporadic duodenal adenomas: comparison of endoscopic mucosal resection (EMR) with hybrid endoscopic submucosal dissection (ESD) techniques and the risks of late delayed bleeding. *Surg Endosc* 2014; 28: 1594–1600
- [122] Hara Y, Goda K, Dobashi A et al. Short- and long-term outcomes of endoscopically treated superficial non-ampullary duodenal epithelial tumors. *World J Gastroenterol* 2019; 25: 707–718
- [123] Klein A, Nayyar D, Bahin FF et al. Endoscopic mucosal resection of large and giant lateral spreading lesions of the duodenum: success, adverse events, and long-term outcomes. *Gastrointest Endosc* 2016; 84: 688–696
- [124] Klein A, Ahlenstiel G, Tate DJ et al. Endoscopic resection of large duodenal and papillary lateral spreading lesions is clinically and economically advantageous compared with surgery. *Endoscopy* 2017; 49: 659–667
- [125] Lupu A, Faller J, Oung B et al. Endoscopic submucosal dissection using countertraction with clips and rubber band allows safe en bloc resection of recurrent duodenal superficial lesions with intense fibrosis. *Endoscopy* 2020; 52: E398–E399
- [126] Niimi K, Fujishiro M, Kodashima S et al. Long-term outcomes of endoscopic submucosal dissection for colorectal epithelial neoplasms. *Endoscopy* 2010; 42: 723–729
- [127] Saito Y, Yamada M, So E et al. Colorectal endoscopic submucosal dissection: Technical advantages compared to endoscopic mucosal resection and minimally invasive surgery. *Dig Endosc* 2014; 26: (Suppl. 01): 52–61
- [128] Russo P, Barbeiro S, Awadie H et al. Management of colorectal laterally spreading tumors: a systematic review and meta-analysis. *Endosc Int Open* 2019; 7: E239–E259
- [129] Rahmi G, Hotayt B, Chaussade S et al. Endoscopic submucosal dissection for superficial rectal tumors: prospective evaluation in France. *Endoscopy* 2014; 46: 670–676
- [130] Ronnow CF, Uedo N, Toth E et al. Endoscopic submucosal dissection of 301 large colorectal neoplasias: Outcome and learning curve from a specialized center in Europe. *Endosc Int Open* 2018; 6: E1340–E1348
- [131] Fuccio L, Hassan C, Ponchon T et al. Clinical outcomes after endoscopic submucosal dissection for colorectal neoplasia: A systematic review and meta-analysis. *Gastrointest Endosc* 2017; 86: 74–86.e17
- [132] De Ceglie A, Hassan C, Mangiavillano B et al. Endoscopic mucosal resection and endoscopic submucosal dissection for colorectal lesions: A systematic review. *Crit Rev Oncol Hematol* 2016; 104: 138–155
- [133] Fujiya M, Tanaka K, Dokoshi T et al. Efficacy and adverse events of EMR and endoscopic submucosal dissection for the treatment of colon neoplasms: a meta-analysis of studies comparing EMR and endoscopic submucosal dissection. *Gastrointest Endosc* 2015; 81: 583–595
- [134] Arezzo A, Passera R, Marchese N et al. Systematic review and meta-analysis of endoscopic submucosal dissection vs endoscopic mucosal resection for colorectal lesions. *United European Gastroenterol J* 2016; 4: 18–29
- [135] Klein A, Tate DJ, Jayasekaran V et al. Thermal ablation of mucosal defect margins reduces adenoma recurrence after colonic endoscopic mucosal resection. *Gastroenterology* 2019; 156: 604–613.e603
- [136] Sidhu M, Shahidi N, Gupta S et al. Outcomes of thermal ablation of the mucosal defect margin after endoscopic mucosal resection: A prospective, international, multicenter trial of 1000 large nonpedunculated colorectal polyps. *Gastroenterology* 2021; 161: 163–170.e163
- [137] Fuccio L, Repici A, Hassan C et al. Why attempt en bloc resection of non-pedunculated colorectal adenomas? A systematic review of the prevalence of superficial submucosal invasive cancer after endoscopic submucosal dissection *Gut* 2018; 67: 1464–1474

- [138] Bahin FF, Heitman SJ, Rasouli KN et al. Wide-field endoscopic mucosal resection versus endoscopic submucosal dissection for laterally spreading colorectal lesions: a cost-effectiveness analysis. *Gut* 2018; 67: 1965–1973
- [139] Keswani RN, Law R, Ciolino JD et al. Adverse events after surgery for nonmalignant colon polyps are common and associated with increased length of stay and costs. *Gastrointest Endosc* 2016; 84: 296–303.e291
- [140] Patel M, Haque M, Kohli D et al. Endoscopic resection reduces morbidity when compared to surgery in veterans with large and complex colorectal polyps. *Surg Endosc* 2020; doi:10.1007/s00464-020-07482-y
- [141] Gamaleldin M, Benlice C, Delaney CP et al. Management of the colorectal polyp referred for resection: A case-matched comparison of advanced endoscopic surgery and laparoscopic colectomy. *Surgery* 2018; 163: 522–527
- [142] Nakamura F, Saito Y, Haruyama S et al. Short-term prospective questionnaire study of early postoperative quality of life after colorectal endoscopic submucosal dissection. *Dig Dis Sci* 2017; 62: 3325–3335
- [143] Nam MJ, Sohn DK, Hong CW et al. Cost comparison between endoscopic submucosal dissection and transanal endoscopic microsurgery for the treatment of rectal tumors. *Ann Surg Treat Res* 2015; 89: 202–207
- [144] Yamashita K, Oka S, Tanaka S et al. Preceding endoscopic submucosal dissection for T1 colorectal carcinoma does not affect the prognosis of patients who underwent additional surgery: a large multicenter propensity score-matched analysis. *J Gastroenterol* 2019; 54: 897–906
- [145] Lowe D, Saleem S, Arif MO et al. Role of endoscopic resection versus surgical resection in management of malignant colon polyps: A National Cancer Database analysis. *J Gastrointest Surg* 2020; 24: 177–187
- [146] Yeh JH, Tseng CH, Huang RY et al. Long-term outcomes of primary endoscopic resection vs surgery for T1 colorectal cancer: A systematic review and meta-analysis. *Clin Gastroenterol Hepatol* 2020; 18: 2813–2823.e2815
- [147] Inoue T, Koyama F, Kuge H et al. Short-term outcomes of endoscopic submucosal dissection versus laparoscopic surgery for colorectal neoplasms: An observational study. *J Anus Rectum Colon* 2018; 2: 97–102
- [148] Moon JY, Kim GH, Kim JH et al. Clinicopathologic factors predicting lymph node metastasis in superficial esophageal squamous cell carcinoma. *Scand J Gastroenterol* 2014; 49: 589–594
- [149] Sgourakis G, Gockel I, Lang H. Endoscopic and surgical resection of T1a/T1b esophageal neoplasms: a systematic review. *World J Gastroenterol* 2013; 19: 1424–1437
- [150] Xu W, Liu XB, Li SB et al. Prediction of lymph node metastasis in superficial esophageal squamous cell carcinoma in Asia: a systematic review and meta-analysis. *Dis Esophagus* 2020; doi:10.1093/dote/daaa032
- [151] Ye B, Zhang X, Su Y et al. The possibility of endoscopic treatment of cN0 submucosal esophageal cancer: results from a surgical cohort. *Surg Endosc* 2020; doi:10.1007/s00464-020-07420-y
- [152] Zhang Y, Liu L, Wang Q et al. Endoscopic submucosal dissection with additional radiotherapy in the treatment of T1a esophageal squamous cell cancer: randomized controlled trial. *Endoscopy* 2020; 52: 1066–1074
- [153] Hisano O, Nonoshita T, Hirata H et al. Additional radiotherapy following endoscopic submucosal dissection for T1a-MM/T1b-SM esophageal squamous cell carcinoma improves locoregional control. *Radiat Oncol* 2018; 13: 14
- [154] Ikeda A, Hoshi N, Yoshizaki T et al. Endoscopic submucosal dissection (ESD) with additional therapy for superficial esophageal cancer with submucosal invasion. *Intern Med* 2015; 54: 2803–2813
- [155] Kawaguchi G, Sasamoto R, Abe E et al. The effectiveness of endoscopic submucosal dissection followed by chemoradiotherapy for superficial esophageal cancer. *Radiat Oncol* 2015; 10: 31
- [156] Suzuki G, Yamazaki H, Aibe N et al. Endoscopic submucosal dissection followed by chemoradiotherapy for superficial esophageal cancer: Choice of new approach. *Radiat Oncol* 2018; 13: 246
- [157] Yoshimizu S, Yoshio T, Ishiyama A et al. Long-term outcomes of combined endoscopic resection and chemoradiotherapy for esophageal squamous cell carcinoma with submucosal invasion. *Dig Liver Dis* 2018; 50: 833–838
- [158] Minashi K, Nihei K, Mizusawa J et al. Efficacy of endoscopic resection and selective chemoradiotherapy for stage I esophageal squamous cell carcinoma. *Gastroenterology* 2019; 157: 382–390.e383
- [159] Kitagawa Y, Uno T, Oyama T et al. Esophageal cancer practice guidelines 2017 edited by the Japan Esophageal Society: part 1. *Esophagus* 2019; 16: 1–24
- [160] Koterazawa Y, Nakamura T, Oshikiri T et al. A comparison of the clinical outcomes of esophagectomy and chemoradiotherapy after noncurative endoscopic submucosal dissection for esophageal squamous cell carcinoma. *Surg Today* 2018; 48: 783–789
- [161] Tsou YK, Lee CH, Le PH et al. Adjuvant therapy for pT1a-m3/pT1b esophageal squamous cell carcinoma after endoscopic resection: Esophagectomy or chemoradiotherapy? A critical review. *Crit Rev Oncol Hematol* 2020; 147: 102883
- [162] Hirasawa K, Kokawa A, Oka H et al. Superficial adenocarcinoma of the esophagogastric junction: long-term results of endoscopic submucosal dissection. *Gastrointest Endosc* 2010; 72: 960–966
- [163] Yoshinaga S, Gotoda T, Kusano C et al. Clinical impact of endoscopic submucosal dissection for superficial adenocarcinoma located at the esophagogastric junction. *Gastrointest Endosc* 2008; 67: 202–209
- [164] Alvarez Herrero L, Pouw RE, van Vilsteren FG et al. Risk of lymph node metastasis associated with deeper invasion by early adenocarcinoma of the esophagus and cardia: study based on endoscopic resection specimens. *Endoscopy* 2010; 42: 1030–1036
- [165] Manner H, May A, Pech O et al. Early Barrett's carcinoma with "low-risk" submucosal invasion: long-term results of endoscopic resection with a curative intent. *Am J Gastroenterol* 2008; 103: 2589–2597
- [166] Manner H, Pech O, Heldmann Y et al. Efficacy, safety, and long-term results of endoscopic treatment for early stage adenocarcinoma of the esophagus with low-risk sm1 invasion. *Clin Gastroenterol Hepatol* 2013; quiz e645 11: 630–635
- [167] Manner H, Pech O, Heldmann Y et al. The frequency of lymph node metastasis in early-stage adenocarcinoma of the esophagus with incipient submucosal invasion (pT1b sm1) depending on histological risk patterns. *Surg Endosc* 2015; 29: 1888–1896
- [168] Manner H, Wetzka J, May A et al. Early-stage adenocarcinoma of the esophagus with mid to deep submucosal invasion (pT1b sm2–3): the frequency of lymph-node metastasis depends on macroscopic and histological risk patterns. *Dis Esophagus* 2017; 30: 1–11
- [169] Benech N, O'Brien JM, Barret M et al. Endoscopic resection of Barrett's adenocarcinoma: Intramucosal and low-risk tumours are not associated with lymph node metastases. *United European Gastroenterol J* 2021; 9: 362–369
- [170] Larghi A, Lightdale CJ, Ross AS et al. Long-term follow-up of complete Barrett's eradication endoscopic mucosal resection (CBE-EMR) for the treatment of high grade dysplasia and intramucosal carcinoma. *Endoscopy* 2007; 39: 1086–1091
- [171] Fleischer DE, Overholt BF, Sharma VK et al. Endoscopic radiofrequency ablation for Barrett's esophagus: 5-year outcomes from a prospective multicenter trial. *Endoscopy* 2010; 42: 781–789

- [172] Peters FP, Kara MA, Rosmolen WD et al. Endoscopic treatment of high-grade dysplasia and early stage cancer in Barrett's esophagus. *Gastrointest Endosc* 2005; 61: 506–514
- [173] Sawas T, Alsawas M, Bazerbachi F et al. Persistent intestinal metaplasia after endoscopic eradication therapy of neoplastic Barrett's esophagus increases the risk of dysplasia recurrence: meta-analysis. *Gastrointest Endosc* 2019; 89: 913–925 e916
- [174] Gotoda T, Yanagisawa A, Sasako M et al. Incidence of lymph node metastasis from early gastric cancer: estimation with a large number of cases at two large centers. *Gastric Cancer* 2000; 3: 219–225
- [175] Hirasawa T, Gotoda T, Miyata S et al. Incidence of lymph node metastasis and the feasibility of endoscopic resection for undifferentiated-type early gastric cancer. *Gastric Cancer* 2009; 12: 148–152
- [176] Nakahara K, Tsuruta O, Tateishi H et al. Extended indication criteria for endoscopic mucosal resection of early gastric cancer with special reference to lymph node metastasis—examination by multivariate analysis. *Kurume Med J* 2004; 51: 9–14
- [177] Abdelfatah MM, Barakat M, Othman MO et al. The incidence of lymph node metastasis in submucosal early gastric cancer according to the expanded criteria: a systematic review. *Surg Endosc* 2019; 33: 26–32
- [178] Chu YN, Yu YN, Jing X et al. Feasibility of endoscopic treatment and predictors of lymph node metastasis in early gastric cancer. *World J Gastroenterol* 2019; 25: 5344–5355
- [179] Lee SH, Choi CW, Kim SJ et al. Risk factors for lymph node metastasis in mucosal gastric cancer and re-evaluation of endoscopic submucosal dissection. *Ann Surg Treat Res* 2016; 91: 118–126
- [180] Choi KK, Bae JM, Kim SM et al. The risk of lymph node metastases in 3951 surgically resected mucosal gastric cancers: implications for endoscopic resection. *Gastrointest Endosc* 2016; 83: 896–901
- [181] Ma DW, Lee SJ, Kook MC et al. The suggestion of revised criteria for endoscopic resection of differentiated-type submucosal gastric cancer. *Ann Surg Oncol* 2020; 27: 795–801
- [182] Choi JY, Park YS, Jung HY et al. Identifying predictors of lymph node metastasis after endoscopic resection in patients with minute submucosal cancer of the stomach. *Surg Endosc* 2015; 29: 1476–1483
- [183] Kim TS, Min BH, Kim KM et al. Endoscopic submucosal dissection for papillary adenocarcinoma of the stomach: low curative resection rate but favorable long-term outcomes after curative resection. *Gastric Cancer* 2019; 22: 363–368
- [184] Lee HJ, Kim GH, Park DY et al. Endoscopic submucosal dissection for papillary adenocarcinoma of the stomach: is it really safe? *Gastric Cancer* 2017; 20: 978–986
- [185] Chen JN, Wang QW, Zhang QW et al. Poorly differentiated is more significant than signet ring cell component for lymph node metastasis in mixed-type early gastric cancer: a retrospective study from a large-volume hospital. *Surg Endosc* 2020; doi:10.1007/s00464-020-07532-5
- [186] Seo HS, Lee GE, Kang MG et al. Mixed histology is a risk factor for lymph node metastasis in early gastric cancer. *J Surg Res* 2019; 236: 271–277
- [187] Lee IS, Lee S, Park YS et al. Applicability of endoscopic submucosal dissection for undifferentiated early gastric cancer: Mixed histology of poorly differentiated adenocarcinoma and signet ring cell carcinoma is a worse predictive factor of nodal metastasis. *Surg Oncol* 2017; 26: 8–12
- [188] Lee JH, Choi JJ, Han HS et al. Risk of lymph node metastasis in differentiated type mucosal early gastric cancer mixed with minor undifferentiated type histology. *Ann Surg Oncol* 2015; 22: 1813–1819
- [189] Takizawa K, Ono H, Yamamoto Y et al. Incidence of lymph node metastasis in intramucosal gastric cancer measuring 30 mm or less, with ulceration; mixed, predominantly differentiated-type histology; and no lymphovascular invasion: a multicenter retrospective study. *Gastric Cancer* 2016; 19: 1144–1148
- [190] Takizawa K, Hatta W, Gotoda T et al. Recurrence patterns and outcomes of salvage surgery in cases of non-curative endoscopic submucosal dissection without additional radical surgery for early gastric cancer. *Digestion* 2019; 99: 52–58
- [191] Yamada S, Hatta W, Shimosegawa T et al. Different risk factors between early and late cancer recurrences in patients without additional surgery after noncurative endoscopic submucosal dissection for early gastric cancer. *Gastrointest Endosc* 2019; 89: 950–960
- [192] Libanio D, Pimentel-Nunes P, Afonso LP et al. Long-term outcomes of gastric endoscopic submucosal dissection: Focus on metachronous and non-curative resection management. *GE Port J Gastroenterol* 2017; 24: 31–39
- [193] Hatta W, Gotoda T, Oyama T et al. A scoring system to stratify curability after endoscopic submucosal dissection for early gastric cancer: "eCura system". *Am J Gastroenterol* 2017; 112: 874–881
- [194] Hatta W, Gotoda T, Oyama T et al. Is the eCura system useful for selecting patients who require radical surgery after noncurative endoscopic submucosal dissection for early gastric cancer? A comparative study *Gastric Cancer* 2018; 21: 481–489
- [195] Figueiredo PC, Pimentel-Nunes P, Libanio D et al. A systematic review and meta-analysis on outcomes after R0 or R1 endoscopic resection of superficial gastric cancer. *Eur J Gastroenterol Hepatol* 2015; 27: 1249–1258
- [196] Jeon MY, Park JC, Hahn KY et al. Long-term outcomes after non-curative endoscopic resection of early gastric cancer: the optimal time for additional endoscopic treatment. *Gastrointest Endosc* 2018; 87: 1003–1013.e1002
- [197] Japanese Gastric Cancer Association. Japanese gastric cancer treatment guidelines 2018 (5th edition). *Gastric Cancer* 2020; doi:10.1007/s10120-020-01042-y
- [198] Hirashita T, Ohta M, Tada K et al. Prognostic factors of non-ampullary duodenal adenocarcinoma. *Jpn J Clin Oncol* 2018; 48: 743–747
- [199] Goda K, Kikuchi D, Yamamoto Y et al. Endoscopic diagnosis of superficial non-ampullary duodenal epithelial tumors in Japan: Multi-center case series. *Dig Endosc* 2014; 26: (Suppl. 02): 23–29
- [200] Kuroki K, Sanomura Y, Oka S et al. Clinical outcomes of endoscopic resection for superficial non-ampullary duodenal tumors. *Endosc Int Open* 2020; 8: E354–E359
- [201] Probst A, Freund S, Neuhaus L et al. Complication risk despite preventive endoscopic measures in patients undergoing endoscopic mucosal resection of large duodenal adenomas. *Endoscopy* 2020; 52: 847–855
- [202] Choi JY, Jung SA, Shim KN et al. Meta-analysis of predictive clinicopathologic factors for lymph node metastasis in patients with early colorectal carcinoma. *J Korean Med Sci* 2015; 30: 398–406
- [203] Bosch SL, Teerenstra S, de Wilt JH et al. Predicting lymph node metastasis in pT1 colorectal cancer: a systematic review of risk factors providing rationale for therapy decisions. *Endoscopy* 2013; 45: 827–834
- [204] Ronnow CF, Arthursson V, Toth E et al. Lymphovascular infiltration, not depth of invasion, is the critical risk factor of metastases in early colorectal cancer: retrospective population-based cohort study on prospectively collected data, including validation. *Ann Surg* 2020; doi:10.1097/SLA.0000000000003854
- [205] Kawachi H, Eishi Y, Ueno H et al. A three-tier classification system based on the depth of submucosal invasion and budding/sprouting can improve the treatment strategy for T1 colorectal cancer: a retrospective multicenter study. *Mod Pathol* 2015; 28: 872–879
- [206] Han J, Hur H, Min BS et al. Predictive factors for lymph node metastasis in submucosal invasive colorectal carcinoma: a new proposal of depth of invasion for radical surgery. *World J Surg* 2018; 42: 2635–2641

- [207] Ebbelohj AL, Jorgensen LN, Krarup PM et al. Histopathological risk factors for lymph node metastases in T1 colorectal cancer: meta-analysis. *Br J Surg* 2021; doi:10.1093/bjs/znab168
- [208] Cubiella J, Gonzalez A, Almazan R et al. pT1 Colorectal cancer detected in a colorectal cancer mass screening program: treatment and factors associated with residual and extraluminal disease. *Cancers (Basel)* 2020; 12: doi:10.3390/cancers12092530
- [209] Boenicke L, Fein M, Sailer M et al. The concurrence of histologically positive resection margins and sessile morphology is an important risk factor for lymph node metastasis after complete endoscopic removal of malignant colorectal polyps. *Int J Colorectal Dis* 2010; 25: 433–438
- [210] Kim JY, Han SJ, Jung Y et al. The relationship between local recurrence and positive lateral margin after en bloc resection of colorectal neoplasm. *Scand J Gastroenterol* 2018; 53: 1541–1546
- [211] Makazu M, Sakamoto T, So E et al. Relationship between indeterminate or positive lateral margin and local recurrence after endoscopic resection of colorectal polyps. *Endosc Int Open* 2015; 3: E252–257
- [212] Yamada M, Saito Y, Takamaru H et al. Long-term clinical outcomes of endoscopic submucosal dissection for colorectal neoplasms in 423 cases: a retrospective study. *Endoscopy* 2017; 49: 233–242
- [213] Backes Y, de Vos Tot Nederveen Cappel WH, van Bergeijk J et al. Risk for incomplete resection after macroscopic radical endoscopic resection of T1 colorectal cancer: A multicenter cohort study. *Am J Gastroenterol* 2017; 112: 785–796
- [214] Chen K, Cao G, Chen B et al. Laparoscopic versus open surgery for rectal cancer: A meta-analysis of classic randomized controlled trials and high-quality nonrandomized Studies in the last 5 years. *Int J Surg* 2017; 39: 1–10
- [215] Wu Q, Wei M, Ye Z et al. Laparoscopic colectomy versus open colectomy for treatment of transverse colon cancer: A systematic review and meta-analysis. *J Laparoendosc Adv Surg Tech A* 2017; 27: 1038–1050
- [216] Jeong JU, Nam TK, Kim HR et al. Adjuvant chemoradiotherapy instead of revision radical resection after local excision for high-risk early rectal cancer. *Radiat Oncol* 2016; 11: 114
- [217] Sasaki T, Ito Y, Ohue M et al. Postoperative chemoradiotherapy after local resection for high-risk T1 to T2 low rectal cancer: Results of a single-arm, multi-institutional, phase II clinical trial. *Dis Colon Rectum* 2017; 60: 914–921
- [218] Barbeiro S, Libanio D, Castro R et al. Narrow-band imaging: Clinical application in gastrointestinal endoscopy. *GE Port J Gastroenterol* 2018; 26: 40–53
- [219] Kim GH, Min YW, Lee H et al. Risk factors of metachronous recurrence after endoscopic submucosal dissection for superficial esophageal squamous cell carcinoma. *PLoS One* 2020; 15: e0238113
- [220] Sawada G, Niida A, Uchi R et al. Genomic landscape of esophageal squamous cell carcinoma in a Japanese population. *Gastroenterology* 2016; 150: 1171–1182
- [221] Uno K, Koike T, Kusaka G et al. Risk of metachronous recurrence after endoscopic submucosal dissection of esophageal squamous cell carcinoma. *Dis Esophagus* 2017; 30: 1–8
- [222] Urabe Y, Kagemoto K, Nakamura K et al. Construction of a risk model for the development of metachronous squamous cell carcinoma after endoscopic resection of esophageal squamous cell carcinoma. *Esophagus* 2019; 16: 141–146
- [223] Fukuda H, Ishihara R, Shimamoto Y et al. Effect of horizontal margin status and risk of local recurrence after endoscopic submucosal dissection for superficial esophageal cancer. *JGH Open* 2020; 4: 160–165
- [224] Cotton CC, Haidry R, Thrift AP et al. Development of evidence-based surveillance intervals after radiofrequency ablation of Barrett's esophagus. *Gastroenterology* 2018; 155: 316–326.e316
- [225] Brito-Goncalves G, Libanio D, Marcos P et al. Clinicopathologic characteristics of patients with gastric superficial neoplasia and risk factors for multiple lesions after endoscopic submucosal dissection in a Western country. *GE Port J Gastroenterol* 2020; 27: 76–89
- [226] Okada K, Suzuki S, Naito S et al. Incidence of metachronous gastric cancer in patients whose primary gastric neoplasms were discovered after *Helicobacter pylori* eradication. *Gastrointest Endosc* 2019; 89: 1152–1159.e1151
- [227] Park WY, Lee SJ, Kim YK et al. Occurrence of metachronous or synchronous lesions after endoscopic treatment of gastric epithelia dysplasia- impact of histologic features of background mucosa. *Pathol Res Pract* 2018; 214: 95–99
- [228] Yang HJ, Kim SG, Lim JH et al. Novel risk stratification for metachronous recurrence after curative endoscopic submucosal dissection for early gastric cancer. *Gastrointest Endosc* 2018; 87: 419–428.e413
- [229] Yang HJ, Kim SG, Lim JH et al. Surveillance strategy according to age after endoscopic resection of early gastric cancer. *Surg Endosc* 2018; 32: 846–854
- [230] Moon HS, Yun GY, Kim JS et al. Risk factors for metachronous gastric carcinoma development after endoscopic resection of gastric dysplasia: Retrospective, single-center study. *World J Gastroenterol* 2017; 23: 4407–4415
- [231] Abe S, Oda I, Suzuki H et al. Long-term surveillance and treatment outcomes of metachronous gastric cancer occurring after curative endoscopic submucosal dissection. *Endoscopy* 2015; 47: 1113–1118
- [232] Pimentel-Nunes P, Libanio D, Marcos-Pinto R et al. Management of epithelial precancerous conditions and lesions in the stomach (MAPS II): European Society of Gastrointestinal Endoscopy (ESGE), European Helicobacter and Microbiota Study Group (EHMSG), European Society of Pathology (ESP), and Sociedade Portuguesa de Endoscopia Digestiva (SPED) guideline update 2019. *Endoscopy* 2019; 51: 365–388
- [233] Hahn KY, Park JC, Kim EH et al. Incidence and impact of scheduled endoscopic surveillance on recurrence after curative endoscopic resection for early gastric cancer. *Gastrointest Endosc* 2016; 84: 628–638.e621
- [234] Oka S, Tanaka S, Saito Y et al. Local recurrence after endoscopic resection for large colorectal neoplasia: a multicenter prospective study in Japan. *Am J Gastroenterol* 2015; 110: 697–707
- [235] Yoshii S, Nojima M, Noshio K et al. Factors associated with risk for colorectal cancer recurrence after endoscopic resection of T1 tumors. *Clin Gastroenterol Hepatol* 2014; 12: 292–302.e293
- [236] Green RJ, Metlay JP, Propert K et al. Surveillance for second primary colorectal cancer after adjuvant chemotherapy: an analysis of Inter-group 0089. *Ann Intern Med* 2002; 136: 261–269
- [237] Hassan C, Pickhardt PJ, Zullo A et al. Cost-effectiveness of early colonoscopy surveillance after cancer resection. *Dig Liver Dis* 2009; 41: 881–885
- [238] Hassan C, Antonelli G, Dumonceau JM et al. Post-polypectomy colonoscopy surveillance: European Society of Gastrointestinal Endoscopy (ESGE) Guideline – Update 2020. *Endoscopy* 2020; 52: 687–700
- [239] Benson AB, Venook AP, Al-Hawary MM et al. NCCN guidelines insights: Colon Cancer, version 2, 2018. *J Natl Compr Canc Netw* 2018; 16: 359–369
- [240] Shaikat A, Kaltenbach T, Dominitz JA et al. Endoscopic recognition and management strategies for malignant colorectal polyps: Recommendations of the US Multi-Society Task Force on Colorectal Cancer. *Am J Gastroenterol* 2020; 115: 1751–1767
- [241] Butte JM, Tang P, Gonen M et al. Rate of residual disease after complete endoscopic resection of malignant colonic polyp. *Dis Colon Rectum* 2012; 55: 122–127