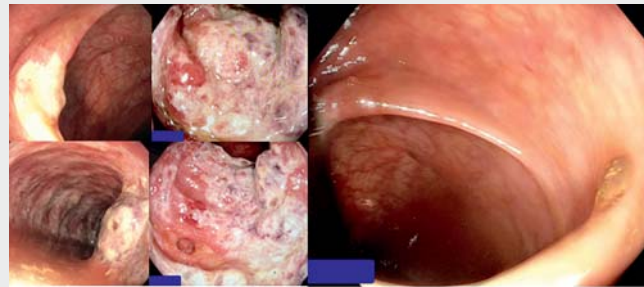


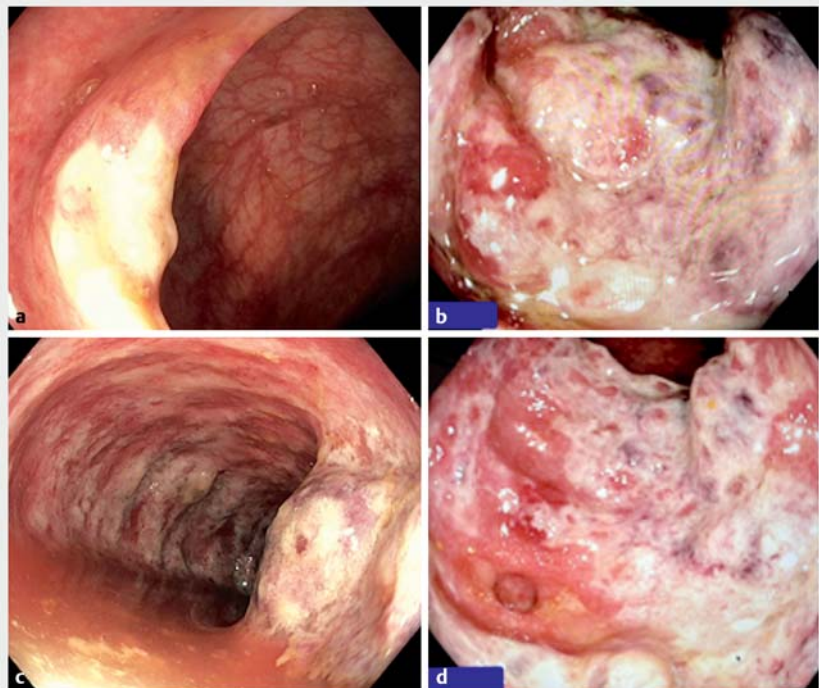
Ischemic colitis after COVID-19 mRNA vaccine

An 82-year-old woman with a history of hypertension and osteoarthritis was admitted with abdominal pain and hematochezia that developed 7 days after she had received her second COVID-19 mRNA vaccination (BioNTech, Germany). Severe lower abdominal tenderness was present with decreased bowel sounds. Abnormal laboratory findings were leukocytosis (18 000/ μ L; normal 4500–10 500/ μ L) and increased C-reactive protein (50 mg/dL; normal <5 mg/dL). Abdominal ultrasound revealed massive edema of the colon but no atherosclerosis of the aorta or narrowing of the pelvic arteries. Sigmoidoscopy revealed deep ulcers, luminal narrowing, and frank mucosal necrosis starting at the rectosigmoid and extending into the entire sigmoid colon (► **Video 1**, ► **Fig. 1**). Additional extensive evaluation including stool cultures and studies for viral and autoimmune diseases did not reveal any other cause for the ischemic colitis. Histology showed frank necrosis with lymphocytic infiltration of the lamina propria, in addition to occluded vessels with inflammatory infiltrates, without eosinophilia or pseudomembranes. The patient was treated with intravenous fluids and metronidazole for 5 days. Her symptoms slowly subsided and she was discharged home on day 7. The temporal relationship, in the absence of any other inciting factors, medications, or abnormal anatomic vessel abnormalities, suggests that the causative event for the ischemic colitis was the mRNA vaccination. The SARS-CoV-2 spike is a key pathogenic factor of this novel coronavirus, allowing the virion to attach itself to the cells and then deliver its genetic contents inside the cytoplasm [1]. Some COVID-19 vaccines are a form of genetic therapy that use nanoparticles carrying mRNA to transfect the cell introducing the genetic material encoding the S-spike inside. SARS-CoV-2 spike protein dysregulates prothrombin and fibrinogen chains [2]. The S-spike also phosphorylates ACE2, leading to



• Sigmoidoscopy revealed, deep ulcers, luminal narrowing, frank mucosal necrosis starting at the rectosigmoid and extending into the entire sigmoid colon.

► **Video 1** The sigmoid colon had signs of severe ischemic colitis, with necrosis and luminal narrowing.



► **Fig. 1** Ischemic colitis in an 82-year-old woman after COVID-19 mRNA vaccine. **a** The distal part of the rectosigmoid was spared from inflammation or necrosis. **b** The patchy colitis started at the distal sigmoid colon. **c** Frank ulcerations, necrosis, edema, and exfoliation of necrotic tissue was seen in the mid and proximal sigmoid colon. **d** The mucosa is frankly necrotic, swollen, and friable, with luminal narrowing.

MAPK signaling activation with phosphorylation of Erk, p-38, and JNK and subsequent platelet activation, release of coagulation factors, and secretion of inflammatory cytokines [2]. This inflammatory state may further enhance the thrombophilia per se or in the setting of vaccine-induced thrombocytopenia, autoimmune vasculitis or result in arterial or venous thrombosis in different parts of the body.

Endoscopy_UCTN_Code_CCL_1AD_2AF

Competing interests

The authors declare that they have no conflict of interest.

The authors

Klaus Mönkemüller^{1,2}, Elnura Abdullayeva¹, Kiril Manovski¹, Miguel Cacho-Díaz¹

- 1 Department of Gastroenterology, Aneos Teaching University Hospital (Otto-von-Guericke University – Magdeburg), Halberstadt, Germany
- 2 University of Belgrade, Belgrade, Serbia

Corresponding author

Klaus Mönkemüller, FJGES (Japan)

Division of Gastroenterology, University Teaching Hospital Aneos Klinikum Halberstadt, Gleimstr. 5, 38820 Halberstadt, Germany
moenkemueller@yahoo.com

References

- [1] Grobbelaar LM, Venter C, Vlok M et al. SARS-CoV-2 spike protein S1 induces fibrin(ogen) resistant to fibrinolysis: implications for microclot formation in COVID-19. *Biosci Rep* 2021; 41: BSR20210611
- [2] Zhang S, Liu Y, Wang X et al. SARS-CoV-2 binds platelet ACE2 to enhance thrombosis in COVID-19. *J Hematol Oncol* 2020; 13: 120–122

Bibliography

Endoscopy 2022; 54: E765–E766
DOI 10.1055/a-1816-7631
ISSN 0013-726X
published online 13.5.2022
© 2022, Thieme. All rights reserved.
Georg Thieme Verlag KG, Rüdigerstraße 14, 70469 Stuttgart, Germany

ENDOSCOPY E-VIDEOS

<https://eref.thieme.de/e-videos>



Endoscopy E-Videos is an open access online section, reporting on interesting cases and new techniques in gastroenterological endoscopy. All papers include a high quality video and all contributions are freely accessible online. Processing charges apply (currently EUR 375), discounts and waivers acc. to HINARI are available.

This section has its own submission website at
<https://mc.manuscriptcentral.com/e-videos>