

# Surface Cranial Ultrasound: The Natural Heir to X-Ray for the Screening of Skull Deformities in Infants

## Kranialer Ultraschall der Schädeloberfläche: Nachfolger der Röntgen-Untersuchung bei Schädeldeformitäten von Säuglingen

### Authors

Laura Maria Pogliani<sup>1</sup>, Gian Vincenzo Zuccotti<sup>2,3</sup>, Maddalena Reggiori<sup>3</sup>, Alessandra Erbetta<sup>4</sup>, Michele Lacerenza<sup>5</sup>, Francesco Prada<sup>6,7</sup>, Marika Furlanetto<sup>6</sup>, Ignazio Gaspare Vetrano<sup>6</sup>, Laura Grazia Valentini<sup>6</sup>

### Affiliations

- 1 Pediatric Department, Ospedale di Legnano Nuova Sede, Legnano, Italy
- 2 Department of Biomedical and Clinical Sciences, Università degli Studi di Milano, Milan, Italy
- 3 Pediatrics, Ospedale Luigi Sacco-Polo Universitario, Milan, Italy
- 4 Neuroradiology, Fondazione IRCCS Istituto Neurologico Carlo Besta, Milan, Italy
- 5 Physics, Politecnico di Milano, Milan, Italy
- 6 Neurosurgical Department, Fondazione IRCCS Istituto Neurologico Carlo Besta, Milano, Italy
- 7 Neurological Surgery, University of Virginia School of Medicine, Charlottesville, United States

### Key words

cranial ultrasound, craniosynostosis, infants, computerized tomography, cranial sutures

received 22.09.2020

accepted 13.03.2022

published online 27.06.2022

### Bibliography

Ultraschall in Med 2023; 44: 503–511

DOI 10.1055/a-1820-8101


ISSN 0172-4614

© 2022, Thieme. All rights reserved.

Georg Thieme Verlag KG, Rüdigerstraße 14, 70469 Stuttgart, Germany

### Correspondence

Dr. Laura Grazia Valentini  
Fondazione IRCCS Istituto Neurologico Carlo Besta  
Neurosurgical Department, Milano, Italy  
laura.valentini@istituto-besta.it

 Additional material is available at <https://doi.org/10.1055/a-1820-8101>.

### ABSTRACT

**Purpose** Volumetric tomography (3D-CT) is currently considered the gold standard for the diagnosis of craniosynostosis,

but its use as the first-line examination for cranial deformities is a topic of debate, because of skull X-ray radiation and low sensitivity and specificity. Cranial ultrasound is an emerging noninvasive radiation-free alternative, but its diagnostic accuracy still needs confirmation.

**Materials and Methods** The present prospective study included 350 infants with skull deformities, who underwent cranial ultrasound as the first-line examination, followed by 3D-CT if the echography results was positive or unclear. If the results were negative, infants underwent physical treatment and follow-up. To evaluate ultrasound reliability, we focused on cases that underwent both the index test and the gold standard and performed a double-blind comparison of the echography and 3D-CT results.

**Results** Ultrasound documented patent sutures in 293 infants and 9 had inconclusive results. The 293 ultrasound-negative infants were followed clinically: all improved, except 28 that underwent 3D-CT. In all of these cases, 3D-CT confirmed the ultrasonography results (no false negatives). 48 infants showed premature suture closure and underwent 3D-CT: 47 were confirmed (true positive), 1 was false positive. The sensitivity was 100%, the specificity was 99.7%, the positive and negative predictive values were 97.9% and 100%, respectively, the accuracy was 99.7%, and the diagnostic test evaluation was conclusive.

**Conclusion** The study documented the high sensitivity and specificity of echography for the diagnosis of craniosynostosis in a referral center, with better results being achieved before 6 months of age. Major limitations are the loss of diagnostic significance as the child grows and the learning curve needed. The advantages are avoidance of radiation and chance to evaluate the brain at the same time.

### ZUSAMMENFASSUNG

**Ziel** Die volumetrische Tomografie (3D-CT) gilt derzeit als Goldstandard für die Diagnose von Kraniosynostosen, ist jedoch für die Erstuntersuchung von Schädeldeformitäten aufgrund der Strahlenbelastung und der geringen Sensitivität/Spezifität umstritten. Die kraniale Sonografie ist eine aufkommende, nicht-invasive, strahlungsfreie Alternative, aber ihre diagnostische Genauigkeit muss noch bestätigt werden.

**Material und Methoden** Die vorliegende prospektive Studie umfasste 350 Säuglinge mit Schädeldeformitäten, die als Erstuntersuchung einem kranialen Ultraschall unterzogen wurden, gefolgt von einer 3D-CT, wenn die sonografischen Befunde positiv oder fraglich waren. War der Befund negativ, wurden die Kinder ärztlich behandelt und nachuntersucht. Um die Zuverlässigkeit der Sonografie zu bewerten, konzentrierten wir uns auf Fälle, die sowohl dem Index-Test als auch dem Goldstandard unterzogen wurden, und verglichen unter doppelter Verblindung Sonografie- und 3D-CT-Befunde.

**Ergebnisse** Bei 293 Säuglingen wurden sonografisch offene Nähte nachgewiesen, bei 9 Kindern war der Befund nicht eindeutig. Die 293 Säuglinge mit unauffälligem sonografischen Befund wurden klinisch nachverfolgt: Bei allen, verbesserte sich das klinische Bild, mit Ausnahme von 28, die mit 3D-CT untersucht wurden. In all diesen Fällen bestätigte die 3D-CT

den Ultraschallbefund (keine falsch-negativen). 48 Säuglinge zeigten einen verfrühten Nahtverschluss und wurden einer 3D-CT unterzogen: 47 Fälle wurden bestätigt (richtig-positiv), 1 Fall war falsch-positiv. Die Sensitivität betrug 100 %, die Spezifität 99,7 %, der positive und negative Vorhersagewert 97,9 % bzw. 100 %, die Genauigkeit 99,7 %. Die Evaluation des diagnostischen Tests war schlüssig.

**Schlussfolgerung** Die Studie dokumentiert die hohe Sensitivität und Spezifität der Sonografie bei der Diagnose der Kraniosynostose in einem Spezialzentrum, mit besseren Ergebnissen vor dem 6. Lebensmonat. Die wichtigsten Einschränkungen sind die geringere Aussagekraft bei zunehmendem Alter und der erforderliche Lernprozess; Vorteile sind die Vermeidung der Strahlenbelastung und die Möglichkeit, das Gehirn gleichzeitig zu untersuchen.

## Introduction

Craniosynostosis (CS) is one of the most frequent malformations in newborns, affecting 1:2000–1:2500 live births, mainly males [1]. CS is characterized by premature fusion of the cranial sutures, resulting in an abnormal head shape. CS is often categorized, according to the cause, as primary and secondary. In the latter case, CS could be due to metabolic disorders or drug use as phenytoin or valproic acid during pregnancy [2]. CS may be simple, involving only one main cranial suture, or complex, affecting multiple sutures as part of a syndromic pattern [1]. Cranial sutures are essential for correct brain expansion. If one suture is fused, the “compensatory” skull growth occurs in parallel planes, resulting in the recognizable skull and head deformities [3, 4]. Complex CS is frequently associated with abnormal craniofacial growth, resulting in hydrocephalus, Chiari malformation, upper airway obstruction, and intracranial hypertension, negatively impacting neurodevelopment [5]. In contrast, the effects of simple CS are still a matter of debate, ranging from cosmetic problems to mild neurodevelopmental delay and cerebellar ectopia.

During the last years, the number of evaluations of skull deformities has dramatically increased, both for improved CS awareness and due to the worldwide application of the “Back to sleep campaign”, promoted by the American Academy of Pediatrics, in favor of supine sleep to prevent sudden infant death syndrome [6]. A prolonged supine sleep position can lead to cranial deformations, secondary to the prolonged stay in the same position. Such deformations are defined as positional plagiocephaly (PP), which ameliorates with compensatory position changes. On the contrary, a true CS requires surgical treatment, usually within 12 months of life [1]. Therefore, an early differential diagnosis between PP and CS is advisable.

For a very long time, skull X-rays (sx-r) were the first-line examination to evaluate an abnormal head shape, followed by 3D-computerized tomography (3D-CT) to confirm and define the diagnosis. Nowadays, 3D-CT has become the diagnostic imaging method of first choice [1]. Anamnesis with accurate, repeated

clinical evaluation is the stronghold for a correct suspicion [7], but the increased prevalence of PP and the concerns about the risks of leukemia and brain tumors related to ionizing radiation exposure [8, 10, 9], caused physicians to reduce the number of 3D-CT, looking for a radiation-free diagnostic imaging technique able to differentiate between CS and PP. Several studies suggested that, due to its characteristics, such as the low cost and the lack of ionizing radiations, cranial ultrasound (CUS) could represent an optimal first-line examination [8].

Therefore, we aim to analyze and evaluate the accuracy of Superficial Cranial Ultrasound (SCUS), considered the index exam for the diagnosis of CS, in a prospectively collected series of consecutive children with cranial deformities.

## Materials and methods

We retrospectively reviewed prospectively collected databases including consecutive infants referred to a multidisciplinary craniofacial team from 2011 to 2019 for abnormal head shapes. With parental consent, we collected the following data: age, sex, birth weight, gestational age, conception and birth type, diagnostic suspicion. Moreover, other adjunctive data were recorded, such as the preferential position while sleeping, the head shape evolution, maternal uterine fibroids, drug consumption during pregnancy, or familiarity with CS. All patients underwent SCUS with a complete evaluation of six major sutures: metopic, sagittal, bicoronal, and lambdoids. All SCUS examinations were performed by the same operator, a neonatologist with twenty years of experience performing ultrasound in newborns. The same ultrasound device (Logiq 5, GE Healthcare, USA), equipped with an 11 MHz linear transducer, was used for all examinations. The children were in a supine position in the arm of the parents, held by the shoulders to expose the whole head to the examiner. To obtain better compliance, we used maternal breastfeeding or a bottle in newborns up to 6 months of age, while the parents' cooperation and the use of songs or games were helpful in older

children. With these measures, all exams were able to be performed without sedation.

### Imaging evaluation

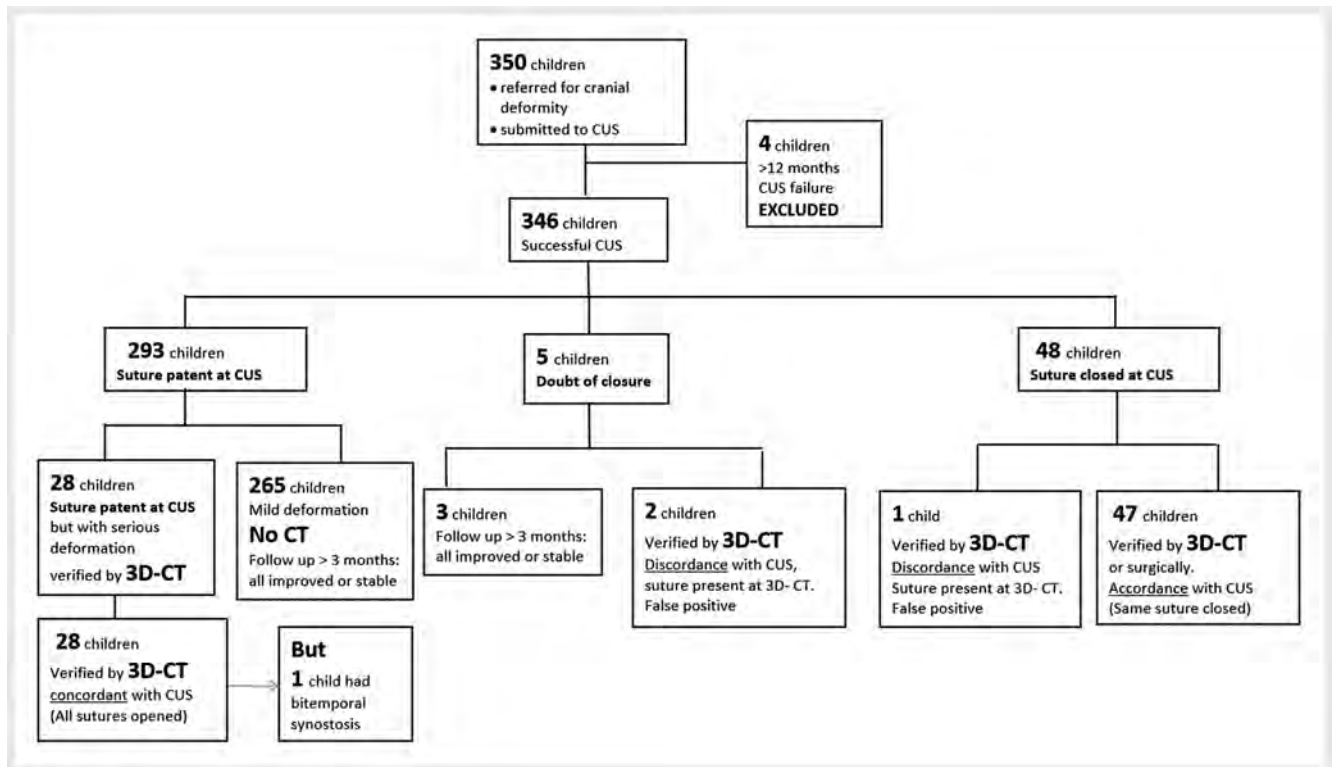
While performing SCUS, the probe is moved along the whole length of the sutures, with the transducer lying perpendicular to the skull and to the major suture axis, to obtain coronal sections on the sutures and cranial bones. The sutures appear as an anechogenic gap between two hyperechogenic plates represented by the cranial bones. A cranial suture was considered physiologically patent if no hyperechogenic bridges were found, with an anechogenic gap measuring at least 0.5 mm. In the case of hyperechoic bridging, with or without a bone ridge, the suture was defined as synostotic, and the length of the fusion was measured.

If SCUS showed synostosis (positive) or it was doubtful, children were referred to the neuroradiologists to obtain further examinations. In such cases, a 3D-CT scan was performed with children during spontaneous sleeping using a fast scanning and low radiation protocol. It included axial volumetric acquisition (thickness 0.8 mm; increment 0.3 mm; pitch 0.688 mm; rotation time 0.75 sec; collimation 16 × 0.75; mAs/slice 300; KV 120; FOV 250 × 250; matrix 512 × 512). A reconstruction algorithm for bone and soft tissue was then applied. If a 3D-CT scan was necessary, it was performed after SCUS, except in very few cases. However, in such cases a blinded protocol avoided a possible influence of the CT results on the SCUS examination. In fact, the neuroradiologists performing CT were different from the pediatricians that executed SCUS, and the two examinations were carried out at two different institutions.

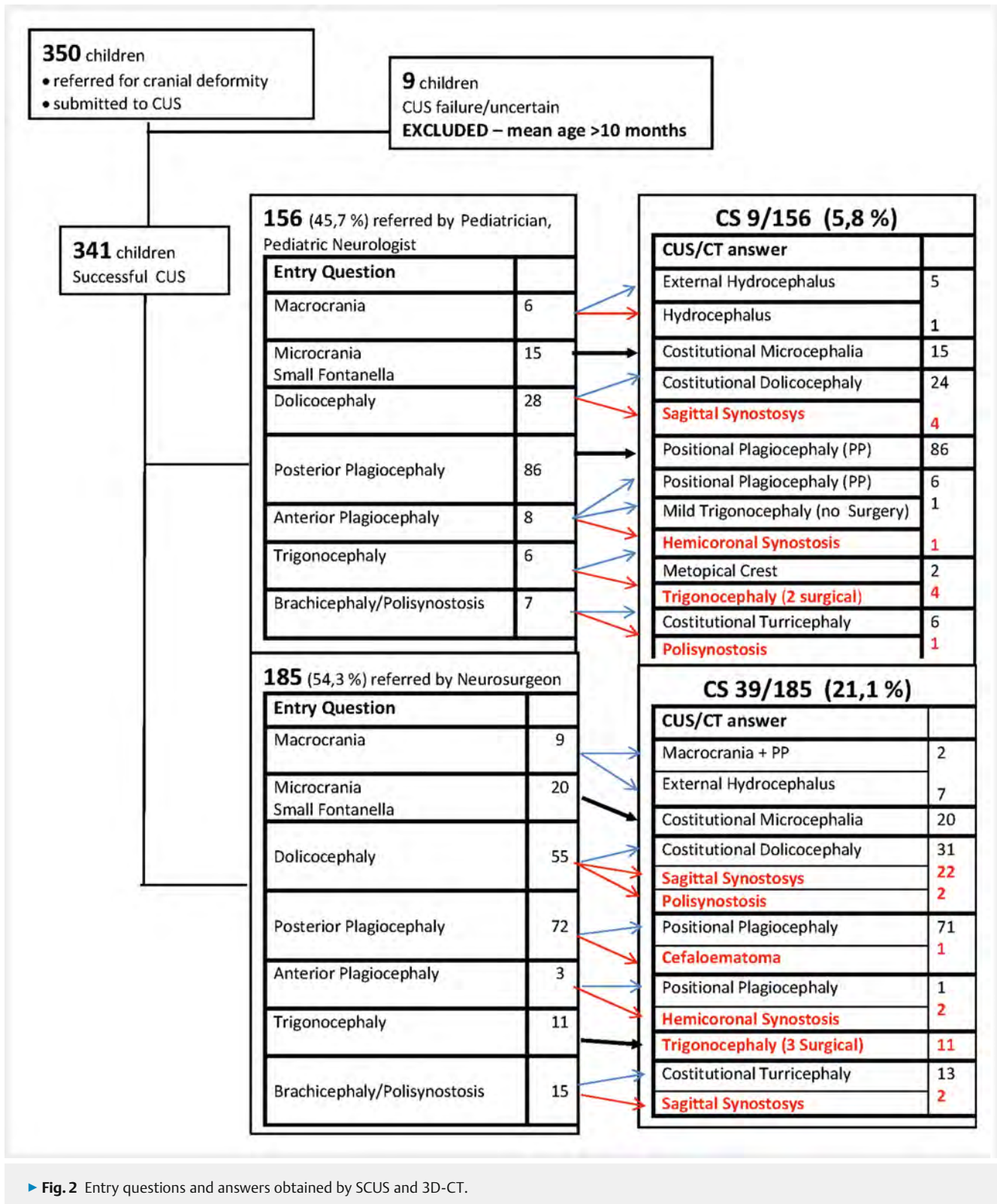
If SCUS documented patency of all sutures (and therefore, it was negative), children were strictly followed up for at least three months to evaluate normalization of the head shape with positioning and helmet therapy. In cases of no improvement, a second SCUS was performed, and a 3D-CT scan was suggested. The diagnostic pathway is plotted in ► Fig. 1.

### Statistics

SCUS sensitivity and specificity were evaluated in comparison with 3D-CT, which is considered the gold standard. To analyze the data, we performed a likelihood ratio test on two different population samples from the same cohort. The first sample includes all patients with evaluable SCUS in which the final diagnosis was obtained either by 3D-CT scan or by clinical follow-up. The second sample included only patients who underwent both SCUS and 3D-CT scans. For both groups, calculations estimate pre-test/post-test probability and pre-test/post-test odds, likelihood ratios and relative prevalence, sensitivity, specificity, and the accuracy of the test itself. The likelihood ratio value is used to define the clinical test results and their conclusiveness for diagnosing the individual patient (Supplementary Table 1). The results have also been reported in Fagan’s nomograms to provide better visualization of the pre-test and post-test probabilities and likelihood ratios of diagnostic tests. Analysis and calculations were obtained using the MATLAB and Statistics Toolbox (The MathWorks Inc, Natick, MA, US).



► Fig. 1 Diagnostic flowchart applied in the whole series of 350 babies (CUS, 3D-CT, and follow-up results).



► Fig. 2 Entry questions and answers obtained by SCUS and 3D-CT.

This document was downloaded for personal use only. Unauthorized distribution is strictly prohibited.



## Results

### Patient characteristics

The whole series comprises 350 infants with an abnormal head shape. In all cases, SCUS was well tolerated, without any need for sedation or other pharmacological therapies. The total cohort was composed of 232 males (66.3%) and 118 females (33.7%), ranging in age between 0 and 18 months at the time of SCUS (average 4.4 months, median 4.2). 56.3% of the children were born via uncomplicated vaginal delivery, while 39.1% were delivered via cesarean section. In 4.6% of cases, a suction cap was necessary. The mean gestational age was 38.5 weeks (median 39), and the mean birth weight was 3182.1 g (median 3245 g).

The cranial deformities that lead to clinical observation were: posterior plagiocephaly (right, left, or both) in 159 children

(45.4%), dolichocephaly in 84 (24%), brachycephaly in 26 (7.4%), trigonocephaly in 17 (4.9%), anterior plagiocephaly in 13 (3.7%), microcephaly in 34 (9.7%), and other deformations in 17 (4.9%). The overall population characteristics are summarized in **Supplementary Table 2**.

### Superficial Cranial Ultrasound evaluation

SCUS was successfully executed in 341/350 patients. In 4 cases, imaging failed due to age-related restlessness and failure to see the gap between bones (mean age of this group 13.8 months, see ► **Fig. 1**). In 5 children, the result was unclear, so it was not possible to strongly confirm or exclude a possible CS. This subgroup of nine children was excluded from the analysis (but the children were strictly monitored to see the clinical evolution). In 48 infants, SCUS documented partial or complete fusion of one or more sutures (SCUS positive); in the remaining 293, it was negative (► **Fig. 2**). In patients referred for macrocephaly and complete CS, a transfontanelar scan was performed.

The results of SCUS were examined according to the clinical suspicion and to the physicians that required the examination. 192 infants (54.9%) were referred by neurosurgeons, 132 (37.7%) by pediatricians, 22 (6.3%) by pediatric neurologists, 4 (1.1%) by other professionals such as osteopaths and physiotherapists. To analyze the concordance between entry questions and SCUS/CT results, we dichotomized this aspect as all clinicians (45.7%) versus neurosurgeons (54.3%). As expected, the percentage of CS was higher in the group referred by neurosurgeons (21.1% vs. 5.8%). More interestingly, in our series none of the clinical diagnoses of PP, macro- or microcephaly, or early fontanelle closures, were confirmed by SCUS/CT as being related to CS (► **Fig. 2**).

A 3D-CT scan was performed in 48 SCUS-positive cases and 28/293 SCUS-negative cases if a severe deformity had not improved at follow-up. The remaining 265 SCUS-negative cases underwent strict clinical follow-up; none of them showed CS. 3D-CT confirmed SCUS results in 75/76 cases: 47/48 SCUS-positive cases (true positives), with a concordance of involved suture and length of synostotic tract and 28/28 SCUS-negative cases (true negatives). One SCUS-positive case was a false positive, since 3D-CT visualized all sutures physiologically open. CS

► **Table 1** Statistical evaluation of the population sample with craniosynostosis.

CS (n = 47)		
Male		35 (74.5%)
Female		12 (25.5%)
Age (range)		1 day – 10 months
▪ Mean (± SD)		3.0 months (± 2.5)
▪ Median		4 months
Gestational age (gestational weeks)		
▪ Mean (± SD)		38.6 (± 1.9)
▪ Median		39
Birth weight (grams)		
▪ Mean (± SD)		3304.0 (± 567.8)
▪ Median		3407.5
Kind of delivery		
▪ Uncomplicated vaginal delivery		25 (53.2%)
▪ Caesarean section		19 (40.4%)
▪ Obstetric suction cap		3 (6.4%)
Assisted fertilization		3(6.4%)
Clinical head deformity		Prevalence M/F
▪ Scaphocephaly	28 (59.6%) 5f 23 m	4.6:1 (82.1% – 17.9%)
▪ Trigonocephaly	10 (21.3%) 2f 8 m	4:1 (80.0% – 20.0%)
▪ Anterior plagiocephaly	4 (8.5%)	1:1
▪ Brachycephaly	5 (10.6%) 3f 2 m	0.7:1 (40.0% – 60.0%)
First observation		
▪ Neurosurgeon		38 (80.9%)
▪ Pediatrician		8 (17.0%)
▪ Infant neuropsychiatrist		1 (2.1%)

► **Table 2** Likelihood ratio test performed on patients with evaluable results (9 children excluded).

n. subjects = 341	Result (%)	Confidence interval 95%
Prevalence	13.8	10.3 – 17.9
Sensitivity	100	92.5 – 100
Specificity	99.7	98.1 – 99.9
Positive predictive value	97.9	86.9 – 99.7
Negative predictive value	100	
Test accuracy	99.7	98.4 – 100.0
Likelihood ratio + (LR+)	294	41.6 – 2080.3
Likelihood ratio – (LR–)	0	0

was primary in 46/48 cases and secondary in 2 cases: one child with sagittal and bicoronal synostosis was affected by hypophosphatemic rickets, and another with bitemporal synostosis had congenital hyperthyroidism.

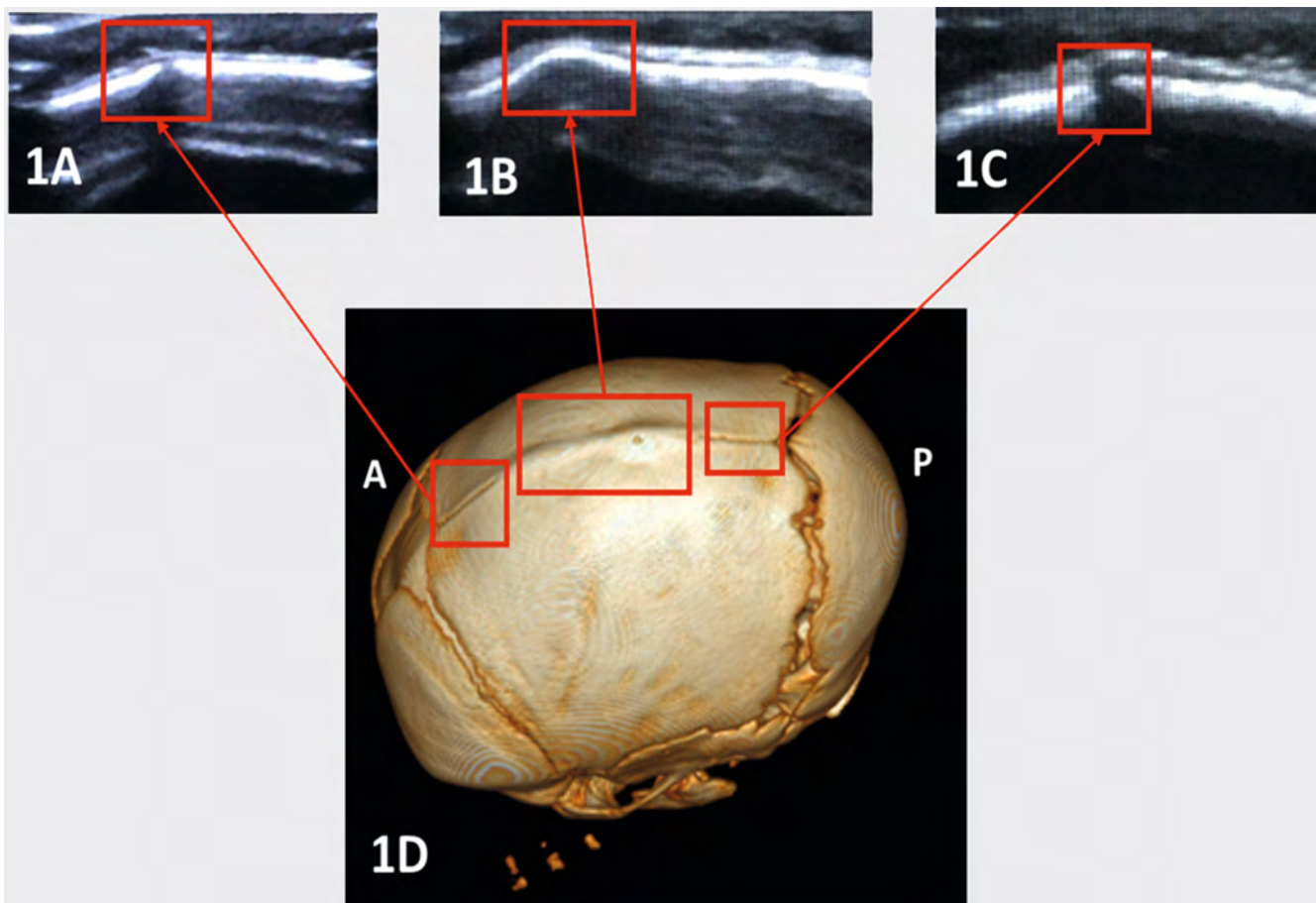
### Concordance between SCUS and 3 D-CT imaging

The likelihood ratio test was performed on two different population samples: the first one comprised all cases in which SCUS yielded evaluable results (341 children, **Supplementary Table 2**), the second one included only the 47 confirmed CS cases (**► Table 1**). Concerning the first group, we constructed a 2×2 table composed of true positives, false positives, true negatives, and false negatives (**Supplementary Table 3**). We defined healthy patients as those who were negative on 3D-CT (gold standard) or on clinical follow-up and affected patients as those with positive 3D-CT. Children showing SCUS signs of premature closure of one or more sutures were considered positive; the remaining ones were considered negative (341 children). Results from the test are summarized in **► Table 2**. We calculated a pre-test probability of illness of 13.8% (10.3%–17.9%, odds pre-test: 0.16) and a post-test probability of 97.9% (86.9–99.7%, odds post-test: 15.7). A Fagan's nomogram reports the results for the first cohort

(**Supplementary Fig. 1**). A second likelihood ratio test was carried out on a restricted patient cohort (**Supplementary Table 4**). In this case, we analyzed the diagnostic accuracy measurements only in the children that underwent both SCUS and 3 D-CT (gold standard) (**Supplementary Table 5**). This latter cohort showed a pre-test probability of illness of 61.8% (95% CI: 50.0–72.8%, odds pre-test: 1.62), and a post-test probability of 97.9% (95% CI: 87.3–99.7%, odds post-test: 47.0). The results for the restricted cohort are reported as Fagan's nomogram (**Supplementary Fig. 2**).

### Discussion

The current study confirmed the high efficacy of SCUS for evaluating the skull and cranial sutures. During the last decades, ultrasound examination has dramatically improved and it has become a point-of-care technique [9]. It is a quick, repeatable, and fairly inexpensive technique. Furthermore, it is radiation-free. This last topic became relevant after the alert about correlation between radiation and leukemia-brain tumors [10, 11, 12]. Also, in the field of CS, the widespread application of the ALARA principle (as low as reasonably achievable) to minimize radiation exposure sug-



**► Fig. 3** Dolichocephaly with partial synostosis of the sagittal suture, associated with a bone ridge. **1 D** (3D-CT) confirms CUS results. We can see the agreement between the two methods: the anterior tract is unfused **1A**, the bone bridge corresponds with the ridge **1B**, and the posterior tract is also unfused **1C**. A: anterior; P: posterior.

gests postponing 3D-CT, if necessary, until after the third month of life [1]. Different diagnostic dilemmas lead to neuroimaging evaluation in abnormal cranial shapes, ranging from deformities to micro- or macrocephaly, or simply crests and fontanelle dimensions. Both high and low cranial volumes with shape deformity are reported to be associated with CS. The cranial volume and the dimensions of the fontanelle were often the suspicious findings that led to SCUS in our series, in both referral groups (clinicians 14.5%, neurosurgeons 15.7%). However, SCUS excluded CS in all cases, determining the correct diagnostic pathway (► Fig. 2). If the entry question was, instead, “deformation”, the diagnosis of CS was more frequent in children referred by neurosurgeons (21%).

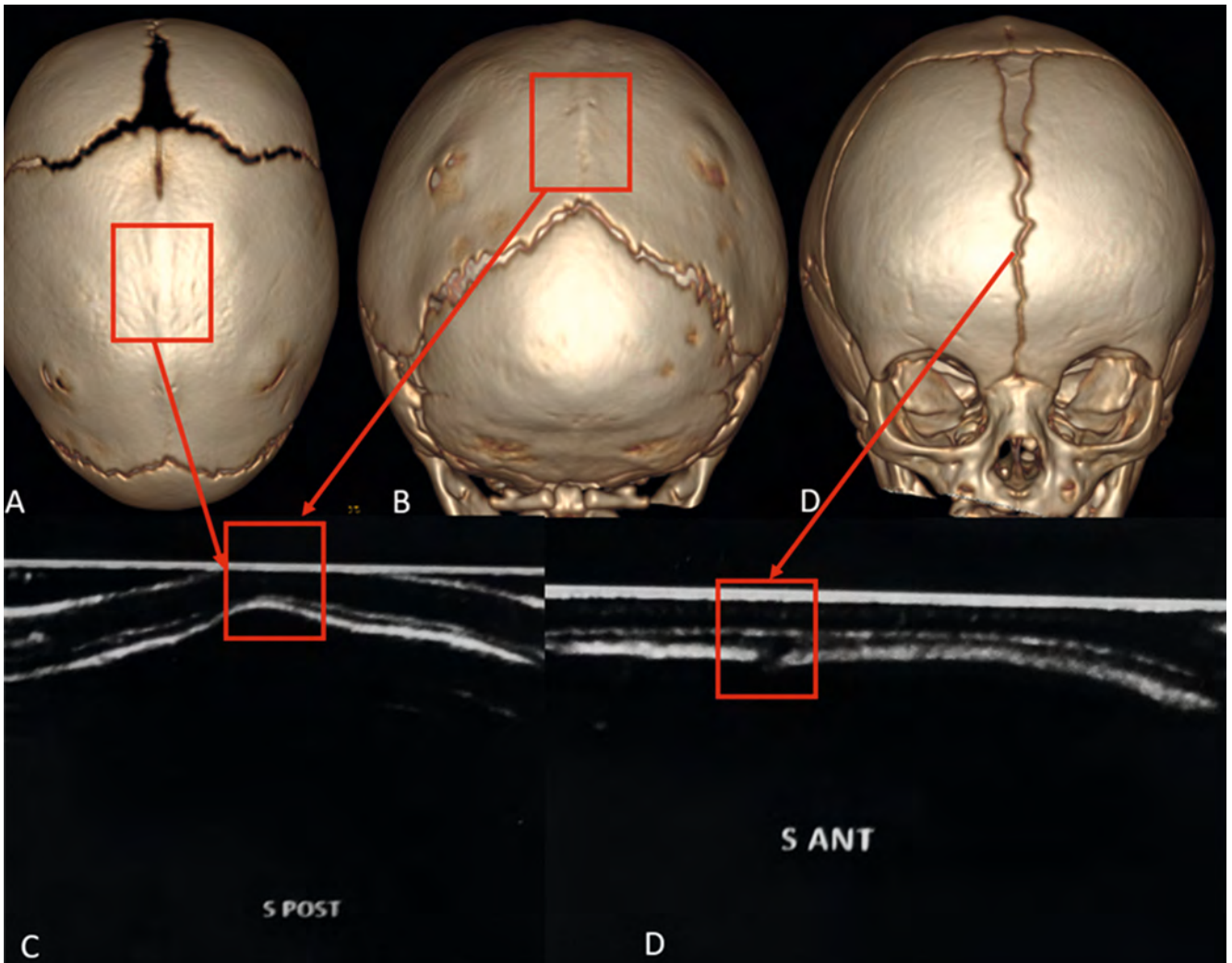
### Suitability of SCUS for decision making

In this scenario, we evaluated the role of SCUS for the diagnosis of CS in one of the largest cohorts of infants ever reported [15, 18, 17, 16]. Comparing SCUS and 3D-CT results, the study confirmed the diagnostic accuracy of SCUS in CS. Considering the whole

cohort of performed SCUS examinations (341 children), we found a sensitivity of 100%, a specificity of 96.6%, with positive and negative predictive values of 97.9% and 100%, respectively. The negative predictive value allowed us to exclude the disease in the case of a negative SCUS examination. More interestingly, when performing an analysis of the highly selected cohort of children who underwent both SCUS and 3D-CT (76), the pre-test probability of CS is higher than expected, and the post-test probability is consistent with 97.9% in the case of a positive SCUS examination, while it is 0% in negative SCUS examinations, thus excluding the presence of CS.

Our results confirmed in a large cohort what was previously reported in smaller series [13].

Sze et al. showed sensitivity of 100% and specificity of 89% in 41 patients, comparing CT and CUS results for evaluating the lambdoid suture [14]. Alizadeh compared CUS and CT results in 44 patients, obtaining a sensitivity of 96.9% and a specificity of 100%, with a positive predictive value of 100% and a negative predictive value of 92.3% [15]. In 2016, Rozovsky et al. analyzed



► **Fig. 4** Dolichocephaly with complete synostosis of the sagittal suture and compensating diastasis of the anterior fontanelle and metopic suture. Images **A, B** (3D-CT) confirm the CUS results in **C** of sagittal closure, while **D** depicts the compensatory metopic diastasis anticipated by SCUS.



126 infants with similar results [16]. Hall et al. demonstrated a sensitivity, specificity, and negative predictive value of 100% for CUS compared to CT or clinical follow-up [17], and similar results were also obtained by Proisy and coauthors [18], always in smaller series compared to the current one. Based on these results, Safran and coauthors included CUS among the promising innovative diagnostic technologies able to improve the standard of care for CS [19].

Our study reports complete agreement between SCUS and 3D-CT with respect to affected suture and fusion length, particularly if the two techniques were performed in close temporal proximity to one another (► Fig. 3). Moreover, SCUS was also able to document the compensatory diastasis of the fontanelle and other sutures (► Fig. 4) and the presence of Wormian bones (► Fig. 5).

SCUS is particularly relevant in PP, as also suggested by other groups [25, 23, 24, 26]. In our series, none of the PP children were confirmed as CS. This aspect is relevant because an early diagnosis of PP improves the correction rate with postural and helmet therapy, whose efficacy is inversely related to age [20]. Another advantage of SCUS is that sedation or nurse assistance is unnecessary. Parent collaboration significantly contributes to obtaining conclusive results. To further reduce observation time and limit inhomogeneity between operators, Okamoto proposed a 2-point method [21], but this technique may fail to identify partial closures.

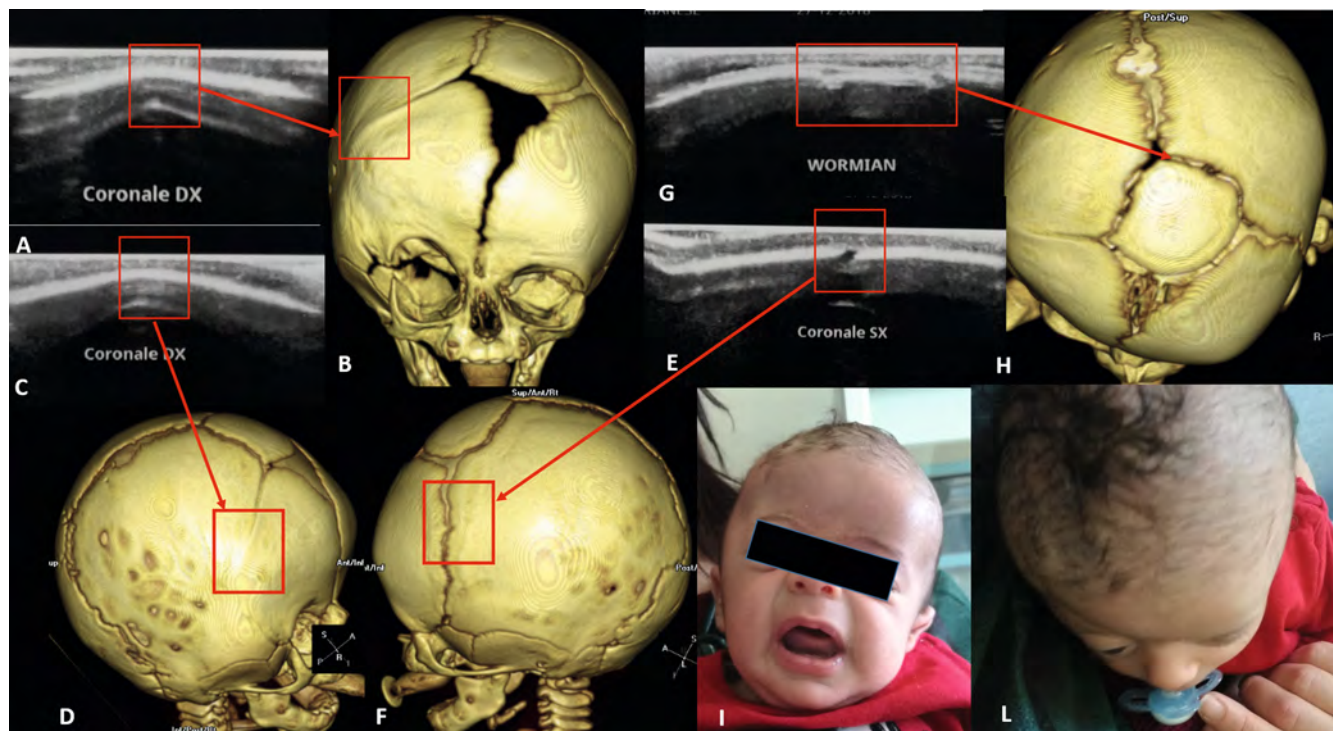
Our data on clinical evaluation show that even neurosurgical suspicion, despite being more accurate than the pediatrician's

assessment, may fail. Only SCUS reaches the same accuracy as 3D-CT, so that it is a candidate for use in selected cases. Finally, CUS can “have a quick look” inside the brain (depending on the child's age), especially in complex CS [21], which often needs multiple examinations in case of multistep treatments.

### Limitations

The main SCUS limitation is age. In children about one year old, the technique becomes less significant because it recognizes the “gap” between two bones that progressively decreases, as documented by CT on normal children [22]. Contrary to Okamoto [23], who reported some diagnoses after one year using ultrasound, we found the method problematic in older children due to lower compliance and the presence of thick hair. We consider the “golden age” for SCUS to be between 3 and 6 months. Consequently, the high reliability documented in our series could be linked to the selection bias of the young patient age (4.4 months).

Another limitation is the time relation between SCUS and suture closure: all sutures are expected to be open at birth and to close during the first and the second year of life, except for the metopic suture, which may be closed physiologically at term. Therefore, a closed suture is diagnostic for primary CS. In rare secondary CS cases, sutures are open at birth and close later on. Consequently, a proper diagnosis may depend on the timing of the SCUS and 3D-CT examinations. Therefore, clinical follow-up plays an important role and repeat SCUS is needed in the case of unexpected clinical worsening. The minor sutures, such as the sphenofrontal and squamosal sutures, are hard to identify and



► Fig. 5 Anterior plagiocephaly due to a right hemicoronal synostosis, causing orbital I and frontal L asymmetry. SCUS documented the right hemicoronal closure A, C, confirmed by 3D-CT B, C, the patent left hemicoronal E, confirmed by 3D-CT F, and the presence of a Wormian bone G also confirmed by CT H. [rerif]



are variable in appearance. Furthermore, SCUS is operator-dependent. This limitation is overcome by performing SCUS in a referral center by trained and experienced operators.

## Conclusion

The present study strongly confirms the accuracy of SCUS for the differential diagnosis between CS and PP. The absence of radiation means that SCUS can be repeated as necessary, starting on the first day of life. Consequently, SCUS is useful for diagnosis, making it possible to delay 3D-CT, and also for follow-up. Prospectively, SCUS should be considered the first-line imaging method in cranial deformity, thereby restricting the need for 3D-CT only to surgical cases.

## Conflict of Interest

The authors declare that they have no conflict of interest.

## References

- [1] Mathijssen IMJ. Guideline for Care of Patients With the Diagnoses of Craniosynostosis: Working Group on Craniosynostosis. *J Craniofac Surg* 2015; 26: 1735–1807
- [2] Jentink J, Loane MA, Dolk H et al. Valproic acid monotherapy in pregnancy and major congenital malformations. *N Engl J Med* United States 2010; 362: 2185–2193. doi:10.1056/NEJMoa0907328
- [3] Furuya Y, Edwards MS, Alpers CE et al. Computerized tomography of cranial sutures. Part 1: Comparison of suture anatomy in children and adults. *J Neurosurg* United States 1984; 61: 53–58. doi:10.3171/jns.1984.61.1.0053
- [4] Morris LM. Nonsyndromic Craniosynostosis and Deformational Head Shape Disorders. *Facial Plast Surg Clin North Am* United States 2016; 24: 517–530. doi:10.1016/j.fsc.2016.06.007
- [5] Choi JW, Lim SY, Shin H-J. Craniosynostosis in Growing Children: Pathophysiological Changes and Neurosurgical Problems. *J Korean Neurosurg Soc* 2016; 59: 197–203. doi:10.3340/jkns.2016.59.3.197
- [6] American Academy of Pediatrics AAP Task Force on Infant Positioning and SIDS: Positioning and SIDS. *Pediatrics* United States 1992; 89: 1120–1126
- [7] Ghizoni E, Denadai R, Raposo-Amaral CA et al. Diagnosis of infant synostotic and nonsynostotic cranial deformities: a review for pediatricians. *Rev Paul Pediatr* 2016; 34: 495–502. doi:10.1016/j.rpped.2016.01.004
- [8] Linz C, Collmann H, Meyer-Marcotty P et al. Occipital plagiocephaly: unilateral lambdoid synostosis versus positional plagiocephaly. *Arch Dis Child England* 2015; 100: 152–157. doi:10.1136/archdischild-2014-305944
- [9] Moore CL, Copel JA. Point-of-care ultrasonography. *N Engl J Med* United States 2011; 364: 749–757. doi:10.1056/NEJMra0909487
- [10] Brenner D, Elliston C, Hall E et al. Estimated risks of radiation-induced fatal cancer from pediatric CT. *AJR Am J Roentgenol* United States 2001; 176: 289–296. doi:10.2214/ajr.176.2.1760289
- [11] Domeshek LF, Mukundan SJ, Yoshizumi T et al. Increasing concern regarding computed tomography irradiation in craniofacial surgery. *Plast Reconstr Surg* United States 2009; 123: 1313–1320
- [12] Persing J, James H, Swanson J et al. Prevention and management of positional skull deformities in infants. American Academy of Pediatrics Committee on Practice and Ambulatory Medicine, Section on Plastic Surgery and Section on Neurological Surgery. *Pediatrics* United States 2003; 112: 199–202. doi:10.1542/peds.112.1.199
- [13] Simanovsky N, Hiller N, Koplewitz B et al. Effectiveness of ultrasonographic evaluation of the cranial sutures in children with suspected craniosynostosis. *Eur Radiol Germany* 2009; 19: 687–692
- [14] Sze RW, Parisi MT, Sidhu M et al. Ultrasound screening of the lambdoid suture in the child with posterior plagiocephaly. *Pediatr Radiol Germany* 2003; 33: 630–636
- [15] Alizadeh H, Najmi N, Mehdizade M et al. Diagnostic accuracy of ultrasonic examination in suspected craniosynostosis among infants. *Indian Pediatr India* 2013; 50: 148–150
- [16] Rozovsky K, Udjus K, Wilson N et al. Cranial Ultrasound as a First-Line Imaging Examination for Craniosynostosis. *Pediatrics* United States 2016; 137: e20152230. doi:10.1542/peds.2015-2230
- [17] Hall KM, Besachio DA, Moore MD et al. Effectiveness of screening for craniosynostosis with ultrasound: a retrospective review. *Pediatr Radiol Germany* 2017; 47: 606–612
- [18] Proisy M, Riffaud L, Chouklati K et al. Ultrasonography for the diagnosis of craniosynostosis. *Eur J Radiol Ireland* 2017; 90: 250–255. doi:10.1016/j.ejrad.2017.03.006
- [19] Safran T, Viezel-Mathieu A, Beland B et al. The State of Technology in Craniosynostosis. *J Craniofac Surg* United States 2018; 29: 904–907. doi:10.1097/SCS.0000000000004399
- [20] Mazzola C, Baird LC, Bauer DF et al. Guidelines: Congress of Neurological Surgeons Systematic Review and Evidence-Based Guideline for the Diagnosis of Patients With Positional Plagiocephaly: The Role of Imaging. *Neurosurgery* United States 2016; 79: E625–E626
- [21] Massimi L, Bianchi F, Frassanito P et al. Imaging in craniosynostosis: when and what? *Child's Nerv Syst ChNS Off J Int Soc Pediatr Neurosurg Germany* 2019; 35: 2055–2069
- [22] Rozovsky K, Barrowman NJ, Miller E. Centile charts for cranial sutures in children younger than 1 year based on ultrasound measurements. *Pediatr Radiol Germany* 2018; 48: 701–707
- [23] Okamoto T, Nuri T, Harada A et al. Cranial Suture Measurement by 2-point Method in Ultrasound Screening of Craniosynostosis. *Plast Reconstr surgery Glob open* 2019; 7: e2225. doi:10.1097/GOX.00000000000002225
- [24] Pearce MS, Salotti JA, Little MP et al. Radiation exposure from CT scans in childhood and subsequent risk of leukaemia and brain tumours: a retrospective cohort study. *Lancet (London, England)* 2012; 380: 499–505
- [25] Mathews JD, Forsythe A V, Brady Z et al. Cancer risk in 680,000 people exposed to computed tomography scans in childhood or adolescence: data linkage study of 11 million Australians. *BMJ* 2013; 346: f2360. doi:10.1136/bmj.f2360
- [26] Proisy M, Bruneau B, Riffaud L. How ultrasonography can contribute to diagnosis of craniosynostosis. *Neurochirurgie France* 2019; 65: 228–231. doi:10.1016/j.neuchi.2019.09.019
- [27] Regelsberger J, Delling G, Helmke K et al. Ultrasound in the diagnosis of craniosynostosis. *J Craniofac Surg* United States 2006; 17: 623–628. doi:10.1097/00001665-200607000-00002
- [28] Regelsberger J, Delling G, Tsokos M et al. High-frequency ultrasound confirmation of positional plagiocephaly. *J Neurosurg* United States 2006; 105: 413–417. doi:10.3171/ped.2006.105.5.413
- [29] Krimmel M, Will B, Wolff M et al. Value of high-resolution ultrasound in the differential diagnosis of scaphocephaly and occipital plagiocephaly. *Int J Oral Maxillofac Surg Denmark* 2012; 41: 797–800. doi:10.1016/j.jjom.2012.02.022
- [30] Robinson S, Proctor M. Diagnosis and management of deformational plagiocephaly. *J Neurosurg Pediatr* United States 2009; 3: 284–295. doi:10.3171/2009.1.PEDS08330