Article published online: 2022-08-17

Endocavitary Contrast-Enhanced Ultrasound

Kontrastmittelverstärkter Ultraschall: Endokavitäre Applikationen

Authors
Kurt Vollert[1], Dirk Andre Clevert[2], Timm Kleffel[1]

Affiliations
1 Klinik für diagnostische und interventionelle Radiologie und Neuroradiologie, Universitätsklinikum Augsburg, Germany
2 Institut für Klinische Radiologie, Campus Grosshadern, Klinikum der Universität München, Munchen, Germany

Key words
contrast enhanced ultrasound, endocavitary, diagnostic ultrasound, interventional ultrasound, contrast agents

received 31.10.2021
accepted 05.03.2022
published online 17.08.2022

Bibliography
Fortschr Röntgenstr 2022; 194: 1204–1214
DOI 10.1055/a-1826-0325
ISSN 1438-9029
© 2022. Thieme. All rights reserved.
Georg Thieme Verlag KG, Rüdigerstraße 14, 70469 Stuttgart, Germany

Correspondence
Dr. Timm Kleffel
Klinik für diagnostische und interventionelle Radiologie und Neuroradiologie, Universitätsklinikum Augsburg, Stenglinstr. 2, 86156 Augsburg, Germany
Tel.: +49/08 21/4 00 24 41
timm.kleffel@uk-augsburg.de

ABSTRACT

Background Ultrasound is one of the most important imaging methods in the daily routine. Contrast-enhanced ultrasound (CEUS) has put ultrasound on equal footing with computed tomography and magnetic resonance imaging in many areas. Although ultrasound contrast agents are commonly administered intravenously, endocavitary application as performed in the case of iodine-containing contrast agents is also possible.

Method Based on the current literature, this overview provides information regarding possible endocavitary applications of ultrasound contrast agents as they are used and could be used in the daily routine in radiology. Examples are provided to illustrate the advantages and disadvantages of clinical use.

Results and Conclusion Endocavitary CEUS broadens the spectrum of possible ultrasound applications and can be safely used for patient diagnosis and treatment. The method can be safely used for diagnosis and patient management, particularly in patients in whom examinations including exposure to radiation with iodine-containing contrast agents may be contraindicated and who have limited mobility due to disease severity.

Key points:

- Endocavitary CEUS is a safe method that can be readily learned by those with prior ultrasound training. Radiologists benefit from their existing knowledge of contrast-enhanced imaging.
- With ultrasound contrast agents, endocavitary examinations comparable to CT and fluoroscopy can be performed without having to take radiation exposure, preexisting conditions, and patient mobility into consideration.
- In principle, endocavitary CEUS can access every body cavity (physiological and pathological) and body orifice with any access device.
- The method is mainly used for interventions including puncture and drainage. The diluted ultrasound contrast agent can be continuously visualized in the access device and in the target region, including distribution within the target region, with high spatial and temporal resolution. Voiding urosonography and visualization of the salivary duct system should also be mentioned in the radiological context.
- Poor B-mode imaging conditions typically also mean poor CEUS conditions. Imaging methods that can reliably evaluate low-lying structures and structures with overlying air, particularly in obese patients, without artifacts and can provide a good overview have a clear advantage here.

Citation Format

- Vollert K, Clevert DA, Kleffel T. Endocavitary Contrast-Enhanced Ultrasound. Fortschr Röntgenstr 2022; 194: 1204–1214

ZUSAMMENFASSUNG

Hintergrund Ultraschall ist eine der wichtigsten bildgebenden Verfahren in der täglichen Routine. Die kontrastmittelverstärkte Sonografie (CEUS) hat die Methode in vielen Bereichen der Computertomografie und der Magnetresonanztomografie ebenbürtig gemacht. In Anlehnung an die endokavitäre Applikation von jodhaltigem Kontrastmittel kann Ultraschallkontrastmittel (USKM) neben der weit verbreiteten intravenösen Anwendung auch endokavitär verabreicht werden.

This document was downloaded for personal use only. Unauthorized distribution is strictly prohibited.

Methode Dieser Übersichtsartikel informiert, im Kontext der aktuellen Literatur, über die endokavitären Einsatzmöglichkeiten von USKM, wie sie im radiologischen Alltag Platz finden und finden können. Anhand von Beispielen wird die klinische Anwendung mit ihren Vor- und Nachteilen untermauert.

Ergebnisse und Schlussfolgerung CEUS endokavitär erweitert das Spektrum der sonografischen Einsatzmöglichkeiten und findet in der Patientenversorgung in Diagnostik und Therapie eine sichere Anwendung. Sicher im Sinne der Diagnostik und der Patientenführung. Gerade bei Patienten, welche einer strahlenexponierten Untersuchung mit jodhaltigem Kontrastmittel nur bedingt zur Verfügung stehen und aufgrund der Schwere der Erkrankung nur eingeschränkt mobil sind.

Introduction

Ultrasound is the world's most frequently used imaging method for primary diagnosis. Either as an independent modality or as a supplement to other radiological methods, ultrasound is one of the most important imaging methods. The development of ultrasound is remarkable. With the introduction of contrast-enhanced ultrasound (CEUS) at the beginning of 2000 [5], the method experienced a leap forward similar to the advancement from single detector CT to multidetector CT. This article discusses endocavitary contrast-enhanced ultrasound tailored to radiology. The European Federation of Societies for Ultrasound in Medicine and Biology (EFSUMB) regularly publishes guidelines on the hepatic and non-hepatic application of ultrasound contrast agents [1, 2]. Thanks to continuous improvements in the quality of B-mode imaging, color-coded duplex sonography, elastography, contrast-enhanced ultrasound, and fusion imaging, ultrasound has become indispensable in medicine [28]. The lack of radiation exposure, the absence of a nephrotoxic contrast agent, and the ability to perform bedside diagnostics and treatment are all clear advantages.

Technical background

Structure of ultrasound contrast agents

Ultrasound contrast agents are typically comprised of gas bubbles encapsulated by a shell. Sonovue (Bracco, Milan, Italy) is discussed here since it is the most commonly used contrast agent. The shell is comprised of a phospholipid layer and sulfur hexafluoride (SF6) is used as the gas [3]. The size of the gas bubbles corresponds approximately to that of erythrocytes. The gas bubbles that oscillate during the examination (with a low mechanical index) serve as reflectors that send back signals that differ from those of the tissue and can be made visible with various technical methods [4].

Administration

The basic difference between intravenous and endocavitary application is the way in which the contrast agent is administered. Undiluted contrast agent is administered intravenously. Depending on the region to be examined and the transducer being used, 0.6 to 2.5 ml of contrast agent are typically used.

In the case of endocavitary application, dilution with NaCl is required (except for a few exceptions) since the space in which the contrast agent is dispersed is significantly smaller compared to the total blood volume in intravenous administration and there is usually a lack of circulation. This is analogous to endocavitary contrast administration in CT. Undiluted application would result in overexposure and obliteration of the dorsal structures rendering the examination unusable. The literature includes various mixing ratios [8]. The authors found a mixing ratio of 1:200 in a 20-ml syringe practical for most applications. When using a linear transducer, the concentration of contrast agent can be increased slightly since comparatively more contrast bubbles are destroyed when using higher-frequency transducers. After careful swirling of the mixture, the contrast agent is ready for endocavitary application.

Approval and side effects

Ultrasound contrast agents are typically only approved for intravasal application. Sonovue which is used most widely is approved in certain countries for various applications, patient groups, and organ systems. In Germany, use is limited to the liver, breast, and blood vessels with microvascularization and macrovascularization. Pediatric use in voiding urosonography is also approved [6]. Use in all other areas, including endocavitary use, is considered off-label. Ultrasound contrast agents do not require checking of the thyroid hormones and are not nephrotoxic since they are not eliminated by the kidneys [1]. Potenzial side effects of ultrasound contrast agents include hypersensitivity reactions ranging from reddening of the skin and pain to bronchospasm and allergic shock. However, the rate of side effects is low and, in the case of intravenous application, is comparable to that of MRI. The risk of serious adverse events is very low (less than 0.008 %). However, in the case of diluted endocavitary application, the frequency of undesired side effects is significantly lower. Therefore, it is a safe procedure [7–10].

Examination procedure

It was possible to administer the contrast agent during the examination with the hand not holding the transducer or with the help of a trained assistant. The advantage of contrast administration in ultrasound is the ability to perform a dynamic examination and to observe the continuous enhancement of the contrast agent from the first gas bubbles in the inserted instrument and in the target region to the complete distribution of the contrast agent. If the contrast mixture is administered too quickly or in too great a quantity, this information is lost. If a new wash-in of contrast agent is to be evaluated, the gas bubbles can be destroyed with the burst function (high acoustic energy) or using the color-coded duplex sonography function.

This document was downloaded for personal use only. Unauthorized distribution is strictly prohibited.

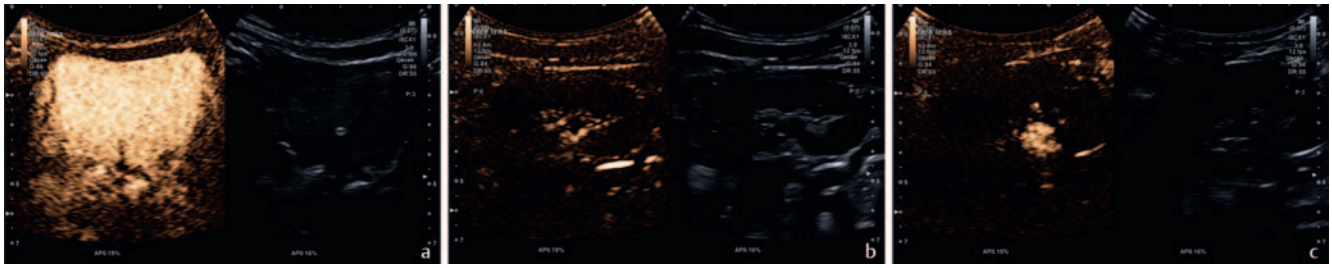

▶ **Fig. 1 a** shows a bladder filled with NaCl and contrast agent. **b** and **c** show a longitudinal section of the kidney. Contrast enhancement of the renal pelvicalyceal system is seen.

Applications

Possible applications of endocavitary CEUS in children

Indication

Ultrasound contrast agents have played an increasingly important role in the clarification of pathological findings in children in recent years. They help in many cases to decrease the use of radiological methods associated with radiation exposure. Voiding urosonography is an already established method of endocavitary application in infants and children. The goal of the examination is to rule out leakage of the contrast agent into the ureters or the renal pelvicalyceal system and to thus rule out vesicoureteral reflux (VUR). The currently established voiding urosonography method can thus be replaced in many cases by an alternative without radiation.

Examination procedure

Using this method, the contrast agent is administered via a transurethral catheter [11]. The bladder is filled with a warmed saline solution under sonographic guidance until it is one third full. A very small amount of contrast agent (approx. 0.1 ml Sonovue) is then sufficient to ensure homogeneous contrast enhancement of the bladder (▶ **Fig. 1a**). The bladder is then filled completely with a saline solution. The applied volume is based on the age of the child and can be calculated using the formula [(age in years + 2) × 30 ml]. In the case of vesicoureteral reflux, the contrast agent can be visualized in the renal pelvicalyceal system (▶ **Fig. 1b, c**). It was able to be shown in multiple studies that this method has a higher sensitivity compared to conventional voiding urosonography. Reflux grading is performed as in voiding urosonography [12]. In the case of grade I reflux, the contrast agent can only be seen in the dilated ureter. Grade II reflux is characterized by contrast agent in the soft, non-dilated calyceal system. Increasing dilation of the normal calyces indicates grade III reflux. Grade IV reflux is characterized by increasing dilation and a change in the shape of the calyces with blunting of the fornices but preserved papillary impressions. The fornices and papillary impressions are no longer present in grade V reflux [13].

Example

▶ **Fig. 1a** shows a bladder filled with saline and contrast agent. ▶ **Fig. 1b, c** shown a longitudinal section of the kidney. Contrast enhancement of the renal pelvicalyceal system is seen.

Salivary gland

Indication

Obstructive diseases of the salivary gland are a common problem in otolaryngology. Salivary stones are the most common cause of obstructive diseases, followed by duct stenosis and rarer diseases of the duct system. In approx. 5–10 % of cases, the cause is not found in spite of multiple different diagnostic options [14]. Intraductal administration of the contrast agent makes it possible to simultaneously evaluate the gland parenchyma as well as the intraglandular and extraglandular duct system.

Interruptions are caused by stenosis or a bent duct, while filling defects are typical for stones. This technique is an effective method for diagnosing and further characterizing obstructive salivary gland diseases. It is possible to simultaneously evaluate the duct system and the gland parenchyma [16–18] (▶ **Fig. 2a–d**).

With the help of this technique, the disease can be better classified, and treatment and treatment monitoring can be adjusted as needed [15, 16].

Examination procedure

In our clinical setting, the examination is performed together with the ENT department. To prepare, a topical anesthesia is applied in the form of a local anesthetic spray. The excretory duct of the gland is then examined and carefully dilated with a dilator. A 20-gauge catheter is then inserted. Contrast agent diluted with a ratio of 1:10 is then administered via the catheter [17, 18].

Using a high-frequency linear probe, the examiner performs the ultrasound examination beginning with a conventional B-mode ultrasound examination to evaluate possible signs of obstruction in the region of the intraductal and extraductal duct system. The intraductal administration of the contrast agent makes it possible to examine both the extraglandular and the intraglandular course of the duct [15–18]. The contrast agent is administered slowly. It is important to pay attention to duct obstructions, filling defects, and delays in the contrast wash-in in the gland.

This document was downloaded for personal use only. Unauthorized distribution is strictly prohibited.

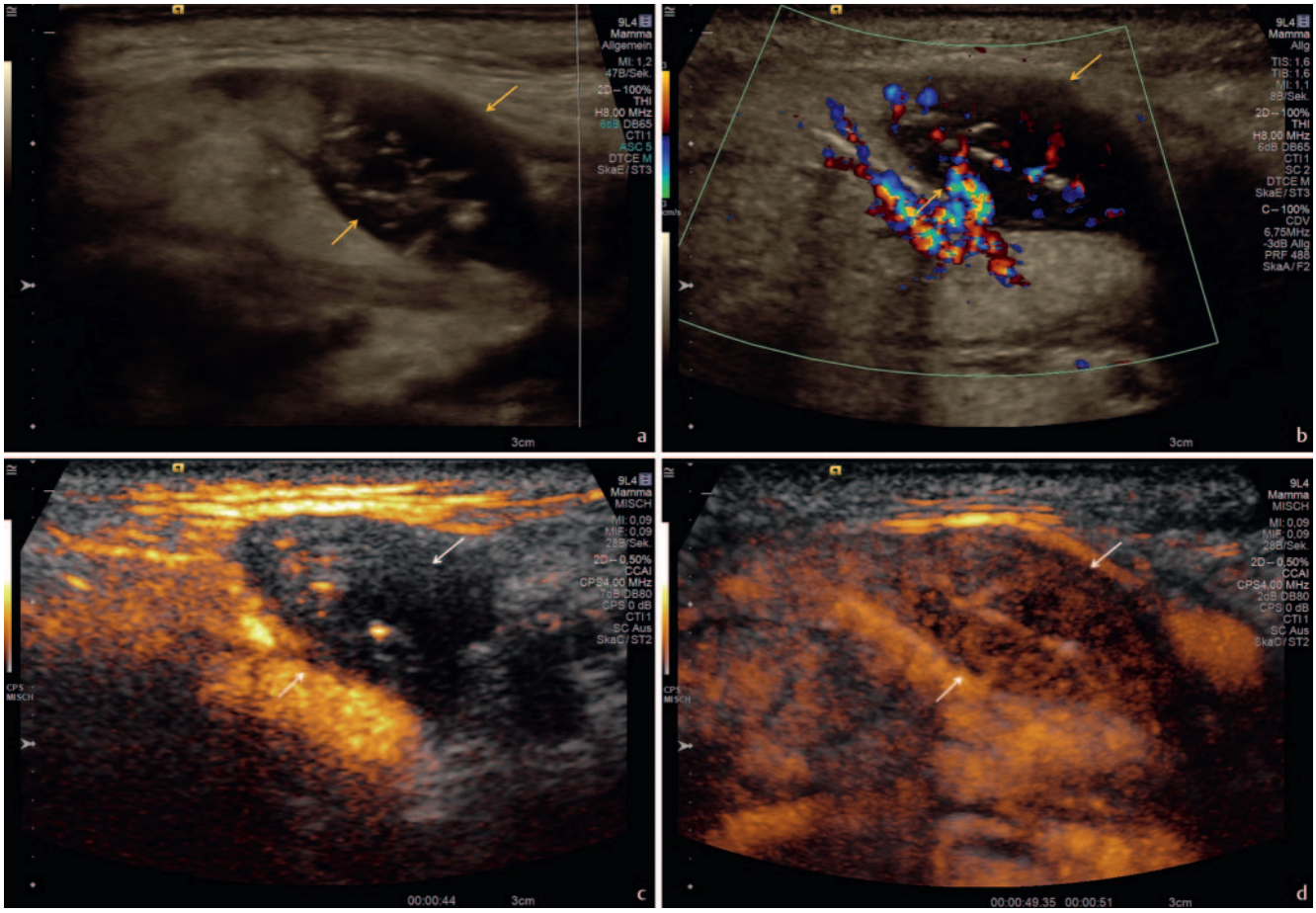

▶ **Fig. 2 a** 80-year-old patient presented at the emergency department with suspicion of left-sided submandibular sialadenitis. A partially anechoic lesion of the submandibular gland can be seen on the conventional B-mode ultrasound image (yellow arrows). **b** Individual vessels within the lesion can be seen on color-coded duplex sonography (yellow arrows). **c** After intraductal contrast agent administration, homogeneous contrast enhancement of the glandular tissue could be seen. There was no contrast enhancement of the suspicious lesion (white arrows). **d** After intravenous contrast agent administration, homogeneous contrast enhancement of the adjacent glandular tissue and the suspicious lesion (white arrows) can be seen. Based on this constellation of findings, the patient underwent submandibulectomy. Histology confirmed infiltration of mantle cell lymphoma.

Example

▶ **Fig. 2a**: 80-year-old patient presented at the emergency department with suspicion of left-sided submandibular sialadenitis. A partially anechoic lesion of the submandibular gland can be seen on the conventional B-mode ultrasound image (yellow arrows).

▶ **Fig. 2b**: Individual vessels within the lesion can be seen on color-coded duplex sonography (yellow arrows).

▶ **Fig. 2c**: After intraductal contrast agent administration, homogeneous contrast enhancement of the glandular tissue could be seen. There was no contrast enhancement of the suspicious lesion (white arrows).

▶ **Fig. 2d**: After intravenous contrast agent administration, homogeneous contrast enhancement of the adjacent glandular tissue and the suspicious lesion (white arrows) can be seen. Based on this constellation of findings, the patient underwent submandibulectomy. Histology confirmed infiltration of mantle cell lymphoma.

Oral

Indication

In principle, ultrasound contrast agents can be used in the same application areas as fluoroscopy. Of course, it is not possible to visualize the entire course from the esophagus to the gastrointestinal tract, and ultrasound plays a secondary role to conventional fluoroscopy here. Refer to the advantages of ultrasound mentioned in the introduction that benefit a selected patient group. The literature includes reports of oral administration to examine diverticula, higher-grade stenosis in the upper gastrointestinal tract, possible fistulas, and ruptures [8, 19, 30].

Examination procedure

In the case of oral administration, a larger quantity of an NaCl contrast agent mixture is needed. The authors used approximately 200 ml of tap water mixed with approximately 1 ml of Sonovue. Similar concentrations are recommended in the literature [8]. The contrast agent can be drunk in doses as in the fluoroscopic examination of the passage of contrast material. Air-filled gastro-

This document was downloaded for personal use only. Unauthorized distribution is strictly prohibited.

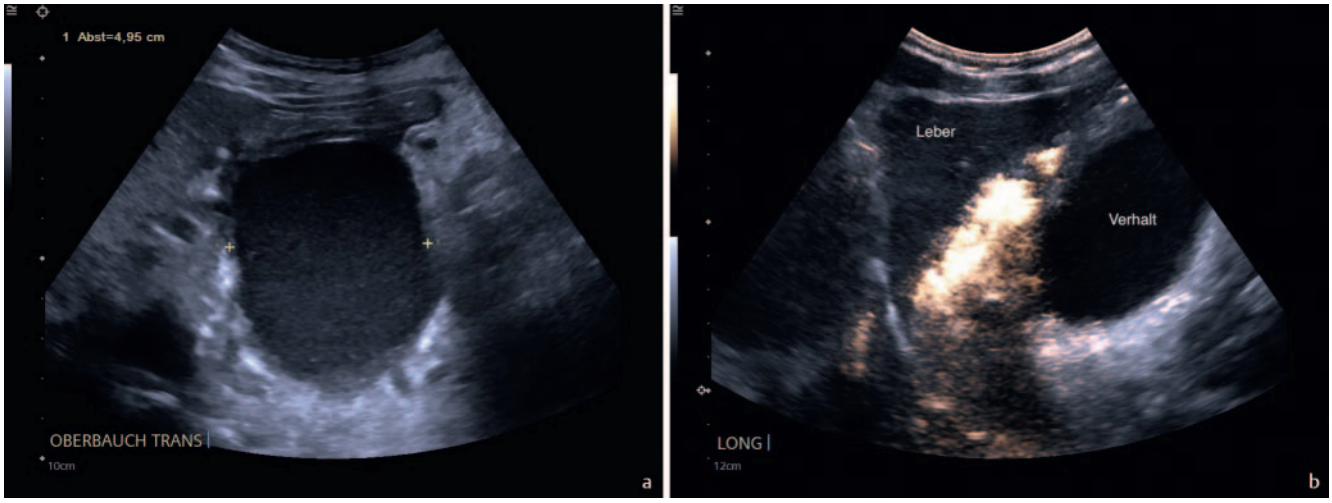

▶ **Fig. 3 a** Evidence of the collection of unclear fluid in the upper abdomen after left-sided pancreatic resection (3a, transverse upper abdominal scan). **b** To verify the diagnosis, CEUS was performed with oral contrast administration. The contrast agent is visible in the empty gastric lumen but not in the fluid collection (3b longitudinal section of the upper abdomen).

intestinal segments are sometimes as echogenic as the applied contrast agent in contrast-enhanced mode due to artifacts. The previously mentioned burst function can be helpful here. It leaves the acoustic characteristics of air unchanged but destroys the contrast bubbles so that the contrast agent is no longer detectable. In principle, carbonated mineral water can be administered but it does not provide the same quality of visualization as contrast agent and may not be sufficiently safe in the case of planned interventions.

Example

▶ **Fig. 3** shows a patient who presented with pain in the upper abdomen after left-sided pancreatic resection. Ultrasound shows a 7.5 × 5.5 × 5 cm hypoechoic fluid-filled lesion. A postoperative fluid collection was suspected. To confirm the suspicion in one examination, oral CEUS was performed. Contrast enhancement of the empty stomach but not the fluid collection was seen. Since the fluid collection was adjacent to the stomach, placement of an Axios Stent™ was planned by the gastroenterology department without further imaging.

Ultrasound contrast agent in the case of punctures, drainage catheters, and other means of access

Fistulas

Indication

Rectal, vesical, intestinal, and vaginal fistulas as well as postoperative and postinflammatory fistulas, for example in the abdominal wall, are common. In principle, any radiological method can be used for examination. MRI is used to diagnose fistulas in the lesser pelvis [20]. The literature also describes the use of CEUS here for diagnosis and treatment planning [21, 22]. However, in general, transrectal ultrasound is not a modality performed in radiology. In addition to MRI, fluoroscopy is an established method for examining fistula systems.

Examination procedure

The type of administration depends on the anatomical region to be examined. If it is possible to scan the fistula system, ultrasound contrast agent can be administered in doses in the concentration described in the “Administration” section. The high spatial resolution of ultrasound particularly in the near range with a linear transducer is advantageous.

Example

▶ **Fig. 4** shows a patient with chronic inflammatory postoperative changes in the abdominal wall and a draining fistula. For further treatment, a possible intraabdominal connection with a potential intestinal fistula needed to be clarified since the patient reported fecal secretion. The patient had a thread-like fistula network with a tiny opening. The intraperitoneal connection but not the intestinal fistula was able to be confirmed by ultrasound contrast agent.

Puncture and drainage of fluid collections

Indication

In the case of good examination conditions and an accessible lesion, the intervention can be performed under B-mode imaging guidance. During the intervention, the tip of the syringe or drainage catheter may not be able to be sufficiently visualized or it may not be possible to aspirate any fluid through the syringe or drainage catheter that is supposedly positioned in the target region. By administering the ultrasound contrast agent via the intervention device, the full length of the device can be visualized and the correct position can be confirmed based on the distribution of the contrast agent within the lesion [32]. If the true size of the punctured fluid collection cannot be clearly seen on B-mode imaging, endocavitary administration of ultrasound contrast agent can be performed and it can be determined based on the size of the fluid collection whether simple aspiration without drainage is

This document was downloaded for personal use only. Unauthorized distribution is strictly prohibited.

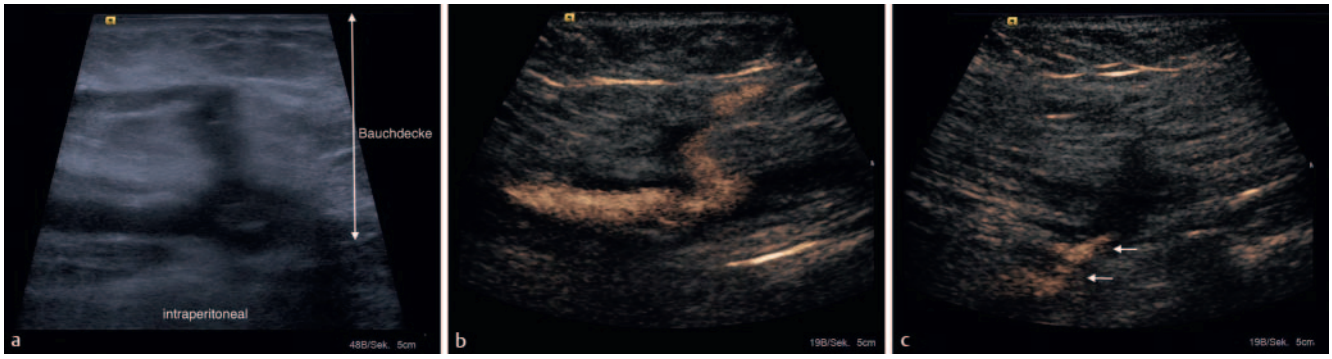

▶ **Fig. 4 a** The fistula system in the abdominal wall is not clearly visible on B-mode ultrasound and can hardly be differentiated from scarring (4a, image of the abdominal wall in the lower abdomen with transverse scan orientation). **b** The fistula system can only be effectively visualized after scanning of the opening of the fistula and administration of diluted ultrasound contrast agent. **c** An intraperitoneal connection is visible (arrows).

sufficient [32]. Based on the distribution of the ultrasound contrast agent within the lesion, it can be determined whether the lesion can be sufficiently drained via the drainage catheter [29]. Septa and non-communicating portions of the fluid collection can be visualized. The potential formation of a fistula to adjacent structures like the bowel, abdominal cavity, abdominal wall, vessels, or organs can be evaluated [8, 29].

A drainage procedure usually also requires follow-up imaging to be able to evaluate treatment success. Fluid collections, which change during treatment, and the position of the drainage catheter are sometimes difficult to visualize on B-mode imaging alone [10]. After endocavitary contrast agent administration, changes in size can be better visualized thereby allowing adjustments to flushing. Based on the distribution of the ultrasound contrast agent, problems with the drainage catheter as can occur in the case of dislodgement, kinking, or blockage can be evaluated.

Examination procedure

The ultrasound contrast agent dose was already described under "Administration" section. Therefore, for example, a 20-ml syringe can be connected to the drainage catheter, the ultrasound contrast agent can be administered in doses, and the wash-in can be evaluated with high spatial and temporal resolution.

Examples

▶ **Fig. 5–8** show the advantages of CEUS in interventions based on four patients.

- ▶ **Fig. 5**: The figure shows a patient with multiple perihepatic fluid collections requiring drainage after a complicated course after cholecystectomy (5a–b, transverse upper abdominal CT after intravenous contrast administration). Three fluid collections (X) with uncertain communication were suspected. The insertion of a drainage catheter (arrow) into a fluid collection lateral to the liver achieved partial drainage. After insertion of another drainage catheter into the fluid collection (X) dorsal to the liver, CEUS was performed. Contrast was seen in the drained fluid collection and the drainage catheter (arrow) but not in the other fluid collections (5c, transverse upper abdominal scan) so that a third drainage catheter was needed in the abscess located further medial.
  Injection of an NaCl-air mixture has become established as a quick treatment monitoring method after placement of a drainage catheter. The syringe is shaken and held so that approximately 5 ml of air initially enter the drainage catheter followed by the saline solution. This approach does not replace endocavitary contrast administration, which can show the finding in much greater detail.
- ▶ **Fig. 6**: Condition after gastrectomy with persistent leukocytosis. CT shows two fluid collections (X) on the left liver lobe (6a, CT with IV and oral contrast administration) into which a drainage catheter was inserted (6b, corresponding US scan). In the further course of treatment, there was suspicion of dislodgement since the drainage catheter could be flushed but aspiration was no longer possible. The applied contrast agent initially accumulated in the fluid collection (X) and the drainage catheter (arrow) but drained through the duodenal stump (*) (6c–d, transverse upper abdomen after contrast administration).
- ▶ **Fig. 7**: CT shows a patient after cesarean section with an abscess (X) ventral to the uterus (7a, sagittal CT after IV and oral contrast administration). A drainage catheter was inserted under ultrasound guidance. After endocavitary contrast administration, monitoring showed enhancement in the uterine cavity (arrow) and fluid collection (X) with an insufficiency (*) in the surgical region (7b, longitudinal section of the lower abdomen after CEUS).
- ▶ **Fig. 8**: Patient with liver abscess drained under ultrasound guidance (8a, intercostal scan with arrow marking the drainage catheter). The follow-up examination shows a fluid collection of decreasing size (X) (8b, intercostal scan) and also explains why flushing is no longer possible since the drainage catheter is no longer located in the abscess due to the decrease in size and is now resting against the liver (8c, intercostal scan after CEUS with contrast agent outside the fluid collection). The arrows show the course of the drainage catheter and X indicates the extraluminal contrast enhancement.

This document was downloaded for personal use only. Unauthorized distribution is strictly prohibited.

▶ **Fig. 5 a–b.** Transverse CT scan of the upper abdomen after intravenous contrast administration. Image of three apparently non-communicating fluid collections (X) and an insufficiently effective drainage catheter (arrow). After placement of a second drainage catheter in the fluid collection shown in a., the communication of the fluid connections is reexamined. **c**. After the administration of US contrast agent into the second drainage catheter, the contrast accumulates only locally so that a third drainage catheter was needed. Fluid collection (X) and drainage catheter (arrow).

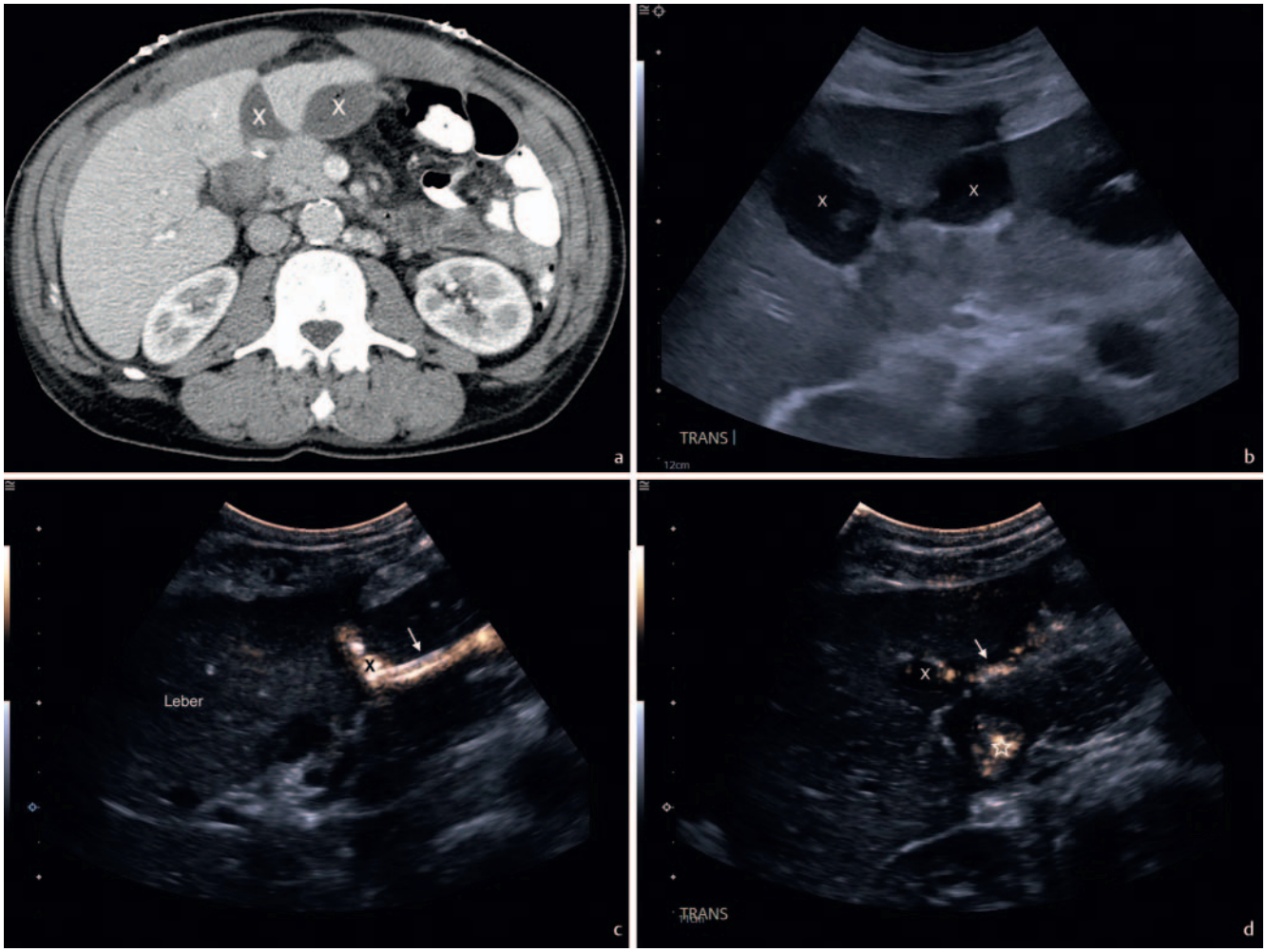

▶ **Fig. 6 a.** CT scan of the upper abdomen after intravenous and oral contrast administration with visualization of two communicating fluid collections (X) that were able to be drained with one drainage catheter. **b**. Corresponding ultrasound scan. **c**. US contrast agent is administered via the drainage catheter (arrow) and accumulates in the abscess of decreasing size (X). **d**. The fluid collection is connected to the duodenal stump (*) via which the US contrast agent drains. Therefore, it can no longer be aspirated.

This document was downloaded for personal use only. Unauthorized distribution is strictly prohibited.

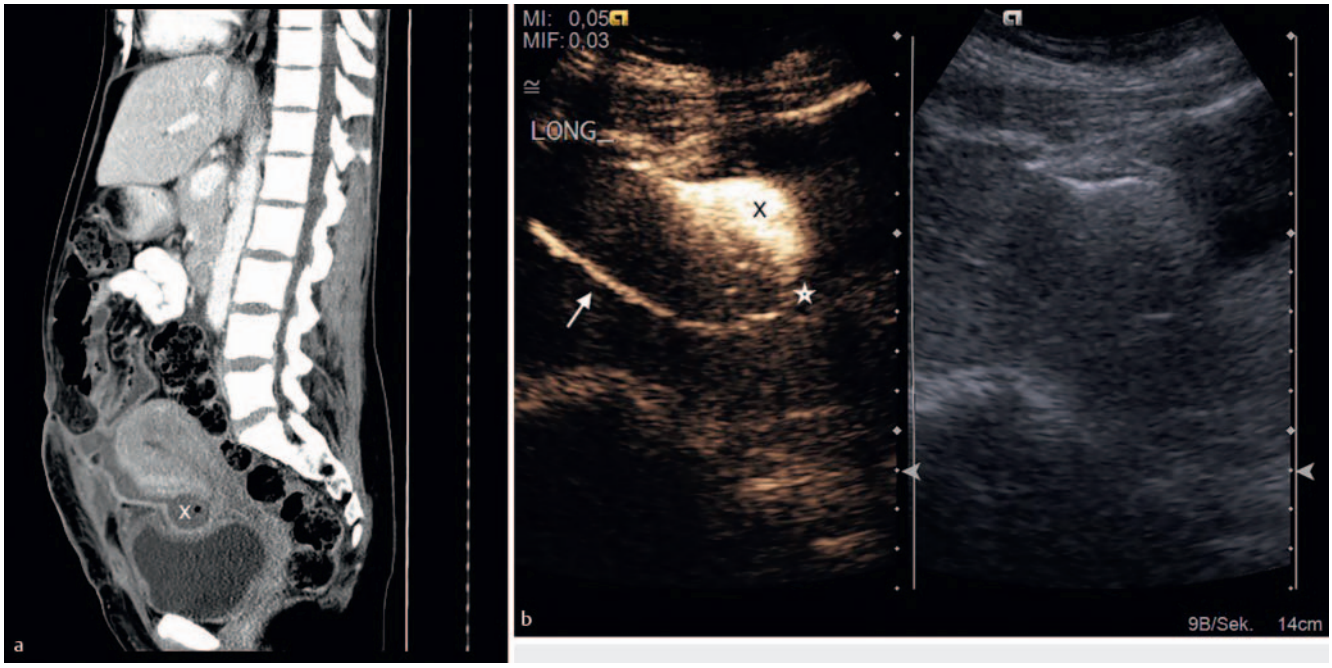

▶ **Fig. 7 a.** Sagittal CT scan after intravenous and oral contrast administration in the case of an abscess (x) after cesarean section. **b**. Longitudinal scan of the lower abdomen after endocavitary contrast administration via the previously placed abscess drainage catheter. US contrast agent is located in the abscess (X) and enters the uterine cavity (arrow) via an insufficiency in the uterus (*).

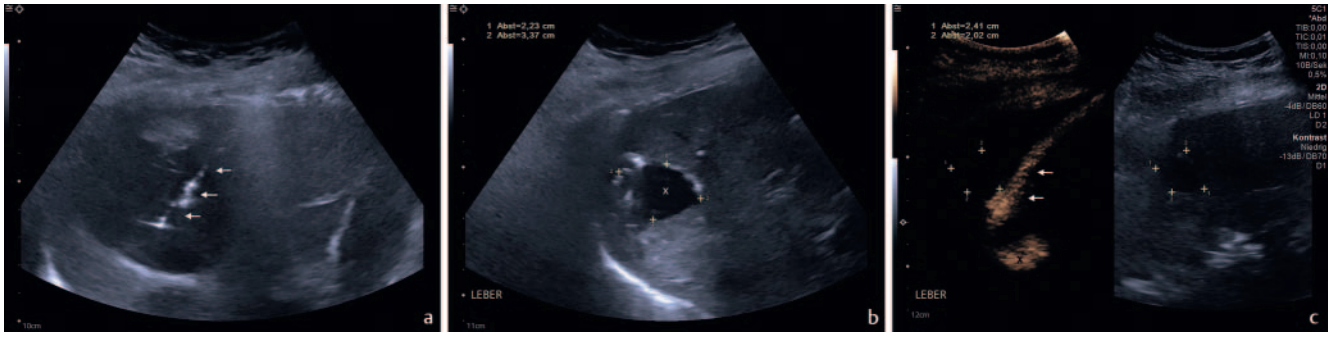

▶ **Fig. 8 a.** After placement of a drainage catheter in a liver abscess. Intercostal scan with arrows marking the drainage catheter. **b**. Follow-up examination. Flushing is no longer sufficient. The size of the abscess has decreased. The position of the drainage tube cannot be clearly determined. **c**. After administration of US contrast agent, enhancement can be seen outside of the abscess (distance marker) in the liver since the drainage tube (arrows) is no longer located in the abscess due to the reduction in the size of the abscess.

PTCD (percutaneous transhepatic biliary drainage)

Indication

The standard method for placing an external biliary drainage catheter combines fluoroscopy and primary sonographic viewing of the dilated bile duct region. Under fluoroscopy guidance, the wire can be easily advanced via enteral access following scanning of the duct system [23]. If the drainage catheter is not functioning properly or if the cholestasis parameters are still elevated, it is necessary to assess whether the catheter has a defect or is dislodged or whether drainage is obstructed internally and/or externally.

Examination procedure

Ultrasound contrast agent can be administered via the drainage catheter as described under “Administration” section. Even just a few milliliters of diluted ultrasound contrast agent can be visualized when passing through the drainage catheter and in the bile duct system so that a suspected complication or dislodgement can be evaluated [8].

Examples

▶ **Fig. 9** shows dysfunction of a drainage catheter with fluid no longer being able to pass at the central end. Daneshi et al. report

This document was downloaded for personal use only. Unauthorized distribution is strictly prohibited.

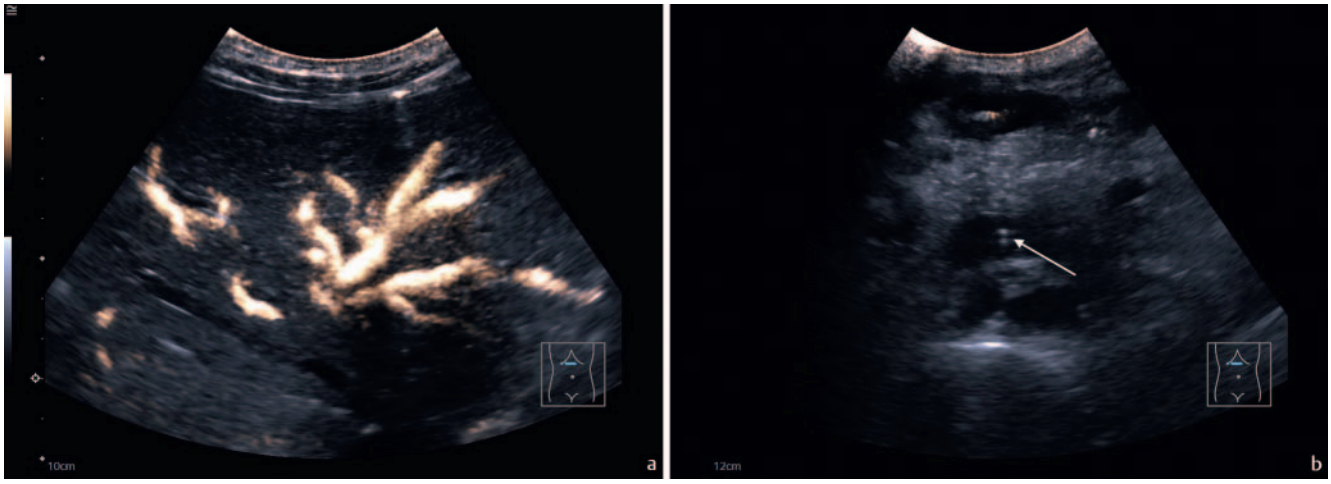

▶ **Fig. 9** shows a patient with metastatic stomach cancer who required percutaneous transhepatic biliary drainage resulting in recurrent leakage of bile next to the insertion site of the drainage catheter. Ultrasound contrast agent is administered via the drainage catheter and collects in the intrahepatic bile ducts (9a). However, no contrast agent is visible in the middle portion of the drainage catheter (arrows) (9b) due to a blockage.

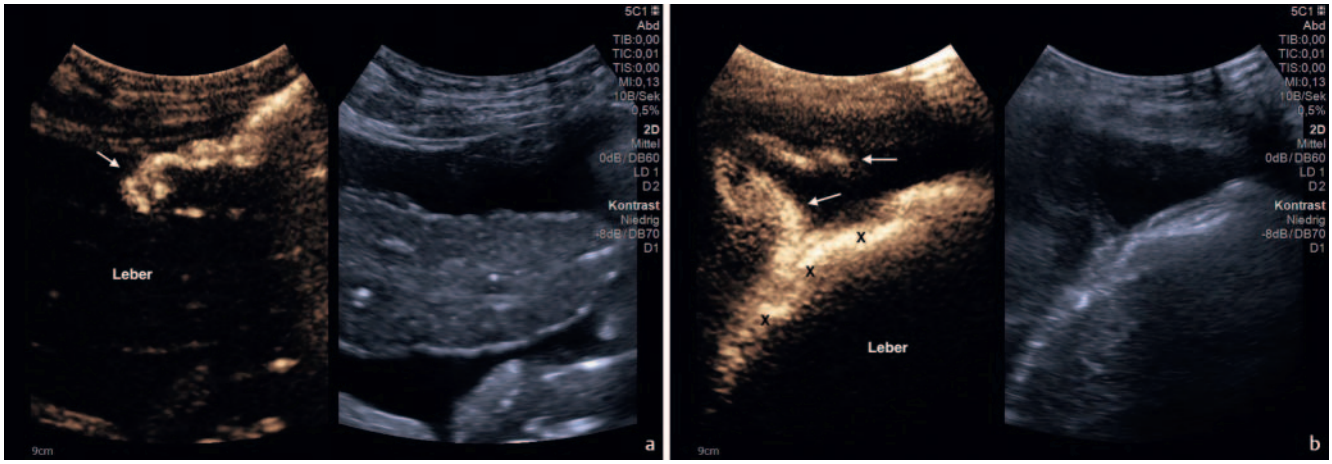

▶ **Fig. 10 a** Injection of contrast agent (arrow) into the perihepatic free fluid (10a, intercostal scan of the right upper abdomen). **b** Contrast enhancement, pleural (arrows) and perihepatic (X) in a high intercostal scan.

on the ability to evaluate bilio-arterial or bilio-venous anastomoses via external administration of ultrasound contrast agent [24].

Peritoneal-pleural communication

Indication

Significant quantities of intraperitoneal fluid can be present, for example in decompensated liver cirrhosis or peritoneal dialysis. In the case of an additional relevant hydrothorax, any diaphragm leakage should be evaluated [31].

Examination procedure

Depending on the site of contrast administration (pleural or peritoneal), it is possible to assess contrast enhancement in the neighboring compartment. As an exception, undiluted contrast agent is here since the abundantly available intraperitoneal fluid or the pleural effusion will ensure the necessary mixture ratio [19].

Example

▶ **Fig. 10** shows a patient who underwent peritoneal dialysis and developed significant unilateral pleural effusion. Following the injection of contrast agent into the peritoneal dialysis solution, rapid passage of the contrast agent in the direction of the pleural effusion can be visualized showing the diaphragm insufficiency.

Percutaneous endoscopic gastrostomy (PEG)

Indication

In the case of suspected complication or dislodgement of the PEG tube, fluoroscopy is an established method for further clarification. After the administration of contrast agent, both the inflow and outflow into the gastrointestinal tract can be evaluated without superimposition. A common examination indication is: “Pain, reddening of the skin, draining wound, and suspicion of dysfunction of a PEG tube”. Ultrasound is often performed as the primary

This document was downloaded for personal use only. Unauthorized distribution is strictly prohibited.

examination since both the abdominal wall and the neighboring gastric wall and intestinal wall can be assessed and other causes of the pain can be ruled out.

Examination procedure

The technique described under "Administration" section is used. The ultrasound contrast agent is administered in doses. The contrast agent in the tube and the distribution of the agent in the stomach are observed.

Example

By administering diluted ultrasound contrast agent via the tube, a functional examination can be performed without the patient having to switch examination rooms after ultrasound. The passage through the tube, the filling of the gastrointestinal tract, and passage through the tract can be visualized. It is easy to detect whether contrast agent is leaking out of the stomach and dispersing intraperitoneally and/or in the abdominal wall.

Nephrostomy

Indication

During the intervention, the position of the syringe or drainage catheter in the renal pelvicalyceal system can be assessed. This can be performed either under X-ray guidance with the administration of iodine-containing contrast agent or under ultrasound guidance with the administration of ultrasound contrast agent. In addition to the position of the syringe or drainage catheter, the ureter with the site of the stenosis can typically also be seen [9].

Examination procedure

The procedure described under "Administration" section is also used here.

Comparison with computed tomography and fluoroscopy

Ultrasound

- Regular repetition of the examination without radiation
- Practically no side effects or contraindications
- Dynamic examination without the need to determine in advance the amount of contrast agent to be administered, such as in endocavitary administration in CT.
- Ultrasound is often the primary examination. Since the administration of contrast agent is required, it is not necessary to perform additional examinations in another room in the case of endocavitary CEUS.
- CEUS is subject to the same limitations as ultrasound in general, particularly in the case of low-lying structures with overlying air and in obese patients. Thus, CEUS conditions are typically also poor if B-mode conditions are poor. Intravenous or endocavitary contrast agent administration may help since the contrast behavior of the finding to be clarified ideally differs greatly from that of neighboring structures [25].
- Spatial and temporal resolution similar to that of fluoroscopy [26].

Fluoroscopy and CT

- Better overview, examination without superimposition despite air and bone. Even in obese patients or very low-lying structures.
- Established, widely available, and safe methods with simple demonstration in the interdisciplinary context.

Comment

Endocavitary contrast-enhanced ultrasound can be used in every physiological and pathological body cavity and body orifice and can be administered via all types of access system. This article discusses the most common application areas as typically performed in the daily routine in radiology. Interested readers can refer to the relevant literature, such as the evaluation of tubal patency in women trying to conceive [27] or endosonographic application [2].

Summary

"CEUS ist kein Hexenwerk" [33]. Radiologists are familiar with the use of contrast agents. Without them, many examinations would not be possible. Radiology has numerous modalities for diagnosis, treatment, and follow-up. Only ultrasound is sometimes met with skepticism. CEUS is unfortunately less established in radiology [34]. The use of contrast agent has become indispensable in ultrasound. The purpose of this article is to elucidate endocavitary use of contrast-enhanced ultrasound. The main area of application is certainly interventions involving puncture and drainage. A purely sonographic approach is possible for diagnosis, treatment, and follow-up. Moreover, there are countless possible applications for ultrasound contrast agents to the primary benefit of patients who can only undergo other radiological examinations with extreme caution due to age, preexisting conditions, and other limitations. Endocavitary CEUS is a method with advantages as well as disadvantages compared to conventional examination modalities. The goal of this article is to arouse the interest of readers and to encourage the intelligent use of ultrasound for the good of patients.

Conflict of Interest

Vollert: Kein Interessenkonflikt
Kleffel: Vortragshonorar von Siemens Healthineers
Clevert: Vortragshonorar von Bracco, Siemens Healtineers, Philips, Esaote, Samsung

References

[1] Dietrich CF, Nolsøe CP, Richard G et al. Guidelines and Good Clinical Practice Recommendations for Contrast Enhanced Ultrasound (CEUS) in the Liver – Update 2020. Ultraschall in Med 2020; 41: 562–585. doi:10.1055/a-1177-0530

[2] Sidhu PS, Cantisani V, Dietrich CF et al. The EFSUMB Guidelines and Recommendations for the Clinical Practice of Contrast-Enhanced Ultrasound (CEUS) in Non-Hepatic Applications: Update 2017 (Long Version). Ultraschall in Med 2018; 39: e2–e44. doi:10.1055/a-0586-1107

This document was downloaded for personal use only. Unauthorized distribution is strictly prohibited.

[3] Quaia E. Microbubble ultrasound contrast agents: an update. Eur Radiol 2007; 17 (8): 1995–2008. doi:10.1007/s00330-007-0623-0

[4] Cosgrove D. Ultrasound contrast agents: an overview. Eur J Radiol 2006; 60 (3): 324–330

[5] Farina R et al. Vesico-ureteral reflux: diagnosis and staging with voiding color Doppler US: preliminary experience. Eur J Radiol 2000; 35: 49–53

[6] Fachinformation Sonovue, Bracco, Mailand, Italien.

[7] Piscaglia F, Bolondi F et al. The safety of Sonovue in abdominal applications: retrospective analysis of 23188 investigations. Ultrasound Med Biol 2006; 32: 1369–1375

[8] Ignee A, Schuessler G, Cui XW et al. Der endocavitäre Kontrastmittelultraschall-verschiedene Anwendungen, eine Übersicht über die Literatur und zukünftige Perspektiven. Ultraschall in Med 2013; 34: 504–528. doi:10.1055/s-0033-1335546

[9] Huang DY, Yusuf GT, Daneshi M et al. Contrast-enhanced US–guided Interventions: Improving Success Rate and Avoiding Complications Using US Contrast Agents. RadioGraphics 2017; 37: 652–664. doi:10.1148/rg.2017160123

[10] Huang DY, Yusuf GT, Daneshi M et al. Contrast-enhanced ultrasound (CEUS) in abdominal intervention. Abdom Radiol 2018; 43: 960–976. doi:10.1007/s00261-018-1473-8

[11] Darge K. Voiding urosonography with ultrasound contrast agents for the diagnosis of vesicoureteric reflux in children. I. Procedure. Pediatr Radiol 2008; 38: 40–45

[12] Papadopoulou F, Ntoulia A, Siomou E et al. Contrast-enhanced voiding urosonography with intravesical administration of a second-generation ultrasound contrast agent for diagnosis of vesicoureteral reflux: prospective evaluation of contrast safety in 1,010 children. Pediatr Radiol 2014; 44: 719–728

[13] Riccabona M, Vivier PH, Ntoulia A et al. ESPR Uroradiology Task Force. ESPR uroradiology task force imaging recommendations in paediatric uroradiology part VII. Standardized terminology, impact of existing recommendations, and update on contrast-enhanced ultrasound of the paediatric urogenital tract. Pedidatr Radiol 2014; 44: 1478–1484

[14] Capaccio P, Minetti AM, Manzo R et al. Int J Maxillo Odontostomatol 2003; 2: 9–12

[15] Zengel P, Schrötzlmair F, Kramer M et al. Management of salivary gland diseases with contrast-enhanced ultrasound. Radiologe 2011; 51 (6): 490–496

[16] Zengel P, Berghaus A, Paprottka P et al. Sonographic analyses of obstructive diseases of the salivary gland using intraductal applications of contrast agent, Laryngorhinootologie; 2011; 90 (4): 196–199

[17] Zengel P, Berghaus A, Weiler C et al. Intraductally applied contrast-enhanced ultrasound (IA-CEUS) for evaluating obstructive disease and secretory dysfunction of the salivary glands. Eur Radiol 2011; 21 (6): 1339–1348

[18] Zengel P, Schrötzlmair F, Reichel C et al. Sonography: the leading diagnostic tool for diseases of the salivary glands. Semin Ultrasound CT MR 2013; 34 (3): 196–203

[19] Sparchez Z, Radu P, Sparchez M et al. Intracavitary Applications of Ultrasound Contrast Agents in Hepatogastroenterology. J Gastrointestin Liver Dis 2013; 22 (3): 349–353

[20] Schäfer AO, Baumann T, Langer M. MRT in der Diagnostik anorektaler Fisteln. RöFo 2006; 178 (11): 1095–1104. doi:10.1055/s-2006-926976

[21] Chen YJ, Mao R, Xie XH et al. Intracavitary Contrast-enhanced Ultrasonography to Detect Enterovesical Fistula in Crohns Disease. Gastroenterology 2016; 150: 315–317

[22] Heinzmann A, Muller T, Leitlein J et al. Endocavity contrast enhanced ultrasound (CEUS) – work in progress. Ultraschall in Med 2012; 33: 76–84

[23] Mahnken A, Thomas C, Wilhelm K Hrsg. Interventionelle Radiologie. 1. Aufl. Stuttgart: Thieme; 2019. doi:10.1055/b-005-143315

[24] Daneshi M, Rajayogeswaran B, Peddu P et al. Demonstration of an occult biliary-arterial fistula using percutaneous contrast-enhanced ultrasound cholangiography in a transplanted liver. J Clin Ultrasound 2014; 42 (2): 108–111

[25] Huang DY, Yusuf GT, Daneshi M et al. Contrast-enhanced ultrasound (CEUS) in abdominal intervention. Abdom Radiol 2018; 43: 960–976. doi:10.1007/s00261-018-1473-8

[26] Yusuf GT, Fang C, Huang DY et al. Endocavitary contrast enhanced ultrasound (CEUS): a novel problem solving technique. Insights into Imaging 2018; 9: 303–311. doi:10.1007/s13244-018-0601-x

[27] Zhou L, Zhang X, Chen X et al. Value of three-dimensional hysterosalpingo-contrast sonography with SonoVue in the assessment of tubal patency. Ultrasound Obstet Gynecol 2012; 40 (1): 93–98

[28] Kloth C, Kratzer W, Schmidberger J et al. Ultraschall 2020 – Diagnostik & Therapie: Auf dem Weg zur multimodalen Sonografie: kontrastverstärkter Ultraschall (CEUS), mikrovaskuläre Dopplerverfahren, Fusionsbildgebung, Sono-Elastografie, interventionelle Sonografie. RöFo 2021; 193 (1): 23–32. doi:10.1055/a-1217-7400

[29] Jung EM, Jung F, Stroszcynski C. Dynamic endoluminal contrast enhanced ultrasound (CEUS) for display of drainages in inflammatory abdominal fluid collections. Clin Hemorheol Microcirc 2022. doi:10.3233/CH-211370

[30] Young A, Yusuf G, Fang C. Cholecystoduodenal fistula identified on oral contrast-enhanced ultrasound. J Ultrasound 2020. doi:10.1007/s40477-020-00535-x

[31] Foschi F, Piscaglia F, Pompili M. Real-time contrast-enhanced ultrasound–a new simple tool for detection of peritoneal-pleural communications in hepatic hydrothorax. Ultraschall in Med 2008 Oct 29 (5): 538–542. doi:10.1055/s-2008-1027328

[32] Francica G. Intracavitary contrast-enhanced ultrasound in ultrasound-guided percutaneous management of abdominal fluid collections/abscessesby a single clinician: an example of point-of-care ultrasound. Journal of Ultrasound 2020; 23: 175–181. doi:10.1007/s40477-020-00467-6

[33] Fischer T. „CEUS ist kein Hexenwerk“. RöFo 2018; 190 (5): 462–464. doi:10.1055/a-0588-2375

[34] Graeter T, Kratzer W, Seufferlein T. Erhebung der Wertigkeit der kontrastverstärkten Sonografie (CEUS) in radiologischen Fachabteilungen in Deutschland. Fortschr Röntgenstr 2017; 189: 748–759. doi:10.1055/s-0043-111011

This document was downloaded for personal use only. Unauthorized distribution is strictly prohibited.