

Evidence-Based and Structured Diagnosis in Breast MRI using the Kaiser Score

Evidenzbasierte und strukturierte Diagnostik in der MR-Mammografie anhand des Kaiser-Score

Authors

Pascal Andreas Thomas Baltzer¹, Kathrin Barbara Krug², Matthias Dietzel³

Affiliations

- 1 Department of Biomedical Imaging and Image-Guided Therapy, Division of Molecular and Gender Imaging, Medical University of Vienna, Medical University of Vienna, Wien, Austria
- 2 Department of Diagnostic and Interventional Radiology, University Hospital Cologne, Köln, Germany
- 3 Department of Radiology, University Hospital Erlangen, Germany

Key words

breast, decision analysis, biopsy, MR imaging

received 28.10.2021

accepted 05.03.2022

published online 25.05.2022

Bibliography

Fortschr Röntgenstr 2022; 194: 1216–1228

DOI 10.1055/a-1829-5985

ISSN 1438-9029

© 2022, Thieme. All rights reserved.

Georg Thieme Verlag KG, Rüdigerstraße 14, 70469 Stuttgart, Germany

Correspondence

Herr Prof. Pascal Andreas Thomas Baltzer
Department of Biomedical Imaging and Image-Guided Therapy, Division of Molecular and Gender Imaging, Medical University of Vienna, Waehringer-Guertel 18–20, 1090 Vienna, Austria
Tel.: +43/03 64 19 32 48 01
Fax: +43/1/40 40 04 81 80
pascal.baltzer@meduniwien.ac.at

ABSTRACT

Background Breast MRI is the most sensitive method for the detection of breast cancer and is an integral part of modern breast imaging. On the other hand, interpretation of breast MRI exams is considered challenging due to the complexity of the available information. Clinical decision rules that combine diagnostic criteria in an algorithm can help the radiologist to read breast MRI by supporting objective and largely experience-independent diagnosis.

Method Narrative review. In this article, the Kaiser Score (KS) as a clinical decision rule for breast MRI is introduced, its diagnostic criteria are defined, and strategies for clinical decision making using the KS are explained and discussed.

Results The KS is based on machine learning and has been independently validated by international research. It is largely independent of the examination technique that is used. It allows objective differentiation between benign and malignant contrast-enhancing breast MRI findings using diagnostic BI-RADS criteria taken from T2w and dynamic contrast-enhanced T1w images. A flowchart guides the reader in up to three steps to determine a score corresponding to the probability of malignancy that can be used to assign a BI-RADS category. Individual decision making takes the clinical context into account and is illustrated by typical scenarios.

Key Points:

- The KS as an evidence-based decision rule to objectively distinguish benign from malignant breast lesions is based on information contained in T2w und dynamic contrast-enhanced T1w sequences and is largely independent of specific examination protocols.
- The KS diagnostic criteria are in line with the MRI BI-RADS lexicon. We focused on defining a default category to be applied in the case of equivocal imaging criteria.
- The KS reflects increasing probabilities of malignancy and, together with the clinical context, assists individual decision making.

Citation Format

- Baltzer PA, Krug KB, Dietzel M. Evidence-Based and Structured Diagnosis in Breast MRI using the Kaiser Score. Fortschr Röntgenstr 2022; 194: 1216–1228

ZUSAMMENFASSUNG

Hintergrund Die MR-Mammografie (MRM) ist als sensitivstes Verfahren zur Detektion von Brustkrebs integraler Bestandteil der modernen Mammadiagnostik. Aufgrund umfangreicher multiparametrischer Bildinformationen gilt die Befundung der MRM jedoch als schwierig. Klinische Entscheidungsregeln kombinieren diagnostische Kriterien in einem Algorithmus. Damit unterstützen sie Radiologen dabei, objektive und exakte sowie weitgehend von der Untersuchererfahrung unabhängige MRM-Diagnosen zu stellen.

Methodik Narrativer review. Der Kaiser-Score (KS) als klinische Entscheidungsregel für die MRM wird eingeführt. Befundkriterien werden erläutert, Strategien zur klinischen Entscheidungsfindung diskutiert und illustriert.

Ergebnisse Entwickelt mit Methoden des maschinellen Lernens wurde der Kaiser-Score in internationalen Studien unabhängig validiert. Dabei ist der KS unabhängig von der Untersuchungstechnik. Anhand von auf T2w- und kontrast- angehobenen T1w-Aufnahmen fassbaren diagnostischen

BI-RADS-Kriterien ermöglicht der KS die objektive und genaue Differenzialdiagnose von benignen und malignen Befunden in der MRM. Ein Flowchart leitet den Leser über maximal 3 Zwischenschritte zu einem Punktwert, entsprechend einer Malignomwahrscheinlichkeit. Damit lässt sich der KS direkt einer konkreten BI-RADS-Kategorie zuordnen. Individuelle Managemententscheidungen sollten dabei auch den klinischen Kontext berücksichtigen, was anhand von typischen Beispielen dargestellt wird.

Introduction

Since its introduction in the 1980s, MR mammography or breast MRI has become established as the most sensitive method for detecting breast cancer [1–4]. Even though the method was long overshadowed by X-ray mammography as an easy, cost-efficient, and effective early detection method, it has become an indispensable part of most areas of breast diagnostics. Recent studies have confirmed the method's long suspected added value in the early detection of breast cancer in women with dense breast tissue [5–8]. X-ray mammography is not sufficiently sensitive in these women and the additional benefit of tomosynthesis, ultrasound, and other methods is limited. In a prospective randomized study, the use of breast MRI was able to lower the interval cancer rate in women with very dense breast tissue to that of women with less dense breast tissue. These results are extremely promising, and initial analyses have shown the method to be cost-effective even though a long-term effect has, of course, not been able to be shown yet [5–7].

In spite of significant international differences in the use of breast MRI, a survey conducted by the EUSOBI (European Society of Breast Imaging) showed high acceptance of the method and use beyond the recommendations and guidelines, which can no longer be considered current [9]. The classic indications for breast MRI include the staging of breast cancer, particularly in the case of premenopausal women, high breast density, invasive lobular phenotype, and suspicion of multicentricity [4, 10]. Traditionally, the indication of MRI as a problem-solving tool was not very specific. Current evidence demonstrates that in case of positive or unclear findings on conventional breast imaging, performing MRI can avoid unnecessary follow-up and biopsies thanks to its high negative predictive value [11–14]. The method thus increases the specificity and positive predictive value in contrast to earlier assumptions [11, 12]. There is currently a high level of evidence for the use of MRI as an additional screening method in women with an intermediate risk and the use of MRI to prevent unnecessary biopsies [11, 12, 15, 16]. This does not affect established indications such as the workup of implants or clinical symptoms like pathological secretion without a conventional imaging correlate or the follow-up of neoadjuvant therapies. It should be noted that the empirical evidence for some of these indications is rather limited [3, 4]. Consequently, a continuously increasing rate of breast MRI examinations has been observed and often present a logistic and diagnostic challenge for clinics and departments. In

addition to a standardized examination technique that should include protocols that are as short as possible but also multiparametric for quality as well as capacity reasons, reporting of the examination must be highly structured. Structured reporting has been a topic of interest for years and it has become an established part of most radiology subspecialties. Its importance in breast MRI cannot be overstated. The BI-RADS lexicon for X-ray mammography, breast ultrasound, and breast MRI findings was introduced in radiology as the first structured reporting standard [17]. Numerous systems derived therefrom for other organs are in use today. The BI-RADS lexicon continues to provide a tool for structured reporting that is used internationally. In principle, it covers all aspects from the examination technique to the management recommendation but does not include a clinical decision rule as has been standard, for example, in prostate diagnosis and the PI-RADS system for years [18–20]. Without a clear clinical decision rule, diagnosis is subjective, dependent on experience, and often difficult [21–23]. Breast MRI is therefore challenging to interpret. The Kaiser score solves this problem. Using established BI-RADS criteria (Werner Alois Kaiser, after whom the score is named, was not only an MRI pioneer but also played a major role in the creation of the original MRI BI-RADS lexicon), a simple flowchart guides the interpreting physician in two to three steps toward a risk category that can then be translated into an objective diagnosis and management recommendation under consideration of symptoms [24]. The present article discusses the Kaiser score system and its application in clinical practice.

Examination protocol

A strength of magnetic resonance imaging is its high soft-tissue contrast, which can be varied by changing the sequence parameters or sequence types. The combination of information from various contrasts/sequences is often referred to as multiparametric [25]. At least T2-weighted and T1-weighted sequences before and after contrast administration are interpreted in combination for breast MRI [26]. Functional pathophysiological information regarding contrast dynamics is supplemented by morphological criteria and has high diagnostic significance in the synopsis. As described in detail elsewhere, we recommend performing the examination in a prone position using a dedicated multichannel surface coil (currently standard practice) and an examination protocol in axial slice orientation on a 1.5 or 3 Tesla scanner [26, 27].

Contrast dynamics

The most important part of every breast MRI examination is the contrast dynamics. While maintaining identical parameters, repetitive T1-weighted sequences are measured before and after intravenous administration of MRI contrast agents. The first four minutes after contrast administration are sufficient to determine the curve type [26]. Fat saturation is considered optional. We recommend only using this technique if fat saturation can be consistently achieved with high quality on the available MRI scanner. In our clinical practice, the Dixon method is used for this purpose. This method is robust with respect to B0 inhomogeneities so that it also offers advantages regarding motion artifacts. However, when using older scanners, the potential failure of reconstruction or a fat-water mix-up due to phase shifts must be taken into consideration [26, 28].

The dynamics make it possible to reliably detect malignant findings. Hypervascularization caused by hypoxia-induced angiogenesis is considered the pathophysiological basis for this feature [29]. This process is essential for the development of breast cancer and starts in the earliest tumor stage. Therefore, breast MRI is also capable of detecting ductal carcinoma in situ (DCIS) with high sensitivity [30, 31]. In comparison, non-enhancing cancers are rare. They are only seen in individual case reports [32]. The radiological-pathological correlation in these cases typically indicates low-grade tumors with a low proliferation rate. Therefore, the literature classifies such findings as biologically insignificant [11, 13, 30, 33, 34]. Technical errors are usually the reason for false-negative breast MRI findings. Typical causes like extravasation and incorrect contrast injection can be easily avoided with careful quality management [26].

Benign breast lesions also regularly show pathological enhancement. Dynamics alone are not capable of reliably differentiating benign from malignant findings [35]. Morphological criteria are therefore essential to ensure the high specificity of breast MRI [24, 26]. These include, for example, the margin and the presence of edema.

T2-weighted sequences

T2-weighted sequences without fat saturation are highly suited for evaluating morphological criteria. If the time window allows, a short tau inversion recovery sequence (STIR) can be additionally measured. Both methods are fluid-sensitive and show tissue containing water with high signal intensity [36]. In addition to the differentiation between benign and malignant lesions, T2-weighted sequences allow subtyping of the tissue, e. g., evaluation of tissue fibrosis. At the same time, architectural distortions, post-therapeutic residues, cystic structures, duct ectasia, and edema are effectively visualized [26].

Compared to STIR, the T2-weighted sequence without fat saturation has a higher spatial resolution and a better signal-to-noise ratio. The T2 contrast should be high by selecting a long echo time of approximately 170–200 ms. This sequence is unparalleled in the visualization of architectural distortions, Cooper's ligaments, mild duct ectasia, cysts, and intracystic masses [26, 36]. The STIR sequence also has advantages. Thanks to contrast defined by T1 and T2 weighting, it is particularly sensitive for fluid

and is preferred by some colleagues for lymph node analysis. As a result of the short inversion time, signal loss is often seen in structures with a short T1 time such as oil cysts and duct ectasia with a high foam cell content. Duct ectasia is typically associated with periductal mastitis or non-puerperal mastitis.

Diffusion-weighted imaging (DWI)

The EUSOBI recommends the basic protocol for breast MRI in addition to a diffusion-weighted sequence (DWI), which is already widely available internationally [9, 37]. DWI visualizes the Brownian motion of water molecules in the extracellular space and thus provides insight into the microstructure of the tissue [37, 38]. Clinical DWI protocols should include only two b-values (0 or 50 and 800 s/mm²). Parametric apparent diffusion coefficient (ADC) maps are automatically created from diffusion coefficients calculated on a voxel basis. In clinical practice a quantitative ADC can thus be assigned to every pixel. Conclusions about the microstructure of the examined tissue can be made on this basis like in the case of laboratory values. These features of DWI explain the continued popularity of this technique [37, 39].

Contrast-enhancing lesions on breast MRI

The basis of every breast MRI diagnosis is the identification of contrast-enhancing "findings". These findings can also be referred to as lesions.

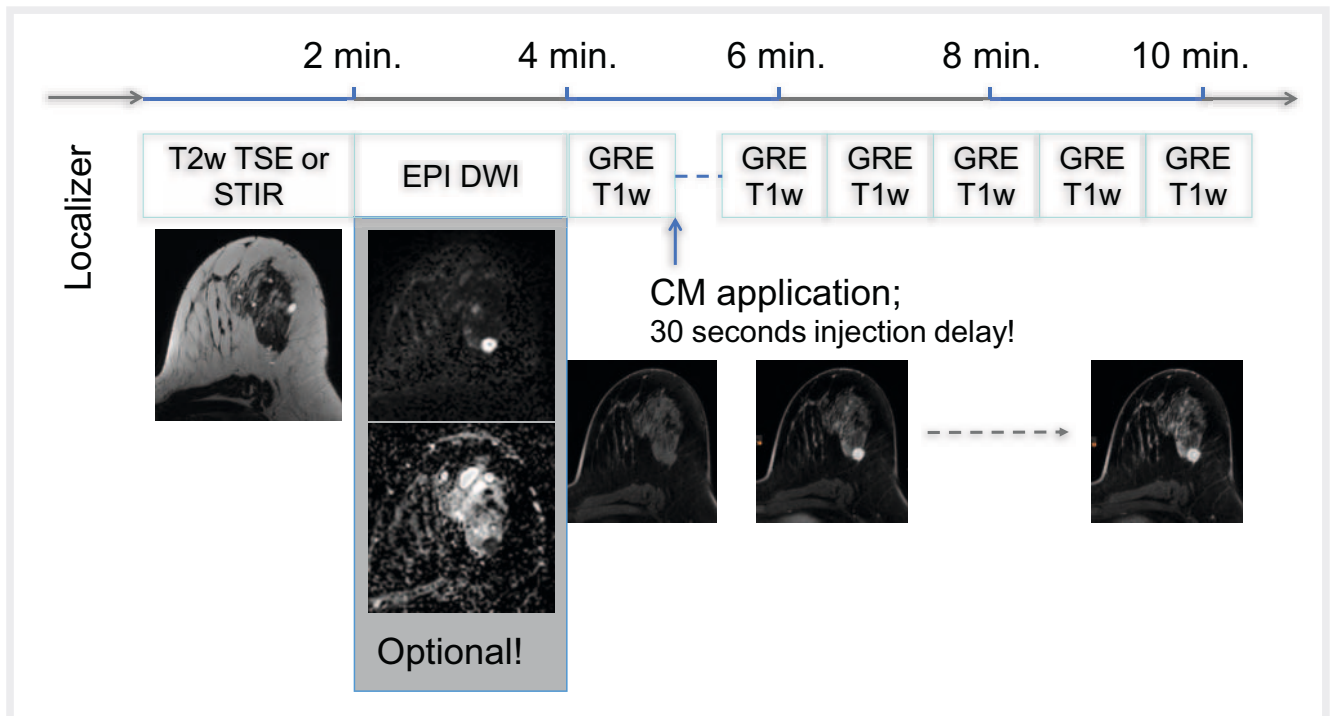
MRI BI-RADS designates any mass or non-mass enhancement in contrast dynamics that cannot be assigned to background parenchymal enhancement as a lesion. The latter has no disease value according to current knowledge.

If there is no contrast-enhancing lesion on breast MRI, the presence of a biologically relevant cancer can be virtually ruled out. If a lesion is found, it must be further categorized as mass or non-mass. Mass lesions are characterized by topographically continuous and space-occupying properties. If the lesion is not space-occupying and its growth is discontinuous, the lesion is a non-mass lesion.

In clinical practice, the definitive categorization of lesions as mass or non-mass is not always possible. In addition, the specific diagnostic non-mass criteria of MRI BI-RADS is insufficient for classifying lesions as benign or malignant. Therefore, the KS does not include specific non-mass criteria.

Principle and application of the Kaiser score

The data on which the Kaiser score is based can be attributed to the MRI pioneer Werner Alois Kaiser. He introduced contrast dynamics and the dedicated breast surface coil and played a key role in the creation of the MRI BI-RADS lexicon with differentiation of mass and non-mass lesions. In regular scientific audits, all MRI examinations at his institute were evaluated based on standardized criteria that he had refined over many years and were added to a continually growing database. Two of the authors of this article participated in this work for years as his students (PATB, MD). The Kaiser score that was derived from this database rightfully



► **Fig. 1** Basic breast MRI examination protocol. The basic protocol is a full multiparametric breast MRI exam. It starts with a T2-weighted sequence. Alternatively or in addition, a Short-Tau-Inversion-Recovery sequence can be acquired (STIR). Dynamic contrast-enhanced scanning starts with a pre-contrast T1-weighted measurement, followed by IV contrast injection and an injection delay of 30 seconds. Subsequently, 4 identical T1-weighted measurements are acquired. DWI is a recommended optional addition. TSE: Turbo-Spin Echo/Fast Spin Echo; EPI: Echo Planar Imaging, DWI: Diffusion Weighted Imaging, GRE: Gradient echo, CM: contrast medium, here gadolinium-based macrocyclic contrast media.

bears his name [26]. The protocol, the Kaiser score and examples are shown in ► **Fig. 1–4**.

The classification algorithm, which belongs to the family of classification trees, tests all diagnostic criteria in the database and statistically identifies the one with the greatest discriminatory power [24]. The thus homogenized database (probably benign and probably malignant findings) is further homogenized by iterative hierarchical application of the remaining diagnostic criteria. This segmentation of the database ends when no further improvement can be statistically achieved. The Kaiser score corresponds to a classification tree with three levels and five diagnostic criteria (see ► **Fig. 5**). On the basis of the lesion assessment based on the diagnostic criteria, the user arrives at a final category ranked according to increasing probability of malignancy [26]. The robustness of the original Kaiser score was ensured by the cross-validation method. The following international validation studies were able to independently demonstrate the value of the Kaiser score in various clinical scenarios and to define limit values [18, 39–44]. Interestingly, the diagnostic categories of the Kaiser score are not only probabilities of malignancy but also represent specific imaging phenotypes of breast lesions. Therefore, every category of the Kaiser score can be assigned to specific differential diagnoses (see ► **Table 1** and ► **Fig. 2, 3, 6, 7**).

Practical application is based on the classification tree in ► **Fig. 2**. Alternatively, an interactive Web application is also available [45].

What differentiates the Kaiser score from other algorithms?

The Kaiser score is the only evidence-based, generally applicable, and thoroughly independently validated decision rule for breast MRI. Other classification algorithms are not based on representative samples, cannot be applied to all findings with strong contrast, or have an insufficient level of accuracy. No other algorithm has been validated on a sufficiently independent basis. A detailed description of other studies exceeds the scope of this article. Therefore, we only reference the primary literature [45–50]. We would like to discuss an important aspect of clinical decision rules, particularly in breast diagnosis. The accuracy of diagnostic tests is based on the number of correctly classified cases that can be assessed by various methods. Even if such values (e. g., 90 % accuracy) allow a satisfactory first assessment of the quality of a test, the practical value is low. “Will I make the correct decision for patient × if I rely on the algorithm” is a more accurate description of the concrete clinical problem. For this purpose, an algorithm must have limit values at which the presence of a disease is highly likely or unlikely. In breast cancer diagnosis, reliable tumor exclusion is of primary relevance as a result of treatment being based on immunohistochemical tumor classification. Such a “rule-out” criterion that rules out a malignant tumor with high reliability has been validated multiple times in various settings for the Kaiser score: a biopsy can be avoided at a Kaiser score < 5 [18, 26, 41, 42]. The Kaiser score can be seamlessly integrated into the clinical

► **Table 1** Typical differential diagnoses of KS categories.

| KS | Benign | Malignant | Comment |
|----|---|---|--|
| 1 | Fibroadenoma, Fine granular enhancement of acinar breast tissue structures | Extremely unlikely | Definitely benign |
| 2 | Fibroadenoma Papilloma (intraductal) | Extremely unlikely | Clinical management depends on symptoms and location (e. g., papilloma) |
| 3 | Regional hormonal or inflammatory enhancement | DCIS (possible) | Typical benign finding, usually non-mass; can correspond to DCIS in association with suspicious microcalcification; type 2 curve usually missed upon visual inspection; DCIS typically shows KS 5 |
| 4 | Adenosis Fibroadenoma (atypical) | Invasive cancer (unlikely, only very small lesions) | This category corresponds to the typical presentation of adenosis, typically multiple and bilateral. Caution: in the case of a very small size and insufficient image quality, a KS of 8 can be misinterpreted as a KS of 4. Always perform a second critical evaluation when assigning a KS of 4 in patients with BRCA-1 mutation (observe default category). |
| 5 | Benign proliferative changes Risk lesions: Complex sclerosing lesions, atypical ductal hyperplasia | DCIS (typical) | Typical phenotype of DCIS; overlap with benign proliferative changes |
| 6 | Inflamed scar tissue (atypical) | Breast cancer recurrence in scar tissue, invasive carcinoma under neoadjuvant therapy | Rarest KS phenotype |
| 7 | Unlikely | Invasive cancer | Classic breast cancer, typically hormone receptor-positive |
| 8 | Less typical: <ul style="list-style-type: none"> ▪ Adenosis ▪ Papilloma ▪ Fibroadenoma | Aggressive breast cancer, e. g., triple-negative cancer (typical), metastasis, lymphoma | Classic phenotype of highly aggressive breast cancer Caution: Potenzial misinterpretation as KS 4 in the case of small size and/or suboptimal image quality |
| 9 | Highly unlikely | Invasive cancer | Classic breast cancer, typically hormone receptor-positive |
| 10 | Highly unlikely | Invasive cancer | Classic breast cancer, typically her2/neu-positive; elevated risk of lymph node metastases |
| 11 | Highly unlikely | Invasive cancer | |

context and can be easily combined with clinical results and algorithms using Bayesian principles. However, a recent multicenter study was not able to prove added value of the integration of quantitative ADC values in the Kaiser score [39].

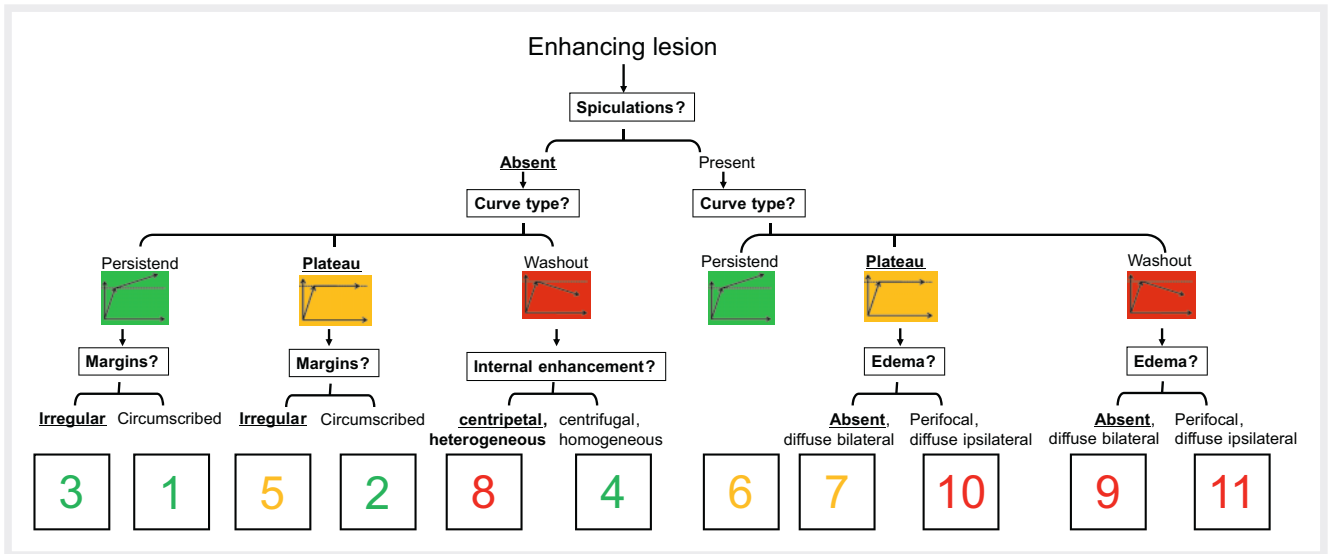
Level of evidence

The Kaiser score is the only evidence-based, generally applicable, and independently validated decision rule for breast MRI.

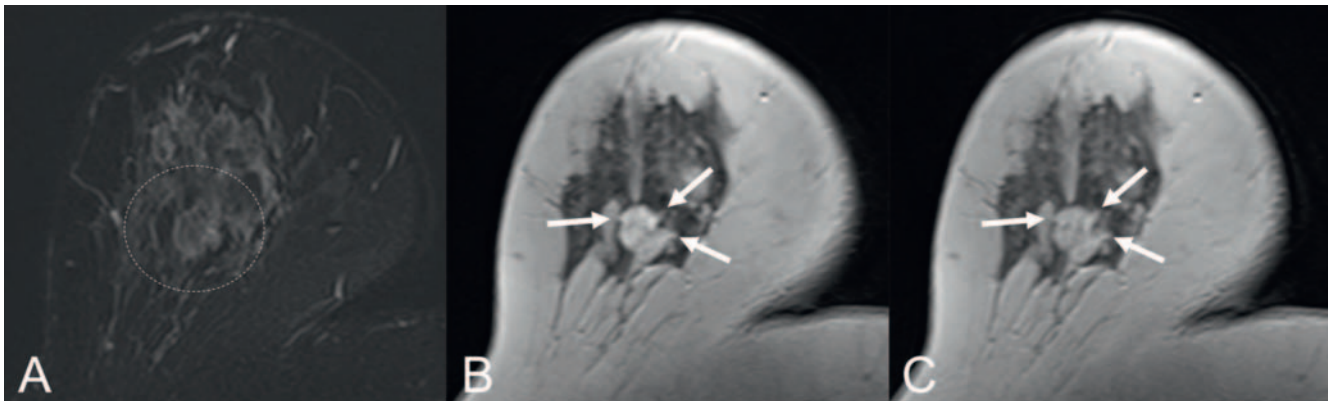
Nonetheless, the literature includes alternative classification algorithms. However, these cannot be used for broad clinical application: Typical limitations are samples that are not representative, a lack of generalizability (e. g., only applicable for masses), and insufficient accuracy. Most notably, none of these algorithms has been independently validated which is a basic requirement for evidence-based clinical use. A detailed overview of alternative classification algorithms is not the goal of this article. Therefore, we only reference the primary literature [46–51].

Diagnostic criteria of the Kaiser score

The diagnostic criteria on which the Kaiser score is based correspond to those of the BI-RADS lexicon [19, 24, 26]. A recent comprehensive German-language presentation of the BI-RADS lexicon [52] and a structured analysis of breast MRI [53] are included in the literature. Based on our experience using the Kaiser score for many years and on numerous interdisciplinary discussions and discussions with colleagues over the last 20 years, the criteria for findings must be clearly defined. However, semantic criteria are always subject to a certain level of subjectivity, for example, the effect of the subjective first impression on the objective description (“looks like cancer...”). Consequently, structured description based on the BI-RADS lexicon is considered difficult to reproduce [18, 21]. In contrast, the Kaiser score is robust with respect to the subjective interpretation of individual criteria. However, some basic definitions are needed.



► **Fig. 2** The Kaiser score integrates the 4 BI-RADS criteria margins, curve type, internal enhancement and edema into a flowchart. The flowchart asks the characteristics of the respective diagnostic criterion (e.g. “circumscribed” vs “irregular” margins). If the diagnostic criterion does not show definite characteristics, the basic category is chosen. The decisions guide through the flowchart to a specific score. These scores range between 1 and 11 and reflect increasing probabilities of malignancy. The traffic light colouring serves as an interpretation guidance (details given in text and tab. 2): green: not suspicious, biopsy primarily not recommended (BI-RADS 2/3). Yellow: suspicious, biopsy recommended (BI-RADS 4a, 4b). Red: highly suspicious, biopsy necessary. If biopsy returns benign results, congruence between biopsy results and imaging has to be carefully reviewed (BI-RADS 4c/5). A free and interactive online application can be accessed at <https://radiologie-weiterbildung.de/kaiser-score/>.

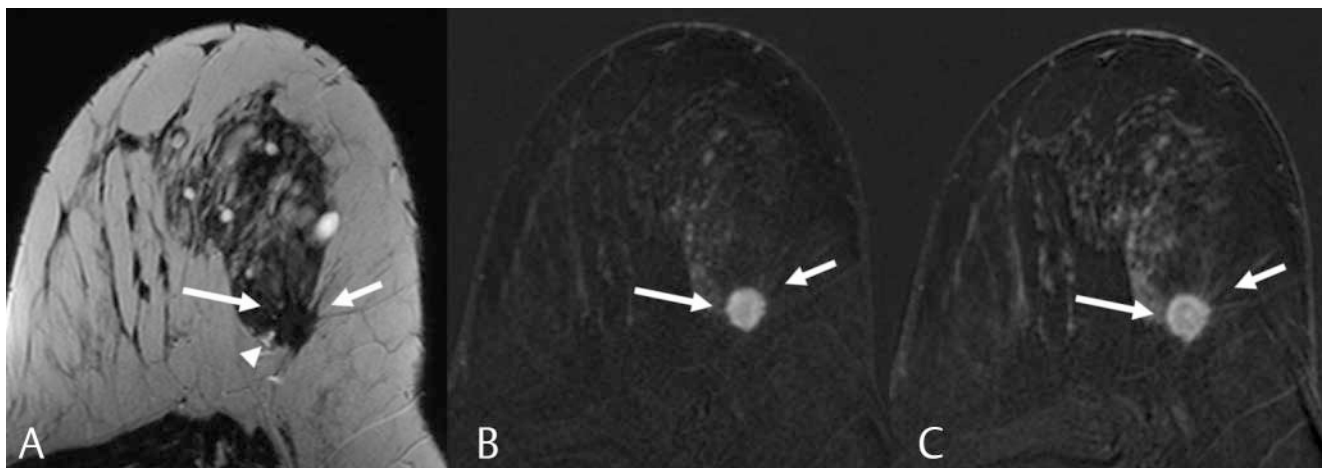


► **Fig. 3** Premenopausal patient with new focal lesion. The STIR sequence **A** reveals an isointense mass lesion without edema (dashed circle: area surrounding the lesion). The lesion exhibits fast initial enhancement in the early dynamic series (**B**, not fat-saturated). The white arrows mark three faint and root-like extensions of the lesion. This finding is consistent with “spiculation”. Compared to the early dynamic phase, the last dynamic phase **C** reveals a signal decline, consistent with “wash-out”. The internal enhancement is “not homogeneous”. According to ► **Fig. 2**, a KS of 9 is assigned. Percutaneous core biopsy revealed invasive ductal carcinoma G2, hormone receptor-positive. Note: The KS is robust and compensates for observer-related bias. In this example – for instance – the user may not acknowledge the presence of “spiculations”. In this reading, a KS of 8 will be assigned, which is also to be considered as “suspicious” (BI-RADS IVC/V).

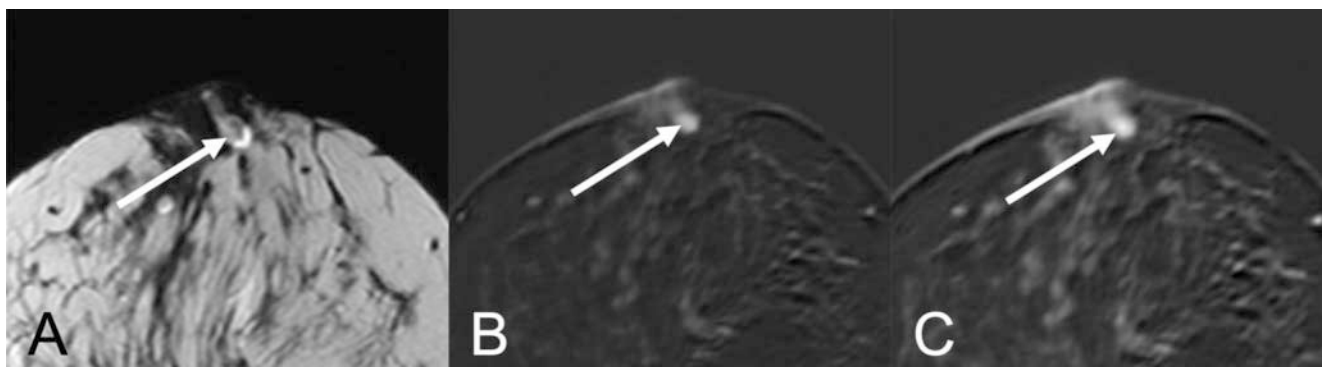
Default category

This includes the term default category as defined in this article for the first time. A diagnostic criterion can be “present” or “not present”. To minimize subjectivity, a criterion should only be evaluated as positive if there is no doubt. If, for example, the presence of spiculation is unclear, it should always be assessed as absent. Only a critical evaluation can minimize the subjective

effect of the first impression on the examiner. Particularly with respect to breast imaging, there is always the fear of overlooking lesions, resulting in a low threshold for assigning high BI-RADS categories and thus in a low biopsy threshold [51]. Especially with regard to value-based health care, we define a default category for every diagnostic criterion that is automatically applied in the case of unclear findings or contradictory images.



► **Fig. 4** Perimenopausal patient with newly detected architectural distortion on mammography. On sonography, multiple indeterminate lesions are evident. The non-fat-saturated T2-weighted sequence reveals a heterogeneous, isointense mass lesion. There is evidence of architectural distortion (arrows in **A**) and perifocal edema (arrowhead in **A**). Subtraction images of the early dynamic series **B** reveal mass lesions with strong enhancement. There is evidence of several subtle spiculations. Both architectural distortion and spiculations are better delineated in the late dynamic sequence (arrows in **C**). Here, peripherally accentuated heterogeneous washout is also evident. Findings are consistent with a KS of 11. Percutaneous core biopsy revealed invasive ductal carcinoma G3, hormone receptor-positive. Two ipsilateral lymph node metastases were confirmed histologically. This example highlights the robustness of the KS to observer-related bias. If the reader is not sure whether spiculations are definitely present, the default category “not spiculated” must be selected. In this case a KS of 8 will be assigned. This will not change the overall KS assessment, as both KS 11 and 8 have to be considered as suspicious (BI-RADS IVc/V).



► **Fig. 5** Premenopausal patient with new onset of bloody secretion. The T2-weighted sequence reveals presence of a retroareolar ductasia (**A**: T2 TSE, echo time 192 ms) with subsequent isointense intraductal lesion (arrow). In the early dynamics (**B**), there is evidence of strong and homogeneous enhancement with subsequent plateau (**C**). Findings translate to a KS of 2. Caveat: There is evidence of delayed enhancement in the surrounding tissue. This pattern may mimic a “persistent signal increase”. However, in equivocal cases, the default category applies, which is “plateau” in this case. The combination of clinical presentation, intraductal location, and generally benign breast MRI phenotype is highly suggestive of a benign papilloma. Management was invasive and the lesion was completely resected. Histology revealed an intraductal papilloma without atypia.

Margin

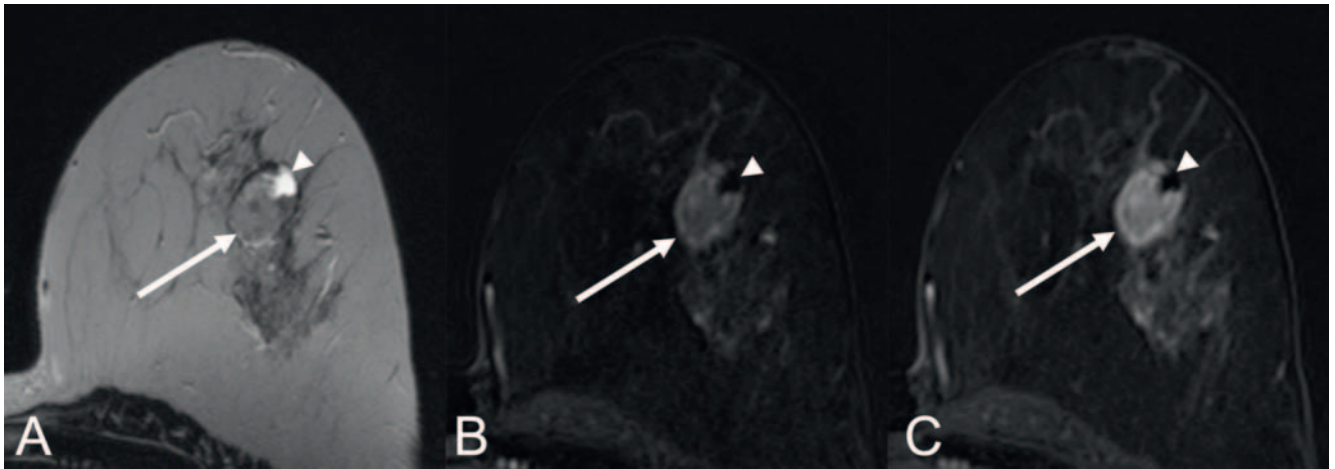
The BI-RADS lexicon differentiates between a “circumscribed” and “non-circumscribed” margin. Spiculation is considered a special type of “non-circumscribed” margin [19]. The machine learning algorithm on which the KS is based identified the independent significance of “spiculation” [24]. Therefore, this feature is discussed separately in the following.

A lesion is considered circumscribed when it can be easily delimited on all sides from the surrounding tissue. There are no zones in which the lesion infiltrates the perifocal tissue. The margin can be seen in both the early dynamic phase and the T2-weighted sequence. Partial volume effects can affect the interpre-

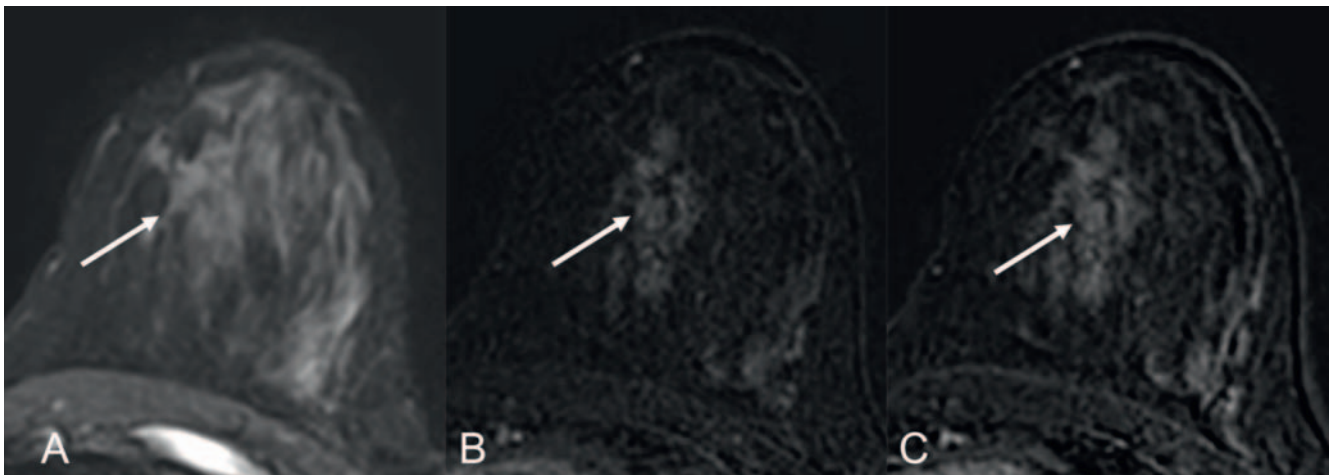
tation of this feature. The default category for the margin is “not circumscribed”.

Spiculation

In X-ray mammography, spiculation is considered a highly specific malignancy criterion. On breast MRI, spiculations have a concave lateral margin and a pointed tip and protrude in a “root-like” manner from contrast-enhancing lesions [40]. A singular spicule can be present and is referred to as the “root sign” by Werner Kaiser. The classic finding with multiple spicules is thus a variant of this criterion [40]. ► **Fig. 2, 3** show examples of spiculations.



► **Fig. 6** Perimenopausal patient with new palpable lesion on the left breast. Breast MRI was indicated for biopsy planning due to sonographically equivocal bilateral lesions. The T2w-TSE sequence (**A**, TE 192 ms) reveals a circumscribed focal lesion (arrow). Slow initial enhancement **B** is followed by a persistent signal increase in the late dynamic phase **C**. No spiculation. No edema. Finding translates to a KS of 1, corresponding to a benign breast MRI phenotype (BI-RADS II). Without guidance of a structured assessment tool, the bizarre internal structure may appear suspicious at first glance. The KS assessment as clearly benign is supported by additional diagnostic criteria. In this case a cystic compartment within the lesion is evident (arrowhead). This pattern is typical of benign findings. According to the patient’s preference, a percutaneous core biopsy was performed. Histologic workup revealed a regressively altered fibroadenoma B2 consistent with the breast MRI phenotype. Upon the patient’s request, the lesion was subsequently surgically removed.



► **Fig. 7** Postmenopausal patient with faint pleomorphic microcalcifications in two small clusters within the left inner quadrants. The STIR sequence **A** reveals no abnormalities. After gadolinium administration, there is evidence of a non-homogeneous regional non-mass. The non-mass reveals multiple grouped and ring-like enhancements in the initial dynamic phase (**B**: subtraction image). In the late phase, signal intensity remains unchanged (plateau). The lesion is not circumscribed. The finding translates to a KS of 5, corresponding to a breast MRI phenotype of a malignant lesion, most likely DCIS. Histological verification by vacuum-assisted biopsy revealed DCIS G3.

The default category is “absent”. Spiculation is thus only categorized as present in textbook cases.

Spiculations can be more evident on T2-weighted sequences than in the dynamic phase. Therefore, this criterion can be evaluated on T2-weighted sequences and in the dynamic phase. Spiculations can sometimes be confused with minor motion artifacts in

the dynamic phase. If there is suspicion of spiculations in the subtraction series, we always verify the finding on the original images.

Practical tip: It is important not to combine the margin and spiculations with one another. In fact, both criteria can be present independently of one another: Accordingly, a spiculated lesion can have a “circumscribed” margin. Conversely, there can be “non-circumscribed” and “non-spiculated” lesions.

Curve type

The BI-RADS lexicon defines three curve types: The spectrum ranges from persistent signal increase between the early and late post-contrast image (type I curve) to plateau (unchanged signal intensity: type II curve) and washout (type III curve). The latter is characterized by signal loss between the late and early post-contrast image.

While a washout curve is suspicious for malignancy, a persistent signal increase tends to indicate a benign lesion. The plateau type of enhancement is nonspecific and should be considered suspicious in case of doubt. However, the curve type alone does not have a sufficient level of diagnostic significance. An invasive carcinoma can show persistent enhancement and benign adenosis is often displayed with washout [35]. It is the combination of the KS criteria that allows a reliable diagnosis.

The default category for the evaluation of curve type is “plateau”. Another curve type should only be diagnosed in the case of clear signal change over time.

We prefer visual assessment of the curve type. This requires a standardized viewing layout (hanging protocol). Alternatively, classic curve measurement using a region of interest (ROI) can be performed. However, this requires the subjective identification of the region with maximum contrast enhancement in the lesion [35]. This type of curve measurement is therefore time-intensive and prone to errors. Therefore, we do not recommend this measurement. Alternatively, software tools with color-coded overlays of the curve types can be used. These tools can support the diagnosis of non-mass lesions [52]. However, even minor motion artifacts can be confused with suspicious curve types. For this reason, we always verify the findings with the original images.

Practical tip: Exact identification of the instant of early enhancement is essential. If the wait time is too short after intravenous contrast administration or in the case of a delayed circulation time, the first measurement will be performed too early. In this case, we use the second measurement after gadolinium administration as a reference for early contrast enhancement. If this approach is not used, a lesion can be overlooked in the worst case or the curve may appear less suspicious [53].

Internal enhancement

Internal enhancement can be “homogeneous” or “not homogeneous”. The default category is “not homogeneous”.

Homogeneous lesions have either no or a structured internal architecture. Septa and compartments are typical examples and are characteristic for these usually benign findings. “Centrifugal” and “central” are subtypes of homogeneous internal enhancement [26]. Such lesions are to be identified on non-contrast images. In the early dynamic phase, only enhancement of a central compartment is seen. In the case of the “centrifugal” phenotype, there is also enhancement of the lesion periphery over time. This does not occur in the case of “central” internal enhancement. Histology usually shows fibroadenomas with regressive changes.

All other lesions are considered “not homogeneous”. A structured internal architecture is not present here. An unstructured enhancement pattern typical for cancer without clear internal structures is typically seen. “Centripetal internal enhancement”

is a subtype. This is pathognomonic for a malignant lesion. Central fibrotic or necrotic carcinomas are typically seen in the histological correlation. On breast MRI, only enhancement of the periphery is initially seen. In contrast, enhancement of the center of the lesion occurs only with a delay and usually incompletely.

Practical tip: Ring-like enhancement is often primarily evaluated as typical of malignancy. However, the differential diagnosis also includes benign findings like abscesses and simple cysts. Homogeneous ring-like enhancement is the rule in these cases, while malignant lesions with ring-like enhancement have a different morphological pattern. Heterogeneous contrast enhancement of the periphery is seen. Irregular or even nodular thickening is possible there.

It is challenging to analyze the internal enhancement of a non-mass. The analogy to microcalcification diagnosis is helpful here. The morphology of scattered (discontinuous) lesions is decisive also in these cases. Monomorphic calcification shows a uniform (homogeneous) morphology. The opposite is true for polymorphic microcalcification (not homogeneous). Analogously, the internal enhancement on breast MRI can be classified as homogeneous (= monomorphic) and not homogeneous (= polymorphic).

A lesion with homogeneous enhancement and central washout is typical for benign adenosis. However, caution is advised in the case of very small areas of enhancement, which can imitate homogeneous enhancement due to the small size.

Edema

Ipsilateral edema is a highly specific criterion for malignancy. It indicates an aggressive breast cancer phenotype. Ipsilateral edema is associated with higher grading, lymphangitic carcinomatosis, and a poor prognosis. To avoid false-positive findings, the criterion may not be used after recent biopsy, surgery, or radiotherapy. Bilateral edema indicates a systemic etiology (renal, cardiac) [54–56].

The default category is “not present”. Ipsilateral edema can be further classified as perifocal, prepectoral, diffuse, or subcutaneous.

Further diagnostic criteria: unimportant?

Experienced diagnosticians know a number of additional criteria for the interpretation of breast MRI (shown with maximum detail in [57]). The lack of inclusion in the Kaiser score does not mean that they cannot provide additional diagnostic value. The Kaiser score is based on a machine learning algorithm that categorizes semantic lesion features provided by radiologists according to various imaging phenotypes [24]. In general, under such conditions, the greater the database, the more subcategories can be defined. The Kaiser score can be used for any enhancement of the breast [18, 26]. The classification algorithm of the Kaiser score lumps all enhancement together. This has advantages and disadvantages: the Kaiser score is simple, easy to use, and diagnostically accurate. However, there are special cases in which the clinical context modifies the diagnosis (as discussed in the corresponding section of this article). One example is intraductal enhancement. The presence of T1 hyperintense duct ectasia argues strongly against a malignant origin and for a stasis of secretions with possible periductal inflammation, while T2w intra-

► **Table 2** Management recommendation depending on KS and clinical situation.

| Clinical situation | KS | BI-RADS and clinical management |
|--|------|--|
| Asymptomatic patient with low risk without specific conventional correlate | 1–4 | BI-RADS 2; follow-up can be considered |
| Any patient with a new lesion or without prior images | 5–11 | BI-RADS 4 (KS 5–7) or 5 (KS > 7); percutaneous biopsy needed |
| Asymptomatic risk patient without specific conventional correlate | 3–4 | BI-RADS 3; 6-month follow-up recommended. Low biopsy threshold in new KS 4 lesion in patients with BRCA-1 mutation |
| Symptomatic patient with new finding on palpation | 1–4 | BI-RADS 3; 6-month follow-up recommended, possibly also biopsy |
| Symptomatic patient with ipsilateral nipple discharge | 2, 4 | BI-RADS 4a; when intraductal or retroareolar biopsy with suspected diagnosis of papilloma recommended |
| Corresponding mammographic microcalcifications BI-RADS 4 | 3 | BI-RADS 4; biopsy recommended, also follow-up with X-ray mammography or MRI possible (maximum DCIS possible) |
| Known lesion with long-term stability documented on imaging | 8 | BI-RADS 2 (when stable ≥ 2 years); otherwise, BI-RADS 3 and follow-up |
| Post-therapeutic scar tissue < 5 years after intervention | 5–7 | BI-RADS 3; 6-month follow-up recommended. Biopsy can be considered but if the PPV is low, progression in the short term is not likely. |

ductal fluid with high signal intensity in association with a contrast-enhancing focal lesion is virtually pathognomonic for the diagnosis of a papilloma (see ► **Fig. 4**). The Kaiser score reflects a probability of malignancy but can be combined under consideration of additional criteria and clinical information for more specific diagnoses (see ► **Table 2**). However, the results of the Kaiser score are sufficient for a general differentiation between benign and malignant contrast-enhancing lesions.

Management recommendation based on the Kaiser score

The KS is not a fully automatic algorithm. Its use supports the interpreting physician in that it translates the physician's structured reporting of criteria into a probability of malignancy in an evidence-based manner. From the KS result, the examiner can derive a concrete clinical management recommendation that also includes the individual senological situation of the patient. The combination of the clinical picture (symptoms, palpation findings), conventional imaging (new lesion), and hormone status allows accurate personalized diagnosis. For example, a new palpable lesion is considered suspicious for malignancy in postmenopausal patients until proven otherwise, while the situation is more complex in premenopausal women with the same constellation of findings. In the following we discuss some typical scenarios with more details being provided in ► **Table 2**.

For example, a lesion with a KS of 2 is to be evaluated as definitely benign (► **Fig. 2**). However, the finding can still require invasive management. This is the case, for example, in a symptomatic intraductal papilloma (see ► **Fig. 5**).

In high-risk situations, false-negative findings should be avoided. Caution is advised when assigning a KS of 4 in high-risk situations. Insufficient image quality and/or a small lesion size can result in misinterpretation of KS 8 findings as KS 4. It is important to system-

atically apply the default category, thereby resulting in a KS of 8 in case of doubt.

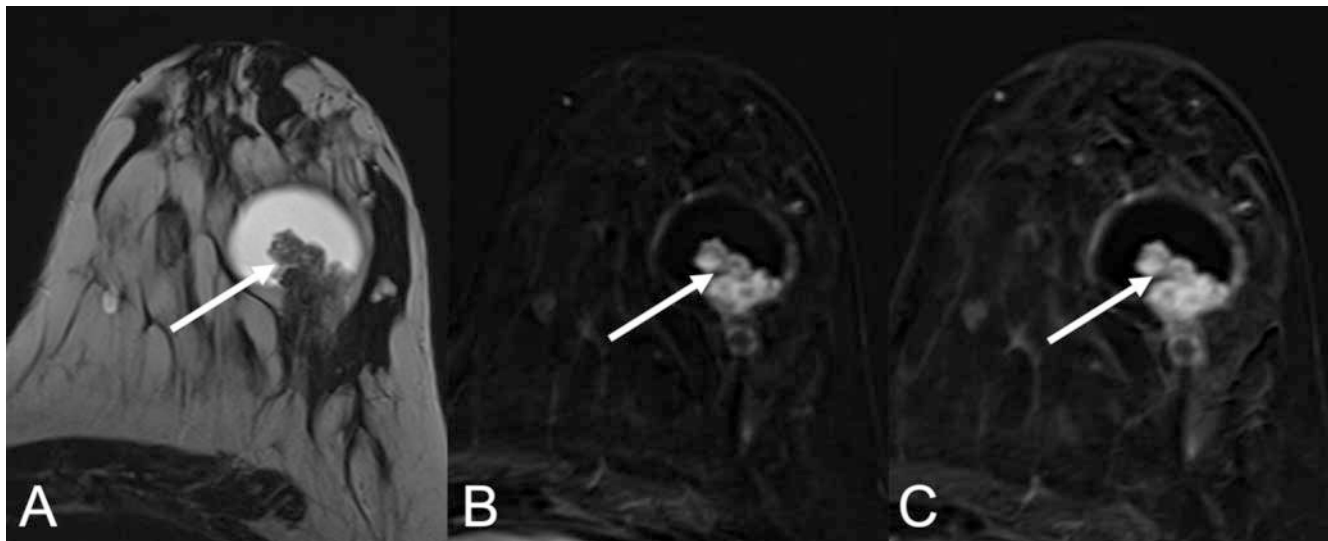
The long-term clinical course also affects the management recommendation. Large adenosis or fibroadenomas are sometimes classified as KS 8. This corresponds to the KS of a suspicious finding. If these findings remain unchanged for years, a biopsy is not recommended.

The management recommendation after determination of the KS in breast MRI must also take current diagnostic imaging into account. A lesion with a KS of 3 is to be evaluated as benign. However, if suspicious pleomorphic microcalcifications are present on X-ray mammography or tomosynthesis, this finding must be included in the management recommendation. In this case, a lesion with unclear malignant potential (B3) must be suspected. We, therefore, recommend invasive management.

In the case of a contrast-enhancing lesion within a cyst, the finding is "complex cyst". The differential diagnosis includes the entire family of papillary lesions and ranges from papilloma (without atypia) to papillary DCIS and invasive carcinoma. Thus, histological workup is indicated in every case regardless of the KS and invasive management is necessary (see ► **Fig. 8**).

Summary and future developments

The KS is an easy-to-use, evidence-based decision rule for breast MRI. Based on its structure, the KS supports an objective description, structured documentation, and exact diagnosis of contrast-enhancing lesions on breast MRI. Under consideration of clinically relevant information, it can support rational patient management. The KS defines specific imaging phenotypes derived from the combination of four BI-RADS criteria. The KS greatly simplifies and shortens the documentation of findings, which has a positive effect on the clinical workflow.



► **Fig. 8** Perimenopausal patient with new palpable lesion. On breast MRI a “complex cyst” is diagnosed corresponding to a contrast-enhancing lesion within a cyst (arrow in A, TSE sequence, TE 192 ms). The internal enhancement is heterogeneous. The curve type is indistinct, so the basic category “plateau” applies. The margin is circumscribed. The finding translates to a KS of 2. Although the KS is strongly suggestive of a benign finding, management of the lesion has to be invasive. The finding was biopsied and surgically removed. An intracystic papilloma without atypia was diagnosed upon histological verification.

Establishing the KS in the clinical routine is the most important task for the near future. Integration in the BI-RADS lexicon as in the case of PI-RADS is the next step. A clinical decision rule has been integrated in PI-RADS since version 2.0, a development we would also like to see for the BI-RADS lexicon.

Conflict of Interest

The authors declare that personal connections exist for Matthias Dietzel and Pascal Baltzer: both are managing directors of a GBR (radiologie-weiterbildung.de).

References

- [1] Kaiser WA. MR Mammography (MRM). 1st ed. Berlin Heidelberg: Springer; 1994
- [2] Kaiser WA. False-positive results in dynamic MR mammography. Causes, frequency, and methods to avoid. *Magn Reson Imaging Clin N Am* 1994; 2: 539–555
- [3] Sardanelli F, Boetes C, Borisch B et al. Magnetic resonance imaging of the breast: recommendations from the EUSOMA working group. *Eur J Cancer* 2010; 46: 1296–1316. doi:10.1016/j.ejca.2010.02.015
- [4] Mann RM, Balleyguier C, Baltzer PA et al. European Society of Breast Imaging (EUSOBI), with language review by Europa Donna – The European Breast Cancer Coalition, Breast MRI: EUSOBI recommendations for women’s information. *Eur Radiol* 2015; 25: 3669–3678. doi:10.1007/s00330-015-3807-z
- [5] Bakker MF, de Lange SV, Pijnappel RM et al. DENSE Trial Study Group, Supplemental MRI Screening for Women with Extremely Dense Breast Tissue. *N Engl J Med* 2019; 381: 2091–2102. doi:10.1056/NEJMoa1903986
- [6] Kaiser CG, Dietzel M, Vag T et al. Cost-effectiveness of MR-mammography vs. conventional mammography in screening patients at intermediate risk of breast cancer – A model-based economic evaluation. *Eur J Radiol* 2020; 109355. doi:10.1016/j.ejrad.2020.109355
- [7] Tollens F, Baltzer PAT, Dietzel M et al. Cost-Effectiveness of Digital Breast Tomosynthesis vs. Abbreviated Breast MRI for Screening Women with Intermediate Risk of Breast Cancer-How Low-Cost Must MRI Be? *Cancers (Basel)* 2021; 13. doi:10.3390/cancers13061241
- [8] Baltzer PAT. Supplemental screening using breast MRI in women with mammographically dense breasts. *Eur J Radiol* 2021; 136: 109513. doi:10.1016/j.ejrad.2020.109513
- [9] Clauser P, Mann R, Athanasiou A et al. A survey by the European Society of Breast Imaging on the utilisation of breast MRI in clinical practice. *Eur Radiol* 2018; 28: 1909–1918. doi:10.1007/s00330-017-5121-4
- [10] Debald M, Abramian A, Nemes L et al. Who may benefit from preoperative breast MRI? A single-center analysis of 1102 consecutive patients with primary breast cancer. *Breast Cancer Res Treat* 2015; 153: 531–537. doi:10.1007/s10549-015-3556-3
- [11] Fueger BJ, Clauser P, Kapetas P et al. Can supplementary contrast-enhanced MRI of the breast avoid needle biopsies in suspicious microcalcifications seen on mammography? A systematic review and meta-analysis. *Breast* 2021; 56: 53–60. doi:10.1016/j.breast.2021.02.002
- [12] Gommers JJ, Voogd AC, Broeders MJ et al. Breast magnetic resonance imaging as a problem solving tool in women recalled at biennial screening mammography: A population-based study in the Netherlands. *Breast* 2021; 60: 279–286. doi:10.1016/j.breast.2021.11.014
- [13] Bennani-Baiti B, Bennani-Baiti N, Baltzer PA. Diagnostic Performance of Breast Magnetic Resonance Imaging in Non-Calcified Equivocal Breast Findings: Results from a Systematic Review and Meta-Analysis. *PLoS ONE* 2016; 11: e0160346. doi:10.1371/journal.pone.0160346
- [14] Spick C, Szolar DHM, Preidler KW et al. Breast MRI used as a problem-solving tool reliably excludes malignancy. *Eur J Radiol* 2015; 84: 61–64. doi:10.1016/j.ejrad.2014.10.005
- [15] Comstock CE, Gatsonis C, Newstead GM et al. Comparison of Abbreviated Breast MRI vs Digital Breast Tomosynthesis for Breast Cancer Detection Among Women With Dense Breasts Undergoing Screening. *JAMA* 2020; 323: 746–756. doi:10.1001/jama.2020.0572
- [16] Geuzinge HA et al. Cost-effectiveness of MRI screening for women with extremely dense breast tissue. *Journal of the National Cancer Institute* 2021; 113 (11): 1476–1483. doi:10.1093/jnci/djab119

- [17] Ikeda DM, Hylton NM, Kinkel K et al. Development, standardization, and testing of a lexicon for reporting contrast-enhanced breast magnetic resonance imaging studies. *J Magn Reson Imaging* 2001; 13: 889–895
- [18] Marino MA, Clauser P, Woitek R et al. A simple scoring system for breast MRI interpretation: does it compensate for reader experience? *Eur Radiol* 2016; 26: 2529–2537. doi:10.1007/s00330-015-4075-7
- [19] Morris EA, Comstock C, Lee C et al. ACR BI-RADS® Magnetic Resonance Imaging, in: ACR BI-RADS® Atlas, Breast Imaging Reporting and Data System. 5th ed. Reston, VA: American College of Radiology; 2013
- [20] Weinreb JC, Barentsz JO, Choyke PL et al. PI-RADS Prostate Imaging – Reporting and Data System: 2015, Version 2. *Eur. Urol* 2016; 69: 16–40. doi:10.1016/j.eururo.2015.08.052
- [21] Stoutjesdijk MJ, Fütterer JJ, Boetes C et al. Variability in the description of morphologic and contrast enhancement characteristics of breast lesions on magnetic resonance imaging. *Invest Radiol* 2005; 40: 355–362
- [22] Baltzer PAT, Kaiser WA, Dietzel M. Lesion type and reader experience affect the diagnostic accuracy of breast MRI: A multiple reader ROC study. *Eur J Radiol* 2015; 84: 86–91. doi:10.1016/j.ejrad.2014.10.023
- [23] Jansen SA, Shimauchi A, Zak L et al. The diverse pathology and kinetics of mass, nonmass, and focus enhancement on MR imaging of the breast. *J Magn Reson Imaging* 2011; 33: 1382–1389. doi:10.1002/jmri.22567
- [24] Baltzer PAT, Dietzel M, Kaiser WA. A simple and robust classification tree for differentiation between benign and malignant lesions in MR-mammography. *Eur Radiol* 2013; 23: 2051–2060. doi:10.1007/s00330-013-2804-3
- [25] Marino MA, Helbich T, Baltzer P et al. Multiparametric MRI of the breast: A review. *J Magn Reson Imaging* 2018; 47: 301–315. doi:10.1002/jmri.25790
- [26] Dietzel M, Baltzer PAT. How to use the Kaiser score as a clinical decision rule for diagnosis in multiparametric breast MRI: a pictorial essay. *Insights Imaging* 2018; 9: 325–335. doi:10.1007/s13244-018-0611-8
- [27] Dietzel M, Wenkel E, Hammon M et al. Does higher field strength translate into better diagnostic accuracy? A prospective comparison of breast MRI at 3 and 1.5 Tesla. *Eur J Radiol* 2019; 114: 51–56. doi:10.1016/j.ejrad.2019.02.033.
- [28] Clauser P, Pinker K, Helbich TH et al. Fat saturation in dynamic breast MRI at 3 Tesla: is the Dixon technique superior to spectral fat saturation? A visual grading characteristics study. *Eur Radiol* 2014; 24: 2213–2219. doi:10.1007/s00330-014-3189-7
- [29] Folkman J. The role of angiogenesis in tumor growth. *Semin Cancer Biol* 1992; 3: 65–71
- [30] Kuhl CK, Schradang S, Bieling HB et al. MRI for diagnosis of pure ductal carcinoma in situ: a prospective observational study. *Lancet* 2007; 370: 485–492. doi:10.1016/S0140-6736(07)61232-X
- [31] Vag T, Baltzer PAT, Renz DM et al. Diagnosis of ductal carcinoma in situ using contrast-enhanced magnetic resonance mammography compared with conventional mammography. *Clin Imaging* 2008; 32: 438–442. doi:10.1016/j.clinimag.2008.05.005
- [32] Baltzer PAT, Benndorf M, Gajda M et al. An exception to tumour neoangiogenesis in a malignant breast-lesion. *Breast J* 2010; 16: 197–198. doi:10.1111/j.1524-4741.2009.00875.x
- [33] Bennani-Baiti B, Baltzer PA. MR Imaging for Diagnosis of Malignancy in Mammographic Microcalcifications: A Systematic Review and Meta-Analysis. *Radiology* 2017; 283: 692–701. doi:10.1148/radiol.2016161106
- [34] Kuhl CK, Keulers A, Strobel K et al. Not all false positive diagnoses are equal: On the prognostic implications of false-positive diagnoses made in breast MRI versus in mammography/digital tomosynthesis screening. *Breast Cancer Res* 2018; 20: 13. doi:10.1186/s13058-018-0937-7
- [35] Baltzer PAT, Freiberg C, Beger S et al. Clinical MR-mammography: are computer-assisted methods superior to visual or manual measurements for curve type analysis? A systematic approach. *Acad Radiol* 2009; 16: 1070–1076. doi:10.1016/j.acra.2009.03.017
- [36] Baltzer PAT, Dietzel M, Camara O et al. A systematic comparison of two pulse sequences for edema assessment in MR-mammography. *Eur J Radiol* 2012; 81: 1500–1503. doi:10.1016/j.ejrad.2011.03.001
- [37] Baltzer P, Mann RM, Lima M et al. EUSOBI international Breast Diffusion-Weighted Imaging working group, Diffusion-weighted imaging of the breast—a consensus and mission statement from the EUSOBI International Breast Diffusion-Weighted Imaging working group. *Eur Radiol* 2020; 30: 1436–1450. doi:10.1007/s00330-019-06510-3
- [38] Baltzer PAT, Kapetas P, Sodano C et al. Kontrastmittelfreie Mamma-MRT. *Radiologe* 2019. doi:10.1007/s00117-019-0524-7
- [39] Dietzel M, Krug B, Clauser P et al. A Multicentric Comparison of Apparent Diffusion Coefficient Mapping and the Kaiser Score in the Assessment of Breast Lesions. *Invest Radiol* 2021; 56: 274–282. doi:10.1097/RLI.0000000000000739
- [40] Woitek R, Spick C, Schernthaner M et al. A simple classification system (the Tree flowchart) for breast MRI can reduce the number of unnecessary biopsies in MRI-only lesions. *Eur Radiol* 2017; 27: 3799–3809. doi:10.1007/s00330-017-4755-6
- [41] Wengert GJ, Pipan F, Almohanna J et al. Impact of the Kaiser score on clinical decision-making in BI-RADS 4 mammographic calcifications examined with breast MRI. *Eur Radiol* 2020; 30: 1451–1459. doi:10.1007/s00330-019-06444-w
- [42] Milos RI, Pipan F, Kalovidouri A et al. The Kaiser score reliably excludes malignancy in benign contrast-enhancing lesions classified as BI-RADS 4 on breast MRI high-risk screening exams. *Eur Radiol* 2020; 30: 6052–6061. doi:10.1007/s00330-020-06945-z
- [43] Jajodia A, Sindhwani G, Pasricha S et al. Application of the Kaiser score to increase diagnostic accuracy in equivocal lesions on diagnostic mammograms referred for MR mammography. *European Journal of Radiology* 2020; 109413. doi:10.1016/j.ejrad.2020.109413
- [44] Zhang B, Feng L, Wang L et al. [Kaiser score for diagnosis of breast lesions presenting as non-mass enhancement on MRI]. *Nan Fang Yi Ke Da Xue Xue Bao* 2020; 40: 562–566. doi:10.12122/j.issn.1673-4254.2020.04.18
- [45] Baum F, Fischer U, Vosschenrich R et al. Classification of hypervascularized lesions in CE MR imaging of the breast. *Eur Radiol* 2002; 12: 1087–1092. doi:10.1007/s00330-001-1213-1
- [46] Nunes LW, Schnall MD, Orel SG et al. Breast MR imaging: interpretation model. *Radiology* 1997; 202: 833–841
- [47] Demartini WB, Kurland BF, Gutierrez RL et al. Probability of malignancy for lesions detected on breast MRI: a predictive model incorporating BI-RADS imaging features and patient characteristics. *Eur Radiol* 2011; 21: 1609–1617. doi:10.1007/s00330-011-2094-6
- [48] Schnall MD, Blume J, Bluemke DA et al. Diagnostic architectural and dynamic features at breast MR imaging: multicenter study. *Radiology* 2006; 238: 42–53. doi:10.1148/radiol.2381042117
- [49] Ellmann S, Wenkel E, Dietzel M et al. Bäuerle, Implementation of machine learning into clinical breast MRI: Potenzial for objective and accurate decision-making in suspicious breast masses. *PLOS ONE* 2020; 15: e0228446. doi:10.1371/journal.pone.0228446
- [50] Istomin A, Masarwah A, Vanninen R et al. Diagnostic performance of the Kaiser score for characterizing lesions on breast MRI with comparison to a multiparametric classification system. *European Journal of Radiology* 2021; 138: 109659. doi:10.1016/j.ejrad.2021.109659
- [51] Baltzer P, Sardanelli F. The Mantra about Low Specificity of Breast MRI, in: *Breast MRI for High-Risk Screening*. Springer 2020: 11–21. doi:10.1007/978-3-030-41207-4_2
- [52] Vag T, Baltzer PAT, Dietzel M et al. Kinetic analysis of lesions without mass effect on breast MRI using manual and computer-assisted methods. *Eur Radiol* 2011; 21: 893–898. doi:10.1007/s00330-010-2001-6
- [53] Grippo C, Jagmohan P, Helbich TH et al. Correct determination of the enhancement curve is critical to ensure accurate diagnosis using the Kaiser score as a clinical decision rule for breast MRI. *Eur J Radiol* 2021; 138: 109630. doi:10.1016/j.ejrad.2021.109630

- [54] Baltzer PAT, Yang F, Dietzel M et al. Sensitivity and specificity of unilateral edema on T2w-TSE sequences in MR-Mammography considering 974 histologically verified lesions. *Breast J* 2010; 16: 233–239. doi:10.1111/j.1524-4741.2010.00915.x
- [55] Cheon H, Kim HJ, Kim TH et al. Invasive Breast Cancer: Prognostic Value of Peritumoral Edema Identified at Preoperative MR Imaging. *Radiology* 2018; 287: 68–75. doi:10.1148/radiol.2017171157
- [56] Kaiser CG, Herold M, Krammer J et al. Prognostic Value of “Prepectoral Edema” in MR-mammography. *Anticancer Res* 2017; 37: 1989–1995. doi:10.21873/anticancer.11542
- [57] Kaiser WA. *Signs in MR-Mammography*. Berlin Heidelberg: Springer; 2008 <http://www.springer.com/us/book/9783540732921> (accessed March 17, 2015).