

# Endoscopic management of tumors of minor ampulla: a multicenter study



## Authors

Ahamed A. Khalyfa<sup>1</sup>, Nayab Ahsan<sup>2</sup>, Mahnoor Inam<sup>2</sup>, Kamran Ayub<sup>3</sup>

## Institutions

- 1 Franciscan Saint James Health Olympia Fields Campus, Gastroenterology
- 2 Southwest Gastroenterology, Gastroenterology
- 3 Silver Cross Hospital, Gastroenterology

submitted 15.12.2021

accepted after revision 20.4.2022

## Bibliography

Endosc Int Open 2022; 10: E978–E981

DOI 10.1055/a-1839-5401

ISSN 2364-3722

© 2022. The Author(s).

This is an open access article published by Thieme under the terms of the Creative Commons Attribution-NonDerivative-NonCommercial License, permitting copying and reproduction so long as the original work is given appropriate credit. Contents may not be used for commercial purposes, or adapted, remixed, transformed or built upon. (<https://creativecommons.org/licenses/by-nc-nd/4.0/>)

Georg Thieme Verlag KG, Rüdigerstraße 14,  
70469 Stuttgart, Germany

## Corresponding author

Ahamed Khalyfa, Department of Internal Medicine/  
Gastroenterology, Franciscan St. James Health, Olympia  
Fields, IL, United States  
Fax: +1-502-794-8610  
akhalyfa1@gmail.com

## ABSTRACT

**Background and study aims** Papillary and duodenal carcinoma are aggressive cancers with poor 5-year survival rates. Papillectomy is a well-established treatment for early-stage carcinoma of the major papilla. Tumors arising in the minor papilla are relatively rare and there is little research available on the endoscopic management of these tumors.

**Patients and methods** The purpose of this study was to establish the safety and efficacy of endoscopic papillectomy in the management of minor papillary tumors. A total of six patients undergoing ERCP for papillectomy for minor papillary tumor at four hospitals were included in this study over a period of 5 years.

**Results** Papillectomy was technically successful in all six patients. Pathology revealed adenoma in three patients, adenoma with high-grade dysplasia in one patient, carcinoma in one patient, and carcinoid tumor in one patient. For follow-up, one patient had an additional tumor identified at 2 years which was found to be a recurrence of the original adenoma. This patient was treated with repeat papillectomy with no further evidence of recurrence.

**Conclusions** In our pilot study, we demonstrate that endoscopic papillectomy appears safe and effective in the management of minor papillary tumors.

## Introduction

Duodenal tumors occur as sporadic lesions and are a common finding in patients with familial adenomatous polyposis (FAP) [1]. Up to 80% of adult patients with FAP may develop duodenal tumors [2]. However, these tumors are becoming increasingly diagnosed even in patients without FAP due to the increasing number of endoscopies being performed [3]. The majority of these tumors arise in the major duodenal papilla and account for approximately 5% of gastrointestinal neoplasms [3]. In contrast, tumors arising in the minor papilla are uncommon and only described in case reports [4–10]. Tumors of the minor papilla are rare and are almost always reported as adenoma, or neuroendocrine tumors such as carcinoid, or somatostatinoma [4, 6]. Adenocarcinoma of the minor papilla is quite rare. A sur-

gical resection is the primary treatment for both minor and major papillary adenocarcinomas [4].

Benign lesions of the papilla have the potential to undergo malignant transformation to papillary carcinomas [11]. The incidence of malignant transformation to carcinoma in situ or invasive carcinoma has ranged from 25% to 85% [11]. Papillary and duodenal carcinoma are aggressive cancers with poor 5-year survival rates. Like colorectal cancer, papillary carcinomas are also thought to follow the adenoma-carcinoma sequence. To prevent malignant transformation of minor papillary tumors, complete resection or surveillance of these lesions is advisable.

There have been some case reports on endoscopic papillectomy and endoscopic mucosal resection of minor papillary tumors, however all of these studies include no more than one

► **Table 1** Patient demographics and minor papillary tumor characteristics.

	Patient 1	Patient 2	Patient 3	Patient 4	Patient 5	Patient 6
Gender	M	M	F	M	F	M
Age	45	56	61	67	52	41
Tumor type	Carcinoma	Adenoma	Adenoma	Adenoma	Carcinoid	Adenoma with High-grade dysplasia
Tumor Size	1 cm	2 cm	1.5 cm	1.7 cm	2.5 cm	3 cm
FAP	Yes	No	No	No	No	Yes
Pancreatic divisum	Type 1	None	Type 3	None	None	None

FAP, familial adenomatous polyposis.

patient [10, 12]. This lack of data compels further evaluation of managing minor papillary lesions by endoscopy. We report a multicenter case series of endoscopic papillectomy in the management of minor papillary tumors.

## Patients and methods

Consecutive patients undergoing papillectomy for minor papillary tumors at four hospitals were included in this study over a period of 5 years. Inclusion and exclusion criteria are detailed below:

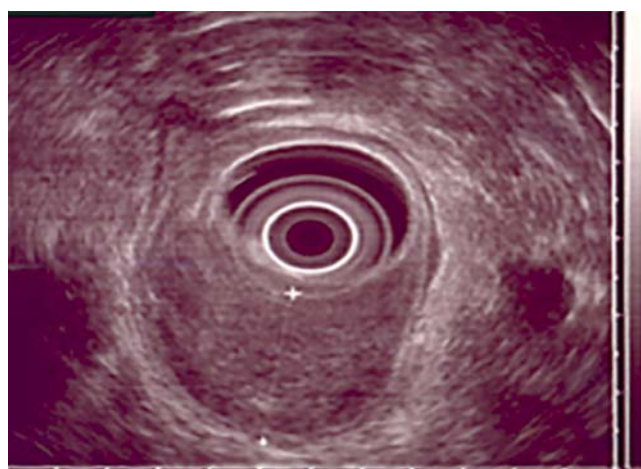
Inclusion criteria:

1. Any patient found to have minor papillary tumor with history of abdominal pain or pancreatitis, deemed to be secondary to the tumor, or tumor felt to be at high risk of progression to carcinoma were included in the study with intention of endoscopic resection.

Exclusion criteria:

1. Inability or refusal to provide informed consent
2. Contraindication to MAC sedation or general anesthesia
3. Contraindication to endoscopic resection including severe coagulopathy, immunosuppression.

A total of six patients were included in the study and all six patients underwent endoscopic retrograde cholangiopancreatography (ERCP) for the purpose of minor papillectomy (► **Table 1**). Magnetic resonance cholangiopancreatography and endoscopic ultrasound was performed on all patients prior to ERCP to rule out invasion (► **Fig. 1**). All patients underwent ERCP, and resection of the minor papilla was performed using snare polypectomy technique. An ERBE generator was used for all cases with the following Endocut Q settings: Effect 2, cut duration 1, cut Interval three. The specimens that were retrieved were sent for histopathologic analysis. Pancreatic stents were placed in the duct of Santorini (minor duct) after papillectomy in five patients, 3F×8-cm single pigtail stents in four patients, and one 5F×5-cm straight stent in one patient. All stents were removed after approximately 2 weeks. Stent placement was not successful in one patient.



► **Fig. 1** Endoscopic ultrasound demonstrating no deep invasion of tumor.

Complications were assessed postoperatively and by close outpatient follow-up. At 10 to 12 weeks, all six patients underwent repeat endoscopy with a standard duodenoscope for evaluation of residual neoplastic tissue. Results were reported as success, residual lesion, recurrence, and complications. Success was defined as a complete resection of the tumor regardless of the number of required procedures with no recurrences on follow-up endoscopies. A residual lesion was one in which gross or microscopic adenomatous tissue was present on follow-up endoscopies. Complications included pancreatitis, bleeding, perforation, and delayed papillary stenosis [13]. Pancreatitis was defined by a three-fold increase in serum amylase or lipase in presence of abdominal pain. Bleeding was defined as a drop in hemoglobin of at least 2 grams or if clinical suspicion led to performing endoscopy to evaluate for possible bleeding. Recurrence was defined as the presence of a new tumor on repeat endoscopy. Complete excision was confirmed by reviewing the pathology of the prior tissue biopsy.

## Results

Papillectomy was technically successful in all six patients. One patient required two ERCPs for complete papillectomy. One patient developed post ERCP pancreatitis and was kept in the hospital for 2 days. No other major complications were noted. Two patients had abdominal pain for one day post ERCP which was considered a minor complication.

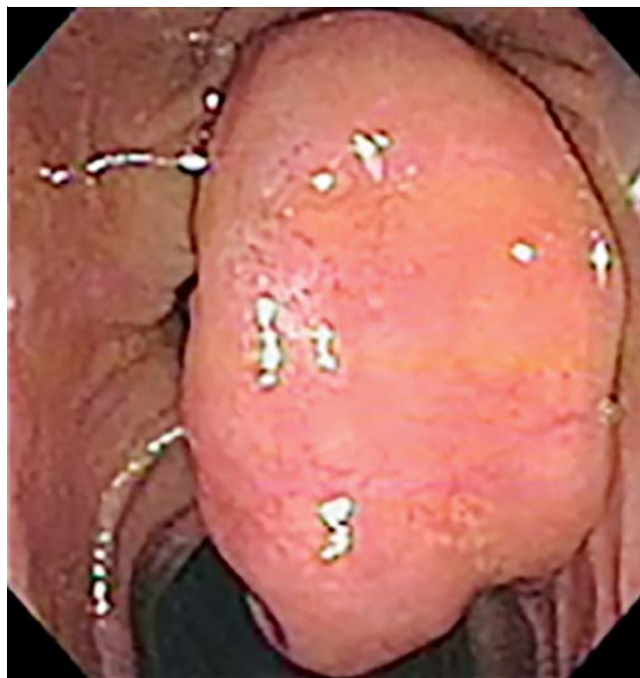
The tumors varied in size from 1 cm to 3 cm (► Fig. 2). Pathology revealed adenoma in three patients, adenoma with high-grade dysplasia in one patient, carcinoma in one patient, and carcinoid tumor in one patient.

Follow-up for these patients ranged from 2 to 5 years with esophagogastroduodenoscopy using duodenoscope at 3 months, at 1 year and yearly thereafter. One patient had an additional tumor identified at 2 years, which was found to be a recurrence of the original adenoma (4mm). This patient was treated with repeat papillectomy. The patient with carcinoma had endoscopies every 3 months for a year followed by yearly endoscopy; no recurrence was noted during the 3 years of follow-up. Confocal laser endomicroscopy was performed at the time of each endoscopy to look for tumor recurrence, showing no further evidence of tumor at the cellular level. Two of six patients (33%) had FAP. Two patients had pancreas divisum, one with Type 1, and other with Type 3 Divisum.

## Discussion

Tumors of the minor papilla are rare [6]. In contrast to tumors of the major papilla, those of the minor papilla are less symptomatic unless they grow large or cause pancreatic duct anomalies [5, 6]. Historically, tumors of major papilla are removed surgically but given the increased risk of post-surgical complications, endoscopic resection is now becoming a safe and effective treatment option in these patients [3]. Surgical or endoscopic resection is indicated for all tumors to prevent progression to carcinomas [11]. There are several existing case reports on endoscopic resection of minor papilla tumors [4–10]. However, very little data are available regarding the long-term outcome for patients after endoscopic treatment of tumors of minor papilla in order to ascertain the long-term safety and efficacy of such treatment. One study identified three cases of minor papillary tumors that were managed by endoscopic resection, but the follow-up duration was only 12 months [9]. Our case series is unique as not only was the follow-up period longer between 2 to 5 years, consistent with follow-up period suggested by recent guidelines on papillary tumor management [14], but it also highlighted that endoscopic resection of benign tumors and early malignant tumors of the minor duodenal papilla is a relatively safe procedure associated with favorable long-term outcomes.

Pancreatitis is a well-recognized complication after endoscopic resection of tumor of major papilla. Recent evidence has suggested prophylactic pancreatic duct stenting to reduce the risk of pancreatitis [14]. With our case series, stents were placed after minor papillary resection into the duct of Santorini, or minor duct. Our case series showed a comparable rate of



► Fig. 2 Endoscopy of minor papillary tumor, carcinoid.

procedure-related complication to reported findings in the literature, as one out of six patients was found to have pancreatitis [3]. The other five patients had no major complications and were discharged within 24 hours. In addition, none of our patients were noted to have delayed stenosis. Among the patients who followed up, there were no recurrences of tumor and no patient was found to have cancer develop over a mean follow-up period of 2 to 5 years. This demonstrates that complete removal of these lesions via endoscopic resection is safe and has favorable outcomes.

Confocal laser endomicroscopy (CLE) is an advanced endoscopic imaging technology that facilitates the observation of gastrointestinal epithelia at a magnified, cellular level [15]. CLE is utilized in the detection of dysplasia, adenoma, and carcinoma. CLE has a high diagnostic accuracy for conditions affecting the gastrointestinal tract, such as esophageal, gastric, and colonic neoplasia, pancreatic cysts and solid lesions, and malignant pancreatobiliary strictures [15]. One single-center study comparing dual-focus narrow band imaging and CLE for real-time diagnosis of adenomatous polyps in patients with FAP, showed that CLE had a similar, high degree of diagnostic value as compared with narrow band imaging [16]. With respect to duodenal papilla, there has been evidence to suggest that CLE provides adequate diagnostic accuracy similar to histopathologic specimens [17]. In our study, we were able to effectively demonstrate CLE as a reliable tool for detection of recurrence of minor papilla tumors.

## Conclusions

In our pilot study, endoscopic papillectomy appears safe and effective in the management of minor papillary tumors. Larger

studies with long-term follow-up are needed to further demonstrate the safety and efficacy of endoscopic resection for minor papillary tumors.

## Competing interests

The authors declare that they have no conflict of interest

## References

- [1] Lapp RT, Hutchins GF. Minor papilla adenoma management in patients with pancreas divisum and familial adenomatous polyposis. *ACG Case Rep J* 2013; 8: 47–50
- [2] Han J, Kim MH. Endoscopic papillectomy for adenomas of the major duodenal papilla (with video). *Gastrointest Endosc* 2006; 63: 292–301
- [3] Irani S, Arai A, Ayub K et al. Papillectomy for ampullary neoplasm: results of a single referral center over a 10-year period. *Gastrointest Endosc* 2009; 70: 923–932
- [4] Sugiyama M, Kimura W, Muto T et al. Endoscopic resection of adenoma of the minor papilla. *Hepato-Gastroenterol* 1999; 46: 189–192
- [5] Lucena JF, Alvarez OA, Gross GWW. Endoscopic resection of heterotopic pancreas of the minor duodenal papilla. *Gastrointest Endosc* 1997; 46: 69–72
- [6] Nakamura Y, Tajiri T, Uchida E et al. Adenoma of the minor papilla associated with pancreas divisum. *Hepato-Gastroenterol* 2007; 54: 1841–1843
- [7] Loew BJ, Lukens FJ, Navarro F et al. Successful endoscopic resection of a gangliocytic paraganglioma of the minor papilla in a patient with pancreas divisum and pancreatitis (with video). *Gastrointest Endosc* 2007; 65: 547–550
- [8] Itoi T, Sofuni A, Itokawa F et al. Endoscopic resection of carcinoid of the minor duodenal papilla. *World J Gastroenterol* 2007; 13: 3763–3764
- [9] Trevino JM, Wilcox CM, Varadarajulu S. Endoscopic resection of minor papilla adenomas (with video). *Gastrointest Endosc* 2008; 68: 383–386
- [10] Kanamori A, Kumada T, Kiriya S et al. Endoscopic papillectomy of minor papillar adenoma associated with pancreas divisum. *World J Gastroenterol* 2009; 15: 1138–1140
- [11] Seifert E, Schulte F, Stolte M. Adenoma and carcinoma of the duodenum and papilla of Vater: a clinicopathologic study. *Am J Gastroenterol* 1992; 87: 37–42
- [12] Kawashima Y, Ogawa M, Yamaji Y et al. A case of endoscopic mucosal resection of carcinoma in adenoma at the minor duodenal papilla. *Case Rep Oncology* 2019; 12: 354–363
- [13] Cotton PB, Lehman G, Vennes J et al. Endoscopic sphincterotomy complications and their management: an attempt at consensus. *Gastrointest Endosc* 1991; 37: 383–393
- [14] Vanbiervliet G, Strijker M, Arvanitakis M et al. Endoscopic management of ampullary tumors: European Society of Gastrointestinal Endoscopy (ESGE) Guideline. *Endoscopy* 2021; 53: 429–448
- [15] Pilonis ND, Januszewicz W, di Pietro M. Confocal laser endomicroscopy in gastro-intestinal endoscopy: technical aspects and clinical applications. *Translat Gastroenterol Hepatol* 2022; 7: 7
- [16] Pittayanon R, Rerknimitr R, Imraporn B et al. Diagnostic values of dual focus narrow band imaging and probe-based confocal laser endomicroscopy in FAP-related duodenal adenoma. *Endosc Int Open* 2015; 03: E450–E455
- [17] Tanisaka Y, Ryozaawa S, Nonaka K et al. Confocal laser endomicroscopic finding of lymphoma of the duodenal papilla. *VideoGIE* 2018; 3: 247–248