

# What size cutoff level should be used to implement optical polyp diagnosis?

## Authors

Mahsa Taghiakbari<sup>1,2</sup>, Heiko Pohl<sup>3,4</sup>, Roupen Djinbajian<sup>2,5</sup> , Joseph C. Anderson<sup>3,4</sup>, Danny Metellus<sup>2,5</sup>, Alan N. Barkun<sup>6</sup>, Mickael Bouin<sup>2,7</sup>, Daniel von Renteln<sup>2,7</sup> 

## Institutions

- 1 University of Montreal, Montreal, Quebec, Canada
- 2 University of Montreal Hospital Research Center (CRCHUM), Montreal, Quebec, Canada
- 3 Dartmouth Geisel School of Medicine, Hanover, New Hampshire, United States
- 4 VA Medical Center, Whiter River Junction, Vermont, United States
- 5 Division of Internal Medicine, University of Montreal Hospital Center (CHUM), Montreal, Quebec, Canada
- 6 Division of Gastroenterology, McGill University Health Center, McGill University, Montreal, Quebec, Canada
- 7 Division of Gastroenterology, University of Montreal Hospital Center (CHUM), Montreal, Quebec, Canada

submitted 5.7.2021

accepted after revision 6.4.2022

published online 3.6.2022

## Bibliography

Endoscopy 2022; 54: 1182–1190

DOI 10.1055/a-1843-9535

ISSN 0013-726X

© 2022. Thieme. All rights reserved.

Georg Thieme Verlag KG, Rüdigerstraße 14, 70469 Stuttgart, Germany

 Tables 1 s–7 s, Fig. 1 s

Supplementary material is available under <https://doi.org/10.1055/a-1843-9535>

## Corresponding author

Mahsa Taghiakbari, MD, MPH, Department of Medicine, Division of Gastroenterology, Montreal University Hospital (CHUM) and Montreal University Hospital Research Center (CRCHUM), 900 Rue Saint-Denis, Montréal, QC H2X 0A9, Canada  
mahtakbar@gmail.com

## ABSTRACT

**Background** The risk of advanced pathology increases with polyp size, as does the potential for mismanagement when optical diagnosis is used. This study aimed to evaluate the proportion of patients who would be assigned inadequate surveillance intervals when different size cutoffs are adopted for use of optical diagnosis.

**Methods** In a post hoc analysis of three prospective studies, the use of optical diagnosis was evaluated for three polyp size groups: 1–3, 1–5, and 1–10 mm. The primary outcome was the proportion of patients in whom advanced adenomas were found and optical diagnosis resulted in delayed surveillance. Secondary outcomes included agreements between surveillance intervals based on high confidence optical diagnosis and pathology outcomes, reduction in histopathological examinations, and proportion of patients who could receive an immediate surveillance recommendation.

**Results** We included 3374 patients (7291 polyps  $\leq 10$  mm) undergoing complete colonoscopies (median age 66.0 years, 75.2% male, 29.6% for screening). The percentage of patients with advanced adenomas and either 2- or 7-year delayed surveillance intervals ( $n = 79$ ) was 3.8%, 15.2%, and 25.3% for size cutoffs of 1–3, 1–5, and 1–10 mm polyps, respectively ( $P < 0.001$ ). Surveillance interval agreements between pathology and optical diagnosis for the three groups were 97.2%, 95.5%, and 94.2%, respectively. Total reductions in pathology examinations for the three groups were 33.5%, 62.3%, and 78.2%, respectively.

**Conclusion** A 3-mm cutoff for clinical implementation of optical diagnosis resulted in a very low risk of delayed management of advanced neoplasia while showing high surveillance interval agreement with pathology and a one-third reduction in overall requirement for pathology examinations.

## Introduction

Small and diminutive colorectal polyps are the most common findings during colonoscopies [1, 2]. Sending such polyps routinely for histopathology evaluation is costly and can likely be replaced by optical diagnosis [1, 3]. However, current modalities for optical diagnosis cannot reliably distinguish between low and high risk dysplasia or provide an accurate prediction of sessile serrated lesions (SSL) [2, 4–6]. Thus, patients with advanced colorectal neoplasia might be at risk of inappropriate management and potential surveillance interval delays when undergoing optical diagnosis. As the risk of colorectal polyps harboring advanced pathology increases with size, a prudent implementation of optical diagnosis might ensure the safety of patient management while confidently introducing optical diagnosis into routine clinical practice. Currently, optical diagnosis is typically used for diminutive ( $\leq 5$  mm) colorectal polyps [7–10], although some authors have suggested expanding its application to polyps up to 10 mm [11]. It has even been suggested that pathology cannot be regarded as the reference standard for diagnosing polyps  $\leq 3$  mm, especially when a high confidence optical diagnosis identifies an adenoma [12]. To date, no study has evaluated the impact of different size cutoffs on the appropriate management of patients undergoing optical diagnosis. We hypothesized that a lower polyp size cutoff (e.g. 1–3 mm) would be associated with a lower risk of misclassifying advanced neoplasia or even cancer when using optical diagnosis. The aim of this study was thus to evaluate how the application of different cutoffs (1–3 mm, 1–5 mm, 1–10 mm) would affect the safety and efficacy of optical diagnosis.

## Methods

### Study design and patients

This study was a post hoc analysis of data from three prospective single-center studies (two centers, 22 staff endoscopists; see **Table 1s** in the online-only Supplementary Material), in which all patients underwent optical diagnosis for all polyps  $\leq 10$  mm found in the study cohorts [13, 14]. The study population included patients aged 45–80 years undergoing complete elective colonoscopies at the Montréal University Hospital Center (CHUM) [13, 14] and VA Medical Center White River Junction (Vermont, USA). Exclusion criteria were known inflammatory bowel disease, active colitis, coagulopathy, familial polyposis syndrome, poor general health (American Society of Anesthesiologists class  $>3$ ), and missing or unclear data on demographic or colonoscopy characteristics. Study outcomes are reported by following the Standards for Reporting Diagnostic accuracy studies (STARD) recommendations [15]. Each study was approved by the institutional research board (IRB numbers: NORD study: 16.367; OPTIVISTA study: 17.135; VA study: 921356) and was registered at ClinicalTrials.gov (NCT04032912 and NCT03515343, respectively) for CHUM.

### Study procedures

Patients underwent standard bowel preparation. Participating endoscopists included board-certified gastroenterologists and

fellows with various levels of expertise in optical diagnosis. During colonoscopies, endoscopists optically evaluated polyps  $\leq 10$  mm using different image-enhanced endoscopy equipment: Optivista (1 and 2 Optivista Enhanced [OE] settings), I-SCAN (1, 2, and 3 settings) (both Pentax Medical, Tokyo, Japan) [13, 14, 16], and narrow-band imaging (NBI; VA study). Polyps were then classified based on the validated NBI International Colorectal Endoscopic (NICE) classification system as hyperplastic or adenoma in both centers. An additional assessment was performed in polyps classified as hyperplastic to evaluate for the presence of serrated features, according to the Sano classification [16], and any such polyps were defined as SSLs [16]. For each polyp, endoscopists also recorded whether the optical diagnosis was made with high or low confidence. A high level of confidence in optical diagnosis was assigned when a polyp had endoscopic color, surface, and/or vessel features associated with a specific type of histology in the NICE classification [17]. Common colonoscopy quality metrics such as cecal intubation and quality of bowel preparation, as well as size, location, and morphological characteristics of each polyp based on the Paris classification [18], were also documented. For analysis, polyps were stratified into three groups according to the endoscopic size: 1–3 mm, 1–5 mm, and 1–10 mm.

### Definition of advanced polyp histology

All 1–10 mm polyps with tubulovillous or villous histology, traditional serrated adenomas, any polyp histology with high grade dysplasia, or cancer were considered as having advanced pathology [5]. As the latest US Multi-Society Task Force on Colorectal Cancer (USMSTF) guideline recommends a shorter surveillance interval for patients with traditional serrated adenoma owing to the potential for malignancy, we considered traditional serrated adenoma as advanced adenoma [5, 19].

Histopathological assessment was available for all resected polyps. Qualified pathologists assessed polyp specimens according to current and institutional practice standards. Polyps were categorized as neoplastic (including adenomatous or SSLs, large hyperplastic polyps  $\geq 10$  mm, SSL with dysplasia) or non-neoplastic (including hyperplastic polyps, inflammatory or mucosal prolapse, etc.) [20].

### Surveillance interval calculation

Postcolonoscopy surveillance intervals based on optical diagnosis were determined for each patient based on a combination of the high confidence optical pathology prediction, the histopathology results of polyps optically diagnosed with low confidence, and the histopathology outcomes of all other concomitant polyps. Poor bowel preparation and positive family history of colorectal cancer were considered in final decisions on surveillance intervals. The reference standard surveillance interval was based on histopathological outcomes using the most recent (2020) USMSTF guideline [5]. Therefore, four different possible surveillance intervals were assigned to the patients: one based on actual histopathology outcomes, and three based on high confidence optical pathology prediction using cutoffs of 1–3 mm, 1–5 mm, and 1–10 mm coupled with the histopa-

thology reports of polyps with low confidence optical diagnosis.

## Study outcomes

The primary outcome was the proportion of patients in whom a polyp with advanced pathology undergoing optical diagnosis was misdiagnosed as a nonadvanced or non-neoplastic polyp, resulting in an inappropriately delayed follow-up of either 2 or 7 years for those patients. This outcome was determined for each of the polyp size groups (1–3 mm, 1–5 mm, and 1–10 mm) in an attempt to determine the optimal size threshold for safe implementation of optical diagnosis. Thus, we calculated 1) the proportion of polyps with advanced pathology in each size group, and 2) the proportion of patients with advanced polyps who would have been assigned a delayed follow-up based on the NICE classification system.

Secondary outcomes included the agreements between surveillance intervals based on the optical diagnosis of polyps of the three size groups and the pathology-based recommendations. Other secondary outcomes were the diagnostic properties of optical prediction for neoplastic rectosigmoid polyps, including accuracy, sensitivity, specificity, positive predictive value, and negative predictive value (NPV). The proportion of histopathology examinations that could be avoided and the proportion of patients who could receive an immediate surveillance recommendation were also calculated for each of the three size cutoffs.

## Statistical analyses

Continuous variables are presented as mean (SD) or median (range), as appropriate. Categorical variables are presented as proportions with 95% CIs.

The diagnostic characteristics of optical diagnosis were calculated by sub-stratifying polyps into hyperplastic polyps and adenomas (excluding SSLs) within each of the three polyp size groups. The reduction in pathology examinations was calculated for: 1) the reference standard – the number of polyps sent for histopathology evaluation divided by the total number of polyps; 2) optical diagnosis – the number of polyps 1–3 mm, 1–5 mm, and 1–10 mm, respectively, optically diagnosed with high confidence divided by the total number of polyps. The proportion of patients who could have received immediate surveillance interval recommendations was calculated for: 1) reference standard – the total number of patients without polyp identification during colonoscopy (normal colonoscopy) divided by the total number of patients; 2) optical diagnosis – the sum of all patients without any polyps (normal colonoscopy) and patients with only polyps 1–3 mm, 1–5 mm, and 1–10 mm, respectively, optically diagnosed with high confidence divided by the total number of patients.

Comparing 1–3 mm polyps with 4–5 mm polyps would introduce bias related to the size estimation by the endoscopists and histology determination by the pathologists. Therefore, the polyp size groups partially overlapped, and observations from individuals tended to be correlated. To compare the proportions of outcomes of interest using different size cutoffs, we used generalized linear models (i. e. binomial regressions)

and a logit link to analyze all correlated errors and population-averaged estimates. To allow for within-subject observations that are equally correlated, we used an exchangeable working correlation matrix with robust standard errors. Hence, the separate regression models were fitted for our primary outcomes. The complete statistical methods are described in **Table 2s**. The surveillance interval agreements between optical diagnosis for different polyp size cutoffs and pathology were calculated for both the whole cohort of patients and the cohort of patients for whom optical diagnosis could have changed the recommended next colonoscopy (e. g. excluding patients with normal colonoscopy, polyps  $\geq 10$  mm in size, and poor bowel preparation). The agreements between the surveillance intervals were compared between the different size cutoffs using Cohens Kappa–Fleiss adjusted standard error [21,22]. Moreover, the proportions of correct and incorrect (shorter or longer) surveillance intervals using optical diagnosis were calculated for three size groups.

All point estimates are presented with 95% CIs, and a *P* value of  $<0.05$  was considered to indicate statistical significance. SPSS version 26.0 (IBM Corp., Armonk, New York, USA) and MedCalc Version 19.4 (MedCalc Software, Ostend, Belgium) were used for analyses.

## Results

### Patient, procedure, and polyp characteristics

During the study period, 3921 patients underwent colonoscopy, and 3374 met the inclusion criteria and were included in the final analysis (**Fig. 1s**). The median age of patients was 66.0 years, and 75.2% were male. Nearly a third (29.6%) of colonoscopies were performed for screening. Details of patient and colonoscopy characteristics are presented in **Table 1**. During colonoscopies, 5906 polyps 1–5 mm in size and 1385 polyps 6–10 mm in size (total 1–10 mm polyps = 7291) were detected. Among polyps sized 1–3 mm, 1–5 mm, and 1–10 mm with optical polyp evaluation, 2588/3212 (79.0%), 4813/5783 (81.5%), and 6033/7142 (82.7%), respectively, were diagnosed with high confidence. Polyp characteristics are presented in **Table 2**.

### Proportion of polyps with advanced pathology in the respective groups

Among polyps sized 1–3 mm, 1–5 mm, and 1–10 mm, 0.5%, 0.6%, and 1.2% of polyps, respectively, were found to have advanced pathology (**Table 2**). Significant differences were noted in advanced histopathology proportions when comparing the 1–3 mm group vs. 1–10 mm group and 1–5 mm vs. 1–10 mm groups (**Table 2s, Table 3s**).

### Primary outcome

When using optical diagnosis for polyps 1–3 mm, 1–5 mm, and 1–10 mm, the number of patients with advanced adenomas undergoing optical polyp diagnosis ( $n=79$ ) resulting in delayed surveillances of either 2 or 7 years would have been 3 (3.8%), 12 (15.2%), and 20 (25.3%), respectively (**Table 3**). For both surveillance delay durations, the differences between polyps

**► Table 1** Demographic and clinical characteristics of patients.

Total number of patients, n	3374 (100)
Age, median (range), years	66.0 (45–80)
Male sex, n (%)	2537 (75.2)
ASA class, n (%)	
▪ 1	792 (23.5)
▪ 2	1871 (55.5)
▪ 3	711 (21.1)
Antithrombotic medication use (Yes) <sup>1</sup> , n (%)	909 (26.9)
Family history of CRC in first-degree relatives (Yes) <sup>2</sup> , n (%)	397 (11.8)
<b>Colonoscopy characteristics<sup>3</sup></b>	
Colonoscopy indications, n (%)	
▪ Screening	998 (29.6)
▪ FIT positive	144 (4.3)
▪ Adenoma surveillance	1288 (38.2)
▪ CRC surveillance	76 (2.3)
▪ Anemia/bleeding	384 (11.4)
▪ Diarrhea	86 (2.5)
▪ Other <sup>4</sup>	396 (11.7)
Cecal intubation during colonoscopy (Yes) <sup>5</sup> , n (%)	3260 (96.6)
Boston Bowel Preparation Scale $\geq 6$ <sup>6</sup> , n (%)	3104 (92.0)
<b>Number of patients with polyps, n (%)</b>	
▪ No polyp	822 (24.4)
▪ Polyp 1–3 mm	1684 (49.9)
▪ Polyp 1–5 mm	2283 (67.7)
▪ Polyp 1–10 mm	2477 (73.4)
ASA, American Society of Anesthesiologists; FIT, fecal immunochemical test; CRC, colorectal cancer.	
<sup>1</sup> Missing = 9 (0.3%).	
<sup>2</sup> Missing = 1936 (57.4%), information on the family history of CRC was only available for patients from CHUM center.	
<sup>3</sup> Missing = 2 (0.06%).	
<sup>4</sup> Other indications included surveillance due to family history of CRC, pre- and post-graft or organ donation, change in bowel habits such as constipation, post-polypectomy surveillance, screening for inflammatory diseases, ruling out diverticulitis, abdominal pain, celiac disease follow-up.	
<sup>5</sup> Missing = 2 (0.06%).	
<sup>6</sup> Missing = 11 (0.3%).	

sized 1–3 mm, 1–5 mm, and 1–10 mm, were statistically significant (**Table 2s**).

In patients for whom the optical diagnosis of 1–3 mm polyps resulted in either a 2- or 7-year delay compared with the surveillance intervals calculated based on the pathology results (n=3), 33.3% (1/3) and 66.7% (2/3) of delays were due to misdiagnosis of an adenoma and villous component, respectively.

In the patients for whom the optical diagnosis of 1–5 mm polyps resulted in either a 2- or 7-year delay compared with

the surveillance intervals calculated based on the pathology results (n=12), 16.7% (2/12) and 83.3% (10/12) of delays were due to misdiagnosis of an adenoma and villous component, respectively.

In the patients for whom the optical diagnosis of 1–10 mm polyps resulted in either a 2- or 7-year delay compared with the surveillance intervals calculated based on the pathology results (n=20), 10% (2/20) and 90% (18/20) of delays were due to misdiagnosis of an adenoma and villous component, respectively.

### Surveillance interval agreements

Surveillance interval agreements are presented in **► Fig. 1**. In the whole cohort of patients (n=3374), the agreement between surveillance intervals based on the high confidence optical diagnosis of polyps 1–3 mm and pathology-based recommendations was 97.2% (95%CI 0.97–0.98). Moreover, the agreements between high confidence optical diagnosis with polyp size cutoffs of 1–5 mm and 1–10 mm and pathology-based recommendations were 95.5% (95%CI 0.95–0.96) and 94.2% (95%CI 0.93–0.95), respectively (all  $P < 0.001$ ) (**► Fig. 1**).

In the cohort in which patients with normal colonoscopy, polyps >10 mm, and poor bowel preparation were excluded, the agreements between surveillance intervals based on the high confidence optical diagnosis of polyps 1–3 mm, 1–5 mm, and 1–10 mm and pathology-based recommendations were 96.2% (95%CI 0.95–0.97), 93.6% (95%CI 0.92–0.95), and 92.1% (95%CI 0.91–0.93), respectively. The agreements between polyps 1–3 mm and 1–5 mm, between 1–3 mm and 1–10 mm, and between 1–5 mm and 1–10 mm were different ( $P < 0.001$ ).

The details of surveillance interval agreements are presented in **Table 4s** and **Table 5s**.

### NPV for neoplastic rectosigmoid polyps

Overall, 16.4%, 73.3%, and 8.2% of polyps 1–10 mm in size were optically predicted as hyperplastic (NICE 1), adenoma (NICE 2), and SSLs, respectively (**Table 6s**).

The NPV of optical diagnosis for diagnosing rectosigmoid neoplastic polyps was as follows: 1–3 mm: 81.4% (95%CI 78.0–84.4); 1–5 mm: 80.9% (95%CI 78.0–83.6); 1–10 mm: 80.6% (95%CI 77.7–83.3) (**► Table 4**). Moreover, the accuracy of optical diagnosis for distinguishing neoplastic from hyperplastic polyps (regardless of polyp location) was only moderate for all three polyp size groups (1–3 mm: 78.3% [95%CI 76.7–79.9]; 1–5 mm: 80.3% [95%CI 79.2–81.4]; 1–10 mm: 81.0% [95%CI 80.0–82.0]) (**► Table 4**).

### Reduction in histopathology examinations and allocation of immediate surveillance intervals

Use of optical diagnosis would have resulted in a 33.5% (95%CI 0.32–0.35), 62.3% (95%CI 0.61–0.63), and 78.2% (95%CI 0.77–0.80) reduction in histopathology examinations for polyps of 1–3 mm, 1–5 mm, and 1–10 mm, respectively (**► Fig. 2**). Furthermore, optical diagnosis could have allowed 41.0% (95%CI 0.39–0.43), 58.2% (95%CI 0.56–0.60), and 73.3% (95%CI 0.72–0.75) of patients, respectively, to be given immedi-

► **Table 2** Characteristics of the detected polyps stratified by size.

Clinicopathological characteristics of polyps	Polyp size cutoff		
	1–3 mm	1–5 mm	1–10 mm
Number of polyps, n/N (%)	3278/7655 (42.8)	5906/7655 (77.2)	7291/7655 (95.2)
<b>Anatomical location, n (%)</b>			
▪ From cecum to descending colon	2432 (74.2)	4448 (75.3) <sup>1</sup>	5472 (75.1) <sup>2</sup>
▪ Rectosigmoid colon	846 (25.8)	1458 (24.7)	1819 (24.9)
Polyp size, mean (SD), mm	2.4 (0.6)	3.4 (1.2)	4.2 (2.0)
<b>Histopathology results, n (%)</b>			
▪ Hyperplastic polyps	738 (22.5)	1259 (21.3)	1453 (19.9)
▪ Tubular adenoma	1997 (60.9)	3718 (63.0)	4648 (63.7)
▪ Tubulovillous adenoma	11 (0.3)	24 (0.4)	64 (0.9)
▪ Villous adenoma	2 (0.1)	5 (0.1)	8 (0.1)
▪ Traditional serrated adenoma	3 (0.1)	4 (0.1)	10 (0.1)
▪ Sessile serrated adenoma/polyp	70 (2.1)	200 (3.4)	343 (4.7)
▪ High grade dysplasia	–	1 (0.02)	2 (0.03)
▪ Other benign lesions	457 (13.9)	695 (11.8)	763 (10.5)
Polyps with advanced pathology <sup>3</sup> , n (%)	16 (0.5)	34 (0.6)	84 (1.2)
Serrated lesions <sup>4</sup> , n (%)	73 (2.2)	204 (3.5)	353 (4.8)

<sup>1</sup> Missing = 3 (0.1 %).  
<sup>2</sup> Missing = 5 (0.1 %).  
<sup>3</sup> Including tubulovillous adenoma and villous adenoma, traditional serrated adenoma, polyp with high grade dysplasia and cancer.  
<sup>4</sup> Including sessile serrated adenoma, traditional serrated adenoma.

► **Table 3** Number of patients with surveillance delays for 79 patients with advanced pathology.

Patients with advanced polyps	No delay, n (%) <sup>1</sup>	2-year delay, n (%) <sup>1</sup>	7-year delay, n (%) <sup>1</sup>	Total with delay, n (%) [95%CI]
1–3 mm (n = 14) <sup>2</sup>	11 (13.9)	0 (0)	3 (3.8)	3 (3.8) [0.008–0.1]
1–5 mm (n = 32) <sup>3</sup>	20 (25.3)	2 (2.5)	10 (12.7)	12 (15.2) [0.1–0.2]
1–10 mm (n = 79) <sup>4</sup>	59 (74.6)	3 (3.8)	17 (21.5)	20 (25.3) [0.2–0.4]

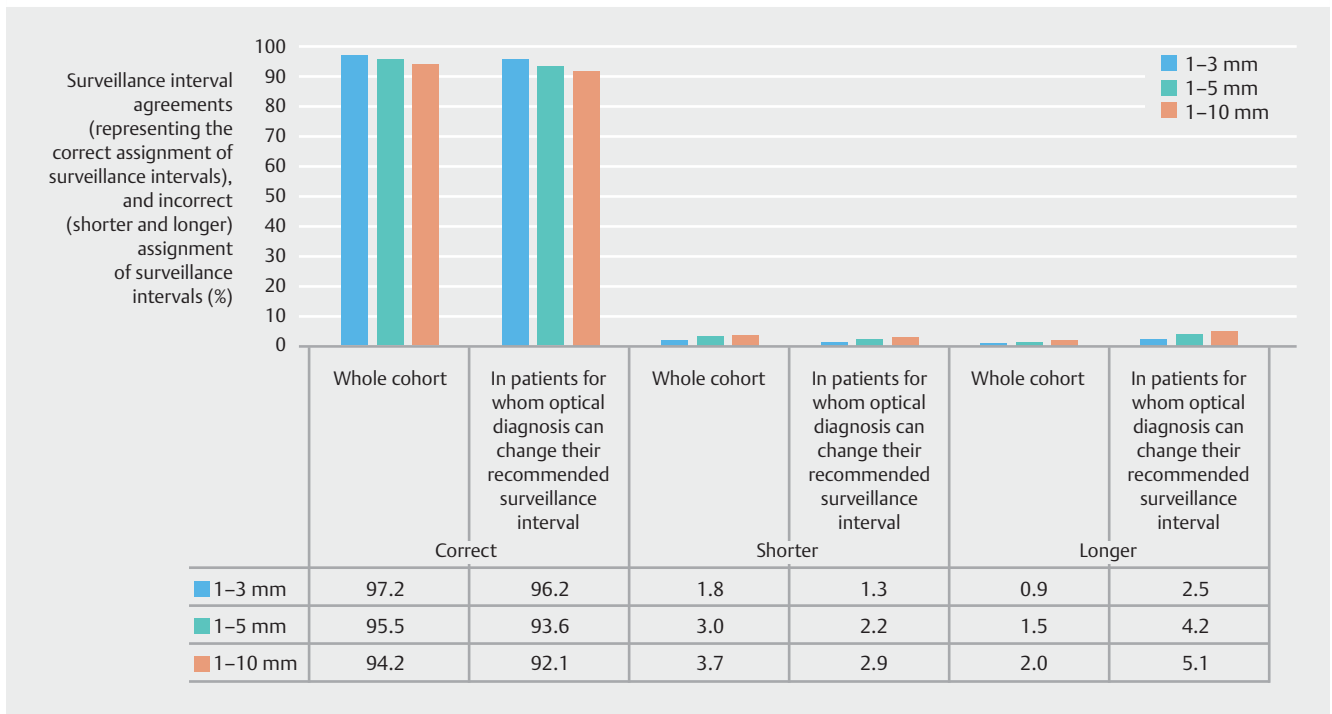
<sup>1</sup> Compared with surveillance intervals based on pathology results.  
<sup>2</sup> Missing = 2 (2.5 %).  
<sup>3</sup> Missing = 4 (5.1 %).  
<sup>4</sup> Missing = 8 (10.1 %).

ate, same-day surveillance interval recommendations. These proportions were greater than the corresponding proportions if the recommendations were followed based on pathology outcomes ( $P < 0.001$  for all) (Table 2s).

## Discussion

In this study, which included 3374 patients with 7655 polyps undergoing optical diagnosis, we found that when limiting optical diagnosis to polyps sized 1–3 mm, the proportion of delayed follow-up assignments in patients who had polyps with advanced pathology was exceedingly low. Only a few

polyps with serrated or villous pathology were found in the 1–3 mm group ( $n = 73$ ; 2.2%). If the optical diagnosis is limited to 1–3 mm polyps, the proportion of delayed surveillance intervals for patients with advanced neoplastic polyps is lower compared with using optical diagnosis for polyps up to 5 mm or up to 10 mm. Using optical diagnosis for 1–3 mm polyps exclusively resulted in only 0.5% of advanced neoplastic polyps and only three patients (3.8%) with a 7-year delay in the next surveillance colonoscopy. In contrast, when 4–10 mm polyps were included in the optical evaluation, 1.2% of polyps had advanced pathology, and 3 (3.8%) and 17 (21.5) patients had a 2-year and 7-year delay in their next surveillance colonoscopy, respec-



**Fig. 1** The percentage of surveillance interval agreement (correct assignment of surveillance intervals) between histopathology and optical diagnosis in all patients with valid determination of surveillance intervals, and in patients for whom optical diagnosis could have affected their next recommended surveillance intervals, using the Narrow-band imaging International Colorectal Endoscopic (NICE) classification system and different cutoff points for size.

tively. As the proportion of advanced pathology increases with polyp size ( $P < 0.001$ ), so does the rate of inappropriately delayed surveillance intervals.

Notably, we considered adenomas with a villous component as adenomas with advanced pathology. However, some studies have found no association between villous adenomas and an increased risk of neoplasia [23, 24]. The latest European Society of Gastrointestinal Endoscopy guidelines [7] do not consider polyps with a villous component as “advanced” polyps. However, the 2020 USMSTF guidelines on which we based our study still consider these polyps as advanced. When villous polyps are excluded from advanced pathology criteria, the surveillance delays for 11 patients with advanced pathology were 9.1%, 18.2%, and 18.2% for 3-, 5-, and 10-mm cutoffs, respectively.

It is critically important that colorectal adenocarcinomas are not inappropriately discarded when using the “resect and discard” strategy. It is often recommended to use NICE 3 classification for flat-depressed or ulcerated morphology (Paris IIc and III) to potentially identify adenocarcinomas among small polyps. A recent analysis by Vleugels et al. evaluated optical diagnosis for polyps up to 10 mm and found that it would have resulted in five T1 cancers being discarded without histopathology evaluation and appropriate management [11]. In this study, the prevalence of T1 cancers among polyps 1–10 mm was 0.33% [11]. All cancers had Ip or Is morphology and were often judged through optical diagnosis as NICE 2 adenomas [11]. Thus, in this study, as in our current cohort where no cancer was recorded, no correlation between NICE 3 and Paris IIc/III

morphology was found for the diagnosis of adenocarcinoma. In our cohort, out of 5346 polyps predicted to be adenomas in the 1–10 mm polyps, 763 (14.3%) were evaluated to be hyperplastic or SSL during histopathology examination. We did not encounter any adenocarcinoma among the polyps sized 1–10 mm. Thus, the best approach seems to be using a smaller cutoff to limit the risk of mismanaging advanced colorectal neoplasia within a “resect and discard” strategy.

Starting optical diagnosis at the low threshold of 1–3 mm might be feasible and ensure a cost-effective and safe approach to implementing the “resect and discard” strategy in routine clinical practice. Although the highest reduction in pathology examinations was naturally found when optical diagnosis was expanded to include 1–10 mm polyps (78.2%), limiting optical diagnosis to 1–3 mm polyps significantly reduced the need for pathology examinations (33.5%), as well as increasing the safety profile compared with larger size cutoffs. Furthermore, a significant proportion of patients could have received an immediate surveillance recommendation, even when limiting optical diagnosis to 1–3 mm polyps (73.3% in the 1–10 mm group vs. 41.0% in the 1–3 mm group).

The results of our study support the use of optical diagnosis for 1–3 mm polyps especially in light of recent evidence indicating the unreliability of histopathology assessment for this polyp size group [25]. A recent study comparing optical diagnosis of 1–3 mm polyps with histopathology outcomes found that about 15% of polyps recorded as adenoma by optical diagnosis were reported as normal mucosa by pathology experts [25].

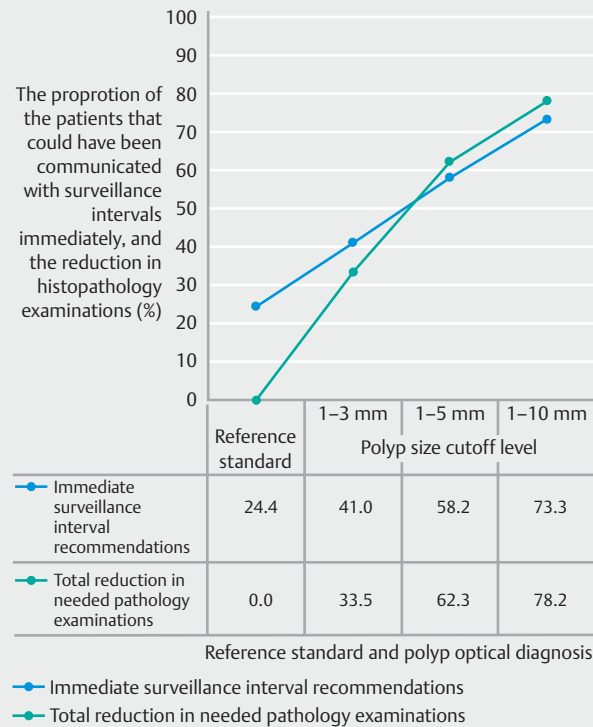
**► Table 4** Diagnostic performance of optical diagnosis\* for differentiating hyperplastic from adenomatous polyps in patients with at least one polyp 1–3 mm, 1–5 mm, 1–10 mm in size, respectively.

Polyp size cut-off	Diagnostic properties (adenoma vs. hyperplastic)			
	In rectosigmoid polyps		In all polyps	
	%	95%CI	%	95%CI
<b>1–3 mm</b>				
▪ Sensitivity	73.8	68.0–79.0	88.0	86.5–89.4
▪ Specificity	66.9	61.4–70.3	52.3	48.6–55.9
▪ PPV	55.4	51.8–59.0	83.3	82.2–84.3
▪ NPV	81.4	78.0–84.4	61.7	58.4–64.9
▪ Accuracy	68.8	65.2–72.2	78.3	76.7–79.9
<b>1–5 mm</b>				
▪ Sensitivity	78.9	75.1–82.4	91.4	90.5–92.3
▪ Specificity	59.6	56.0–63.2	47.4	44.6–50.2
▪ PPV	56.5	54.1–58.9	83.8	83.0–84.5
▪ NPV	80.9	78.0–83.6	65.0	62.2–67.7
▪ Accuracy	67.3	64.6–69.9	80.3	79.2–81.4
<b>1–10 mm</b>				
▪ Sensitivity	83.8	80.8–86.4	92.6	91.8–93.4
▪ Specificity	54.9	51.5–58.3	43.3	40.7–45.9
▪ PPV	60.1	58.2–62.0	84.1	83.5–84.7
▪ NPV	80.6	77.7–83.3	64.4	61.7–67.1
▪ Accuracy	67.8	65.5–70.1	81.0	80.0–82.0

PPV, positive predictive value; NPV, negative predictive value; NICE, Narrow-band imaging International Colorectal Endoscopic classification.  
\* Optical diagnosis using the NICE classification system and image-enhanced endoscopy. Sessile serrated polyps/adenomas were not considered in the analysis.

Another study reported a similar discrepancy, with 28.9% of 1–3 mm polyps having mismatched optical and pathological diagnoses [12]. These findings suggest that high confidence optical diagnosis is a safe method for accurate adenoma identification for 1–3 mm polyps, given the potential for pathology evaluations to erroneously report adenomatous polyps as normal mucosa. Furthermore, multiple recent studies have identified interrater variability between pathologists, or that expert high confidence diagnoses of 1–3 mm polyps matched interpretation assisted by artificial intelligence (AI) but not the pathology results. Polyps previously diagnosed as hyperplastic might be reclassified as adenoma or sessile serrated adenomas after slide reassessment by another pathologist [11, 26–29].

The appropriate size cutoff for optical diagnosis is also relevant for future developments in AI-assisted optical diagnosis. AI-assisted optical diagnosis has improved detection with promising accuracy [30, 31]. Despite recent research efforts to im-



**► Fig. 2** Reduction in histopathology examinations and proportion of patients who could have received immediate surveillance interval recommendations.

prove the diagnostic precision of AI models, similarly to regular optical diagnosis, it cannot distinguish between different adenoma entities such as high vs. low grade dysplasia, or reliably identify serrated or villous pathology. Limiting optical diagnosis to 1–3 mm polyps will help decrease the risk of inappropriate management of advanced adenomas, regardless of the optical diagnosis modality used.

Some strengths and limitations of this study should be mentioned. To our knowledge, this is the first study to evaluate polyp size cutoffs for implementation of optical diagnosis. We included the data from two academic centers with variable endoscopist experience in optical diagnosis, reflecting real-world practice. Thus, it is possible to cautiously generalize the results to community practices. Study limitations include the post hoc nature of the analysis, and the fact that polyp size was based on endoscopists' measurements. Endoscopists tend to overestimate polyp size compared with the size measured during pathological examination [32, 33]. However, the method reflects general clinical practice and will remain a limitation until better techniques are widely available to improve real-time polyp measurement during colonoscopy. Additionally, the NICE classification system does not accurately distinguish SSLs from hyperplastic polyps, resulting in misclassification of some polyps. Other optical diagnosis classification systems were not used because of the multiplicity of centers. The NICE classification has not been validated for blue-light imaging; however, there was no decrease in diagnostic performance

when compared with other optical imaging techniques [34]. One major limitation is the biased calculation of surveillance intervals due to the lack of data on the family history of colorectal cancer for patients from the VA Medical Center. Consistent with other studies [11,35], our study did not reach the American Society for Gastrointestinal Endoscopy Preservation and Incorporation of Valuable endoscopic Innovations (PIVI) benchmark of an NPV of  $\geq 90\%$  to support the use of a “diagnose and leave” strategy for rectosigmoid polyps  $\leq 10$  mm [9]. In a sub-analysis of per-endoscopist NPVs, only six expert endoscopists reached the recommended PIVI benchmark for implementation of this strategy in each size group (Table 7s).

In conclusion, this study showed that limiting optical diagnosis to polyps sized 1–3 mm resulted in an excellent safety profile with a very low risk of inappropriate management of advanced adenomas, which makes routine clinical implementation of the “resect and discard” strategy feasible. Implementing a 3-mm cutoff could be a starting point for endoscopists to feel comfortable with the “resect and discard” strategy, with the potential of implementing a 5-mm cutoff, once optical diagnosis becomes more popular, and endoscopists become more comfortable with its use.

## Competing interests

Daniel von Renteln is supported by the “Fonds de Recherche du Québec Santé” career development award and has received research funding from ERBE, Ventage, Pendopharm, and Pentax, and is also a consultant for Boston Scientific and Pendopharm. The remaining authors declare that they have no conflict of interest. The findings, statements, and views expressed are those of the authors and do not represent the views of the Department of Veterans Affairs or the United States Government.

## References

- [1] Gupta N, Bansal A, Rao D et al. Prevalence of advanced histological features in diminutive and small colon polyps. *Gastrointest Endosc* 2012; 75: 1022–1030
- [2] Lieberman D, Moravec M, Holub J et al. Polyp size and advanced histology in patients undergoing colonoscopy screening: implications for CT colonography. *Gastroenterology* 2008; 135: 1100–1105
- [3] Kessler WR, Imperiale TF, Klein RW et al. A quantitative assessment of the risks and cost savings of forgoing histologic examination of diminutive polyps. *Endoscopy* 2011; 43: 683–691
- [4] Fan C, Younis A, Bookhout CE et al. Management of serrated polyps of the colon. *Curr Treat Options Gastroenterol* 2018; 16: 182–202
- [5] Gupta S, Lieberman D, Anderson JC et al. Recommendations for follow-up after colonoscopy and polypectomy: a consensus update by the US Multi-Society Task Force on Colorectal Cancer. *Gastroenterology* 2020; 158: 1131–1153
- [6] Chandran S, Parker F, Lontos S et al. Can we ease the financial burden of colonoscopy? Using real-time endoscopic assessment of polyp histology to predict surveillance intervals *Intern Med J* 2015; 45: 1293–1299
- [7] Hassan C, Antonelli G, Dumonceau J-M et al. Post-polypectomy colonoscopy surveillance: European Society of Gastrointestinal Endoscopy (ESGE) Guideline – Update 2020. *Endoscopy* 2020; 52: 687–700
- [8] Rutter MD, East J, Rees CJ et al. British Society of Gastroenterology/ Association of Coloproctology of Great Britain and Ireland/Public Health England post-polypectomy and post-colorectal cancer resection surveillance guidelines. *Gut* 2020; 69: 201–223
- [9] Rex DK, Kahi C, O'Brien M et al. The American Society for Gastrointestinal Endoscopy PIVI (Preservation and Incorporation of Valuable Endoscopic Innovations) on real-time endoscopic assessment of the histology of diminutive colorectal polyps. *Gastrointest Endosc* 2011; 73: 419–422
- [10] Bisschops R, East JE, Hassan C et al. Advanced imaging for detection and differentiation of colorectal neoplasia: European Society of Gastrointestinal Endoscopy (ESGE) Guideline – Update 2019. *Endoscopy* 2019; 51: 1155–1179
- [11] Vleugels JLA, Hazewinkel Y, Dijkgraaf MGW et al. Optical diagnosis expanded to small polyps: post-hoc analysis of diagnostic performance in a prospective multicenter study. *Endoscopy* 2019; 51: 244–252
- [12] Shahidi N, Rex DK, Kaltenbach T et al. Use of endoscopic impression, artificial intelligence, and pathologist interpretation to resolve discrepancies between endoscopy and pathology analyses of diminutive colorectal polyps. *Gastroenterology* 2020; 158: 783–785
- [13] Alaoui A, Oumedjbeur K, Djinbachian R et al. A79 Clinical validation of the simple classification for optical diagnosis of diminutive and small colorectal polyps. *J Can Assoc Gastroenterol* 2020; 3: 93–94
- [14] Djinbachian R, Pohl H, Marques P et al. Sa2010 Optical diagnosis of small colorectal polyps using Optivista and iScan image enhanced endoscopy: a randomized controlled trial. *Gastrointest Endosc* 2020; 91: AB240
- [15] Bossuyt PM, Reitsma JB, Bruns DE et al. STARD 2015: an updated list of essential items for reporting diagnostic accuracy studies. *BMJ* 2015; 351: h5527
- [16] Von Renteln D, Leduc R, Bouchard S et al. A78 Comparison of the NICE, Sano, and WASP classifications for optical diagnosis of small colorectal polyps. *J Can Assoc Gastroenterol* 2020; 3: 92–93
- [17] Rex DK. Narrow-band imaging without optical magnification for histologic analysis of colorectal polyps. *Gastroenterology* 2009; 136: 1174–1181
- [18] The Paris endoscopic classification of superficial neoplastic lesions. esophagus, stomach, and colon: November 30 to December 1, 2002. *Gastrointest Endosc* 2003; 58: S3–43
- [19] Rex DK, Ahnen DJ, Baron JA et al. Serrated lesions of the colorectum: review and recommendations from an expert panel. *Am J Gastroenterol* 2012; 107: 1315–1329
- [20] Jass JR, Sobin LH, Morson BC. Histological typing of intestinal tumours. 2nd ed. Berlin, New York: Springer-Verlag; 1989
- [21] Fleiss JL, Levin B, Paik MC. Statistical methods for rates and proportions. Hoboken, NJ: John Wiley & Sons; 2013
- [22] Landis JR, Koch GGJB. The measurement of observer agreement for categorical data. *Biometrics* 1977; 33: 159–174
- [23] Bonithon-Kopp C, Piard F, Fenger C et al. Colorectal adenoma characteristics as predictors of recurrence. *Dis Colon Rectum* 2004; 47: 323–333
- [24] Saini SD, Kim HM, Schoenfeld P. Incidence of advanced adenomas at surveillance colonoscopy in patients with a personal history of colon adenomas: a meta-analysis and systematic review. *Gastrointest Endosc* 2006; 64: 614–626
- [25] Ponugoti P, Rastogi A, Kaltenbach T et al. Disagreement between high confidence endoscopic adenoma prediction and histopathological diagnosis in colonic lesions  $\leq 3$  mm in size. *Endoscopy* 2019; 51: 221–226
- [26] Schachschal G, Sehner S, Choschzick M et al. Impact of reassessment of colonic hyperplastic polyps by expert GI pathologists. *Int J Colorectal Dis* 2016; 31: 675–683



- [27] Singh H, Bay D, Ip S et al. Pathological reassessment of hyperplastic colon polyps in a city-wide pathology practice: implications for polyp surveillance recommendations. *Gastrointest Endosc* 2012; 76: 1003–1008
- [28] Anderson JC, Lisovsky M, Greene MA et al. Factors associated with classification of hyperplastic polyps as sessile serrated adenomas/polyps on morphologic review. *J Clin Gastroenterol* 2018; 52: 524–529
- [29] Baldin RKS, Anselmi Júnior RA, Azevedo M et al. Interobserver variability in histological diagnosis of serrated colorectal polyps. *J Coloproct (Rio J)* 2015; 35: 193–197
- [30] Byrne MF, Chapados N, Soudan F et al. Real-time differentiation of adenomatous and hyperplastic diminutive colorectal polyps during analysis of unaltered videos of standard colonoscopy using a deep learning model. *Gut* 2019; 68: 94–100
- [31] van der Sommen F, de Groof J, Struyvenberg M et al. Machine learning in GI endoscopy: practical guidance in how to interpret a novel field. *Gut* 2020; 69: 2035–2045
- [32] Anderson BW, Smyrk TC, Anderson KS et al. Endoscopic overestimation of colorectal polyp size. *Gastrointest Endosc* 2016; 83: 201–208
- [33] Atalaia-Martins C, Marcos P, Leal C et al. Variation between pathological measurement and endoscopically estimated size of colonic polyps. *GE Port J Gastroenterol* 2019; 26: 163–168
- [34] Yoshida N, Hisabe T, Hirose R et al. Improvement in the visibility of colorectal polyps by using blue laser imaging (with video). *Gastrointest Endosc* 2015; 82: 542–549
- [35] Sola-Vera J, Cuesta R, Uceda F et al. Accuracy for optical diagnosis of colorectal polyps in clinical practice. *Rev Esp Enferm Dig* 2015; 107: 255–261