Small-sized versus standard magnetic capsule endoscopy in adults: a two-center, double-blinded randomized controlled trial

INFOGRAPHIC

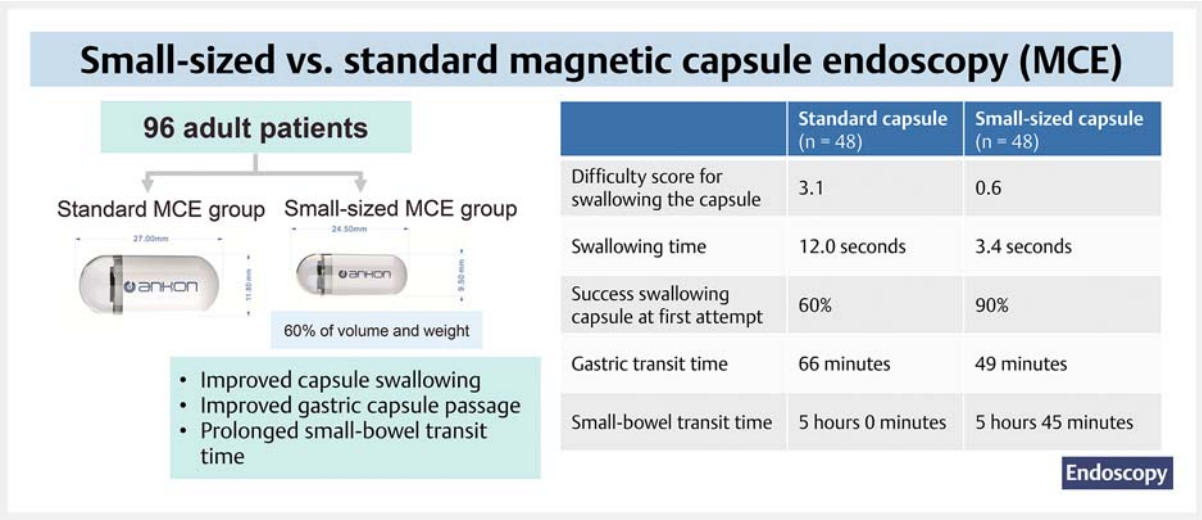

	Standard capsule (n = 48)	Small-sized capsule (n = 48)
Difficulty score for swallowing the capsule	3.1	0.6
Swallowing time	12.0 seconds	3.4 seconds
Success swallowing capsule at first attempt	60%	90%
Gastric transit time	66 minutes	49 minutes
Small-bowel transit time	5 hours 0 minutes	5 hours 45 minutes

Authors

Xi Jiang*,[1], Xiao-Ou Qiu*,[1], Zhen Li[2], Jun Pan[1], Cheng Peng[2], Xiu-Li Zuo[2], Zhuan Liao[1], Zhao-Shen Li[1]

Institutions

1 National Clinical Research Center for Digestive Diseases, Department of Gastroenterology, Changhai Hospital, Naval Medical University, Shanghai, China

2 Department of Gastroenterology, Qilu Hospital of Shandong University, Jinan, Shandong, China

submitted 20.12.2021
accepted after revision 20.5.2022
published online 12.7.2022

Bibliography

Endoscopy 2023; 55: 52–57
DOI 10.1055/a-1881-4369
ISSN 0013-726X

Georg Thieme Verlag KG, Rüdigerstraße 14, 70469 Stuttgart, Germany

Corresponding author

Zhuan Liao, MD, National Clinical Research Center for Digestive Diseases, Department of Gastroenterology, Changhai Hospital, Naval Medical University, 168 Changhai Road, Shanghai 200433, China
liaozhuan@smmu.edu.cn

Supplementary material
Supplementary material is available under https://doi.org/10.1055/a-1881-4369

Scan this QR-Code for the author commentary.

ABSTRACT

Background Certain patients experience difficulty swallowing a video capsule endoscopy (VCE) device owing to its relatively large size. The newly developed small-sized magnetically controlled capsule endoscopy (MCE) device is the smallest VCE device ever reported. We aimed to evaluate the performance of the small-sized MCE device in terms of ingestion and examination efficacy.

Methods Patients in two centers were prospectively enrolled and randomized to the small-sized or standard MCE groups. Differences in capsule ingestion difficulties, visuali-

* Joint first authors

zation of the gastrointestinal tract, and capsule transit times were compared.

Results 96 patients were enrolled (48 in each group). In the small-sized MCE group, the mean (SD) difficulty score and time to swallow the capsule, and success rate for swallowing the capsule at the first attempt were 0.6 (1.0), 3.4 (1.3) seconds, and 89.6%, which was significant better compared with the standard MCE group with 3.1 (1.7), 12.0 (14.3) seconds and 60.4%, respectively (all $P<0.001$). Visualization of the esophagus, stomach, and small bowel were comparable between the two groups. The small-sized MCE group had a significantly shorter gastric transit time (49.4 minutes vs. 66.2 minutes; $P=0.04$) and longer small-bowel transit time (5.8 hours vs. 5.0 hours; $P=0.045$).

Conclusions The small-sized MCE device is feasible and safe for gastrointestinal examination, alleviating difficulties in capsule ingestion, improving gastric emptying under magnetic control, and prolonging the small-bowel transit time.

Introduction

Video capsule endoscopy (VCE) has been refined with devices providing superior resolution, increased battery life, better control methods, and therefore improved capabilities for viewing of the gastrointestinal (GI) tract, since its introduction to the public in 2001 [1]. Magnetically controlled capsule endoscopy (MCE) devices, with diagnostic accuracy equally favorable as conventional gastroscopes, have been widely used in GI examination [2–4]. However, the MCE technique still has some limitations in clinical practice, including the fact that some patients experience difficulties swallowing the capsule owing to its relatively large size, which sometimes leads to examination failure, especially in children and elderly individuals [5, 6]. For those unable to swallow the capsule, endoscopic delivery of the capsule to the stomach or directly into the duodenum is required [7, 8], which greatly increases patient discomfort, examination costs, and the risks (by adding those associated with endoscopic procedures). Therefore, it is crucial to make the capsule easier to swallow and reducing the size of the capsule may ease swallowing difficulties.

Therefore, a small-sized MCE device (Ankon Technologies, Wuhan, China) with a diameter of 9.5 mm, a length of 24.5mm, and a weight of 3.0 g has been developed. This new type of MCE device is approximately 0.6 times the volume and weight of the conventional MCE device (11.8 × 27 mm) (▶ **Fig. 1**). The currently available VCE systems for viewing the esophagus, stomach, small bowel, and colon are shown in **Table 1s**, see online-only Supplementary material [1, 9, 10], with the small-sized MCE device being the smallest of these. Therefore, this study aimed to clarify whether the small-sized MCE device can optimize the capsule swallowing procedure and to evaluate its feasibility and GI transit times compared with the standard MCE device.

Methods

Study design

This study was a two-center, double-blinded randomized controlled trial. The study protocol was approved by the ethics committees of Shanghai Changhai Hospital and Qilu Hospital of Shandong University. Written informed consent was obtained from each enrolled patient.

▶ **Fig. 1** Comparison of a standard magnetically controlled capsule endoscopy (MCE) device and the small-sized MCE device (both Ankon Technologies Co., Ltd., Wuhan, China).

Study patients

From January 2021 to May 2021, adult patients with abdominal complaints or asymptomatic individuals who were scheduled to undergo MCE examination in Changhai Hospital and Qilu Hospital were eligible for this study. These patients were prospectively enrolled and randomly allocated into the standard MCE group or small-sized MCE group in a 1:1 ratio. Patients with any contraindications for MCE were excluded [11].

Study intervention

Procedures were performed using the NaviCam magnetic capsule guidance system (Ankon Technologies, Wuhan, China) [11]. Except for their size and weight, other parameters of these two capsules are consistent, with both capsules having a battery life of more than 8 hours and offering a viewing field of 140°. Images can be captured at a rate of 0.5–6 frames per second with a resolution of 480 × 480 pixels.

After a standardized GI preparation regimen for MCE [11], patients were instructed to enter the examination room. Assistant nurses who were independent of the study then assisted the patient in swallowing the assigned MCE device. During the ingestion procedure, the capsule was held in the assistant nurse's hand with only part of its lens exposed (so as to avoid recognition of the capsule size by the patient), and then put into

the patient's mouth. After the capsule entered the patient's esophagus, the endoscopists (Wei Zhou in Changhai Hospital, Bao-Ling Tian in Qilu Hospital) entered the examination room and performed the examination procedure following a standardized protocol [11].

Study outcomes and definition

The primary outcome was the difficulty score for swallowing the capsule, which was assessed on a visual analog scale ranging from 0 (very easy with no nausea) to 10 (very difficult or with severe nausea) [12]. In addition, the time required to swallow the capsule and the success rate for swallowing the capsule at the first attempt were recorded as other parameters for capsule ingestion difficulty. The capsule swallowing time was defined as the time between the first mouth image and the first esophageal image. If the patient swallowed the capsule directly with a sip of water at the first attempt, it was defined as a success for swallowing the capsule at the first attempt; if the capsule entered the esophagus after several swallowing attempts or with endoscopic placement, it was defined as a failure.

In addition, visualization of upper GI (UGI) tract and small bowel, diagnostic yield, GI transit times, and safety were also assessed. Visualization of the esophagus was indicated by the number of images and quadrants captured for the Z-line [13]. Visualization of the stomach was indicated by complete visualization of the gastric mucosa in the six anatomic landmarks [2]. Visualization of the small bowel was determined by the small-bowel complete examination rate. The detection of lesions included positive findings in the UGI tract and small bowel.

GI transit times recorded included the esophageal transit time, gastric transit time, pyloric transit time, and small-bowel transit time [14]. The gastric examination time was defined as the time required to perform complete examination of the stomach twice. The total recording time was the time the last picture of the GI tract was taken by the capsule. The frequency of the capsule passing through the pylorus under magnetic control and the duodenal papilla detection rate were also highlighted.

Each MCE video was independently and blindly interpreted by two other experienced MCE readers. Where there was a discrepancy between the two MCE readers, the final decision was made by a central committee composed of two MCE experts. The randomization schedule was generated by the investigator using a random number table. The patients, endoscopists, and outcome assessors were all blinded to the examination protocol assigned.

Sample size estimation and statistical analysis

For the primary end point, the sample size was calculated using the method of two sample *t* test. In previous studies, there are few data analyzing the difficulty score for capsule swallowing on MCE. Therefore, we conducted a pilot study and estimated that the mean difficulty scores in the small-sized and the standard MCE groups were 2.00 and 4.47, respectively, with an overall SD of 4.12. With a power of 0.80 and two-sided significance level of 0.05, 45 patients would be needed in each group to detect the difference between two groups. Considering a dropout rate of 5 %, the target total sample size was 96 (48 per group). The sample size calculation was performed using PASS software, version 15.0.5.

Quantitative data were summarized with mean (SD), or median and interquartile range (IQR); categorical data were presented as frequency (percentage). Quantitative data with a normal distribution were compared using a two-sample *t* test, and non-normally distributed data were compared using the Wilcoxon test. Categorical data were compared between groups by a chi-squared test or Fisher's exact test. A two-sided *P* value of <0.05 was considered statistically significant. All data were analyzed with SPSS software, version 23.0.

Results

Patient characteristics and safety analysis

A total of 96 consecutive patients (48 in each group) aged 24 to 79 years were enrolled from Changhai Hospital and Qilu Hospital, and all patients completed the study. Baseline characteristics of the patients are shown in **Table 2s**; no statistical difference was observed between the two groups. No adverse events were reported throughout the study.

Capsule ingestion difficulties

The small-sized MCE device greatly alleviated the difficulties on capsule ingestion, with the difficulty score for capsule swallowing (mean [SD], 0.6 [1.0] vs. 3.1 [1.7]; $P<0.001$) (▶ **Fig. 2a**) and time to swallow the capsule (mean [SD], 3.4 [1.3] seconds vs. 12.0 [14.3] seconds; $P<0.001$) (▶ **Fig. 2b**) in the small-sized MCE group being significantly lower than those in the standard MCE group. In the small-sized MCE group, 89.6 % of patients successfully swallowed the MCE at the first attempt, whereas the success rate was 60.4 % in the standard MCE group ($P<0.001$) (▶ **Fig. 2c**).

Visualization and positive findings of the UGI and small bowel

▶ **Table 1** shows the results for visualization of the esophagus, stomach, and small bowel in the two groups. Representative images of anatomic landmarks using the small-sized MCE device are shown in ▶ **Fig. 3**. There was no significant difference in the detection rate of the Z-line ($P=0.67$), captured frames of the Z-line ($P=0.73$), or quadrants observed in the Z-line ($P=0.67$). In all patients, more than 90 % of the gastric mucosa in the six anatomic landmarks was observed. The small-bowel complete examination rate was 97.9 % and 100 % in the small-sized and standard MCE groups, respectively ($P>0.99$).

The diagnoses identified in each group in the UGI tract and small bowel are summarized in **Table 3s** and illustrated in ▶ **Fig. 4**. There were no significant differences in the detection of lesions between the two groups.

Gastrointestinal transit times

Detailed data on GI transit times are shown in ▶ **Table 1**. No significant difference in the gastric examination time or capsule excretion time existed between the two groups ($P=0.30$ and 0.74, respectively). The small-sized MCE group had a signifi-

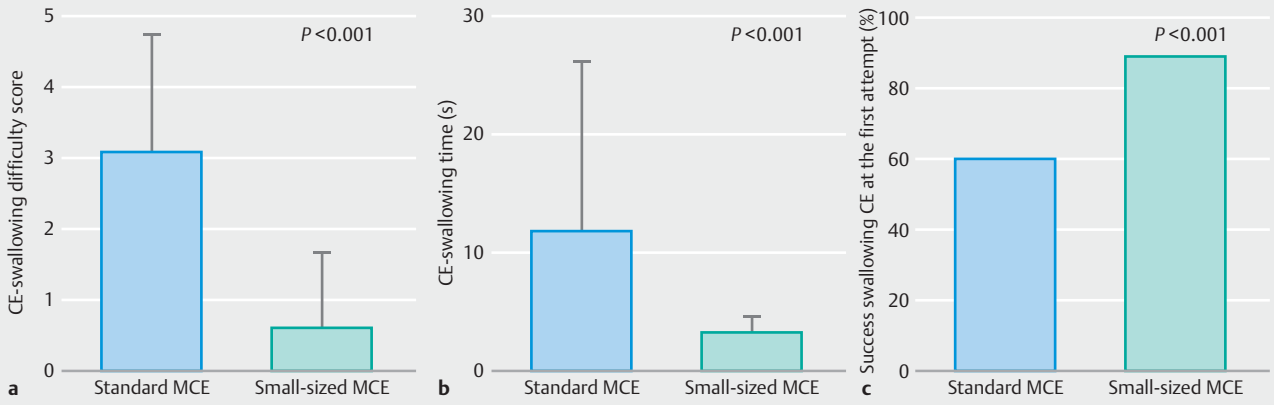

▶ **Fig. 2** Comparison of capsule ingestion difficulties between the small-sized magnetically controlled capsule endoscopy (MCE) device and standard MCE device in terms of: **a** the difficulty score for capsule swallowing; **b** the capsule swallowing time; **c** the success rate for swallowing the capsule at the first attempt.

▶ **Table 1** Efficacy analysis between the small-sized magnetically controlled capsule endoscopy (MCE) device and the standard MCE device.

Characteristic	Small-sized MCE device (n = 48)	Standard MCE device (n = 48)	*P* value
Visualization of the esophagus			
▪ Detection of Z-line, n (%)	29 (60.4 %)	31 (64.6 %)	0.67
▪ Frames of Z-line, median (IQR)	1.0 (0.0–8.0)	2.0 (0.0–6.8)	0.73
▪ Quadrants of Z-line visualization, median (IQR)	1.6 (0.0–3.2)	1.5 (0.0–2.5)	0.67
Complete gastric mucosal visualization, n (%)			
▪ Cardia	48 (100 %)	48 (100 %)	> 0.99
▪ Fundus	48 (100 %)	48 (100 %)	> 0.99
▪ Body	48 (100 %)	48 (100 %)	> 0.99
▪ Angulus	48 (100 %)	48 (100 %)	> 0.99
▪ Antrum	48 (100 %)	48 (100 %)	> 0.99
▪ Pylorus	48 (100 %)	48 (100 %)	> 0.99
Visualization of the small bowel, n (%)			
Small-bowel complete examination rate	47 (97.9 %)	48 (100 %)	> 0.99
Capsule transit times, median (IQR)			
▪ Esophageal, seconds	12.0 (7.3–23.5)	18.0 (11.0–33.8)	0.02
▪ Gastric, minutes	49.4 (8.3–79.7)	66.2 (37.4–113.7)	0.04
▪ Pyloric, minutes	38.8 (0.4–67.4)	54.2 (29.5–100.5)	0.04
▪ Small bowel, mean (SD), hours	5.8 (1.7)	5.0 (1.8)	0.045
Gastric examination time, mean (SD), minutes	9.2 (3.9)	10.0 (3.6)	0.30
Total recording time, median (IQR), hours	11.2 (10.2–11.4)	12.7 (11.7–13.4)	< 0.001
Excretion time, median (IQR), days	1.5 (1.0–2.5)	1.9 (1.0–2.2)	0.74
Magnetically controlled gastric transit rate, n (%)	21 (43.8 %)	10 (20.8 %)	0.02
Duodenal papilla detection rate, n (%)	9 (18.8 %)	4 (8.3 %)	0.23

IQR, interquartile range.

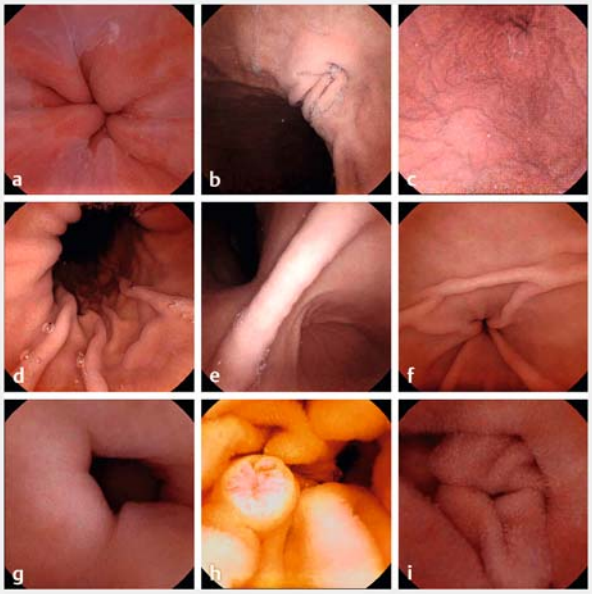

▶ **Fig. 3** Representative images of anatomic landmarks using the small-sized magnetically controlled capsule endoscopy device showing: **a** esophageal Z-line; **b** gastric cardia; **c** fundus; **d** gastric body; **e** angulus; **f** antrum; **g** pylorus; **h** duodenal papilla; **i** small intestine.

cantly shorter esophageal transit time ($P = 0.02$), pyloric transit time ($P = 0.04$), gastric transit time ($P = 0.04$), and a significantly longer small-bowel transit time ($P = 0.045$). The median total recording time was shorter in the small-sized MCE group ($P < 0.001$) owing to its smaller battery size. The small-sized MCE device was easier to guide into the duodenum under magnetic control ($P = 0.02$). In addition, the duodenal papilla detection rate was somewhat higher in the small-sized MCE group than in the standard MCE group (18.8 % vs. 8.3 %; $P = 0.23$).

Discussion

The performance of the small-sized MCE device in terms of the ingestion procedure and examination efficacy has not been explored in previous studies. To our knowledge, our study demonstrated for the first time that the small-sized MCE device greatly alleviated capsule ingestion difficulties. In the small-sized MCE group, the subjects swallowed the capsule with a lower difficulty score and a shorter swallowing time. Most patients in the small-sized MCE group were able to swallow capsule directly with a sip of water, while approximately 40 % of patients in the standard MCE group required several attempts to swallow the capsule. Previous studies have reported that more than 50 % of pediatric patients, ranging from 1.6 to 18.5 years in age, failed to swallow capsules and younger patients showed more difficulty in capsule ingestion [15–17]. In adults, capsule ingestion difficulties also exist, especially in elderly patients [5, 18]. Therefore, a small-sized MCE device may greatly benefit the ingestion procedure in pediatric patients, elderly individuals, and those who fear swallowing or are unable to swallow the capsule, thereby reducing the rates of endoscopic placement and examination failure.

The efficacy of the small-sized MCE device in visualization and lesion detection in the UGI tract and small bowel is comparable to that of the standard MCE device. In addition, no adverse events were observed in this trial, suggesting that the small-sized MCE device is safe and feasible in GI examination.

The gastric transit rate under magnetic control was increased in the small-sized MCE group, while the median pyloric and gastric transit times were significantly reduced. This showed that the reduced size of the capsule made it easier for it to be passed through the pylorus under magnetic control. Additionally, a longer small-bowel transit time was observed in the small-sized MCE group, thereby allowing enough time for superior image acquisition of the intestinal mucosa. Our result of a longer small-bowel transit time for the smaller capsule was consistent with the studies conducted by Pioche et al. [19, 20],

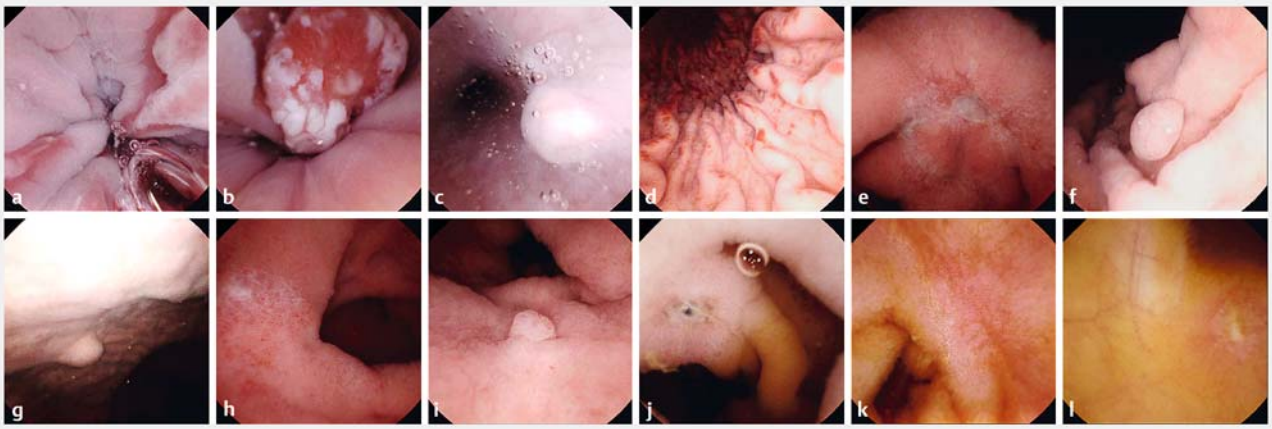

▶ **Fig. 4** Typical gastrointestinal lesions observed using the small-sized magnetically controlled capsule endoscopy device showing: **a** reflux esophagitis; **b** esophageal cancer; **c** esophageal submucosal mass; **d** gastritis; **e** gastric ulcer; **f** gastric polyp; **g** gastric submucosal mass; **h** duodenitis; **i** duodenal polyp; **j** duodenal ulcer; **k** small-bowel inflammation; **l** small-bowel ulcer.

which supported that, in addition to GI motility-related factors, the size of the capsule itself may play an important role in small-bowel transit. In our study, the small-sized MCE device passed through the esophagus faster than the standard MCE, which may be due to the stronger driving effect of the consumed water on the small-sized MCE device. Although the total recording time was shorter in the small-sized MCE group, the small-bowel complete examination rate was comparable between the two groups. This result supports the 11.2-hour battery life of the small-sized MCE device, when combined with enhanced gastric emptying, being sufficient to meet the requirements of small-bowel examination.

Our study has some limitations. In particular, we enrolled only adult patients, and none of the participants in the current study failed to swallow the capsule. Those with a higher incidence of capsule ingestion failure, such as children, were not included, so this study cannot evaluate the efficacy of the small-sized MCE device in improving the capsule ingestion procedure in more diverse populations.

In conclusion, our study demonstrated that the small-sized MCE device alleviated the difficulties of capsule ingestion in adults. The small-sized MCE device enhanced gastric emptying under magnetic control and prolonged the small-bowel transit time. Further studies focusing on pediatric patients, elderly individuals, and those who are unable or afraid to swallow the larger capsule are warranted.

Acknowledgments

The authors would like to thank Professor Cheng Wu (Department of Military Health Statistics, Naval Medical University, Shanghai, China) and Shengyong Wu (Department of Military Health Statistics, Naval Medical University, Shanghai, China) for their help with the statistical analysis.

Competing interests

The authors declare that they have no conflict of interest.

Funding

Shandong Provincial Key Research and Development Program (Major Scientific and Technological Innovation Project) 2019JZZY011007
Shanghai Municipal Hospital Emerging Frontier Technology Joint Project SHDC12019105
"Ten Thousand Plan"-National High Level Talents Special Support Plan

Clinical trial

Trial Registration: ClinicalTrials.gov | Registration number (trial ID): NCT05073536 | Type of study: Prospective, Randomized, Two-Center Study

References

[1] Melson J, Trikudanathan G, Abu Dayyeh B et al. Video capsule endoscopy. Gastrointest Endosc 2021; 93: 784–796

[2] Liao Z, Hou X, Lin-Hu E et al. Accuracy of magnetically controlled capsule endoscopy, compared with conventional gastroscopy, in detection of gastric diseases. Clin Gastroenterol Hepatol 2016; 14: 1266–1273.e1

[3] Li Z, Liu J, Ji C et al. Screening for upper gastrointestinal cancers with magnetically controlled capsule gastroscopy: a feasibility study. Endoscopy 2021; 53: 914–919

[4] Liao Z, Zou W, Li Z. Clinical application of magnetically controlled capsule gastroscopy in gastric disease diagnosis: recent advances. Sci China Life Sci 2018; 61: 1304–1309

[5] Wang Y, Pan J, Liu Y et al. Adverse events of video capsule endoscopy over the past two decades: a systematic review and proportion meta-analysis. BMC Gastroenterol 2020; 20: 364–374

[6] Nuutinen H, Kolho K, Salminen P et al. Capsule endoscopy in pediatric patients: technique and results in our first 100 consecutive children. Scand J Gastroenterol 2011; 46: 1138–1143

[7] Rondonotti E, Spada C, Adler S et al. Small-bowel capsule endoscopy and device-assisted enteroscopy for diagnosis and treatment of small-bowel disorders: European Society of Gastrointestinal Endoscopy (ESGE) Technical Review. Endoscopy 2018; 50: 423–446

[8] Argüelles-Arias F, Donat E, Fernández-Urien I et al. Guideline for wireless capsule endoscopy in children and adolescents: A consensus document by the SEGHNP (Spanish Society for Pediatric Gastroenterology, Hepatology, and Nutrition) and the SEPD (Spanish Society for Digestive Diseases). Rev Esp Enferm Dig 2015; 107: 714–731

[9] Eliakim R. Where do I see minimally invasive endoscopy in 2020: clock is ticking. Ann Transl Med 2017; 5: 202

[10] Jiang B, Qian Y, Pan J et al. Second-generation magnetically controlled capsule gastroscopy with improved image resolution and frame rate: a randomized controlled clinical trial (with video). Gastrointest Endosc 2020; 91: 1379–1387

[11] Jiang X, Pan J, Li Z et al. Standardized examination procedure of magnetically controlled capsule endoscopy. VideoGIE 2019; 4: 239–243

[12] Fernandez-Urien I, Borobio E, Elizalde I et al. Z-line examination by the PillCam SB: prospective comparison of three ingestion protocols. World J Gastroenterol 2010; 16: 63–68

[13] Gralnek I, Adler S, Yassin K et al. Detecting esophageal disease with second-generation capsule endoscopy: initial evaluation of the PillCam ESO 2. Endoscopy 2008; 40: 275–279

[14] Luo Y, Pan J, Chen Y et al. Magnetic steering of capsule endoscopy improves small bowel capsule endoscopy completion rate. Dig Dis Sci 2019; 64: 1908–1915

[15] Burgess C, McIntyre E, Withers G et al. Comparing swallowing of capsule to endoscopic placement of capsule endoscopy in children. JGH Open 2017; 1: 11–14

[16] Oikawa-Kawamoto M, Sogo T, Yamaguchi T et al. Safety and utility of capsule endoscopy for infants and young children. World J Gastroenterol 2013; 19: 8342–8348

[17] Fritscher-Ravens A, Scherbakov P, Bufler P et al. The feasibility of wireless capsule endoscopy in detecting small intestinal pathology in children under the age of 8 years: a multicentre European study. Gut 2009; 58: 1467–1472

[18] Goenka M, Majumder S, Goenka U. Capsule endoscopy: Present status and future expectation. World J Gastroenterol 2014; 20: 10024–10037

[19] Pioche M, Gaudin J, Filoche B et al. Prospective, randomized comparison of two small-bowel capsule endoscopy systems in patients with obscure GI bleeding. Gastrointest Endosc 2011; 73: 1181–1188

[20] Choi E, Mergener K, Semrad C et al. A multicenter, prospective, randomized comparison of a novel signal transmission capsule endoscope to an existing capsule endoscope. Gastrointest Endosc 2013; 78: 325–332