

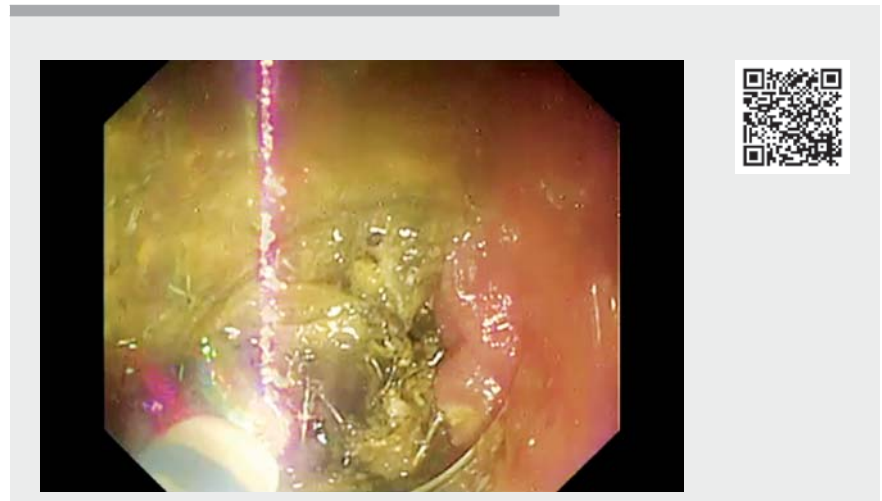
Esophageal stent removal by stent cutting using the endoscopic submucosal dissection technique



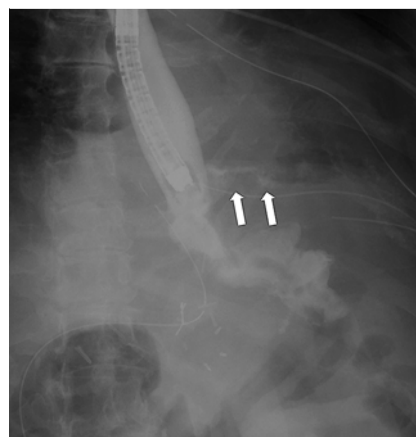
The European Society of Gastrointestinal Endoscopy recommends temporary esophageal stenting for the treatment of benign esophageal leaks, but there is no consensus on the duration of stent placement [1]. Prolonged stenting can result in tissue hyperplasia that makes removal difficult, and forcible removal can cause esophageal perforation requiring surgery [2]. There are reports that a stent-in-stent approach enables stent removal [3], but it involves the cost of another stent. Argon plasma coagulation (APC) and an endoscopic submucosal dissection (ESD) knife are used to resect hyperplasia and reportedly allow stent removal [4,5]. We unsuccessfully attempted to cut a stent using APC and completed the procedure by switching to an ESD knife. There are no reports of cutting gastrointestinal stents with an ESD knife and we report the procedure herein (► **Video 1**).

A covered esophageal stent (Niti-S Esophageal ComVi Stent 18×100 mm; TaeWoong Medical, Gimpo-si, South Korea) was implanted in a 76-year-old woman for leakage at the esophageal jejunal anastomosis after proximal gastrectomy (► **Fig. 1**, ► **Fig. 2**). The leak improved after 4 months and stent removal was attempted, but the proximal and distal flared ends were embedded in the hyperplastic esophageal wall and could not be removed.

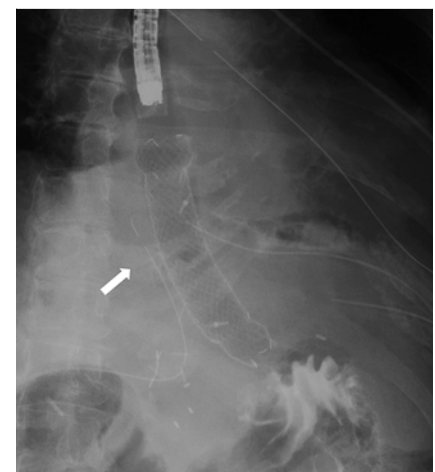
We used a GIF-Q260 J (Olympus, Tokyo, Japan) scope with tip attachment and a VIO-300D (Erbe Elektromedizin GmbH, Tübingen, Germany). APC was set at Forced APC flow rate of 2L/min, 100W. Effective stent cutting on the distal side was not possible because the working space was too narrow for selective discharge by APC. Therefore, we changed to a Dual Knife J (Olympus), setting it to Swift coagulation mode effect 4, 40W. While cutting with the ESD knife, it was important to keep a small distance between the tip of the knife and the stent,



► **Video 1** Stent cutting using endoscopic submucosal dissection technique.



► **Fig. 1** Image of the leak. Contrast leakage is observed (arrow).



► **Fig. 2** Image of esophageal stenting: stent is implanted, and the leak area is covered (arrow).



and to be aware that the knife was cutting with a discharge. Using the ESD knife, the metal parts could be cut selectively and the cover parts easily. The stent was removed by cutting circumferentially.

Endoscopy_UCTN_Code_CPL_1AH_2AD

Competing interests

The authors declare that they have no conflict of interest.

The authors

Chikamasa Ichita¹ , Akiko Sasaki¹, Jun Kawachi², Chihiro Sumida¹, Takashi Nishino¹, Sakue Masuda¹ , Kazuya Koizumi¹ 

- 1 Gastroenterology Medicine Center, Shonan Kamakura General Hospital, Kamakura, Kanagawa, Japan
- 2 Department of Surgery, Shonan Kamakura General Hospital, Kamakura, Kanagawa, Japan

Corresponding author

Chikamasa Ichita, MD

Gastroenterology Medicine Center,
Shonankamakura General Hospital, 1370-1
Okamoto, Kamakura, Kanagawa 247-8533,
Japan

Fax: +81-467-45-0190

ichikamasa@yahoo.co.jp

References

- [1] Spaander MCW, van der Bogt RD, Baron TH et al. Esophageal stenting for benign and malignant disease: European Society of Gastrointestinal Endoscopy (ESGE) guideline update 2021. *Endoscopy* 2021; 53: 751–762
- [2] Hirdes MM, Vleggaar FP, Van der Linde K et al. Esophageal perforation due to removal of partially covered self-expanding metal stents placed for a benign perforation or leak. *Endoscopy* 2011; 43: 156–159
- [3] Aiolfi A, Bona D, Ceriani C et al. Stent-in-stent, a safe and effective technique to remove fully embedded esophageal metal stents: case series and literature review. *Endoscopy Int Open* 2015; 3: E296–299
- [4] Fiocca F, Cereatti F, Antypas P et al. Argon plasma coagulation: a less-expensive alternative to the 'stent-in-stent' technique for removal of embedded partially covered esophageal stents. *Gastrointest Endosc* 2016; 83: 453
- [5] Chon SH, Ramadori E, Pinto Dos Santos D et al. Endoscopic removal of a fractured esophageal stent from the mediastinum and leak closure with endoscopic vacuum therapy. *Endoscopy* 2022; 54: 334–335

Bibliography

Endoscopy 2022; 54: E935–E936

DOI 10.1055/a-1882-4724

ISSN 0013-726X

published online 14.7.2022

© 2022. The Author(s).

This is an open access article published by Thieme under the terms of the Creative Commons Attribution-NonDerivative-NonCommercial License, permitting copying and reproduction so long as the original work is given appropriate credit. Contents may not be used for commercial purposes, or adapted, remixed, transformed or built upon. (<https://creativecommons.org/licenses/by-nc-nd/4.0/>)

Georg Thieme Verlag KG, Rüdigerstraße 14,
70469 Stuttgart, Germany



ENDOSCOPY E-VIDEOS

<https://eref.thieme.de/e-videos>



Endoscopy E-Videos is an open access online section, reporting on interesting cases and new techniques in gastroenterological endoscopy. All papers include a high quality video and all contributions are freely accessible online. Processing charges apply (currently EUR 375), discounts and waivers acc. to HINARI are available.

This section has its own submission website at

<https://mc.manuscriptcentral.com/e-videos>