Article published online: 2022-07-21

How to confirm the appropriate incision depth using a guidewire during needle-knife fistulotomy

OPEN ACCESS

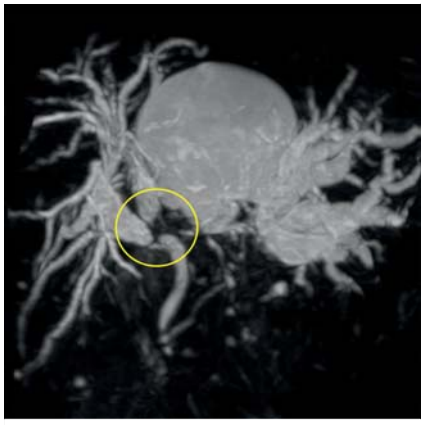

▶ **Fig. 1** Magnetic resonance cholangiopancreatography (MRCP) reveals Bismuth type IV perihilar stenosis (yellow circle).

An early attempt at needle-knife fistulotomy (NKF) is the rescue technique for selective biliary cannulation (SBC) [1–3]. To complete NKF, it is crucial to identify critical landmarks, including the glistening pink adventitia of the bile duct, the onion skin-like biliary orifice within the incision, and the pearly-white biliary mucosa [4]. However, owing to the diversity of papillary morphology, it is challenging to identify these landmarks and determine appropriate incision depth in every individual attempt [5].

An 88-year-old female patient with a nonspecific medical history was referred to our department because of obstructive jaundice. Magnetic resonance cholangiopancreatography revealed Bismuth type IV perihilar cholangiocarcinoma (▶ **Fig. 1**). Transpapillary biliary drainage was attempted; however, primary wire-guided cannulation met the criteria for difficult SBC [1]. We performed NKF using a needle knife (KD-V451M; Olympus Medical Systems, Tokyo, Japan) with a generator (VIO 200D; ERBE, Tubingen, Germany) in accordance with the manufacturer's recommendations [1]. Layer-by-layer incision was extended to the narrow distal segment (▶ **Fig. 2 a**). However, SBC could not be achieved after several attempts and we were therefore considering whether a further cut might be needed. We then inserted a guidewire into the narrow distal segment from the papillary orifice, and the emergence of the guidewire from the incision site (▶ **Fig. 2 b**) indicated that the incision depth was appropriate. Hence, further NKF was unnecessary, and we resumed

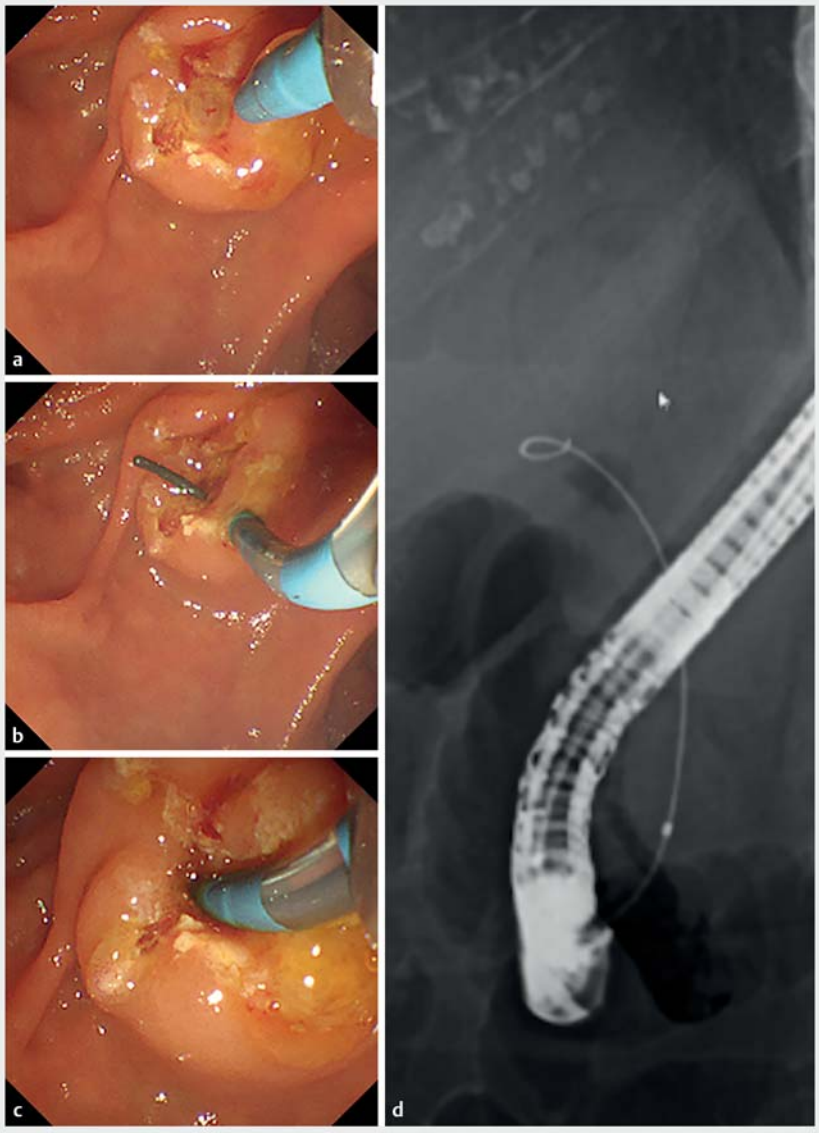

▶ **Fig. 2** Needle-knife fistulotomy (NKF) and confirmation of incision depth by guidewire insertion from the papillary orifice. **a** Layer-by-layer NKF incision reached the narrow distal segment; however, biliary access was not obtained. **b** The emergence of the guidewire, which was inserted from the papillary orifice, indicated that the NKF incision depth was appropriate. **c, d** Achievement of biliary access from the incision.

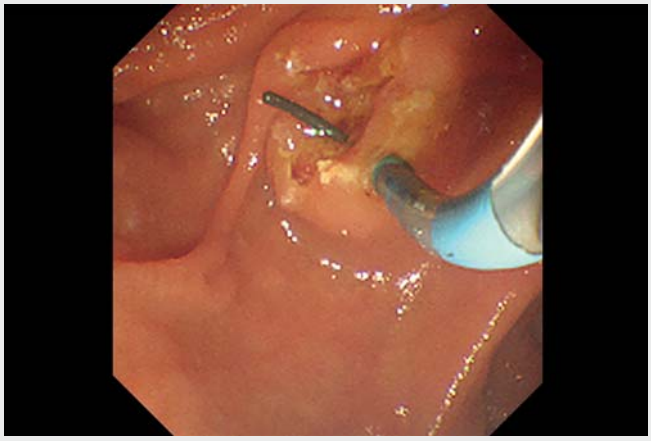

Video 1 Confirmation of appropriate incision depth using a guidewire during needle-knife fistulotomy (NKF). SBC, selective biliary cannulation; NDS, narrow distal segment; BDC, bile duct cannulation.

guidewire insertion from the fistula until SBC was achieved (▶ **Fig. 2 c, d**; ▶ **Video 1**). Finally, we completed transpapillary biliary drainage using multiple inside (that is, placed above the duodenal papilla) plastic stents.

Guidewire insertion from the papillary orifice can help confirm the appropriate depth of NKF and avoid thermal injury of the main pancreatic duct and retroperitoneal perforation caused by an unnecessarily deep incision. When the guidewire sticks at the narrow distal segment, further NKF incision is needed. If the guidewire advances into the main pancreatic duct, transpancreatic sphincterotomy could be a useful alternative precut technique.

Endoscopy_UCTN_Code_TTT_1AR_2AC

Competing interests

The authors declare that they have no conflict of interest.

The authors

Tesshin Ban, Yoshimasa Kubota, Tomoaki Ando
Department of Gastroenterology and Hepatology, Gamagori City Hospital, Gamagori, Aichi, Japan

Corresponding author

Tesshin Ban, MD
Department of Gastroenterology and Hepatology, Gamagori City Hospital, Gamagori, Aichi, Japan, 1-1 Mukaida, Hirata, Gamagori, Aichi 443-8501, Japan
Fax: +81-533-662295
venzosan0204@gmail.com

References

[1] Testoni PA, Mariani A, Aabakken L et al. Papillary cannulation and sphincterotomy techniques at ERCP: European Society of Gastrointestinal Endoscopy (ESGE) clinical guideline. Endoscopy 2016; 48: 657–683
[2] Facciorusso A, Ramai D, Gkolfakis P et al. Comparative efficacy of different methods for difficult biliary cannulation in ERCP: systematic review and network meta-analysis. Gastrointest Endosc 2022; 95: 60–71.e12
[3] Jang SI, Kim DU, Cho JH et al. Primary needle-knife fistulotomy versus conventional cannulation method in a high-risk cohort of post-endoscopic retrograde cholangiopancreatography pancreatitis. Am J Gastroenterol 2020; 115: 616–624
[4] Magulick JP, Campbell EV3rd, Muniraj T et al. Access fistulotomy: technical tips for success. VideoGIE 2020; 6: 49–53
[5] Zhang QS, Xu JH, Dong ZQ et al. Success and safety of needle knife papillotomy and fistulotomy based on papillary anatomy: A prospective controlled trial. Dig Dis Sci 2021. doi:10.1007/s10620-021-06983-7

Bibliography

Endoscopy 2022; 54: E958–E959
DOI 10.1055/a-1883-9658
ISSN 0013-726X
published online 21.7.2022
© 2022. The Author(s).
This is an open access article published by Thieme under the terms of the Creative Commons Attribution-NonDerivative-NonCommercial License, permitting copying and reproduction so long as the original work is given appropriate credit. Contents may not be used for commercial purposes, or adapted, remixed, transformed or built upon. (https://creativecommons.org/licenses/by-nc-nd/4.0/)
Georg Thieme Verlag KG, Rüdigerstraße 14, 70469 Stuttgart, Germany

ENDOSCOPY E-VIDEOS
https://eref.thieme.de/e-videos

Endoscopy E-Videos is an open access online section, reporting on interesting cases and new techniques in gastroenterological endoscopy. All papers include a high quality video and all contributions are freely accessible online. Processing charges apply (currently EUR 375), discounts and wavers acc. to HINARI are available.

This section has its own submission website at https://mc.manuscriptcentral.com/e-videos