Article published online: 2022-08-04

Massive bleeding on removing a stent placed during endoscopic ultrasound-guided transluminal drainage

OPEN ACCESS

▶ **Fig. 1** An abdominal computed tomography image shows walled-off necrosis (arrows). The diameter of the lesion is approximately 8 cm.

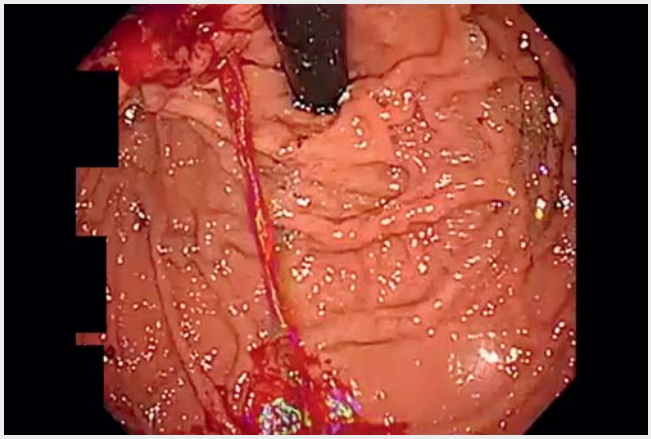

▶ **Video 1** Massive bleeding caused by the removal of a double-pigtail plastic stent after its prolonged placement for internal drainage of a walled-off necrosis.

▶ **Fig. 2** Endoscopic ultrasound-guided transluminal drainage was performed using a 6-Fr endoscopic nasobiliary drainage catheter (white arrowheads) as an external drainage tube and a 7-Fr/7-cm double-pigtail plastic stent (yellow arrowheads) as an internal drainage tube.

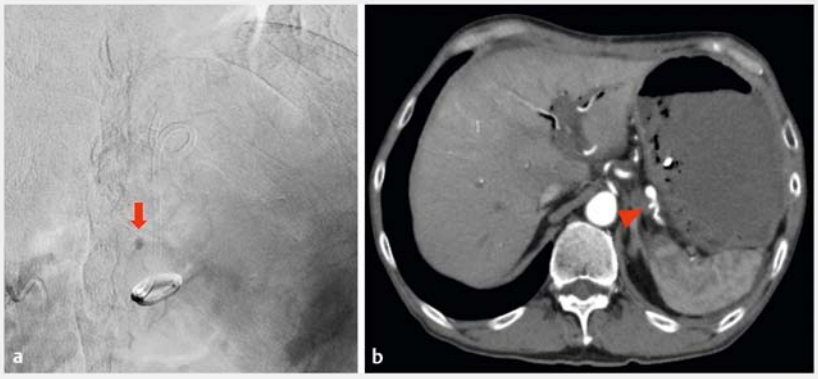

▶ **Fig. 3** Interventional radiology detected a splenic artery pseudoaneurysm. **a** Selective angiogram of the celiac artery showed pooling of contrast medium (arrow), indicating the presence of a splenic artery pseudoaneurysm. **b** A computed tomography image detected the splenic artery pseudoaneurysm (arrowhead).

A 67-year-old man with pancreatic head cancer developed acute pancreatitis due to obstruction of the main pancreatic duct. He subsequently developed an infected walled-off necrosis (WON) (▶ **Fig. 1**). Endoscopic ultrasound-guided transluminal drainage (EUS-TD) was performed using a 6-Fr endoscopic nasobiliary drainage catheter (SilkyPass; Boston Scientific, Tokyo, Japan) as an external drainage tube and a 7-Fr/7-cm double-pigtail plastic stent (DPS) (Zimmon biliary stent; Cook Medical, Tokyo, Japan) as an internal drainage tube (▶ **Fig. 2**). Subsequently, the patient's condition improved, and the external drainage tube was removed. Computed tomography (CT) performed 4 months after EUS-TD revealed that the WON had disappeared. The DPS was in place until pancreaticoduodenectomy after neoadjuvant chemotherapy and was removed endoscopically 8 months after EUS-TD because of the risk that the DPS could cause infection during adjuvant chemotherapy. At the time the stent was removed, massive arterial bleeding occurred from the fis-

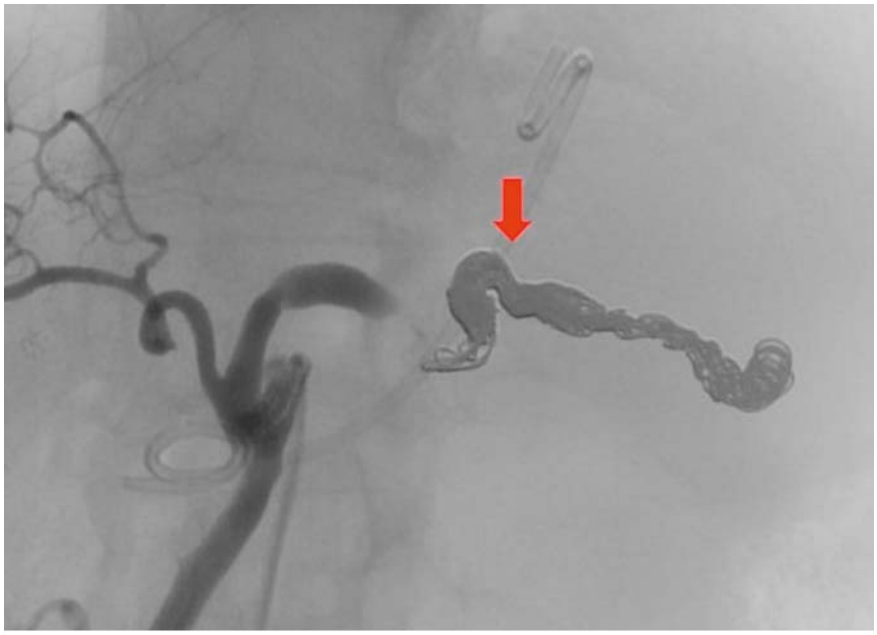

▶ **Fig. 4** Angiogram after coil embolization for hemostasis shows no pooling of the contrast medium (arrow).

tula (▶ **Video 1**). Since endoscopic hemostasis was difficult, urgent interventional radiology was performed, and a splenic artery pseudoaneurysm causing massive bleeding was detected (▶ **Fig. 3**). Hemostasis was achieved using coil embolization (▶ **Fig. 4**).

WON is a late complication of acute necrotizing pancreatitis. Currently, EUS-TD is the best therapeutic option for WON [1]. Although lumen-apposing covered self-expanding metal stents have been introduced, EUS-TD with DPS remains the main endoscopic therapy for WON. DPS is associated with lower rates of procedure-related bleeding, such as serious pseudoaneurysm bleeding [2, 3]. Nevertheless, in this case, massive bleeding due to a pseudoaneurysm occurred after stent removal. The pseudoaneurysm may have been formed by the long period of stent placement and contact, causing arteritis. When removing a plastic stent after a long period of placement, it is crucial to consider that serious complications can occur, and contrast-enhanced CT should be performed to check for the presence of a pseudoaneurysm before stent removal.

Endoscopy_UCTN_Code_TTT_1AO_2AD

Competing interests

The authors declare that they have no conflict of interest.

The authors

Ikuhisa Takimoto, Tomoaki Matsumori, Masataka Yokode, Masahiro Shiokawa, Norimitsu Uza, Hiroshi Seno
Department of Gastroenterology and Hepatology, Kyoto University Graduate School of Medicine, Kyoto, Japan

Corresponding author

Tomoaki Matsumori, MD, PhD
Department of Gastroenterology and Hepatology, Kyoto University Graduate School of Medicine, 54 Kawara-cho, Shogoin, Sakyo-ku, Kyoto 606-8507, Japan
tom.matu@kuhp.kyoto-u.ac.jp

References

[1] Ang TL, Teoh AYB. Endoscopic ultrasonography-guided drainage of pancreatic fluid collections. Dig Endosc 2017; 29: 463–471
[2] Brimhall B, Han S, Tatman PD et al. Increased incidence of pseudoaneurysm bleeding with lumen-apposing metal stents compared to double-pigtail plastic stents in patients with peripancreatic fluid collections. Clin Gastroenterol Hepatol 2018; 16: 1521–1528
[3] Lang GD, Fritz C, Bhat T et al. EUS-guided drainage of peripancreatic fluid collections with lumen-apposing metal stents and plastic double-pigtail stents: comparison of efficacy and adverse event rates. Gastrointest Endosc 2018; 87: 150–157

Bibliography

Endoscopy 2022; 54: E990–E991
DOI 10.1055/a-1887-5667
ISSN 0013-726X
published online 4.8.2022

Georg Thieme Verlag KG, Rüdigerstraße 14, 70469 Stuttgart, Germany