



# No Differences in Cerebral Immunohistochemical Markers following Remote Ischemic Postconditioning in Newborn Piglets with Hypoxia–Ischemia

Hannah B. Andersen<sup>1,\*</sup> Mads Andersen<sup>1,\*</sup> Kristine Bennedsgaard<sup>1</sup> Sigrid Kern-Jespersen<sup>1</sup>  
Kasper J. Kyng<sup>1</sup> Ida E. Holm<sup>2</sup> Tine B. Henriksen<sup>1</sup>

<sup>1</sup>Department of Paediatrics and Adolescent Medicine, Aarhus University Hospital, Aarhus, Denmark

<sup>2</sup>Department of Pathology, Randers Regional Hospital, Randers, Denmark

Address for correspondence Mads Andersen, BM, Department of Paediatrics and Adolescent Medicine, Aarhus University Hospital, Palle Juul-Jensens Boulevard. 99, Aarhus 8200, Denmark (e-mail: mads.andersen@clin.au.dk).

Neuropediatrics 2022;53:423–431.

## Abstract

**Background** Despite therapeutic hypothermia, neonates with hypoxic–ischemic encephalopathy still develop neurological disabilities. We have previously investigated neuroprotection by remote ischemic postconditioning (RIPC) in newborn piglets following hypoxia–ischemia (HI). The aim of this study was to further investigate potential effects of RIPC on cerebral immunohistochemical markers related to edema, apoptosis, and angiogenesis.

**Methods** Brain expression of aquaporin 4, caspase-3, B-cell lymphoma 2, and vascular endothelial growth factor was analyzed by immunohistochemistry in 23 piglets, randomly selected from a larger study of RIPC after HI. Twenty animals were subjected to 45 minutes of HI and randomized to treatment with and without RIPC, while three animals were randomized to sham procedures. RIPC was conducted by four conditioning cycles of 5-minute ischemia and reperfusion. Piglets were euthanized 72 hours after the HI insult.

**Results** Piglets subjected to HI treated with and without RIPC were similar at baseline and following the HI insult. However, piglets randomized to HI alone had longer duration of low blood pressure during the insult. We found no differences in the brain expression of the immunohistochemical markers in any regions of interest or the whole brain between the two HI groups.

**Conclusion** RIPC did not influence brain expression of markers related to edema, apoptosis, or angiogenesis in newborn piglets at 72 hours after HI. These results support previous findings of limited neuroprotective effect by this RIPC protocol. Our results may have been affected by the time of assessment, use of fentanyl as anesthetic, or limitations related to our immunohistochemical methods.

## Keywords

- hypoxia–ischemia
- hypoxic–ischemic encephalopathy
- remote ischemic postconditioning
- immunohistochemistry
- piglet model

\* These authors have contributed equally to this work and share first authorship.

received

December 7, 2021

accepted

June 2, 2022

accepted manuscript online

July 1, 2022

article published online

August 28, 2022

DOI <https://doi.org/10.1055/a-1889-8544>.

ISSN 0174-304X.

© 2022. The Author(s).

This is an open access article published by Thieme under the terms of the Creative Commons Attribution-NonDerivative-NonCommercial-License, permitting copying and reproduction so long as the original work is given appropriate credit. Contents may not be used for commercial purposes, or adapted, remixed, transformed or built upon. (<https://creativecommons.org/licenses/by-nc-nd/4.0/>)

Georg Thieme Verlag KG, Rüdigerstraße 14, 70469 Stuttgart, Germany

## Introduction

Each year, over 1 million neonates develop neonatal encephalopathy worldwide.<sup>1</sup> The condition is associated with increased infant mortality and neurological disability.<sup>1</sup> Perinatal hypoxia and ischemia (HI) resulting in hypoxic–ischemic encephalopathy (HIE) is the leading cause of neonatal encephalopathy.<sup>2</sup> Therapeutic hypothermia is a well-established neuroprotective treatment in HIE.<sup>3</sup> However, around 50% of neonates treated with hypothermia still die or suffer from neurodevelopmental impairments.<sup>4</sup> Low-resource settings have the highest incidence of HIE, but there is sparse evidence of an effect of therapeutic hypothermia in these countries and results may even be compatible with adverse outcomes.<sup>1,5,6</sup> Therefore, inexpensive, readily available, and easily applicable treatments are needed either alone or in combination with therapeutic hypothermia.

Remote ischemic postconditioning (RIPC) fulfills these criteria. After a severe HI insult, endogenous tissue protection may be induced by application of local ischemia in one or multiple limbs. However, the neuroprotective effect of RIPC in neonatal HIE remains questionable.<sup>7</sup> We have previously shown that RIPC of four cycles with 5-minute ischemia and reperfusion was associated with improved brain metabolism in newborn piglets, 72 hours following HI, indicated by a lower brain lactate/N-acetyl-aspartate ratio assessed by magnetic resonance spectroscopy.<sup>8</sup> Brain lactate/N-acetyl-aspartate has been shown to be the most accurate predictor of long-term outcome in neonatal HIE.<sup>9,10</sup> However, we found no association between RIPC and multiple other outcomes including cerebral diffusion-weighted imaging, histopathology, and functional capabilities. Another piglet model of HI induced by carotid-clamping also found that RIPC of four cycles with 10-minute ischemia and reperfusion was associated with lower lactate/N-acetyl-aspartate, as well as histological cell death after 48 hours but only in the cerebral white matter.<sup>11</sup> Therefore, we wanted to conduct additional analyses based on a subset of brain samples from our previous study to further investigate plausible effects of RIPC.

Edema, apoptosis, and angiogenesis have been implicated in the development of neonatal HI brain injury or protection.<sup>12–14</sup> In rodent models of cerebral ischemia, postconditioning has been found to decrease brain expression of the water-channel aquaporin 4 (AQP4) and the apoptotic caspase-3, while increasing the expression of the antiapoptotic B-cell lymphoma 2 (Bcl-2) and the angiogenic vascular endothelial growth factor (VEGF).<sup>15–21</sup> Thorough investigation of these markers in larger animal models may take RIPC one step further into clinical testing in human newborns with HIE.<sup>22</sup> The aim of this study was therefore to compare the brain expression of AQP4, caspase-3, Bcl-2, and VEGF in newborn piglets 72 hours after a standardized HI insult treated with and without RIPC.

## Methods

### Ethical Statement

The experiment was approved by the Danish Animal Experiments Inspectorate (identifier: 2012 – 15 – 2934 – 00036). Reporting of the study complies with the Animal Research:

Reporting of In Vivo Experiments guidelines (**Supplementary Material S1**, available in the online version).<sup>23</sup>

### Study Design

As part of a larger study investigating the neuroprotective effect of RIPC in newborn piglets following HI ( $n = 54$ ), we randomly selected 10 piglets subjected to HI, 10 piglets subjected to HI treated with RIPC, and 3 sham piglets.<sup>8</sup> All animals from our main study were individually numbered, and the numbers were written down on same-sized paper sheets. For each group, these papers were drawn until all slots were filled. These animals were further evaluated for cerebral immunohistochemical markers including AQP4, caspase-3, Bcl-2, and VEGF.

### Experimental Procedures

We have previously described the experimental procedures.<sup>8</sup> Briefly, piglets were anesthetized with sevoflurane by mask (1–2%). Following intravenous administration of propofol (5 mg/kg), fentanyl (10 µg/kg), and rocuronium (1 mg/kg), the piglets were intubated and mechanically ventilated. Anesthesia was maintained by intravenous infusion of propofol (4–12 mg/kg/h) and fentanyl (10 µg/kg/h). Ventilator settings were adjusted to maintain partial arterial CO<sub>2</sub> pressure between 4.5 and 5.5 kPa. An umbilical artery and the umbilical vein were aseptically cannulated for monitoring of blood pressure, blood sampling, and additional intravenous infusion. Continuous intravenous infusion of 5% dextrose with 0.45% NaCl (5–10 mL/kg/h) was then initiated. Piglets were monitored by pulse oximetry, electrocardiography, and single-channel amplitude-integrated electroencephalography (aEEG). A 45-minute HI insult was initiated by reducing FiO<sub>2</sub> to 4% with a respiratory rate of 16/min. After reaching an upper margin of aEEG <7 µV, the oxygenation was titrated to maintain an amplitude between 3 and 5 µV and to obtain a mean arterial blood pressure (MABP) <70% of baseline for 10 minutes.<sup>24</sup> The HI insult was terminated by resuscitation with 21% oxygen. One hour after the HI insult, the piglets were randomized to either no intervention or RIPC using sealed envelopes in blocks of four to eight animals. The RIPC treatment was induced using plastic strips applied externally around the most proximal part of both hind limbs to obstruct blood circulation. The obstruction of arterial blood flow was verified by absence of flow evaluated by Doppler ultrasound; however, the exact applied pressure was not assessed. Four conditioning cycles of 5-minute ischemia and reperfusion were conducted. The anesthesia was then halted and the piglets were extubated. During the recovery period, each piglet was closely monitored. The piglets received daily antibiotics and were fed every 2 hours. Sham animals only received anesthesia, normoxic positive pressure ventilation, and supportive care. After 72 hours, all piglets were anesthetized again, scanned, and euthanized by a lethal dose of pentobarbital. The brain was lifted from the skull and the right hemisphere was immersed in 4% formaldehyde. After fixation, the hemisphere was cut in coronal blocks of 3 to 4 mm, while the cerebellum was cut in sagittal blocks. All blocks were embedded in paraffin. Sections were

stained with hematoxylin and eosin followed by evaluation and scoring of the histopathology by the grading system of Thoresen et al 1996.<sup>25</sup>

### Immunohistochemistry

In this study, unstained sections of 4 µm were cut from each paraffin block. The immunohistochemical staining was performed using Ventana Benchmark ULTRA slide staining system. The unstained slides were deparaffinized and rehydrated in graded ethanol and distilled water. Heat-induced epitope retrieval was performed in ULTRA CC1 buffer. Sections were incubated at 37°C with the primary antibodies: rabbit monoclonal antiactive caspase-3 (1:25, Abcam, Inc., Cambridge, United Kingdom), mouse monoclonal anti-Bcl-2 (RTU, Ventana Medical Systems, Inc., Tucson, Arizona, United States), rabbit polyclonal anti-AQP4 (1:1500, Santa Cruz Biotechnology, Inc., Santa Cruz, California, United States), and anti-VEGF (1:200, Santa Cruz Biotechnology, Inc., Santa Cruz, California, United States). After incubation, endogenous peroxidase activity was blocked with OptiView Peroxidase inhibitor for 4 minutes at 36°C. Sections were then incubated with secondary and tertiary antibodies (OptiView HQ Universal Linker and OptiView HRP Multimer) both for 8 minutes at 36°C. Staining was visualized using OptiView DAB and OptiView H<sub>2</sub>O<sub>2</sub>. OptiView Copper was used to amplify the signal. All sections were examined using an Olympus BX40 microscope. All tissue sections were examined by an investigator blinded to treatment and clinical course. For cleaved caspase-3, Bcl-2, and VEGF, the frequency of positive cells was evaluated using a semiquantitative scale ranging from 0 to 100% with fixed 10% intervals to assess the relative number of positive cells in each region of interest. For each region, the frequency of immunoreactive cells was evaluated in five nonoverlapping fields of view at ×40 magnification and averaged. We chose these smaller 10% intervals based on pilot studies indicating that evaluation of group-specific differences would prove difficult using wider intervals, as the majority of samples would receive the same frequency score.<sup>26</sup> For AQP4, the immunoreactivity was examined according to intensity due to a complex expression pattern that made cell-counting impossible. We used a semiquantitative scale ranging from 1 to 5.<sup>27</sup> All areas of the stained regions were evaluated. The scores represent the predominant staining intensity found in each region.

### Experimental Outcomes

Six regions of interest were selected for immunohistochemical analyses as follows: (1) cerebral cortex, (2) basal ganglia, (3) thalamus, (4) hippocampus, (5) cerebellum, and (6) white matter (posterior limb of internal capsule). Grades from each region were compiled into whole brain scores. The whole brain scores were correlated with the histopathological scores by hematoxylin and eosin staining reported in our previous study.<sup>8</sup>

### Statistical Methods

Three-group comparisons were analyzed by one-way analysis of variance (ANOVA) followed by Fisher's Least Significant

Difference test, while two-group comparisons were analyzed by Student's *t*-test. Nonnormally distributed data were analyzed by Kruskal–Wallis test or Mann–Whitney test. Parametric data are presented as mean values with standard deviations, while nonparametric data are presented as median values with 2.5 and 97.5 percentiles. Categorical data were analyzed by Chi-square test and presented as *n* (%). Spearman's correlation was used to investigate the correlation between the immunohistochemical markers and the histopathological scores reported in our previous study.<sup>8</sup> A two-sided *p*-value less than 0.05 was considered statistically significant. All statistical analyses were performed using Stata 13 (StataCorp. 2013. Stata Statistical Software: Release 13. College Station, Texas, United States: StataCorp LP) and GraphPad Prism 8 (GraphPad Prism version 8.4.2 for macOS, GraphPad Software, La Jolla, California, United States).

## Results

### Mortality and Baseline Data

The animals were of either sex, less than 25 hours of age, and weighing between 800 and 2,500 g.

Immunohistochemical analyses were performed on all included animals (*n* = 23). For animals who deteriorated before 72 hours, brain tissue was fixated at time of death. Three piglets subjected to HI alone were euthanized prior to 72 hours, while four piglets treated with RIPPC were euthanized prior to 72 hours. All piglets were euthanized between 48 and 72 hours after HI. None of the sham piglets died. Euthanasia was performed due to no return of spontaneous breathing after resuscitation. ► **Table 1** shows the descriptive data of the piglets in each group. The groups were similar with regard to baseline and end-hypoxia values. However, we observed a difference in age. The insult severity between the two HI groups was also similar with respect to the duration of aEEG < 7 µV. However, piglets subjected to HI alone had a longer duration of MABP < 70% of baseline.

### Immunohistochemistry

Immunohistochemical stains with examples of different gradings in the cerebellum and the hippocampal CA3 are provided in ► **Figs. 1 and 2**.

### Aquaporin 4

We detected AQP4 immunoreactivity in the cytoplasm of ependymal cells but particularly in astrocytic end-feet processes around blood vessels and at the pial surface. We found no immunoreactivity in any types of neurons in any regions of interest. In the cerebellum, AQP4 was observed in Bergmann's glial cells, the molecular layer, the granular cell layer, and the white matter. In the cerebral cortex, AQP4 was detected in the molecular layer of the neuropile and around blood vessels. A similar pattern was found in the basal ganglia and thalamus. In the hippocampal region, the immunoreactivity was particularly seen in astrocytes and surrounding blood vessels located in the area of the fused molecular layers of the dentate gyrus and the CA3/CA1 region. We found no difference between piglets subjected to HI treated with and

**Table 1** Descriptive data of the piglets randomized to sham, HI alone, and HI with RIPC

Parameters	Sham (n = 3)	HI group (n = 10)	HI + RIPC group (n = 10)	p-Value
General				
Weight (g)	2,067 (404)	1,565 (301)	1,515 (320)	0.05
Age (h)	19.8 (0.8)	20.8 (2.0)	22.9 (1.8)	0.02
Female (n)	1 (33%)	3 (30%)	6 (60%)	0.37
Baseline				
Heart rate (bpm)	136 (25)	149 (33)	138 (17)	0.60
MABP (mm Hg)	–	51 (44–60)	50 (39–71)	0.96
Arterial CO <sub>2</sub> (kPa)	4.8 (–)	5.0 (4.1–5.3)	4.8 (4.5–6.3)	0.91
pH	7.7 (–)	7.5 (7.47–7.54)	7.5 (7.4–7.7)	0.27
Standard base excess (mM)	–	7.6 (5.5–9.0)	7.2 (2.3–12.5)	0.71
Glucose (mM)	4.7 (–)	6.7 (2.7)	6.5 (2.0)	0.73
Lactate (mM)	2.6 (–)	1.8 (1.2–3.0)	3.1 (0.8–5.1)	0.37
HI insult severity				
Duration of aEEG <7μV (min)		38 (6)	38 (7)	0.95
Duration of MABP < 70% baseline (min)		11 (8)	3 (5)	0.03
End of HI insult				
Heart rate (bpm)		176 (38)	195 (35)	0.26
MABP (mm Hg)		51 (18)	55 (23)	0.68
Arterial CO <sub>2</sub> (kPa)		6.0 (4.8–9.1)	5.7 (3.6–22.1)	0.57
pH		7.0 (0.1)	6.9 (0.2)	0.77
Standard base excess (mM)		–18.2 (4.9)	–19.4 (5.2)	0.61
Glucose (mM)		11.9 (3.6)	12.2 (3.0)	0.86
Lactate (mM)		17.6 (3.3)	17.9 (4.2)	0.90

Abbreviations: aEEG, amplitude-integrated electroencephalography; HI, hypoxia–ischemia; MABP, mean arterial blood pressure; RIPC, remote ischemic postconditioning.

Note: Three-group comparisons were analyzed by one-way analysis of variance, while two-group comparisons were analyzed by Student's *t*-test. When nonnormally distributed, data was analyzed by Kruskal–Wallis or Mann–Whitney test. Parametric data are presented as means with standard deviations, while nonparametric data are presented as medians with 2.5–97.5 percentiles. Categorical data were analyzed by Chi-square test and is presented as *n* (%).

without RIPC in any regions of interest or the whole brain (► **Fig. 3**). AQP4 was upregulated in both groups subjected to HI as seen by higher immunostaining intensity compared with sham piglets. We found a statistically significant correlation between the AQP4 immunostaining intensity and the histopathological scores ( $r_s = 0.69$ ; ► **Fig. 4**).

### Caspase-3 and B-Cell Lymphoma 2

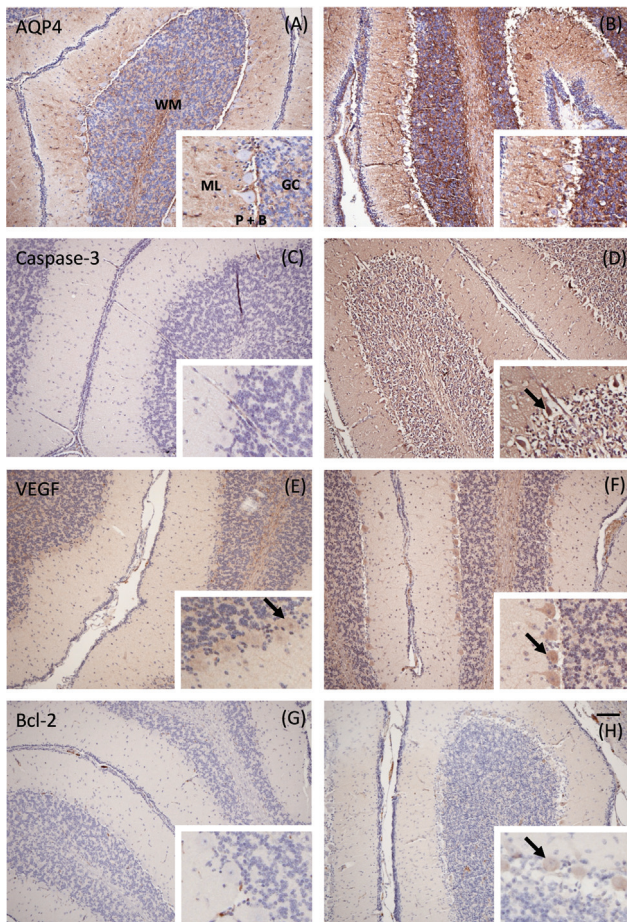
Bcl-2 was expressed in the vascular endothelium and the cytoplasm of various neurons throughout the brain; the Purkinje cells of the cerebellum, pyramidal cells of the cerebral cortex, hippocampal CA1–CA4 pyramidal cells, and neurons in the basal ganglia and thalamic nuclei. Bcl-2 were also faintly expressed in the white matter. Caspase-3 immunoreactivity was found in the cytoplasm of the Purkinje cells in the cerebellum, pyramidal cells of the cerebral cortex, hippocampal CA1–CA4 pyramidal cells, thalamic neurons, and vascular endothelium. We found no immunoreactive cells in the basal ganglia or the white matter. The frequency

of caspase-3 and Bcl-2 positive cells did not differ in any regions of interest or the whole brain when comparing piglets subjected to HI treated with and without RIPC. However, we found an increased expression of caspase-3 in sham piglets compared with both HI groups (► **Fig. 3**). Only Bcl-2 was found to correlate with the histopathological score ( $r_s = 0.51$ ; ► **Fig. 4**).

### Vascular Endothelial Growth Factor

Immunoreactivity was observed in endothelial cells and astrocytes, as well as in the cytoplasm of various neurons, the Purkinje cells of the cerebellum, pyramidal cells of the cerebral cortex, hippocampal CA1–CA4 pyramidal cells, and neurons in the thalamic nuclei. We found no immunoreactive neurons in the basal ganglia. In the white matter, we detected VEGF-positive astrocytes. VEGF immunoreactivity was similar in all regions of interest and the whole brain between sham piglets, piglets subjected to HI, and piglets subjected to HI treated with RIPC (► **Fig. 3**). Furthermore, we



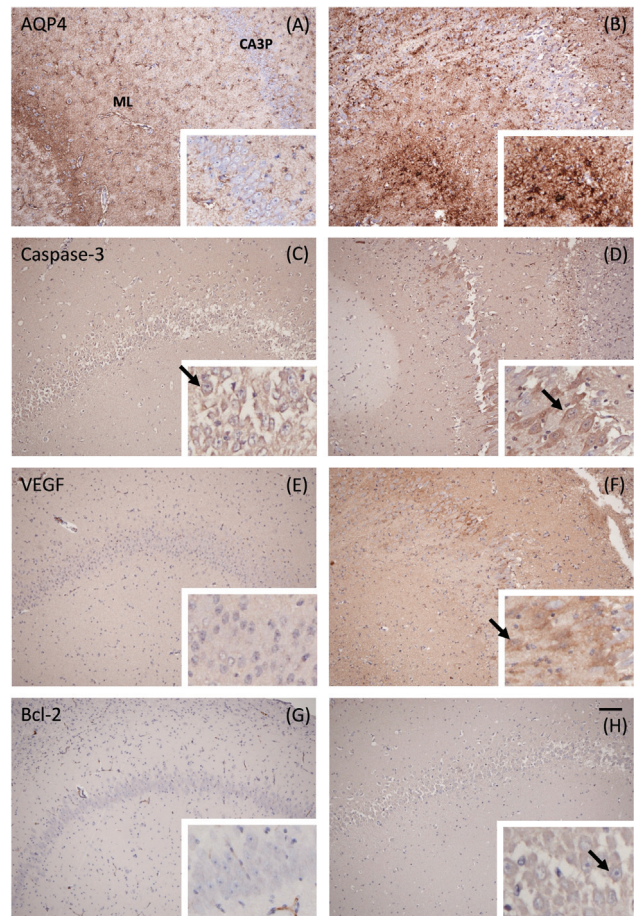


**Fig. 1** Immunohistochemical staining of sections from the cerebellum. (A) Aquaporin 4 (AQP4) staining intensity grade 1. Weak staining of the molecular layer (ML), the granular cell layer (GC), the white matter (WM), and the Bergman's glial cells (B). No staining of Purkinje's cells (P). (B) AQP4 staining intensity grade 5. Intense staining of ML, GC, WM, and B. No staining of P. (C) Caspase-3 staining with a frequency score of 0%. (D) Caspase-3 staining with a frequency score of 50 to 60%. (E) Vascular endothelial growth factor (VEGF) staining with a frequency score of 10 to 20%. (F) VEGF staining with a frequency score of 60 to 70%. (G) B-cell lymphoma 2 (Bcl-2) staining with a frequency score of 0%. (H) Bcl-2 staining with a frequency score of 10 to 20%. Scale-bar = 100  $\mu$ m. The arrows indicate examples of positive cells.

found no correlation between VEGF and the corresponding histopathological score ( $\rightarrow$  Fig. 4).

#### Deceased and Surviving Animals

The expression of AQP4, caspase-3, and Bcl-2 was higher in piglets that died before the 72-hour assessment with mean whole brain scores of 18.5 versus 12.9 ( $p = 0.02$ ), 11.1 versus 3.7 ( $p = 0.01$ ), and 7.6 versus 2.6 ( $p = 0.02$ ), respectively. The expression of VEGF did not differ between piglets with HI who died or survived until 72 hours. As in our primary analysis, no differences between groups were found when excluding deceased animals. Mean whole brain scores of AQP4, caspase-3, Bcl-2, and VEGF between surviving piglets subjected to HI treated with and without RIPC were 14.7 versus 12.7 ( $p = 0.15$ ), 3.3 versus 4.0 ( $p = 0.81$ ), 3.1 versus 2.1 ( $p = 0.33$ ), and 12.7 versus 15.1 ( $p = 0.42$ ), respectively.

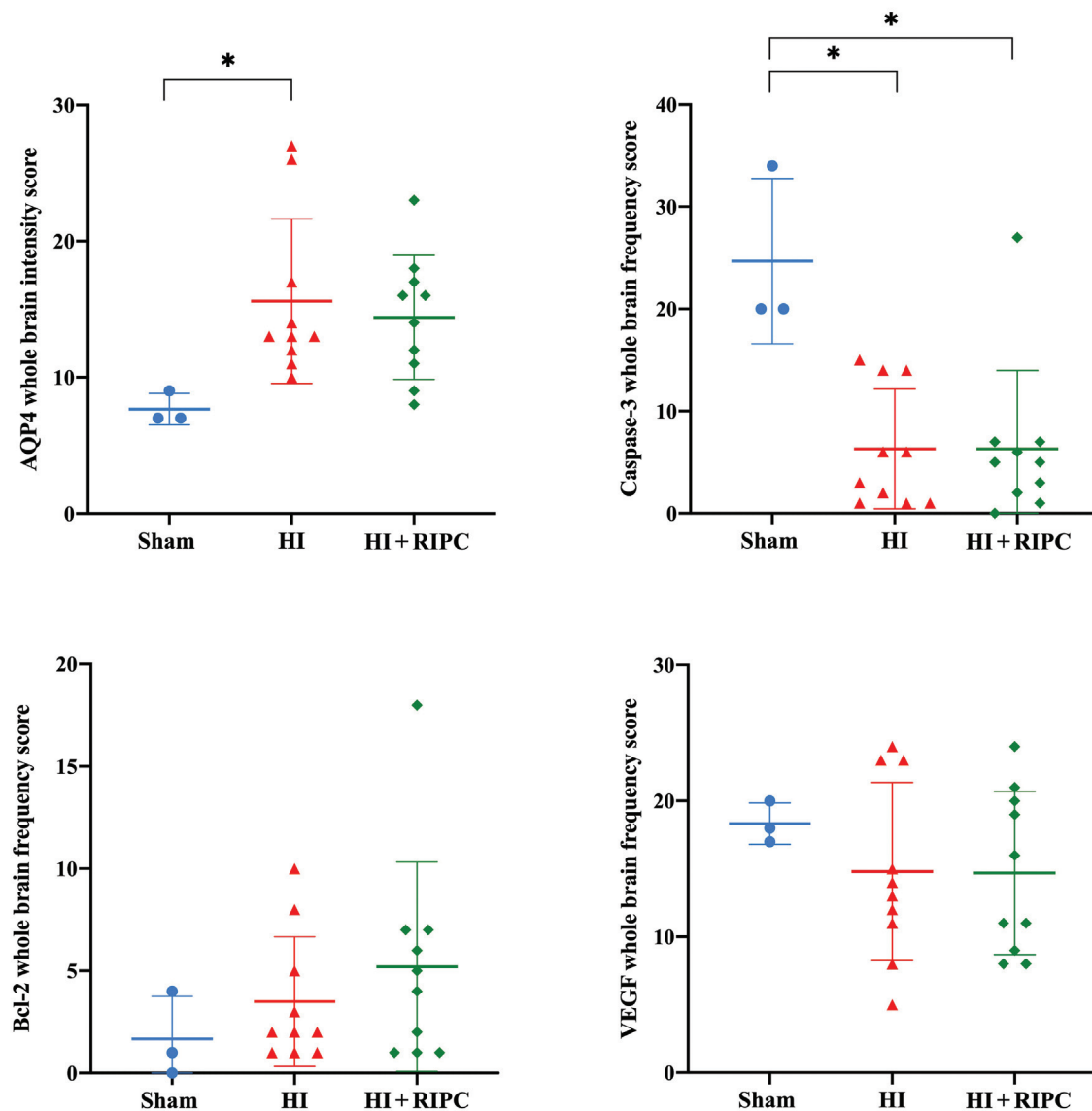


**Fig. 2** Immunohistochemical staining of sections from the hippocampal CA3. (A) Aquaporin (AQP4) staining intensity grade 1. Weak staining of blood vessels and astrocytes, but no staining of CA3 pyramidal cells (CA3P). Moderate staining of the molecular layer (ML). (B) AQP4 staining intensity grade 5. Intense staining of astrocytes in the ML-WM. No neuronal staining of CA3P. (C) Caspase-3 staining with a frequency score of 80 to 90%. (D) Caspase-3 staining with a frequency score of 40 to 50%. (E) Vascular endothelial growth factor (VEGF) staining with a frequency score of 0%. (F) VEGF staining with a frequency score of 30 to 40%. (G) B-cell lymphoma 2 (Bcl-2) staining with a frequency score of 0%. (H) Bcl-2 staining with a frequency score of 80 to 90%. Scale-bar = 100  $\mu$ m. The arrows indicate examples of positive cells.

## Discussion

### Summary of Findings

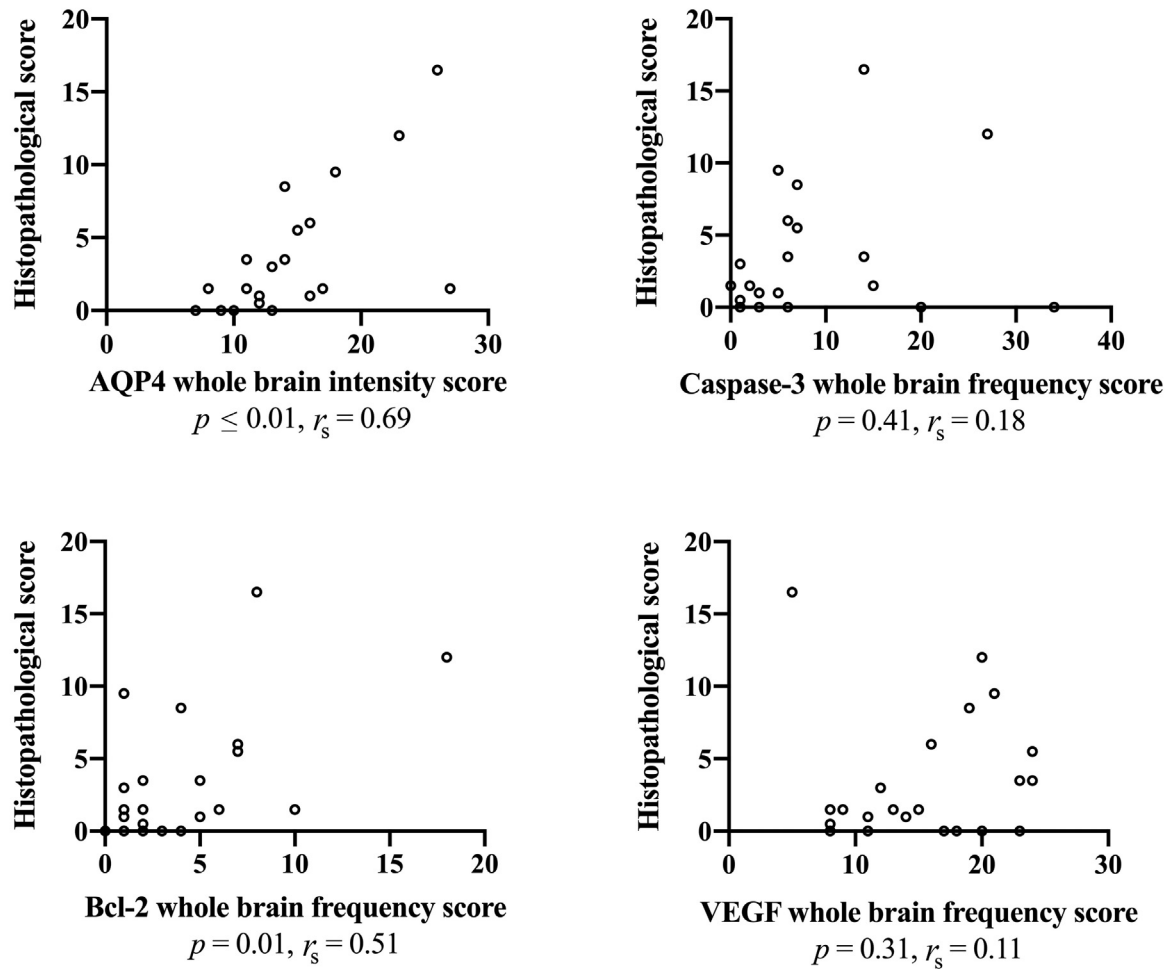
Several animal studies have investigated the neuroprotective effect of RIPC in neonatal HIE.<sup>8,11,28–31</sup> However, with conflicting findings showing effect and lack of effect, it is still uncertain whether RIPC may induce neuroprotection.<sup>7</sup> Therefore, we aimed to further investigate plausible effects of RIPC by cerebral immunohistochemical markers related to edema, apoptosis, and angiogenesis. However, we found no differences in the brain expression of AQP4, caspase-3, Bcl-2, or VEGF when comparing piglets subjected to HI treated with and without RIPC. In our main study, we investigated the apparent diffusion coefficient (ADC) by diffusion-weighted imaging.<sup>8</sup> We found that piglets with HI had lower ADC values compared with sham piglets, which could indicate the presence of brain edema.<sup>8</sup> In the current study, piglets



**Fig. 3** Whole brain scores for aquaporin 4 (AQP4), caspase-3, B-cell lymphoma 2 (Bcl-2), and vascular endothelial growth factor (VEGF). Results on AQP4, caspase-3, Bcl-2, and VEGF are presented for each group; shams, hypoxia–ischemia (HI), and HI and remote ischemic postconditioning (RIPC). The statistical analysis was performed using one-way analysis of variance (ANOVA) followed by Fisher's Least Significant Difference test and presented with mean values and standard deviations. \* indicates statistical significance.

with HI had higher expression of AQP4. Furthermore, we found that higher AQP4 expression was associated with early death and more severe histopathology. Whether this is due to an increased expression of AQP4 between 48 and 72 hours after HI or whether this may be an indication of edema formation, and worse neurological outcome is uncertain. In our main study, we also found similar ADC values in piglets with HI treated with and without RIPC.<sup>8</sup> These results correspond to our current findings of similar AQP4 expression between these two groups. Yu et al found ischemic postconditioning to reduce the AQP4 expression and formation of brain edema from 6 to 24 hours in a rat model of neonatal HIE.<sup>15</sup> However, after 48 hours, they observed similar values between rats treated with and without ischemic postconditioning. As we found RIPC to have no effect on the AQP4 expression at 72 hours, it is possible that the

interesting regulation of the protein expression already happens within the first 24 hours. We found increased Bcl-2 to be associated with early death and increased histopathology. We speculate that increased cell stress may lead to both increased cell death and anticell death activity 72 hours after an HI insult.<sup>32</sup> We found no difference in the expression of caspase-3 and Bcl-2 in piglets treated with and without RIPC. Previous newborn animal studies of HI have found RIPC to reduce neuronal cell death evaluated by terminal deoxynucleotidyl transferase dUTP nick end labeling (TUNEL) staining and expression of the proapoptotic Bcl-2-associated X protein (BAX) protein.<sup>11,29</sup> As for AQP4, we may have failed to elucidate any difference in markers of apoptosis between piglets treated with and without RIPC due to our time of assessment. The expression of caspase-3 has been shown to peak at 24 hours after an HI insult.<sup>33</sup> This may also explain



**Fig. 4** Spearman's correlations between whole brain scores of the immunohistochemical markers and the histopathology. Results are presented for aquaporin-4 (AQP4), caspase-3, B-cell lymphoma 2 (Bcl-2), and vascular endothelial growth factor (VEGF). The histopathological scores were included from the previous study by Kyng et al.<sup>8</sup>

the lack of association between caspase-3 and the histopathological scores. Another limitation of our evaluation of apoptosis is the seemingly increased expression of caspase-3 in sham piglets; animals otherwise expected to have low caspase-3 frequency scores. Sham piglets needed more propofol and fentanyl for sedation and pain relief during reanesthetization, presumably due to their higher metabolism compared with piglets subjected to HI. Propofol may induce caspase-3 activation in the developing brain.<sup>34</sup> Other piglet studies have also indicated that increased caspase-3 expression may not be associated with increased neuronal cell death. Robertson et al found no association between cell death evaluated by TUNEL staining and caspase-3 in their 48-hour HI model.<sup>35</sup> In another study, presenting secondary analyses from different HI models, the authors also unexpectedly found that high brain lactate/N-acetyl-aspartate was associated with cell death but low levels of caspase-3.<sup>36</sup> We found similar expression of VEGF at 72 hours between sham piglets and piglets subjected to HI. This is in contrast to the findings of Huang et al

who showed that VEGF mRNA was upregulated in neonatal rats 72 hours following an HI insult.<sup>37</sup> Furthermore, we found that RIPC had no effect on the brain expression of VEGF. An adult rat study of focal cerebral ischemia found that ischemic postconditioning increased the expression of VEGF.<sup>20</sup> However, the type of conditioning and the animal model limit any comparison to our findings.

### Limitations

Limitations of this study may be the use of immunohistochemistry on tissue sections for measures of protein levels, as semiquantitative ranges, as well as intensity staining, were used.<sup>38,39</sup> Application of other analyses on frozen tissue, such as Western blot and enzyme-linked immunosorbent assay, may have provided more accurate measurement of the protein levels in the tissue, while RNA-sequencing could have provided assessments of the cellular transcriptome. These methods could be considered in future studies for optimal assessment of the protein expression in the experimental newborn brain. Once the protein



levels have been established, immunohistochemistry may be an excellent tool to visualize the expression of proteins in different cell types and brain regions. The use of rabbit and mouse monoclonal antibodies against epitopes from other species may also be problematic and it is difficult to ascertain that the antibodies specifically visualize the same antigens in the piglet tissue. Problems with specificity and cross-reactivity should ideally be ruled out by use of various positive and negative controls. The level of background staining also makes it difficult to assess the specificity of the staining. Both ischemia and poor fixation may increase background staining which further calls for quantitative measures in parallel with immunohistochemistry. Our study would also have benefited from the use of additional immunohistochemical markers for validation of both current findings and previously suggested mechanisms of RIPC including release of endogenous opioids, deactivation of BAX, and reduced nitrosative stress.<sup>28,29</sup> Another limitation of the current study was that animals receiving no intervention had longer duration of MABP <70% of baseline during the HI insult compared with animals treated with RIPC. This may have resulted in an overestimation of a potential treatment effect. However, in additional analyses, we found no correlation between duration of low blood pressure and protein expression the whole brain (**Supplementary Material S2**, available in the online version). Also, the association between treatment group and protein expression remained unchanged following adjustment of the duration by linear regression (data not shown). Finally, we found no difference in insult severity between piglets by duration of aEEG suppression. Furthermore, though not statistically significant, the random selection of piglets for this study resulted in an uneven sex distribution with twice as many female animals in the HI group treated with RIPC. As males and females may respond differently to HI and treatment, this may also have affected our results.<sup>40</sup> However, as above, the association between treatment group and protein expression in the whole brain remained unchanged after adjustment for sex (data not shown). All three groups of piglets received fentanyl during the course of the experiment. As RIPC has been suggested to exert neuroprotection through the opioid receptor/Akt signal pathway, the potential effect of RIPC may have been diminished or abolished by the fentanyl treatment.<sup>29</sup> In keeping with our primary aim, to compare neurological outcomes in piglets that were subjected to HI treated with and without RIPC, we only included three sham animals as a proof-of-concept. We believed that three sham piglets would be sufficient to illustrate the level of the immunohistochemical markers in animals exposed only to anesthetics and mechanical ventilation. While the variations in the sham piglets were much less than in those subjected to HI, a larger number could have provided even more precise estimates. At last, several experimental studies of RIPC in neonatal HIE have used 10 minutes of remote ischemia followed by 10 minutes of reperfusion in four cycles.<sup>11,28,29</sup> We can only speculate whether increased cycle duration and number of cycles would have revealed different results.

## Conclusion

We found no effects compatible with neuroprotection by RIPC in our newborn piglet model of HIE when investigating the brain expression of AQP4, caspase-3, Bcl-2, and VEGF as markers related to edema, apoptosis, and angiogenesis. This is consistent with findings of limited neuroprotective effect in our main study, where we found an association between RIPC and more favorable brain lactate/N-acetyl-aspartate, but no association with other neurological measures including histopathology and functional assessment. Our results may have been affected by timing of assessment, use of fentanyl as pain relief and anesthetic, or limitations related to the immunohistochemical methods.

## Funding

The study was supported by the Aase and Ejnar Danielsens Foundations, The Health Research Foundation of Central Denmark Region, Aarhus University Research Foundation, Randers Regional Hospital, and The Elsass Foundation.

## Conflict of Interest

None declared.

## Acknowledgment

The authors would like to acknowledge the staff at the animal facilities at the Department of Clinical Medicine at Aarhus University Hospital, Aarhus, Denmark.

## References

- 1 Lee AC, Kozuki N, Blencowe H, et al. Intrapartum-related neonatal encephalopathy incidence and impairment at regional and global levels for 2010 with trends from 1990. *Pediatr Res* 2013;74 (Suppl 1):50–72
- 2 Kurinczuk JJ, White-Koning M, Badawi N. Epidemiology of neonatal encephalopathy and hypoxic-ischaemic encephalopathy. *Early Hum Dev* 2010;86(06):329–338
- 3 Jacobs SE, Berg M, Hunt R, Tarnow-Mordi WO, Inder TE, Davis PG. Cooling for newborns with hypoxic ischaemic encephalopathy. *Cochrane Database Syst Rev* 2013;(01):CD003311
- 4 Edwards AD, Brocklehurst P, Gunn AJ, et al. Neurological outcomes at 18 months of age after moderate hypothermia for perinatal hypoxic ischaemic encephalopathy: synthesis and meta-analysis of trial data. *BMJ* 2010;340:c363
- 5 Pauliah SS, Shankaran S, Wade A, Cady EB, Thayyil S. Therapeutic hypothermia for neonatal encephalopathy in low- and middle-income countries: a systematic review and meta-analysis. *PLoS One* 2013;8(03):e58834
- 6 Thayyil S, Pant S, Montaldo P, et al; HELIX consortium. Hypothermia for moderate or severe neonatal encephalopathy in low-income and middle-income countries (HELIX): a randomised controlled trial in India, Sri Lanka, and Bangladesh. *Lancet Glob Health* 2021;9(09):e1273–e1285
- 7 Andelius TCK, Henriksen TB, Kousholt BS, Kyng KJ. Remote ischemic postconditioning for neuroprotection after newborn hypoxia-ischemia: systematic review of preclinical studies. *Pediatr Res* 2022;91(07):1654–1661
- 8 Kyng KJ, Kerrn-Jespersen S, Bennedsgaard K, et al. Short-term outcomes of remote ischemic postconditioning 1 h after perinatal hypoxia-ischemia in term piglets. *Pediatr Res* 2021;89(01):150–156



- 9 Thayyil S, Chandrasekaran M, Taylor A, et al. Cerebral magnetic resonance biomarkers in neonatal encephalopathy: a meta-analysis. *Pediatrics* 2010;125(02):e382–e395
- 10 Lally PJ, Montaldo P, Oliveira V, et al; MARBLE consortium. Magnetic resonance spectroscopy assessment of brain injury after moderate hypothermia in neonatal encephalopathy: a prospective multicentre cohort study. *Lancet Neurol* 2019;18(01):35–45
- 11 Ezzati M, Bainbridge A, Broad KD, et al. Immediate remote ischemic postconditioning after hypoxia ischemia in piglets protects cerebral white matter but not grey matter. *J Cereb Blood Flow Metab* 2016;36(08):1396–1411
- 12 Ferrari DC, Nesic O, Perez-Polo JR. Perspectives on neonatal hypoxia/ischemia-induced edema formation. *Neurochem Res* 2010;35(12):1957–1965
- 13 Northington FJ, Chavez-Valdez R, Martin LJ. Neuronal cell death in neonatal hypoxia-ischemia. *Ann Neurol* 2011;69(05):743–758
- 14 Yan F, Zhang M, Meng Y, et al. Erythropoietin improves hypoxic-ischemic encephalopathy in neonatal rats after short-term anoxia by enhancing angiogenesis. *Brain Res* 2016;1651:104–113
- 15 Yu L, Fan SJ, Liu L, et al. Effect of ischemic postconditioning on cerebral edema and the AQP4 expression following hypoxic-ischemic brain damage in neonatal rats. *World J Pediatr* 2015;11(02):165–170
- 16 Han D, Sun M, He PP, Wen LL, Zhang H, Feng J. Ischemic postconditioning alleviates brain edema after focal cerebral ischemia reperfusion in rats through down-regulation of aquaporin-4. *J Mol Neurosci* 2015;56(03):722–729
- 17 Li S, Hu X, Zhang M, et al. Remote ischemic post-conditioning improves neurological function by AQP4 down-regulation in astrocytes. *Behav Brain Res* 2015;289:1–8
- 18 Zhang W, Wang B, Zhou S, Qiu Y. The effect of ischemic postconditioning on hippocampal cell apoptosis following global brain ischemia in rats. *J Clin Neurosci* 2012;19(04):570–573
- 19 Xing B, Chen H, Zhang M, et al. Ischemic postconditioning inhibits apoptosis after focal cerebral ischemia/reperfusion injury in the rat. *Stroke* 2008;39(08):2362–2369
- 20 Esposito E, Hayakawa K, Ahn BJ, et al. Effects of ischemic postconditioning on neuronal VEGF regulation and microglial polarization in a rat model of focal cerebral ischemia. *J Neurochem* 2018;146(02):160–172
- 21 Zhu T, Zhan L, Liang D, et al. Hypoxia-inducible factor 1 $\alpha$  mediates neuroprotection of hypoxic postconditioning against global cerebral ischemia. *J Neuropathol Exp Neurol* 2014;73(10):975–986
- 22 Adstamamongkonkul D, Hess DC. Ischemic Conditioning and neonatal hypoxic ischemic encephalopathy: a literature review. *Cond Med* 2017;1(01):9–16
- 23 Kilkenny C, Browne WJ, Cuthill IC, Emerson M, Altman DG. Improving bioscience research reporting: the ARRIVE guidelines for improving animal research. *PLoS Biol* 2010;8(06):e1000412
- 24 Kyng KJ, Skajaa T, Kerrn-Jespersen S, Andreassen CS, Benneds-gaard K, Henriksen TB. A piglet model of neonatal hypoxic-ischemic encephalopathy. *J Vis Exp* 2015;e52454(99):e52454
- 25 Thoresen M, Haaland K, Løberg EM, et al. A piglet survival model of posthypoxic encephalopathy. *Pediatr Res* 1996;40(05):738–748
- 26 Takeuchi K, Ogata S, Nakanishi K, et al. LAT1 expression in non-small-cell lung carcinomas: analyses by semiquantitative reverse transcription-PCR (237 cases) and immunohistochemistry (295 cases). *Lung Cancer* 2010;68(01):58–65
- 27 Bösmüller H, Fischer A, Pham DL, et al. Detection of the BRAF V600E mutation in serous ovarian tumors: a comparative analysis of immunohistochemistry with a mutation-specific monoclonal antibody and allele-specific PCR. *Hum Pathol* 2013;44(03):329–335
- 28 Rocha-Ferreira E, Rudge B, Hughes MP, Rahim AA, Hristova M, Robertson NJ. Immediate remote ischemic postconditioning reduces brain nitrotyrosine formation in a piglet asphyxia model. *Oxid Med Cell Longev* 2016;2016:5763743
- 29 Zhou Y, Fathali N, Lekic T, et al. Remote limb ischemic postconditioning protects against neonatal hypoxic-ischemic brain injury in rat pups by the opioid receptor/Akt pathway. *Stroke* 2011;42(02):439–444
- 30 Drunalini Perera PN, Hu Q, Tang J, et al. Delayed remote ischemic postconditioning improves long term sensory motor deficits in a neonatal hypoxic ischemic rat model. *PLoS One* 2014;9(02):e90258
- 31 Andelius TCK, Pedersen MV, Andersen HB, et al. No added neuro-protective effect of remote ischemic postconditioning and therapeutic hypothermia after mild hypoxia-ischemia in a piglet model. *Front Pediatr* 2020;8:299
- 32 Banasiak KJ, Cronin T, Haddad GG. bcl-2 prolongs neuronal survival during hypoxia-induced apoptosis. *Brain Res Mol Brain Res* 1999;72(02):214–225
- 33 Wang X, Karlsson JO, Zhu C, Bahr BA, Hagberg H, Blomgren K. Caspase-3 activation after neonatal rat cerebral hypoxia-ischemia. *Biol Neonate* 2001;79(3,4):172–179
- 34 Konno A, Nishimura A, Nakamura S, et al. Continuous monitoring of caspase-3 activation induced by propofol in developing mouse brain. *Int J Dev Neurosci* 2016;51:42–49
- 35 Robertson NJ, Martinello K, Lingam I, et al. Melatonin as an adjunct to therapeutic hypothermia in a piglet model of neonatal encephalopathy: a translational study. *Neurobiol Dis* 2019;121:240–251
- 36 Pang R, Martinello KA, Meehan C, et al. Proton magnetic resonance spectroscopy lactate/N-acetylaspartate within 48 h predicts cell death following varied neuroprotective interventions in a piglet model of hypoxia-ischemia with and without inflammation-sensitization. *Front Neurol* 2020;11(883):883
- 37 Huang YF, Zhuang SQ, Chen DP, Liang YJ, Li XY. Angiogenesis and its regulatory factors in brain tissue of neonatal rat hypoxic-ischemic encephalopathy [in Chinese]. *Zhonghua Er Ke Za Zhi* 2004;42(03):210–214
- 38 Beach TG, Tago H, Nagai T, Kimura H, McGeer PL, McGeer EG. Perfusion-fixation of the human brain for immunohistochemistry: comparison with immersion-fixation. *J Neurosci Methods* 1987;19(03):183–192
- 39 Hilbig H, Bidmon HJ, Oppermann OT, Remmerbach T. Influence of post-mortem delay and storage temperature on the immunohistochemical detection of antigens in the CNS of mice. *Exp Toxicol Pathol* 2004;56(03):159–171
- 40 Smith AL, Alexander M, Rosenkrantz TS, Sadek ML, Fitch RH. Sex differences in behavioral outcome following neonatal hypoxia ischemia: insights from a clinical meta-analysis and a rodent model of induced hypoxic ischemic brain injury. *Exp Neurol* 2014;254:54–67