

# Novel Therapeutic Agents for Rare Diseases of Calcium and Phosphate Metabolism

## Authors

Afroditi Roumpou<sup>1, 2</sup> , Maria P. Yavropoulou<sup>3</sup>, Efstathios Chronopoulos<sup>2</sup>, Eva Kassi<sup>2, 3, 4</sup>

## Affiliations

- 1 Division of Endocrinology, Metabolism and Diabetes, First Department of Pediatrics, “Aghia Sofia” Children’s Hospital, National and Kapodistrian University of Athens School of Medicine, Athens, Greece
- 2 Laboratory for Research of the Musculoskeletal System, National and Kapodistrian University of Athens School of Medicine, Athens, Greece
- 3 Centre of Expertise for Rare Endocrine Diseases, C.E.R.E.D. Disorders of Calcium & Phosphate Metabolism, First Department of Propaedeutic and Internal Medicine, Laiko Hospital, National and Kapodistrian University of Athens School of Medicine, Athens, Greece
- 4 Department of Biological Chemistry, National and Kapodistrian University of Athens, Athens, Greece

## Key words

asfotase alfa, burosumab, X-linked hypophosphatemia, tumor-induced osteomalacia, hypophosphatasia, FGF 23

received 06.05.2022

accepted after revision 24.07.2022

published online 01.09.2022

## Bibliography

Horm Metab Res 2022; 54: 645–657

DOI 10.1055/a-1917-0519

ISSN 0018-5043

© 2022. Thieme. All rights reserved.

Georg Thieme Verlag, Rüdigerstraße 14,  
70469 Stuttgart, Germany

## Correspondence

Dr. Afroditi Roumpou  
National and Kapodistrian University of Athens  
Division of Endocrinology, Metabolism and Diabetes, First  
Department of Pediatrics  
Thivon 1  
11527 Athens  
Greece  
Tel.: 00302132013000  
afroditiroum@gmail.com

## ABSTRACT

The last decade has been revolutionary regarding the management of rare bone diseases caused by impaired calcium and phosphate metabolism. Elucidation of the underlying genetic basis and pathophysiologic alterations has been the determinant factor for the development of new, disease-specific treatment agents. The phosphaturic hormone Fibroblast Growth Factor 23 (FGF23) possesses a critical role in the pathogenesis of various hypophosphatemic disorders. Among them, the genetic disorder of X-linked hypophosphatemia and the acquired syndrome of tumor-induced osteomalacia, although very rare, have attracted the scientific community’s attention towards designing an FGF23-inhibitor as a potential specific therapy. The monoclonal antibody burosumab was approved for the treatment of children and adult patients with X-linked hypophosphatemia and recently for tumor-induced osteomalacia patients, demonstrating benefits regarding their symptoms, biochemical profile and bone mineralization status. Asfotase alfa is a hydroxyapatite-targeted recombinant alkaline phosphatase, an enzymatic replacement therapy, substituting the defective activity of tissue non-specific alkaline phosphatase, in patients suffering from hypophosphatasia. Promising data regarding its favorable effect on survival rate, bone quality, fracture healing, muscle strength, mobility, respiratory function, and general quality of life have led to the approval of the drug for the treatment of childhood-onset hypophosphatasia. Given the high costs of treatment for both agents and their limited clinical use until now, more data are needed to define patients’ characteristics that make them ideal candidates for therapy. Long-term safety issues also need to be clarified.

## Introduction

Clarification of core pathways and discovery of new central molecules in the pathophysiology of rare bone disorders of impaired mineral metabolism have triggered the development of novel, targeted therapies. The recent approval of new drugs is promising for the outcome of severely affected patients. The phosphaturic hormone Fibroblast Growth Factor 23 (FGF23) was found to have critical role in the pathogenesis of various rare hypophosphatemic disorders, including the genetic disorder of X-linked Hypophosphatemia (XLH) and the acquired syndrome of Tumor-Induced Osteomalacia (TIO). Burosumab, a monoclonal antibody against FGF23, was approved as the first specific treatment for children and adult patients with XLH, and recently for TIO patients.

Asfotase alfa is another groundbreaking drug, and the first enzymatic replacement therapy. It substitutes, in a bone-specific manner, the decreased activity of Tissue Nonspecific Alkaline Phosphatase (TNSALP), that is responsible for the multisystemic disorder of hypophosphatasia. Its favorable effect on the course and complications of the disease has led to the approval of the drug for the treatment of childhood-onset HPP. However, more data are needed to ensure long-term safety and cost-efficacy of these agents. Herein, we concisely present the pathophysiology and the therapeutic options of the two rare disorders of mineral metabolism, focusing on the new FDA-approved drugs that add important medical value for their treatment.

### FGF23 and its role in bone metabolism

Phosphate is, following calcium, the second more abundant mineral in the human body. Approximately 85 % of phosphate is stored in bone (hydroxyapatite crystals), 15 % in the intracellular space (phospholipids, nucleic acids, high-energy nucleotides, signaling) and less than 1 % of phosphate is found in the extracellular fluid as inorganic phosphate (Pi) [1]. Extracellular phosphate levels are regulated by hormones, such as parathyroid hormone (PTH), calcitriol [1,25(OH)<sub>2</sub>D], and FGF23, which balance intestinal absorption and urinal excretion of phosphate according to dietary intake (► Fig. 1).

Sodium/phosphate cotransporters (NaPi cotransporters) stimulate phosphate reabsorption, both in renal and small intestinal cells. They are responsible for reabsorption of about 80–90 % of the phosphate filtered from glomeruli [2]. Type IIa and IIc are found in the brush border membrane of renal proximal tubular cells, and type IIb and III (pit-1, pit-2) are located in the brush border membrane of intestinal cells. Their expression is regulated by dietary phosphate intake and hormones, such as FGF23, PTH and calcitriol. Rise in extracellular phosphate, PTH and FGF23 reduce the expression of renal cotransporters, promoting phosphate excretion, whereas calcitriol and decrease in extracellular phosphate enhance the expression of intestinal cotransporters, increasing phosphate reabsorption [1, 2].

FGF23 is a phosphaturic hormone produced in bone, and mainly in osteocytes. It is transcribed and translated as an inactive, peptide of 251 amino acids. The cleavage of the first 24 amino acids (signal peptide) gives rise to the active form (intact FGF23). This peptide can be further cleaved into inactive C- and N-terminal fragments [3]. For its action, it binds to a receptor complex, which consists of Fibroblast Growth Factor Receptor 1 (FGFR1) and the co-re-

ceptor Klotho, thus activating intracellular signaling pathways like Extracellular signal-regulated kinase pathway (ERK) [2]. By down-regulating the expression of CYP27B1, which encodes 25-hydroxyvitamin D-1 $\alpha$ -hydroxylase, and upregulating the expression of CYP24A1, which encodes 25-hydroxyvitamin D-24-hydroxylase, FGF23 suppresses the production of 1,25(OH)<sub>2</sub>D in renal proximal tubules. In conclusion, FGF23 can cause hypophosphatemia directly via renal phosphate wasting and indirectly through decreasing circulating levels of calcitriol [1, 4].

### FGF23-related diseases and FGF23 inhibition as a new therapeutic option

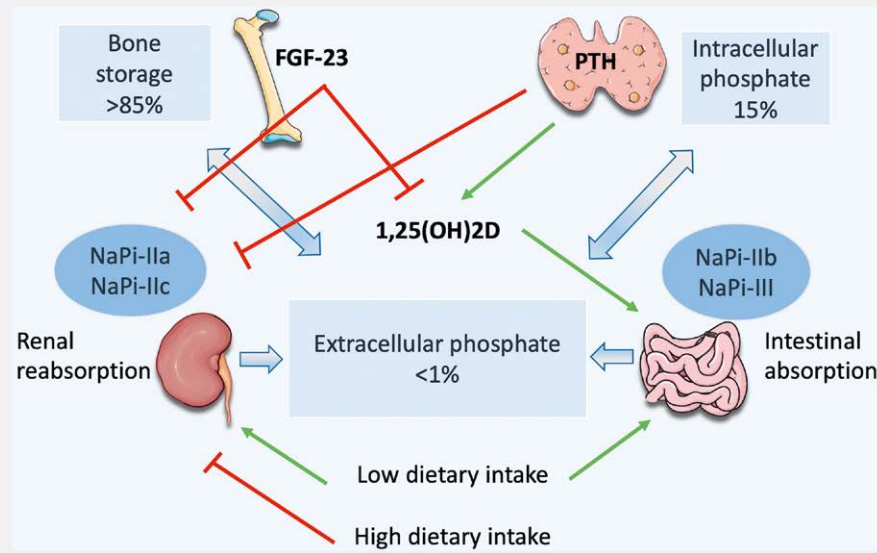
Rickets is a metabolic disease affecting the growing bone in children and adolescents. The underlying defective bone mineralization may be induced by calcium, phosphate and/or vitamin D deficiency. Nutritional vitamin D deficiency is the leading cause of rickets, whereas hereditary forms are rare, accounting for about 13 % of all cases [5].

Hereditary hypophosphatemic rickets is a group of rare disorders, associated with renal phosphate wasting and subsequent hypophosphatemia and bone mineralization defects, such as rickets and osteomalacia. A variety of genetic disorders affecting phosphatonins or phosphate co-transporters are responsible for decreased renal tubular phosphate reabsorption or transport, resulting to hypophosphatemia with normal serum calcium. Serum FGF23 levels may be elevated in some of these genetic defects (FGF23-related or -dependent Hypophosphatemic rickets), while others do not affect serum FGF23 levels (FGF23-independent Hypophosphatemic rickets). Among genetic FGF23-related disorders, X-linked hypophosphatemia results from inactivating mutations in the PHEX gene and is the most prevalent form [1]. On the other hand, Tumor-induced osteomalacia and hypophosphatemia following intravenous iron infusion account for the majority of acquired cases of FGF23-related hypophosphatemia [1]. The spectrum of genetic hypophosphatemic disorders, the affected gene and protein encoded, along with the laboratory characteristics of each disorder are summarized in ► Table 1.

FGF23 levels seem to be a useful tool for the discrimination of hypophosphatemic rickets disorders. The diagnosis of FGF23-related hypophosphatemia may be suspected if a patient with rickets appears with chronic hypophosphatemia and inappropriately elevated serum FGF23 levels. In contrast to what is observed in FGF23-related hypophosphatemic diseases, chronic hypophosphatemia of other causes suppresses FGF23 production (► Table 1).

### X-linked hypophosphatemia (XLH)

XLH is a rare metabolic disorder, with an incidence of approximately 1:20 000 in USA [1], and is the most common cause of genetic hypophosphatemic rickets [2]. The responsible genetic disorder is a mutated, inactivated PHEX gene (phosphate-regulating gene with Homology to Endopeptidases that maps to the X chromosome), which is expressed mainly in bone and teeth [2], and results in FGF23 excess. How exactly PHEX regulates FGF23 levels remains unclear [4]. There have been reported over 300 PHEX mutations causing the disease, the majority of which are inherited, but some of them can arise de novo [1]. FGF23 excess leads to lifelong phosphate wasting, by inhibiting phosphate renal and intestinal reab-



► **Fig. 1** Interactions of FGF-23, PTH, and calcitriol in the regulation of extracellular phosphate levels. PTH, produced by parathyroid cells, and FGF23, produced by osteocytes, suppress proximal tubular phosphate reabsorption by reducing the expression of type IIa and IIc sodium/phosphate cotransporters (NaPi-IIa, NaPi-IIc). PTH increases and FGF23 decreases 1,25(OH)<sub>2</sub>D levels. 1,25(OH)<sub>2</sub>D stimulates sodium-dependent intestinal phosphate absorption by enhancing the expression of type IIb and III sodium/phosphate cotransporters (NaPi-IIb, III). Dietary phosphate intake regulates the expression of these cotransporters as well: low dietary intake enhances renal and intestinal phosphate reabsorption, whereas high dietary intake inhibits renal phosphate reabsorption.

sorption, due to blockage of renal NaPi-II cotransporters and suppression of 1,25-dihydroxyvitamin D levels, respectively. PHEX inactivation also appears to interfere with the metabolism of some bone extracellular matrix proteins (e. g., osteopontin, bone sialoprotein, dentin matrix protein 1). Abnormal metabolism of these proteins gives rise to fragments called ASARM (acidic serine aspartate-rich MEPE associated motifs) peptides, which impede bone mineralization and cause phosphate wasting [4, 6, 7]. The consequent rickets or osteomalacia are the most common clinical findings of XLH, and they are usually present early in childhood. Especially in children, common clinical features include lower extremities deformities, disproportion, short stature, motor delay, musculoskeletal pain and stiffness. Enthesopathies, arthropathies, fractures and pseudofractures cause chronic pain in adult patients and reduce their quality of life. Other symptoms may include dental complications, such as recurrent root abscesses, and hearing loss [1, 8, 9]. A patient with rickets/osteomalacia, chronic hypophosphatemia and elevated serum FGF23 levels raises the suspicion of XLH, even without positive family history or genetic testing [1].

According to the pathophysiology of the hypophosphatemic FGF23-related diseases, hypophosphatemia, hyperphosphaturia, high ALP, high or high normal serum levels of FGF23 and low or low normal levels of 1,25(OH)<sub>2</sub>D are recognized as the most common laboratory findings [1, 2]. Normally, chronic hypophosphatemia should suppress FGF23 expression. Therefore, high or inappropriately normal serum FGF23 levels provides a useful serological tool for discriminating FGF23-related hypophosphatemic rickets from hypophosphatemia of other causes.

There are numerous methods to measure serum FGF23, including intact enzyme-linked immunosorbent assay (intact ELISA), ELISA C-terminal assay, and automated chemiluminescent enzyme immunoassay (CLEIA). The intact assay measures the biologically active FGF23, using two monoclonal antibodies, one directed to the N-terminal domain and the other one to the C-terminal domain. The C-terminal assay detects both intact and fragmented FGF23, using two kinds of antibodies that bind to different epitopes of C-terminal portion and is considered to reflect the amount of FGF23 transcription or translation [3]. CLEIA assay measures full-length FGF23. The disadvantage of C-terminal and CLEIA assay is that the antibodies detect C-terminus of the molecule and the whole molecule, respectively, therefore they both do not discriminate between the biologically inactive and the intact FGF23 molecule. In contrast, the intact FGF23 assay measures only the biologically active intact molecule [10]. However, both intact and C-terminal assay may be useful, and they generally correlate well, except from cases where the processing of FGF23 is accelerated.

An intact serum FGF23 with cut-off value of 30 pg/ml has been proposed to rise the suspicion of FGF23-related disease [2], and values greater than 45 pg/ml are considered pathological [11]. Regarding the evaluation of phosphate excretion, tubular reabsorption of phosphate must be estimated, by calculating the maximum threshold of phosphate tubular reabsorption, corrected for glomerular filtration rate (TmP/GFR). Values <0.82 are considered to indicate hyperphosphaturia [11].

► **Table 1** Genetically-induced syndromes of Hypophosphatemic Rickets.

FGF23-related hypophosphatemic disorders						
Disorder	Gene/protein	Laboratory findings				
		FGF23	TmP/GFR/ Urinary Ca/creatinine	Serum Ca/P	ALP/PTH	1,25(OH) <sub>2</sub> D
X-linked dominant hypophosphatemic rickets	PHEX/Phosphate regulating endopeptidase	↑, n.c.	↓/n.c.	n.c./↓	↑/↑, n.c.	n.c., ↓
Autosomal dominant hypophosphatemic rickets	FGF23/Fibroblast growth factor 23	↑, n.c.	↓/n.c.	n.c./↓	↑/↑, n.c.	n.c., ↓
Autosomal recessive hypophosphatemic rickets Type 1	DMP1/Dentin matrix acidic phosphoprotein 1	↑, n.c.	↓/n.c.	n.c./↓	↑/↑, n.c.	n.c., ↓
Autosomal recessive hypophosphatemic rickets Type 2	ENPP1/Ectonucleotide pyrophosphatase/ phosphodiesterase 1	↑, n.c.	↓/n.c.	n.c./↓	↑/↑, n.c.	n.c., ↓
Hypophosphatemic rickets with hyperparathyroidism	KL/a-Klotho	↑	↓/n.c.	n.c., ↓/↑	↑/↑	n.c.
Osteoglophonic dysplasia	FGFR1/Fibroblast growth factor receptor 1	↑, n.c.	↓, n.c./n.c.	n.c./↓, n.c.	↑, n.c./↑, n.c.	n.c., ↓
McCune-Albright Syndrome	GNAS/Guanine nucleotide binding protein alpha	↑, n.c.	↓, n.c./n.c.	n.c./↓, n.c.	↑, n.c./↑, n.c.	n.c., ↓
Raine Syndrome	FAM20C/Family with sequence similarity 20, member c	↑, n.c.	↓, n.c./n.c.	n.c./↓, n.c.	↑, n.c./↑, n.c.	n.c., ↓
Opsismodysplasia	INPP1/Inositol polyphosphate phosphatase-like 1	↑, n.c.	↓, n.c./n.c.	n.c./↓, n.c.	↑, n.c./↑, n.c.	n.c., ↓
FGF23-independent hypophosphatemic disorders						
Hereditary hypophosphatemic rickets with hypercalciuria	SLC34A3/Sodium-dependent phosphate transport protein 2C	↓, n.c.	↓/↑	n.c./↓	↑, n.c./n.c.	↑
Hypophosphatemic rickets with nephrolithiasis and osteoporosis type 1	SLC34A1/Sodium-dependent phosphatase transport protein 2A	↓, n.c.	↓/↑	n.c., ↓/↑	↑, n.c./↓, n.c.	↑
Hypophosphatemic rickets with nephrolithiasis and osteoporosis type 2	SLC9A3R1/Sodium-hydrogen exchanger regulatory factor 1	↓, n.c.	↓/↑	n.c./↓	↑/↓, n.c.	↑
Infantile hypercalcemia type 2	SLC34A1/Sodium-dependent phosphatase transport protein 2A	↓, n.c.	↓/↑	n.c./↓	↑/↓, n.c.	↑
Fanconi renal tubular syndrome type 2	SLC34A1/Sodium-dependent phosphatase transport protein 2A	↓, n.c.	↓/↑	n.c./↓	↑/↓, n.c.	↑
Dent disease 1	CLCN5/Chloride voltage-gated channel 5	↓, n.c.	↓/↑	n.c./↓	↑/↓, n.c.	↑
Dent disease 2 (Lowe syndrome)	OCRL1/Inositol polyphosphate-5-phosphatase	↓, n.c.	↓/↑	n.c./↓	↑/↓, n.c.	↑

FGF23: Fibroblast Growth Factor 23; TmP/GFR: Tubular maximum transport of Phosphate per Glomerular Filtration Rate; Ca: Calcium; P: Phosphate; ALP: Alkaline Phosphatase; PTH: Parathormone.; ↑ increase, ↓ decrease, n.c. no change.

## Tumor-induced osteomalacia (TIO)

Tumor-induced osteomalacia is a paraneoplastic syndrome derived from FGF23 overexpression by tumor cells, and thus, shares common pathogenetic mechanisms to all FGF23-related hypophosphatemic disorders, including XLH. It is also known as Oncogenic Osteomalacia and is mainly observed in cases of bone and soft tissue malignancy [2, 12]. These mostly benign, slowly growing tumors

are localized in various sites, among which in legs, in craniofacial regions, but also in colon, ovaries, and prostate [1]. Nevertheless, there have been reported a few malignant and metastatic cases of these Phosphaturic Mesenchymal Tumors (PMTs) [10]. The exact pathophysiology is not quite understood, although some tumors causing TIO have been identified as Klotho-expressing [2] and others have been shown to carry fusions between Fibronectin gene

(FN) and either Fibroblast Growth Factor 1 gene (FGF1) or Fibroblast Growth Factor Receptor 1 gene (FGFR1). These processes mediate an overactivation of FGFR1 signaling and excess of FGF23 actions [12].

Clinical features of TIO consist of progressive musculoskeletal pain, fatigue, proximal muscle weakness, and multiple fractures, leading to long-term disability and high morbidity. Profound weakness is the most characteristic symptom, which may distinguish TIO from other phosphate wasting disorders [4]. Because of its non-specific symptoms, high awareness of the disease is required to avoid misdiagnosis, delayed diagnosis, or inappropriate treatment. TIO has common laboratory findings with other hypophosphatemic FGF23-related diseases (low serum phosphate and  $1,25(\text{OH})_2\text{D}$  levels, elevated serum intact FGF23 and ALP, hyperphosphaturia). Additional assistance in localizing the tumor may be given by FDG-PET/CT ( $^{18}\text{F}$ -2-fluoro-2-deoxy-d-glucose (FDG) – positron emission tomography/computed tomography) or imaging studies that target somatostatin receptors, like  $^{68}\text{Ga}$ -DOTA-based PET/CT (gallium-68 Dotatate-based PET/CT) [11], or even selective venous sampling of FGF23 in challenging cases [1]. Biopsies or aspirations of PMTs are not suggested since they increase the concern for tumor seeding [11]. The gold standard for diagnosis of osteomalacia is bone biopsy and it helps to assess the severity of bone disease in TIO [12].

### Conventional therapy

Conventional therapy for XLH includes the substitution of phosphate and active vitamin D to all symptomatic patients and those with osteomalacia. Positive effect on bone metabolism, mineralization and architecture was observed in recent case series [2]. Patients treated with phosphate and vitamin D supplements showed less hypomineralized periosteocytic lesions in bone biopsy [13]. Although supportive therapy helps reducing pain, improves fracture healing and dental disease, no benefit was observed regarding enthesopathies [1, 8]. In another study, conventional therapy failed to achieve a normal height in patients with XLH, when compared to healthy control group [2]. Human growth hormone (hGH) has been introduced as an additional therapy to increase height in children, but it seems to have poor efficacy [14]. Lastly, apart from pharmacological approach, there is often the need for orthopedic intervention.

In patients with TIO, first choice treatment, yet not always applicable, has always been the complete surgical removal of the responsible tumor. Resection of the phosphaturic tumor normalizes the biochemical markers of the disease and improves osteomalacia [12]. However, a minority of cases may recur after primary surgery, as showed in a retrospective study of 230 patients with confirmed TIO. Indeed, Xiang Li et al. demonstrated that 7% of cases recurred with a median time of recurrence of 33 months [15]. When resection is not an option, either due to patient's comorbidities or due to the difficulty in localizing the tumor or due to the location of the malignancy, less invasive methods may be used. Radiotherapy and CT-guided radiofrequency may be effective and well tolerated in patients with TIO and may help in recurrence and metastases prevention [12, 16]. In cases of unresectable tumors, phosphate and active vitamin D supplements improve osteomalacia and symptoms [2].

Nevertheless, the narrow therapeutic window requires careful monitoring to avoid vitamin D overdose, hypercalciuria with or without hypercalcemia, and the potential consequence of nephrocalcinosis, nephrolithiasis and renal impairment [1, 2]. Patient's adherence to conventional treatment may be compromised due to gastrointestinal adverse symptoms (diarrhea and abdominal pain) and the multiple daily dosing regimen required [1, 2]. Phosphate and calcitriol dosage are 20–40 mg/kg and 20–30 ng/kg daily respectively for children, and 1–3 g/d and 0.75–3  $\mu\text{g}/\text{d}$  respectively for adults [12]. It is shown that administering phosphorus 5–7 times daily per os diminishes the risk of secondary hyperparathyroidism, by retaining an adequate phosphorus storage [2, 12, 18]. Cinacalcet has been suggested as an adjuvant treatment when phosphate and calcitriol supplementation is inadequate or contraindicated. The activation of calcium-sensing receptor (CaSR) and the consequent hypoparathyroidism are associated with a reduction of the FGF23-related phosphaturia [19]. However, its use is not spread due to limited data [19]. In order to prevent complications such as secondary/tertiary hyperparathyroidism, nephrolithiasis and renal impairment, patients should be monitored every 3 to 6 months for serum levels of calcium, phosphate, ALP and PTH, 24-hour renal calcium excretion, as well as for their renal function [20].

### Burosumab

The risks of mineral supplementation, patient's noncompliance or non-adherence and the failure of the conventional approaches to deal with the underlying defect of phosphate metabolism, brought out the need for a better treatment. Identification of FGF23 as the central molecule in the pathophysiology of these hypophosphatemic diseases, directed the attention of scientific community towards finding an agent that could possibly block FGF23 action. Preclinical studies in hypophosphatemic mice, showed that inhibition of FGF23, FGF Receptor or ERK signaling suppressed FGF23 and its action, improving hypophosphatemia [21–23]. Moreover, when anti-FGF23 antibodies were administered in hypophosphatemic mice, phosphate levels, rickets, bone mineralization and muscle weakness were ameliorated [24, 25].

Thereafter, numerous clinical trials have been conducted that support the efficacy and favorable safety profile of the drug. The first phase I study of a single administration of anti-FGF23-antibody KRN23 in adult patients with XLH demonstrated increase in serum phosphate,  $1,25(\text{OH})_2\text{D}$  and  $\text{TmP}/\text{GFR}$ , in a dose-dependent mode [26]. Of note, subcutaneous (sc.) administration of the drug led to a prolonged effect, in contrast to intravenous (iv.) injections [27]. In a subsequent phase II trial, a monoclonal antibody that targets FGF23, burosumab, was administered sc. to 52 child patients with XLH rickets either every 2 weeks or every 4 weeks [28]. The results confirmed the benefits, and additionally, showed a radiographic improvement of rickets according to Thacker Rickets Severity Score (RSS) and Radiographic Global Impression of Change (RGI-C) [28]; maintenance of the results after 64 weeks of follow-up was observed [28]. Moreover, the researchers recorded that twice-monthly administration is more effective than monthly-injections in children [28]. On the other hand, in adults, once-monthly regimen exhibited long-term favorable effects with prolonged serological improvements for more than a year [27]. A phase III study including children aged 1–12 years demonstrated that burosumab was

superior to conventional therapy in improving, among many parameters, serum phosphate and 1,25(OH)<sub>2</sub>D, radiographic rickets findings and length/height Z-score at week 64 [29]. In addition, a controlled, multicenter trial including children indicated that burosumab improves long bone mineralization and growth compared to conventional treatment with phosphate and vitamin D supplements [30]. The majority of adverse events related to treatment were linked to injections site reactions (ISRs) (erythema, pruritus, rash, swelling, discomfort, hypersensitivity, inflammation), were mild to moderate and lasted only a few days, with no discontinuation of the treatment or study. Approximately 10% of each group (conventional therapy and burosumab) had a more serious adverse event that was considered unrelated to treatment [29]. However, it is important to clarify whether the increased rate of dental abscesses with burosumab treatment versus conventional therapy were drug-related or related to patient variability or even a direct dental favorable effect of conventional treatment [29]. A recent trial including 5 children with genetically confirmed XLH, proved that when administrating burosumab sc. at 0.8 mg/kg every 2 weeks, the positive effects on phosphate metabolism, ALP levels and growth were continued for a year [31]. No serious adverse events, like those related to conventional therapy, were reported with burosumab, however mild transient adverse events related to injection site as well as headache were noted [31].

After the first clinical trial of Carpenter et al. [26], numerous trials investigating the efficacy and safety of burosumab in XLH included adult patients. A randomized, double-blind, placebo-controlled phase III trial with 134 adults, with confirmed PHEX mutation [32], indicated that burosumab improved serum phosphate, fracture healing, stiffness and physical function scores. Patients in the burosumab group had a 16.8-fold greater chance in fully fracture healing than those in the placebo group at week 24. Bone metabolism markers were also improved significantly [32]. Continuation of burosumab treatment assured a sustained corrected phosphorus state, and ongoing fracture healing and musculoskeletal improvement [33]. Another phase III trial, focused on assessing the effect of burosumab on histomorphometric measures of osteomalacia in adult patients with XLH. Transiliac bone biopsies at week 48 proved enhancement of all osteomalacia-histomorphometric parameters, including osteoid volume/bone volume, osteoid thickness, osteoid surface/bone surface and mineralization lag time. Additional improvement of serum phosphorus levels, bone markers and fracture healing were observed [34]. These trials confirmed the good safety profile of the drug for adult patients. There were no serious adverse events related to burosumab, regarding serum or urine calcium, phosphate, PTH or nephrocalcinosis [32, 34]. Nevertheless, there are a few worrisome data regarding some potentially serious adverse events that require further research. Imel et al. observed that a patient had a deterioration of coronary artery calcification upon dose escalation of burosumab [27].

Burosumab was also shown to improve osteomalacia and its related biochemical features in patients with TIO. Jan De Bur et al., in a phase II study, reported increased and maintained serum phosphorus levels at week 144 in 14 American adult patients with TIO under burosumab therapy [35]. Moreover, transiliac bone biopsies at week 48 suggested improvement of osteomalacia parameters: osteoid volume/bone, osteoid thickness and mineralization lag

time. Patients demonstrated less pain and weakness, improved fracture healing and had fewer new fractures at week 144. It is important that no serious adverse events were related to treatment, and 9 burosumab-related events were all mild to moderate in severity, proving the safety of the drug [35]. Burosumab exhibited similar safety profile, improved phosphate metabolism and osteomalacia in a phase II open-label study including 13 Japanese and Korean TIO patients [36]. Imanishi et al. reported that monthly administration of burosumab led to elevation of fasting serum phosphate level, along to an increase followed by decrease in bone biomarkers, and improved motor function and fracture healing. No serious related adverse events were observed, as previously [36].

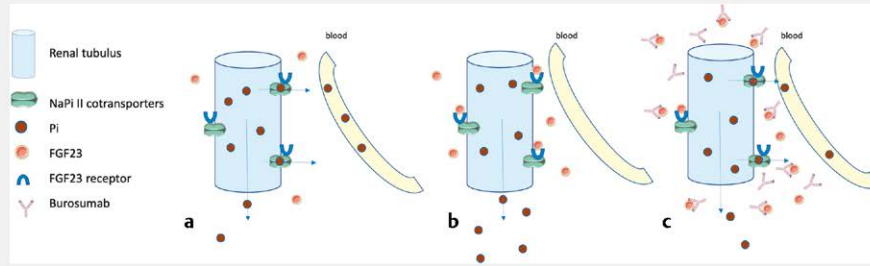
These results triggered the approval of burosumab (Crysvita) for treatment of child and adult patients with XLH by FDA (Food and Drug Administration) and EMA (European Medicines Agency) in 2018, and since then in numerous countries (Asia, South America, Middle East). The approval of FDA regarding TIO treatment followed in June 2020. To date, the published consensus statement from Haffner et al. [37], provides key recommendations for burosumab clinical use [8, 18, 37]. Regarding children and adolescents, burosumab treatment should be considered in XLH patients aged older than 6 months, who are not candidates or do not respond for any reason to conventional treatment or have complications related to conventional therapy. Radiographic evidence of overt bone disease is another reason to consider starting burosumab in those patients [37]. Regarding adults, treatment with burosumab should be considered in symptomatic patients with persistent bone and/or joint pain that limits daily activities, as well as in patients with pseudofractures, fractures or inadequate response to conventional therapy (grade B, moderate recommendation). Moreover, initiation of burosumab should be considered in all XLH patients who experience complications of the conventional therapy (grade D, weak recommendation) [37].

During burosumab therapy, supplementation with phosphate or 1,25-dihydroxyvitamin D is contraindicated and must be stopped at least two weeks before beginning burosumab [4]. It should not be started in patients with significant renal insufficiency [4], as defined by estimated glomerular filtration rate (eGFR) below 29 ml/min/1.73 m<sup>2</sup>. In children, it is administered sc. in a dosage of 0.8 mg/kg every two weeks, and 1 mg/kg every four weeks in adults, with a starting dose of 0.5 mg/kg. Before initiating therapy, patients must have a fasting serum phosphate of <2.5 mg/dl, while titration and dose adjustments are made based on fasting serum phosphate [4]. Regular follow up with blood tests should be performed, including phosphate, calcium, PTH and ALP [30]. The pathophysiology of XLH and TIO along with the new therapeutic approach of burosumab are demonstrated in ► Fig. 2 and ► Table 2.

### Pan-fibroblast growth factor receptor (FGFR) kinase inhibitor

After the identification of the FN1-FGFR1 translocation as the molecular defect in the pathogenesis of some PMTs, FGFR1 inhibition emerged as an appealing new therapeutic target. Wöhrle et al. investigated the impact of a novel selective, pan-specific FGFR inhibitor, infigratinib (BGJ398), in hypophosphatemic mouse model of XLH [38]. They showed that infigratinib suppresses FGF23 renal signaling leading to increased 1,25(OH)<sub>2</sub>D biosynthesis and correc-





► **Fig. 2** Burosumab cancels the effect of FGF23 in renal phosphate regulation. **a:** NaPi II cotransporters mediate renal phosphate reabsorption. **b:** FGF23 excess inhibits the transporter resulting in impaired reabsorption of phosphate and phosphaturia. **c:** Burosumab is an antibody against FGF23, prevents FGF23-mediated inhibition of the phosphate transporter and allows the reabsorption of phosphate (NaPi II; Sodium/Phosphate cotransporters type II, Pi; inorganic phosphate, FGF23; Fibroblast Growth Factor 23).

► **Table 2** Summary of new approved treatment agents for XLH and HPP.

	Burosumab	Asfotase alfa
Commercial name	Crysvita	Strensiq
Mechanism of action	Anti-FGF23 antibody	Enzyme replacement therapy
Indications	X-linked hypophosphatemia (XLH)-Tumor induced osteomalacia (TIO)	Hypophosphatasia (HPP)
Contraindications	Hyperphosphatemia, phosphate and calcitriol supplementation, Renal insufficiency	Allergy
Approval (FDA)	2018 (XLH)/2020(TIO)	2015
Effects	Rickets ↓ Bone mineralization ↑ Growth ↑ Fracture healing ↑ Physical function ↑ Pain ↓ Bone formation markers ↑	Survival rate ↑ Bone mineralization ↑ Respiratory status ↑ Fracture healing ↑ Physical function ↑ Pain ↓ Bone formation markers ↑ Cognitive development ↑
Common side effects	Injection site reactions Headache	Injection site reactions Ectopic calcifications
Bone metabolism parameters		
Calcium	n.c.	n.c. , ↓
Phosphate	↑	n.c. , ↑↓
Calcitriol	↑	–
ALP	↓	↑
TmP/GFR	↑	–
PLP	-	↓
Dose regimen		
Pediatric patients	(>6 months) 0.8 mg/kg q 2 weeks sc.	2 mg/kg/d three days a week sc.
Adult patients	1 mg/kg q 4 weeks sc.	or 1 mg/kg/d six days a week sc.

↑ increase, ↓ decrease, n.c. no change, s.c. subcutaneously.

tion of hypophosphatemia and hypocalcemia in Hyp mice. Furthermore, long-term treatment of Hyp mice with infigratinib led to a complete normalization of hypophosphatemia and hypocalcemia,

enhanced bone mineralization, normalized bone turnover, restored growth plate organization and increased longitudinal growth of the long bones [38].

Hartley et al. described the effect of infigratinib in the treatment of a 66-year-old man with metastatic PMT [39]. The pan-FGFR tyrosine kinase inhibitor induced an immediate and dramatic response regarding FGF23 levels and metastases regression. Infigratinib received FDA approval in 2021 for the treatment of cholangiocarcinomas and thus might hold promise for clinical use in FGF23-related hypophosphatemic disorders in the future, such as XLH and TIO. The efficacy and safety profile of FGFR tyrosine kinase inhibitors in TIO is under ongoing research.

## Alkaline Phosphatase and its role in bone mineralization

Human alkaline phosphatase (ALP) is a glycoprotein composed of four isoenzymes: the intestinal (IAP), the placental (PLAP), the placental-like or germ cell (GCAP), and the liver/bone/kidney (tissue non-specific; TNSALP) isoenzyme. Coding genes for IAP, GCAP and PLAP are located in chromosome 2 and the derived isoforms are 90 to 98% identical in their amino acid sequences, while TNSALP gene is mapped to chromosome 1 and the derived TNSALP has less than 50% homology with the three aforementioned isoenzymes [40]. The cells genetically determined to express TNSALP are found mainly in bone (hypertrophic chondrocytes and osteoblasts), liver and kidney. TNSALP is also found in teeth (odontoblasts), central nervous system, fibroblasts, and other cell types [41]. It is anchored to the plasma membrane, in a way that follows membrane's fluidity [40].

The metalloenzyme ALP possesses an important role in bone mineralization, by hydrolyzing inorganic pyrophosphate (PPI) to inorganic phosphate (Pi). PPI is provided by nucleotide pyrophosphatase phosphodiesterase-1 (NPP1) from nucleotide triphosphates and by ankyrin in membranes of hypertrophic chondrocytes and osteoblasts. Of note, PPI is a strong inhibitor of hydroxyapatite formation. This balance between the activity of TNSALP, that regulates the ratio of Pi to PPI, and the activities of NPP1 and ankyrin, that regulate PPI load, is considered to be critical for bone mineralization [42, 43]. In vitro, inhibition of TNSALP function suppresses TNSALP mRNA expression and mineralization [43]. The physiological substrates of TNSALP, apart from PPI, are thought to be pyridoxal 5'-phosphate (PLP) and, probably, phosphoethanolamine (PEA) [43]. As a result, they accumulate in cases of TNSALP deficiency. Recent studies have also added adenosine triphosphate (ATP), di-phosphoryl lipopolysaccharide (LPS), and phosphorylated osteopontin (p-OPN) as alternative natural substrates [40]. PLP, an activated form of vitamin B6, is involved as a cofactor in the formation of neurotransmitters in neuronal cells, such as dopamine, serotonin, and  $\gamma$ -aminobutyric acid (GABA) [43]. Normally, PLP is not transportable into neuronal cells, but TNSALP transforms PLP to pyridoxal, thus, enables it to enter cells. Perhaps that explains the fact that inactivation of TNSALP gene in mice results in seizures [44].

## Hypophosphatasia (HPP)

Hypophosphatasia (HPP) is a rare inherited metabolic disease that results from inborn mutations in the TNSALP gene (ALPL). So far, there have been reported over 400 mutations, that cause exceptional clinical heterogeneity, ranging from preterm intrauterine death to only dental complications or even asymptomatic carriers [41]. The model of inheritance may be autosomal recessive, that usually causes a more severe phenotype, or autosomal dominant,

that likely appears with variable penetrance [45]. The incidence of the severe phenotype is low and considered to be approximately 1:100 000 in Canada [46] and 1:300 000 in Europe [41]. The mutated TNSALP performs diminished activity and leads to accumulation of its main substrates, PPI and PLP [41]. The inhibitory role of PPI in mineralization along with the role of PLP as a cofactor for many enzymatic procedures explain the musculoskeletal and systemic features of the disorder. The predominant manifestations of the disease consist of impaired bone mineralization, deformities, fractures, delayed fracture healing, premature tooth loss, muscle weakness and musculoskeletal pain [8]. Other non-bone specific manifestations include pulmonary abnormalities, seizures, impaired motor skills and nephrocalcinosis [46].

HPP may manifest through a variety of phenotypes, from lethal disease in early perinatal age, to isolated dental complications and premature tooth loss. According to patient's age of first appearance and the severity of symptoms, HPP is classified as perinatal, infantile, childhood or adult, and there is also the type of odontohypophosphatasia [40, 41]. Perinatal disease is lethal and is presented with almost total absence of bone mineralization, severe pulmonary manifestations and seizures. There are some cases that are categorized as "benign prenatal HPP" and include only long bone deformities, which may improve spontaneously [40]. The infantile type appears about six months after birth and includes rickets-like signs, failure to thrive and pulmonary complications [41]. The childhood type may be mild to moderate in severity, according to the extent of impaired physical function and skeletal deformities. The adult type affects middle-aged adults and shows moderate symptoms of musculoskeletal pain, a mild history of osteomalacia or fractures/pseudofractures, with recurrent metatarsal stress fractures being characteristic [40, 41, 46]. Although dental complications may be present in any HPP type, defective tooth formation is the only clinical abnormality found in odontohypophosphatasia, resulting in loss of primary teeth in children and early loss of permanent teeth or periodontal pathology in adults [40].

Medical history, physical examination, and routine laboratory and radiographic imaging indicative of osteomalacia are matched to elevated substrates of TNSALP and the hallmark of low serum ALP for the diagnosis of HPP [47]. Low levels of ALP below 100U/ml in a child with rickets and less than 40 U/l in adults of both sexes are highly suspicious of HPP [18, 41]. Genetic detection of the mutated ALPL gene sets the definite diagnosis, yet usually unnecessary [9]. Despite the fact that nearly all cases of rickets/osteomalacia suggest hypocalcemia and/or hypophosphatemia, in HPP, the potential hypercalcemia explains the suppression of PTH and the consequent hyperphosphatemia in these patients [47].

## Supportive therapy and experimental treatments

Attempts have been pointed towards improvement of prognosis and quality of life for patients with HPP, for many years. Nonetheless, the supportive treatment offered so far failed to increase the survival rate of severe perinatal cases. Mechanical ventilation can be challenging due to thoracic deformity or pulmonary hypoplasia; pyridoxine administration has little role in restraining severe neurological manifestations due to PPI excess; hydration, dietary calcium restriction or loop diuretic agents may improve mild hypercalcemia; non-steroidal anti-inflammatory treatment, physical



exercise and physiotherapy may be useful for musculoskeletal symptoms; several surgical procedures may be necessary, including craniotomy, postosteotomy, dental procedures and scoliosis operations [47]. Antiresorptives have not only failed to improve the impaired mineralization, but they also prove to be harmful. Bisphosphonates are PPI analogs that have high affinity with hydroxyapatite. N-containing BPs directly inhibit bone TNSALP activity, by binding both  $Zn^{2+}$  and  $Mg^{2+}$  [48]. Indeed, a case series of multiple atypical femoral fractures, associated with bisphosphonate therapy in an adult-onset HPP patient has been reported in literature [49]. Vitamin D, phosphate and calcium should be administered at a necessary minimum, to ensure the prevention of rickets and as well diminish the risk of hypercalcemia, hypercalciuria and nephrocalcinosis. Another treatment that failed to avoid substantial morbidity, is allogeneic stem cell transplantation, whereas anabolic treatment with the parathyroid hormone analogue teriparatide remains controversial [45, 46]. Although teriparatide has been shown to improve mobility and bone pain, increase ALP levels and accelerate fracture healing in HPP cases [50, 51], these benefits were not guaranteed in every case [52] and were not sustained over time [53]. Teriparatide is contraindicated in children [54].

There are some promising data regarding the use of sclerostin-antibody romosozumab in HPP patients. Sclerostin is a protein encoded by the *SOST* gene, is expressed in osteocytes and osteoblasts, and interferes with the Wnt signaling pathway, by preventing low-density-lipoprotein-related protein 5 receptor (LRP5 receptor) from interacting with the frizzled receptor, thus inhibiting osteoblastic bone formation [55]. The phenotype of human genetic disorder of sclerosteosis was reproduced in *SOST*-knock out mice, with high bone mass being the prevalent characteristic [56]. Both in preclinical and clinical studies, administration of monoclonal antibodies against sclerostin (BPS804) was shown to improve bone mineral density, fracture healing and bone formation markers in healthy and osteoporotic individuals [55, 57]. Seefried et al. enrolled 8 adult patients with HPP in a phase IIA open-label study and assessed the beneficial effect of BPS804 regarding bone formation, bone mineral density (BMD), bone biomarkers and ALP activity [58]. Patients received 3 ascending iv. doses of BPS804 and were followed for 16 weeks after the last dose on day 29. BPS804 administration was associated with increased mean ALP, bone-specific ALP activity, bone formation markers and lumbar spine BMD, whereas no serious safety issues were noted [58]. Despite the promising results, romosozumab is not approved for HPP patients, while long-term and large-scale results are not yet available [45].

### Asfotase alfa: recombinant enzyme replacement therapy in HPP

After ineffective efforts to ameliorate clinical symptoms and radiographic signs of HPP using iv. infusions of soluble ALP [46], it has been well-recognized that targeted correction of ALP activity within skeletal tissue was necessary. Asfotase alfa is a human recombinant replacement therapy that targets the bone, by having a deca-aspartate motif that enhances its binding to hydroxyapatite. It also includes the catalytic domain of TNSALP, responsible for its enzymatic function, and the Fc fragment of IgG1, which prolongs its circulating half-life [41]. In 2008, a preliminary animal study in TNSALP knockout mice (a good model for the infantile form of HPP

[59]), demonstrated that administration of human TNSALP enzyme replacement prevented the onset of HPP [60]. Notably, treated mice presented normal growth and had normal biochemical, radiographic and clinical parameters, when sc. administration of therapy was initiated at birth [60]. Later, in 2011, Mckee et al. confirmed, with micro-computed tomography and histology, the dose-dependent favorable effect of mineral-targeting human TNSALP on mineralization of alveolar bone, dentin and cementum in treated knockout mice [61].

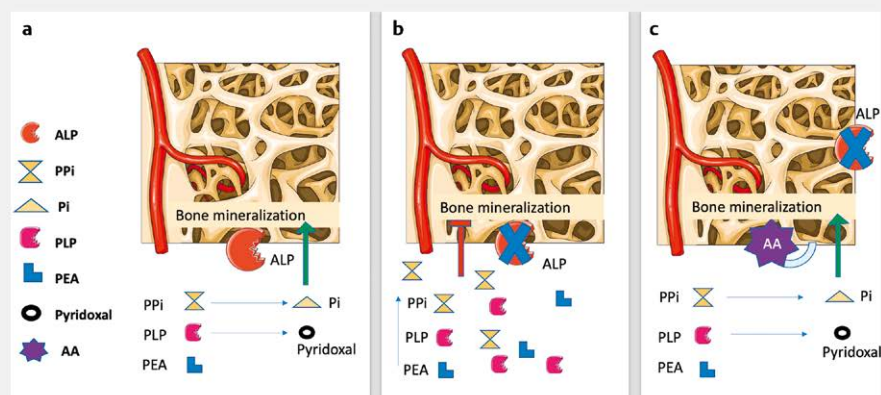
In 2012, the first clinical trial of asfotase alfa was conducted in 11 patients aged less than 3 years old with perinatal or infantile HPP and severe associated symptoms [62]. Asfotase alfa was administered by one iv. infusion followed by numerous sc. injections for up to 1 year and led to improvement of skeletal manifestations as well as respiratory status, motor function and cognitive development. These outcomes were evaluated using RGI-C score, RSS and the Bayley Scales of Infant and Toddler Development third edition (Bayley-III). The most common side effects related to treatment were localized, mild-to-moderate in severity, ISRs [62]. An extension study showed similar efficacy and safety as well as sustained improvements for up to 7 years of treatment. The most frequent side effects were pyrexia and upper respiratory tract infection [63]. When 69 pediatric patients with severe HPP of infantile-onset were evaluated with RGI-C score, after therapy with asfotase alfa up to 6 years, they showed early and sustained radiographic and clinical improvement [64]. Moreover, positive results regarding respiratory status, growth, ALP activity and PPI concentration were observed. The drug was generally well-tolerated and, although all patients had at least one treatment-related adverse event, they were mostly mild and accounted mainly for ISRs (erythema, discoloration, induration, hematoma) or injection associated reactions (pyrexia, chills, rash, anaphylactic reaction). Some cases of abnormal calcium levels were recorded, and anti-asfotase alfa antibodies were identified in 88% of patients, 67% of which were neutralizing, but were not related to adverse events [64]. Therapy with asfotase alfa has also shown a significantly favorable effect in extending the survival of patients with perinatal and infantile HPP, according to data obtained from two multicenter, phase II interventional studies, compared to historical controls [65]. Treated patients received the drug as sc. injection either 1 mg/kg six times per week or 2 mg/kg thrice weekly. 95% of them were alive at 1 year of age, comparing to only 41% of untreated patients. That difference increased more at 5 years of age, when 84% of treated patients survived. Most common AEs were mild to moderate ISRs. No clinically important ectopic calcification (5 patients had probably related to treatment calcium deposits on conjunctiva or cornea) or lipohypertrophy occurred. A recent study assessed the effect of asfotase alfa on the development and exfoliation patterns of primary and permanent teeth in 11 infants and children with early-onset HPP. It concluded that early initiation and continuation of therapy is superior regarding oral health and the amount of prematurely exfoliated primary teeth [66].

Asfotase alfa also seems to be beneficial for adult patients with pediatric-onset HPP, improving the biochemical characteristics of the disease: it increases TNSALP activity and lowers both PLP and PPI levels [67–69], with no significant difference between the ALPL variant states [70]. When a group of adolescents and adults with

childhood-onset HPP, treated with asfotase alfa, was compared to an untreated control group, after 6 months of therapy, there was found a higher TNSALP activity, lower PLP and PPI levels and significant improvement in the 6-minute-walk test [67]. Bone healing is delayed and compromised in patients with HPP. Asfotase alfa treatment of adult patients was found to remarkably improve osseous consolidation in the region of the non-healing bone, by rapidly increasing levels of bone volume per tissue volume (BV/TV) [68]. Moreover, it rapidly increases the callus formation at the osteotomy site [71], increases mineral maturation, ameliorates bone microarchitecture deterioration and mineralization heterogeneity, improving volumetric bone density, structure and strength parameters [72, 73]. In an observational, prospective single-center study, fourteen patients with pediatric-onset HPP, 19 to 78 years old, received asfotase alfa for at least 12 months, with a dosing regimen of either 2 mg/kg sc. three times a week, or 1 mg/kg sc. six times a week [74]. Treated patients demonstrated improved physical function, as assessed by many tests (e. g., 6-minute walk test, timed up-and-go test, Short Physical Performance Battery) as well as better health-related quality of life, including significant decrease in pain intensity at 6 months of treatment. No new safety concerns were identified [74]. Seefried et al. included in their analysis 21 adult patients, with genetically confirmed pediatric-onset HPP, who were treated with asfotase alfa for 24 months. They assessed the changes of many bone turnover and mineral metabolism parameters [PLP, urine PEA/creatinine (Cr) ratio, serum PTH, calcium, phosphate, FGF23, osteocalcin, procollagen type 1 N-propeptide (P1NP), tartrate-resistant acid phosphatase 5b (TRAP5b), N-terminal telopeptide of type 1 collagen (NTx)] as well as BMD T-scores at baseline and 3, 6, 12, 18, and 24 months after treatment initiation. Lumbar spine BMD T-scores continued to increase throughout the follow up. They concluded that asfotase alfa mediates bone mineralization and bone turnover on previously inaccessible bone [69] (► Fig. 3).

To date, little data are available, concerning asfotase alfa use in adult-onset HPP. Magdaleno et al. presented a unique case of a woman, whose symptoms mainly presented in adulthood [75]. She was started on off-label use of asfotase alfa at a dose of 1 mg/kg 3 times weekly sc. and within a few months she presented significant improvements in physical function, bone pain and healing [75]. In Japan, a patient with adult-onset HPP was included in a multicenter prospective trial, among other 12 child patients with perinatal, infantile or childhood form. All patients survived and had significant benefits regarding their radiographic, developmental, physical and respiratory status [76]. Only 2% of a total 195 adverse events were severe, and only 2 were related to treatment (convulsion due to hypocalcemia) [76].

In 2015, asfotase alfa (Strensiq) was approved for patients of any age with pediatric-onset HPP to treat bone manifestations of the disease, first in Japan then in Canada, European Union, United States and elsewhere [47]. Asfotase alfa is also approved for adult form of HPP [41]. Current recommendations suggest that it must be administered sc., with a dosage regimen of either 2 mg/kg/d three days a week or 1 mg/kg/d six days a week [77]. A maximum dose of 9 mg/kg a week may be a choice for patients who respond poorly, but only after excluding other potential reasons for treatment failure [77]. Suboptimal or discontinued treatment leads to HPP symptoms regression, with weakness and radiographic deterioration [78]. Thus, a strict follow-up is required to adjust treatment dose, and to perform functional, growth, radiographic and biochemical assessment [77]. The criteria established by Khan et al., that make adult patients with HPP potential candidates for enzyme-replacement treatment are the presence of osteomalacia and its complications; major osteoporotic fractures, pseudofractures or delayed/incomplete fracture healing; intractable musculoskeletal pain or chondrocalcinosis requiring or unresponsive to opioids; impaired physical function and mobility [79]. The pathophysiology and therapeutic approach of HPP are summarized in ► Fig. 3 and ► Table 2.



► Fig. 3 Pathophysiology and therapeutic approach in hypophosphatasia. **a:** Alkaline phosphatase (ALP) hydrolyzes inorganic pyrophosphate (PPI) to inorganic phosphate (Pi) and pyridoxal phosphate (PLP) to pyridoxal. It promotes bone mineralization, as PPI is a strong inhibitor of hydroxyapatite formation. Phosphoethanolamine (PEA) is considered another natural substrate. **b:** In hypophosphatasia, ALP deficiency leads to ALP substrates accumulation in blood and impaired bone mineralization. **c:** Asfotase alfa (AA) is a recombinant enzyme mimicking the natural effect of ALP in bone and allowing bone mineralization.

## Conclusion

New therapeutic agents are available for the treatment of rare disorders of calcium and phosphate metabolism, with promising data in severe cases. Burosumab is a potent FGF23-inhibitor with proven efficacy and safety as well as superiority to conventional management, both for child and adult patients with XLH. There are data supporting the numerous benefits of its continued use. It was first approved for the treatment of children with XLH and recently for the treatment of adult patients in USA and several countries in Europe. Treatment with burosumab improves the severity of osteomalacia and has positive effects on growth, pain, fracture healing and physical function. A supplementary approval of burosumab for the treatment of TIO was recently released when the responsible mesenchymal tumor can not be removed (non-localizable or non-resectable tumors). Nevertheless, more clinical data are required to prove the efficacy of burosumab in other FGF23-related conditions and to assess the long-term safety profile of the drug.

Many studies have reported the early and sustained efficacy of asfotase alfa, a bone-specific enzyme replacement therapy, in severe cases of pediatric-onset HPP leading to its approval for use since 2015. Lower extracellular TNSALP substrates, resolution of HPP manifestations, such as rachitic changes, respiratory dysfunction, growth and motor impairment are some of the benefits that improve patients' physical function and quality of life. However, it is currently approved for patients with pediatric-onset HPP and severe musculoskeletal manifestations. More data are needed, especially regarding adult HPP patients, in order to expand its use in other forms and grades of severity of HPP. Given the fact that these drugs are highly expensive, clear guidelines regarding initiation, evaluation and continuation of treatment need to be established.

## Conflict of Interest

The authors declare that they have no conflict of interest.

## References

- [1] Kinoshita Y, Fukumoto S. X-linked hypophosphatemia and FGF23-related hypophosphatemic diseases: prospect for new treatment. *Endocr Rev* 2018; 39: 274–291
- [2] Fukumoto S. FGF23-related hypophosphatemic rickets/osteomalacia: diagnosis and new treatment. *J Mol Endocrinol* 2021; 66: R57–R65
- [3] Heijboer AC, Cavalier E. The measurement and interpretation of fibroblast growth factor 23 (FGF23) concentrations. *Calcif Tissue Int* 2022. doi:10.1007/s00223-022-00987-9
- [4] Athonvarangkul D, Insogna KL. New therapies for hypophosphatemia-related to FGF23 Excess. *Calcif Tissue Int* 2021; 108: 143–157
- [5] Acar S, Demir K, Shi Y. Genetic causes of rickets. *J Clin Res Pediatr Endocrinol* 2017; 9: 88–105
- [6] Addison WN, Masica DL, Gray JJ et al. Phosphorylation-dependent inhibition of mineralization by osteopontin ASARM peptides is regulated by PHEX cleavage. *J Bone Miner Res* 2010; 25: 695–705
- [7] Barros NMT, Hoac B, Neves RL et al. Proteolytic processing of osteopontin by PHEX and accumulation of osteopontin fragments in Hyp mouse bone, the murine model of X-linked hypophosphatemia. *J Bone Miner Res* 2013; 28: 688–699
- [8] Kocijan R, Haschka J, Feurstein J et al. New therapeutic options for bone diseases. *Wien Med Wochenschr* 2021; 171: 120–125
- [9] Lewiecki EM, Bilezikian JP, Kagan R et al. Proceedings of the 2019 Santa Fe bone symposium: new concepts in the care of osteoporosis and rare bone diseases. *J Clin Densit* 2020; 23: 1–20
- [10] Florenzano P, Hartley IR, Jimenez M et al. Tumor-induced osteomalacia. *Calcif Tissue Int* 2021; 108: 128–142
- [11] Crotti C, Bartoli F, Coletto LA et al. Tumor induced osteomalacia: a single center experience on 17 patients. *Bone* 2021; 152: 116077
- [12] Dahir K, Zanchetta MB, Stanciu I et al. Diagnosis and management of tumor-induced osteomalacia: perspectives from clinical experience. *J Endocr Soc* 2021; 5: bvab099
- [13] Fratzi-Zelman N, Gamsjaeger S, Blouin S et al. Alterations of bone material properties in adult patients with X-linked hypophosphatemia (XLH). *J Struct Biol* 2020; 211: 107556
- [14] Schindeler A, Biggin A, Munns CF. Clinical evidence for the benefits of burosumab therapy for X-linked hypophosphatemia (XLH) and other conditions in adults and children. *Front Endocrinol (Lausanne)* 2020; 11: 338
- [15] Li X, Jiang Y, Huo L et al. Nonremission and recurrent tumor-induced osteomalacia: a retrospective study. *J Bone Miner Res* 2020; 35: 469–477
- [16] Mishra SK, Kuchay MS, Sen IB et al. Successful management of tumor-induced osteomalacia with radiofrequency ablation: a case series. *JBM Plus* 2019; 3: 10178
- [17] Tarasova VD, Trepp-Carrasco AG, Thompson R et al. Successful treatment of tumor-induced osteomalacia due to an intracranial tumor by fractionated stereotactic radiotherapy. *J Clin Endocrinol Metab* 2013; 98: 4267–4272
- [18] Hoyer-Kuhn H, Schönau E. Pharmacotherapy in rare skeletal diseases. In: *Handbook of Experimental Pharmacology*. Springer; 2020: 87–104
- [19] Minisola S, Peacock M, Fukumoto S et al. Tumour-induced osteomalacia. *Nat Rev Disease Primers* 2017; 3: 17044
- [20] Jiang Y, Li X, Huo L et al. Consensus on clinical management of tumor-induced osteomalacia. *Chin Med J* 2021; 134: 1264–1266. doi:10.1097/CM9.0000000000001448
- [21] Goetz R, Nakada Y, Hu MC et al. Isolated C-terminal tail of FGF23 alleviates hypophosphatemia by inhibiting FGF23-FGFR-Klotho complex formation. *Proc Natl Acad Sci* 2010; 107: 407–412
- [22] Zhang MYH, Ranch D, Pereira RC et al. Chronic inhibition of ERK1/2 signaling improves disordered bone and mineral metabolism in hypophosphatemic (Hyp) mice. *Endocrinology* 2012; 153: 1806–1816
- [23] Wöhrle S, Henninger C, Bonny O et al. Pharmacological inhibition of fibroblast growth factor (FGF) receptor signaling ameliorates FGF23-mediated hypophosphatemic rickets. *J Bone Miner Res* 2013; 28: 899–911
- [24] Aono Y, Yamazaki Y, Yasutake J et al. Therapeutic effects of anti-FGF23 antibodies in hypophosphatemic rickets/osteomalacia. *J Bone Miner Res* 2009; 24: 1879–1888
- [25] Aono Y, Hasegawa H, Yamazaki Y et al. Anti-FGF-23 neutralizing antibodies ameliorate muscle weakness and decreased spontaneous movement of Hyp mice. *J Bone Miner Res* 2011; 26: 803–810
- [26] Carpenter TO, Imel EA, Ruppe MD et al. Randomized trial of the anti-FGF23 antibody KRN23 in X-linked hypophosphatemia. *J Clin Invest* 2014; 124: 1587–1597
- [27] Imel EA, Zhang X, Ruppe MD et al. Prolonged correction of serum phosphorus in adults with X-linked hypophosphatemia using monthly doses of KRN23. *J Clin Endocrinol Metab* 2015; 100: 2565–2573
- [28] Carpenter TO, Whyte MP, Imel EA et al. Burosumab therapy in children with X-linked hypophosphatemia. *N Eng. J Med* 2018; 378: 1987–1998

- [29] Imel EA, Glorieux FH, Whyte MP et al. Burosumab versus conventional therapy in children with X-linked hypophosphataemia: a randomised, active-controlled, open-label, phase 3 trial. *Lancet* 2019; 393: 2416–2427
- [30] Whyte MP, Carpenter TO, Gottesman GS et al. Efficacy and safety of burosumab in children aged 1–4 years with X-linked hypophosphataemia: a multicentre, open-label, phase 2 trial. *Lancet Diabetes Endocrinol* 2019; 7: 189–199
- [31] Martín Ramos S, Gil-Calvo M, Roldán V et al. Positive response to one-year treatment with burosumab in pediatric patients with X-linked hypophosphatemia. *Front Pediatr* 2020; 8: 48
- [32] Insogna KL, Briot K, Imel EA et al. A randomized, double-blind, placebo-controlled, phase 3 trial evaluating the efficacy of burosumab, an anti-FGF23 antibody, in adults with X-linked hypophosphatemia: week 24 primary analysis. *J Bone Miner Res* 2018; 33: 1383–1393
- [33] Portale AA, Carpenter TO, Brandi ML et al. Continued beneficial effects of burosumab in adults with X-linked hypophosphatemia: results from a 24-week treatment continuation period after a 24-week double-blind placebo-controlled period. *Calcif Tissue Int* 2019; 105: 271–284
- [34] Insogna KL, Rauch F, Kamenický P et al. Burosumab improved histomorphometric measures of osteomalacia in adults with X-linked hypophosphatemia: a phase 3, single-arm, international trial. *J Bone Miner Res* 2019; 34: 2183–2191
- [35] Jan de Beur SM, Miller PD, Weber TJ et al. Burosumab for the treatment of tumor-induced osteomalacia. *J Bone Miner Res* 2021; 36: 627–635
- [36] Imanishi Y, Ito N, Rhee Y et al. Interim analysis of a phase 2 open-label trial assessing burosumab efficacy and safety in patients with tumor-induced osteomalacia. *J Bone Miner Res* 2021; 36: 262–270
- [37] Haffner D, Emma F, Eastwood DM et al. Clinical practice recommendations for the diagnosis and management of X-linked hypophosphataemia. *Nat Rev Nephrol* 2019; 15: 435–455
- [38] Wöhrle S, Henninger C, Bonny O et al. Pharmacological inhibition of fibroblast growth factor (FGF) receptor signaling ameliorates FGF23-mediated hypophosphatemic rickets. *J Bone Miner Res* 2013; 28: 899–911
- [39] Hartley IR, Miller CB, Papadakis GZ et al. Targeted FGFR blockade for the treatment of tumor-induced osteomalacia. *N Engl J Med* 2020; 383: 1387–1389
- [40] Villa-Suárez JM, García-Fontana C, Andújar-Vera F et al. Hypophosphatasia: a unique disorder of bone mineralization. *Int J Mol Sci* 2021; 22: 4303
- [41] Tournis S, Yavropoulou M, Polyzos S et al. Hypophosphatasia. *J Clin Med* 2021; 10: 5676
- [42] Vimalraj S. Alkaline phosphatase: structure, expression and its function in bone mineralization. *Gene* 2020; 754: 144855
- [43] Orimo H. The mechanism of mineralization and the role of alkaline phosphatase in health and disease. *J Nippon Med School* 2010; 77: 4–12
- [44] Waymire KG, Mahuren JD, Jaje JM et al. Mice lacking tissue non-specific alkaline phosphatase die from seizures due to defective metabolism of vitamin B-6. *Nat Genet* 1995; 11: 45–51
- [45] Simon S, Resch H, Klaushofer K et al. Hypophosphatasia: from diagnosis to treatment. *Curr Rheumatol Rep* 2018; 20: 69
- [46] Millán JL, Plotkin H. Hypophosphatasia – pathophysiology and treatment. *Actual Osteol* 2012; 8: 164–182
- [47] Whyte MP. Hypophosphatasia: enzyme replacement therapy brings new opportunities and new challenges. *J Bone Miner Res* 2017; 32: 667–675
- [48] Vaisman DN, McCarthy AD, Cortizo AM. Bone-specific alkaline phosphatase activity is inhibited by bisphosphonates: role of divalent cations. *Biol Trace Elem Res* 2005; 104: 131–140
- [49] Sutton RAL, Mumm S, Coburn SP et al. “Atypical femoral fractures” during bisphosphonate exposure in adult hypophosphatasia. *J Bone Miner Res* 2012; 27: 987–994
- [50] Schalin-Jäntti C, Mornet E, Lamminen A et al. Parathyroid hormone treatment improves pain and fracture healing in adult hypophosphatasia. *J Clin Endocrinol Metab* 2010; 95: 5174–5179
- [51] Doshi KB, Hamrahian AH, Licata AA. Teriparatide treatment in adult hypophosphatasia in a patient exposed to bisphosphonate: a case report. *Clin Cases Miner Bone Metab* 2009; 6: 266–269
- [52] Laroche M. Failure of teriparatide in treatment of bone complications of adult hypophosphatasia. *Calcif Tissue Int* 2012; 90: 250–250
- [53] Gagnon C, Sims NA, Mumm S et al. Lack of sustained response to teriparatide in a patient with adult hypophosphatasia. *J Clin Endocrinol Metab* 2010; 95: 1007–1012
- [54] Choida V, Bubbear JS. Update on the management of hypophosphatasia. *Ther Adv Musculoskelet Dis* 2019; 11: 1759720X19863997. doi:10.1177/1759720X19863997
- [55] Lewiecki EM. Role of sclerostin in bone and cartilage and its potential as a therapeutic target in bone diseases. *Ther Adv Musculoskelet Dis* 2014; 6: 48–57
- [56] Li X, Ominsky MS, Niu Q-T et al. Targeted deletion of the sclerostin gene in mice results in increased bone formation and bone strength. *J Bone Miner Res* 2008; 23: 860–869
- [57] McClung MR, Grauer A, Boonen S et al. Romosozumab in postmenopausal women with low bone mineral density. *N Engl J Med* 2014; 370: 412–420
- [58] Seefried L, Baumann J, Hemsley S et al. Efficacy of anti-sclerostin monoclonal antibody BPS804 in adult patients with hypophosphatasia. *J Clin Invest* 2017; 127: 2148–2158
- [59] Fedde KN, Blair L, Silverstein J et al. Alkaline phosphatase knock-out mice recapitulate the metabolic and skeletal defects of infantile hypophosphatasia. *J Bone Miner Res* 1999; 14: 2015–2026
- [60] Millán JL, Narisawa S, Lemire I et al. Enzyme replacement therapy for murine hypophosphatasia. *J Bone Miner Res* 2008; 23: 777–787
- [61] McKee MD, Nakano Y, Masica DL et al. Enzyme replacement therapy prevents dental defects in a model of hypophosphatasia. *J Dent Res* 2011; 90: 470–476
- [62] Whyte MP, Greenberg CR, Salman NJ et al. Enzyme-replacement therapy in life-threatening hypophosphatasia. *N Engl J Med* 2012; 366: 904–913
- [63] Whyte MP, Simmons JH, Moseley S et al. Asfotase alfa for infants and young children with hypophosphatasia: 7 year outcomes of a single-arm, open-label, phase 2 extension trial. *Lancet Diabetes Endocrinol* 2019; 7: 93–105
- [64] Hofmann CE, Harmatz P, Vockley J et al. Efficacy and safety of asfotase alfa in infants and young children with hypophosphatasia: a phase 2 open-label study. *J Clin Endocrinol Metab* 2019; 104: 2735–2747
- [65] Whyte MP, Madson KL, Phillips D et al. Asfotase alfa therapy for children with hypophosphatasia. *JCI Insight* 2016; 1: e85971
- [66] Schroth RJ, Long C, Lee VHK et al. Dental outcomes for children receiving asfotase alfa for hypophosphatasia. *Bone* 2021; 152: 116089
- [67] Kishnani PS, Rockman-Greenberg C, Rauch F et al. Five-year efficacy and safety of asfotase alfa therapy for adults and adolescents with hypophosphatasia. *Bone* 2019; 121: 149–162
- [68] Stürznickel J, Schmidt FN, von Vopelius E et al. Bone healing and reactivation of remodeling under asfotase alfa therapy in adult patients with pediatric-onset hypophosphatasia. *Bone* 2021; 143: 115794
- [69] Seefried L, Rak D, Petryk A et al. Bone turnover and mineral metabolism in adult patients with hypophosphatasia treated with asfotase alfa. *Osteoporos Int* 2021; 32: 2505–2513

- [70] Kishnani PS, del Angel G, Zhou S et al. Investigation of ALPL variant states and clinical outcomes: An analysis of adults and adolescents with hypophosphatasia treated with asfotase alfa. *Mol Genet Metab* 2021; 133: 113–121
- [71] Klidas P, Severt J, Aggers D et al. Fracture healing in two adult patients with hypophosphatasia after asfotase alfa therapy. *JBMR Plus* 2018; 2: 304–307
- [72] Rolvien T, Schmidt T, Schmidt FN et al. Recovery of bone mineralization and quality during asfotase alfa treatment in an adult patient with infantile-onset hypophosphatasia. *Bone* 2019; 127: 67–74
- [73] Freitas TQ, Franco AS, Pereira RMR. Improvement of bone microarchitecture parameters after 12 months of treatment with asfotase alfa in adult patient with hypophosphatasia: Case report. *Medicine* 2018; 97: e13210
- [74] Genest F, Rak D, Petryk A et al. Physical function and health-related quality of life in adults treated with asfotase alfa for pediatric-onset hypophosphatasia. *JBMR Plus* 2020; 4: e10395
- [75] Magdaleno AL, Singh S, Venkataraman S et al. Adult-onset hypophosphatasia: before and after treatment with asfotase alfa. *AACE Clin Case Rep* 5: e344–e348
- [76] Kitaoka T, Tajima T, Nagasaki K et al. Safety and efficacy of treatment with asfotase alfa in patients with hypophosphatasia: Results from a Japanese clinical trial. *Clin Endocrinol (Oxf)* 2017; 87: 10–19
- [77] Kishnani PS, Rush ET, Arundel P et al. Monitoring guidance for patients with hypophosphatasia treated with asfotase alfa. *Mol Genet Metab* 2017; 122: 4–17
- [78] Bowden SA, Adler BH. Reappearance of hypomineralized bone after discontinuation of asfotase alfa treatment for severe childhood hypophosphatasia. *Osteoporos Int* 2018; 29: 2155–2156
- [79] Khan AA, Josse R, Kannu P et al. Hypophosphatasia: Canadian update on diagnosis and management. *Osteoporos Int* 2019; 30: 1713–1722