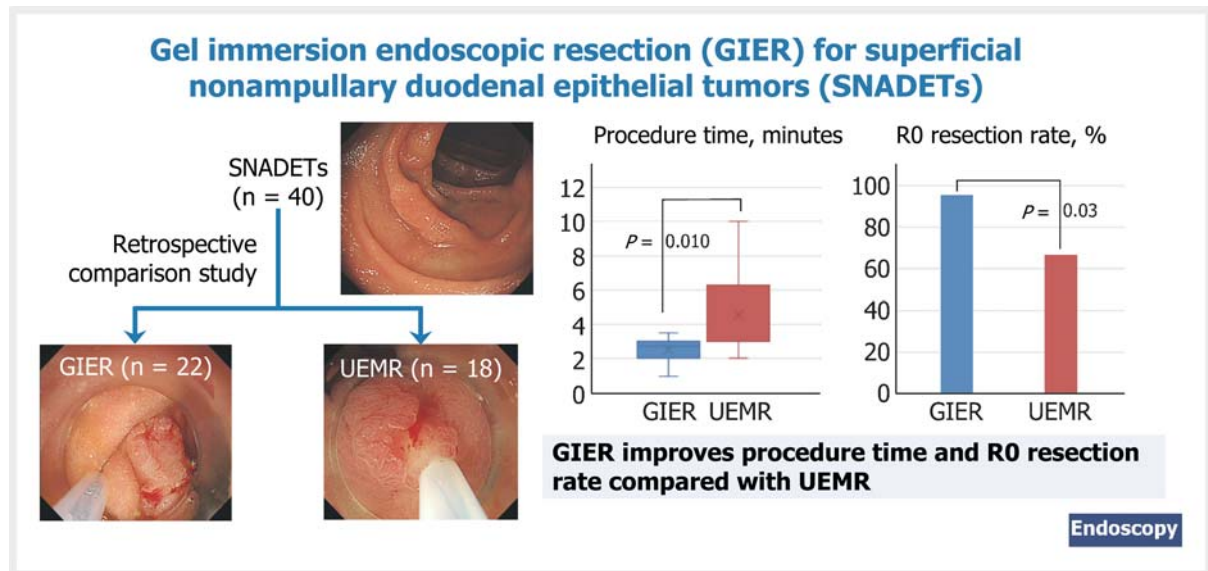


A feasibility study comparing gel immersion endoscopic resection and underwater endoscopic mucosal resection for superficial nonampullary duodenal epithelial tumors

OPEN
ACCESS

GRAPHICAL ABSTRACT



Authors

Akihiro Miyakawa¹, Toshio Kuwai², Yukie Sakuma³, Manabu Kubota¹, Akira Nakamura¹, Ei Itobayashi¹, Haruhisa Shimura¹, Yoshio Suzuki⁴, Kenji Shimura¹

Institutions

- 1 Department of Gastroenterology, Asahi General Hospital, Chiba, Japan
- 2 Department of Gastroenterology, National Hospital Organization Kure Medical Center and Chugoku Cancer Center, Hiroshima, Japan
- 3 Clinical Research Center, Asahi General Hospital, Chiba, Japan
- 4 Department of Pathology, Asahi General Hospital, Chiba, Japan

submitted 19.1.2022

accepted after revision 11.8.2022

published online 15.8.2022

Bibliography

Endoscopy 2023; 55: 261–266

DOI 10.1055/a-1924-4711

ISSN 0013-726X

© 2022. The Author(s).

This is an open access article published by Thieme under the terms of the Creative Commons Attribution-NonDerivative-NonCommercial License, permitting copying and reproduction so long as the original work is given appropriate credit. Contents may not be used for commercial purposes, or adapted, remixed, transformed or built upon. (<https://creativecommons.org/licenses/by-nc-nd/4.0/>)

Georg Thieme Verlag KG, Rüdigerstraße 14,
70469 Stuttgart, Germany

Corresponding author

Akihiro Miyakawa, MD, Department of Gastroenterology, Asahi General Hospital, 1326 I, Asahi, Chiba, 289-2511, Japan
a292miyaka2007@yahoo.co.jp

ABSTRACT

Background Although gel immersion endoscopic resection (GIER) is a potential alternative to underwater endoscopic mucosal resection (UEMR) for superficial nonampullary duodenal epithelial tumors (SNADETs), comparisons between the two are currently insufficient.

Methods 40 consecutive procedures performed in 35 patients were retrospectively reviewed; the primary outcome was procedure time, and the secondary outcomes were en bloc and R0 resection rates, tumor and specimen size, and adverse events.

Results Lesions were divided into GIER ($n=22$) and UEMR groups ($n=18$). The median (range) procedure time was significantly shorter in the GIER group than in the UEMR group (2.75 [1–3.5] minutes vs. 3 [2–10] minutes; $P=0.01$). The en bloc resection rate was 100% in the GIER group, but only 83.3% in the UEMR group. The R0 resection rate was significantly higher in the GIER group than in the UEMR group (95.5% vs. 66.7%; $P=0.03$). The median specimen size was larger in the GIER group than in the UEMR group (14 mm vs. 7.5 mm; $P<0.001$). The tumor size was not significantly different between the groups and no adverse events were observed.

Conclusions GIER is efficacious and safe to treat SNADETs, although additional studies are needed.

Introduction

Although superficial nonampullary duodenal epithelial tumors (SNADETs) were previously considered rare, their recognition has been increasing following an improvement in endoscopic accuracy [1–5]. The opportunities to perform endoscopic resection of SNADETs have therefore recently increased; however, it is considered extremely difficult because of the technical challenges posed by the complex anatomic features of the duodenum [2, 4, 5]. Recently, the safety and efficacy of underwater endoscopic mucosal resection (UEMR) have been increasingly reported [6–15]. UEMR is a water immersion method leading to easy snaring and a low perforation risk [2, 7, 11–14]. Therefore, UEMR is a favorable treatment and results in high resection and low adverse event (AE) rates [4, 7–9, 13–15]. However, continuously maintaining water in the lumen is difficult, leading to large-volume water injection and a long procedure time [6, 13].

Recently, a novel gelatinous liquid (Viscoclear; Otsuka Pharmaceuticals Factory, Inc., Tokushima, Japan) was developed to secure the visual field during endoscopy [16, 17]. This gelatinous liquid comprises xanthan gum, locust bean gum, and glycerin [16]. The viscoelastic properties of the gelatinous liquid enable continuous filling of the lumen and prevent its mixing with fresh blood or feces, resulting in a favorable space for endoscopic visualization and treatment [16, 17]. Yano et al. reported that use of an immersing gelatinous liquid during endoscopy resulted in a favorable visual field and named this method gel immersion endoscopy [16–18]. Applying these features, we devised gel immersion endoscopic resection (GIER), a gel-based EMR technique, as an alternative method to water-based UEMR, and reported its efficacy [19].

Although GIER may effectively treat SNADETs, there have been no reports comparing GIER and UEMR. Therefore, we retrospectively investigated the short-term clinical outcomes of GIER as a treatment for SNADETs as compared with UEMR.

Methods

Study design and participants

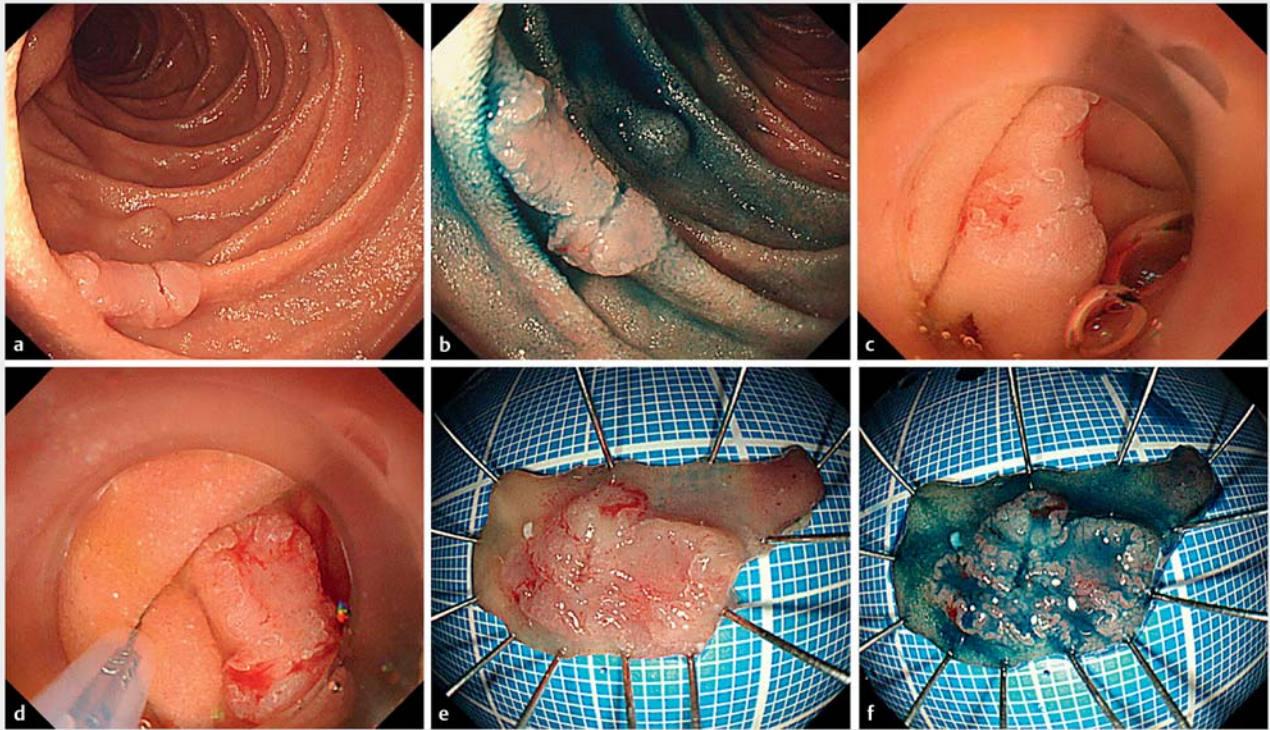
We retrospectively reviewed the outcomes of 40 consecutive SNADET cases treated by GIER and UEMR in 35 patients between April 2019 and December 2021 at Asahi General Hospital, Japan. Because the gelatinous liquid was launched in the Japanese market in October 2020, the 18 consecutive cases before the launch (between April 2019 and September 2020) were treated with UEMR, whereas the 22 consecutive cases after the launch (between October 2020 and December 2021) were treated with GIER.

The institutional review board of Asahi General Hospital approved this retrospective study (16 March 2021). Written informed consent for the procedure was obtained from all the patients. Endoscopic resection was indicated for SNADETs ≤ 20 mm in size.

Procedures

Two board-certified fellows of the Japan Gastroenterological Endoscopy Society and one trainee performed all of the procedures. The patients were admitted 1 day prior to endoscopic resection or on the day of the procedure, and remained in the hospital for approximately 5 days. A gastroscope (GIF-Q260; Olympus Medical Systems, Tokyo, Japan) was used with carbon dioxide insufflation.

For GIER, the gelatinous liquid was injected gently using a syringe, continuously filling the lumen; for UEMR, water was injected. Carbon dioxide insufflation was discontinued during immersion and resection. The lesion was captured using a 10-mm (AG-5076-241023; Hangzhou AGS MedTech Co., Ltd., Zhejiang, China), 13-mm (M00562451; Boston Scientific, Massachusetts, United States), 15-mm (AG-5076-241523; Hangzhou AGS MedTech Co., Ltd.), and 20-mm electrocautery snare (M00561831; Boston Scientific) as appropriate under liquid immersion. The current was passed using a high frequency generator (VIO300D; Erbe Elektromedizin, Tübingen, Germany). The high frequency generator was used with dry-cut mode (effect 4, 40W) for mucosal resection. Prophylactic clip closure



► **Fig. 1** Example of gel immersion endoscopic resection of a superficial nonampullary duodenal epithelial tumor. **a–d** Endoscopic views showing: **a,b** a superficial 11-mm elevated and depressed lesion in the second part of the duodenum; **c** the favorable visual field after the lesion had been immersed in a gelatinous liquid; **d** a sufficient horizontal margin being easily confirmed with the lesion under the gelatinous liquid. **e,f** Macroscopic appearance of the en bloc resected lesion after it had been easily captured using an electrocautery snare, resulting in a specimen of 25 × 10 mm, containing a tumor of 11 × 8 mm that was pathologically diagnosed as a well-differentiated adenocarcinoma with negative margins.

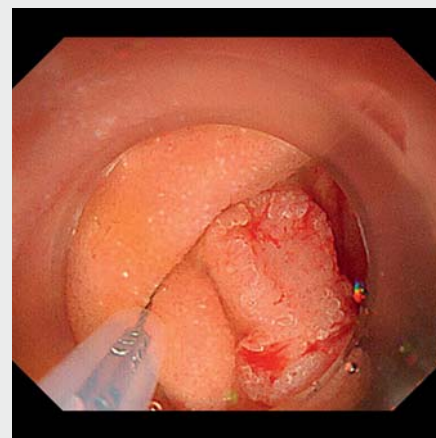
was performed for all cases using endoclips (HX-610–135S; Olympus).

A second-look endoscopy was routinely performed in all cases. All patients received 20 mg intravenous omeprazole for the first 2 days, beginning on the day of the procedure. Thereafter, 20 mg rabeprazole daily was prescribed for approximately 30 days. Treatment of a patient using GIER is shown in ► **Fig. 1** and ► **Video 1**.

The resected specimens were embedded in paraffin and subjected to staining with hematoxylin and eosin for histopathological diagnosis. R0 resection was defined as an en bloc resection where both the horizontal and vertical margins were negative. For en bloc resection specimens, we considered adenomas with unclear lateral margins and expected lateral burning effect as negative margins.

Outcome definitions

The primary outcome was procedure time, defined as the time from liquid immersion into the lumen to resection. The secondary outcomes were en bloc resection rate, R0 resection rate, tumor size, specimen size, and AEs, such as delayed bleeding and perforation. Delayed bleeding was defined as hematemesis or melena requiring endoscopic hemostasis or blood transfusion, or leading to a reduction ≥ 2 g/dL in hemoglobin level.



► **Video 1** Demonstration of the gel immersion endoscopic resection technique for a superficial nonampullary duodenal epithelial tumor.

Online content viewable at:
<https://doi.org/10.1055/a-1924-4711>

Statistical analyses

Continuous variables were reported as the median and range, and compared using the Mann–Whitney–Wilcoxon test. Differences in the categorical variables were analyzed using the likelihood ratio test and Fisher's exact test. These analyses were conducted at the Clinical Research Support Center of Asahi General Hospital. A two-sided *P* value of <0.05 was considered statistically significant. All statistical analyses were performed using the JMP version 16.1.0 software (SAS Institute Japan, Tokyo, Japan).

Results

Patient and lesion characteristics in the GIER and UEMR groups

Overall, 35 patients were treated with 40 consecutive endoscopic resection procedures. UEMR was performed for the first 18 cases, while GIER was performed for the latter 22 cases. The comparison of patient and lesion characteristics between GIER and UEMR groups is presented in ► **Table 1**. No significant differences were observed in the patient and lesion characteristics.

Treatment outcomes in the GIER and UEMR groups

The median (range) procedure time was significantly shorter in the GIER group than in the UEMR group (2.75 [1–3.5] minutes vs. 3 [2–10] minutes; *P*=0.01) (► **Table 2**). The en bloc resection rate was 100% (95%CI 85.1%–100%) in the GIER group, but only 83.3% (95%CI 60.8%–94.2%) in the UEMR group (*P*=0.08). The R0 resection rate was significantly higher in the GIER group than in the UEMR group (95.5% [95%CI 78.2%–99.2%] vs. 66.7% [95%CI 43.7%–83.7%]; *P*=0.03). The median (range) specimen size was larger in the GIER group than in the UEMR group (14 [7–27] mm vs. 7.5 [4–11] mm; *P*<0.001). Tumor size and histological type were not significantly different between the groups. No AEs, such as perforation and delayed bleeding, were observed in the groups. The median (range) amount of gelatinous liquid used during a procedure was 180 (60–300) mL in the GIER group.

Discussion

This study observed that GIER, a form of gel immersion endoscopy, resulted in a short procedure time. Moreover, GIER enabled the resection of a larger specimen size and led to an increased R0 resection rate.

We observed that the procedure time was significantly shorter in the GIER group than in the UEMR group. A Japanese multicenter prospective study reported that the procedure time for treatment with UEMR was 5.4 (SD 4.3) minutes [14]. Moreover, the previous reports comparing UEMR and conventional EMR revealed that the procedure times were 4–7 minutes and 9.5–12 minutes, respectively [12, 13,20]. We believe that our procedure time in patients treated with GIER is markedly shorter than previously reported for treatment with UEMR and conventional EMR. The gelatinous liquid used in GIER allows for

► **Table 1** Patient and lesion characteristics in the gel immersion endoscopic resection (GIER) and underwater endoscopic mucosal resection (UEMR) groups.

| | GIER | UEMR | <i>P</i> value |
|---|---------------|---------------|-------------------|
| Patients, n | 19 | 16 | |
| Age, median (range), years | 67 (45–81) | 63 (35–80) | 0.25 ¹ |
| Sex, n (%) | | | 0.72 ² |
| ▪ Male | 13 (68.4) | 12 (75.0) | |
| ▪ Female | 6 (31.6) | 4 (25.0) | |
| Lesions, n | 22 | 18 | |
| Location, n (%) | | | 0.43 ³ |
| ▪ Bulb | 3 (13.6) | 1 (5.6) | |
| ▪ Second portion | 16 (72.7) | 16 (88.9) | |
| ▪ Third portion | 3 (13.6) | 1 (5.6) | |
| Macroscopic type, n (%) | | | 0.19 ³ |
| ▪ 0-I | 6 (27.3) | 1 (5.6) | |
| ▪ 0-IIa | 9 (40.9) | 10 (55.6) | |
| ▪ 0-IIc | 3 (13.6) | 5 (27.8) | |
| ▪ 0-IIa + IIc | 4 (18.2) | 2 (11.1) | |
| 0-I, protruding; 0-IIa, superficial elevated; 0-IIc, superficial depressed. | | | |
| ¹ Mann–Whitney–Wilcoxon test. | | | |
| ² Fisher's exact test. | | | |
| ³ Likelihood ratio test. | | | |

easier maintenance of continuous lumen filling compared with water, and an additional infusion is unnecessary, leading to a short infusion time [19]. Furthermore, the viscoelastic properties of the gelatinous liquid enable a favorable transparent visual field to be maintained, resulting in easy snaring [19]. These factors might have led to a short procedure time.

The en bloc resection rate tended to be higher in the GIER group, while the R0 resection rate was significantly higher in the GIER group than in the UEMR group. Moreover, the specimen size was larger in the GIER group than in the UEMR group. The previous reports comparing UEMR and conventional EMR revealed that the en bloc resection rates were 75.4%–96.4% and 60.9%–96.4%, respectively [11–13, 15,20]. Moreover, R0 resection rates were 50.8%–76.1% and 34.8%–79.6%, respectively [11–13, 15,20]. In comparison with these reports, we believe that the en bloc and R0 resection rates for treatment with GIER are favorable. As mentioned previously, the favorable visual field under the gelatinous liquid might assist with snaring by allowing a sufficient horizontal margin to be determined, leading to a high resection rate and a large specimen.

A Japanese multicenter retrospective study reported that the en bloc resection rate was significantly lower in patients undergoing UEMR compared with conventional EMR, especially for large lesions [20]. Furthermore, a single-center study revealed that UEMR had lower en bloc and R0 resection rates

► **Table 2** Treatment outcomes of the gel immersion endoscopic resection (GIER) and underwater endoscopic mucosal resection (UEMR) groups.

| | GIER | UEMR | P value |
|---|-------------------------|-------------------------|---------------------|
| Tumor size, median (range), mm | 7 (2–18) | 5 (3–10) | 0.48 ¹ |
| Specimen size, median (range), mm | 14 (7–27) | 7.5 (4–11) | <0.001 ¹ |
| Pathology, n (%) | | | 0.18 ³ |
| ▪ Adenocarcinoma | 1 (4.6) | 4 (22.2) | |
| ▪ Adenoma | 18 (81.8) | 13 (72.2) | |
| ▪ Other | 3 (13.6) | 1 (5.6) | |
| Procedure time, median (range), minutes | 2.75 (1–3.5) | 3 (2–10) | 0.01 ¹ |
| En bloc resection, n (% [95%CI]) | 22 (100 [85.1%–100%]) | 15 (83.3 [60.8%–94.2%]) | 0.08 ² |
| R0 resection, n (% [95%CI]) | 21 (95.5 [78.2%–99.2%]) | 12 (66.7 [43.7%–83.7%]) | 0.03 ² |
| Adverse events, n | 0 (0) | 0 (0) | |
| Liquid consumption, median (range), mL | 180 (60–300) | No data | |

compared with conventional EMR, although the rate of conversion to endoscopic submucosal dissection was reduced [11]. We believe that GIER leads to a large specimen with en bloc resection and can eliminate the drawbacks of UEMR. Moreover, as these advantages may be applicable to the colon, validation through further research is warranted.

When performing GIER, it is necessary to consider the electrical conduction properties of the gelatinous liquid, as well as the risks of current transmission to the wall and delayed transmural thermal injury. As the gelatinous liquid does not contain electrolytes, it has the advantage of not discharging when monopolar devices are used [16, 17]. Yano et al. established appropriate electrical conductivity using rat liver and developed the dedicated gel [16]. They also verified the efficacy of electrocoagulation under the gelatinous liquid with monopolar hemostatic forceps in a porcine model and revealed that severe coagulative necrosis was not observed in the muscularis but was limited to the mucosa [16]. Therefore, we believe that the efficacy of electrocoagulation is favorable and that the risks of current transmission to the wall and delayed transmural thermal injury are low.

Although we propose GIER as a novel replacement method for UEMR, GIER has some drawbacks. First, the gelatinous liquid costs 2000 Japanese Yen per 200 mL, which is more expensive than water. Therefore, a validation of GIER cost-effectiveness is warranted. Second, the specific gravity of the gelatinous liquid is heavier than that of water, which may cause loss of buoyancy of the mucosal and submucosal layers, thereby reducing the advantage offered by the water immersion method. Furthermore, the viscosity of the gelatinous liquid may possibly affect the opening and closing of the snare. These issues might make snaring difficult and lead to perforation and a low resection rate; however, our previous reports revealed that the buoyancy of the mucosal and submucosal layers was favorable and similar to that in underwater endoscopy based on endoscopic ultrasonography findings [19]. Additionally, there was no difficulty in manipulating the snare. In fact, the resection rate was

high in the present study and no cases of perforation were observed.

This study has several limitations. First, this was a single-center retrospective pilot study with a small sample size. Furthermore, some patients were included several times. As a result, we cannot exclude the possibility of statistical dependencies. It should be noted however that GIER is a novel treatment method, and there are no case-control studies or comparative studies with regard to the treatment of SNADET with GIER. Second, the impact of a learning curve and device improvement cannot be denied. In this study, UEMR was performed for the first 18 cases, while GIER was performed for the latter 22 cases. The improvement in technique owing to the learning curve and the use of a novel snare might have led to favorable outcomes in the GIER group. Third, the consumption of water was not recorded in the UEMR group. Therefore, it is unclear whether GIER really reduced the liquid consumption compared with UEMR. Finally, long-term clinical outcomes, such as local residual recurrence, were not validated. The evaluation of whether GIER is definitely an effective treatment requires the verification of long-term outcomes, and additional time is needed.

In conclusion, the gelatinous liquid enables continuous lumen filling and secures a favorable visual field. GIER is a method that applies these features and might result in a short and safe procedure. Therefore, GIER has the potential to be a novel treatment method for SNADETs. To confirm its efficacy, multi-center prospective studies on the short- and long-term clinical outcomes are needed.

Acknowledgments

We are grateful to Yasunori Sato (Department of Preventive Medicine and Public Health, Keio University School of Medicine, Tokyo, Japan) for his insightful comments. This study was supported by the Clinical Research Support Center at Asahi General Hospital, Chiba, Japan. We thank all support team members.

Competing interests

The authors declare that they have no conflict of interest.

References

- [1] Goda K, Kikuchi D, Yamamoto Y et al. Endoscopic diagnosis of superficial non-ampullary duodenal epithelial tumors in Japan: multicenter case series. *Dig Endosc* 2014; 26: (Suppl. 02): 23–29
- [2] Yamasaki Y, Uedo N, Takeuchi Y et al. Current status of endoscopic resection for superficial nonampullary duodenal epithelial tumors. *Digestion* 2018; 97: 45–51
- [3] Yoshida M, Yabuuchi Y, Kakushima N et al. The incidence of non-ampullary duodenal cancer in Japan: the first analysis of a national cancer registry. *J Gastroenterol Hepatol* 2021; 36: 1216–1221
- [4] Vanbiervliet G, Moss A, Arvanitakis M et al. Endoscopic management of superficial nonampullary duodenal tumors: European Society of Gastrointestinal Endoscopy (ESGE) Guideline. *Endoscopy* 2021; 53: 522–534
- [5] Kato M, Kanai T, Yahagi N et al. Endoscopic resection of superficial non-ampullary duodenal epithelial tumor. *DEN Open* 2022; 2: e54
- [6] Binmoeller KF, Shah JN, Bhat YM et al. “Underwater” EMR of sporadic laterally spreading nonampullary duodenal adenomas (with video). *Gastrointest Endosc* 2013; 78: 496–502
- [7] Yamasaki Y, Uedo N, Takeuchi Y et al. Underwater endoscopic mucosal resection for superficial nonampullary duodenal adenomas. *Endoscopy* 2018; 50: 154–158
- [8] Shibukawa G, Irisawa A, Sato A et al. Endoscopic mucosal resection performed underwater for nonampullary duodenal epithelial tumor: evaluation of feasibility and safety. *Gastroenterol Res Pract* 2018; 2018: 7490961
- [9] Bhogal N, Mohan B, Chandan S et al. Efficacy and safety of underwater endoscopic mucosal resection for superficial non-ampullary duodenal epithelial tumors: a systematic review and meta-analysis. *Ann Gastroenterol* 2020; 33: 379–384
- [10] Iwagami H, Takeuchi Y, Yamasaki Y et al. Feasibility of underwater endoscopic mucosal resection and management of residues for superficial non-ampullary duodenal epithelial neoplasms. *Dig Endosc* 2020; 32: 565–573
- [11] Kiguchi Y, Kato M, Nakayama A et al. Feasibility study comparing underwater endoscopic mucosal resection and conventional endoscopic mucosal resection for superficial non-ampullary duodenal epithelial tumor < 20 mm. *Dig Endosc* 2020; 32: 753–760
- [12] Hirasawa K, Ozeki Y, Sawada A et al. Appropriate endoscopic treatment selection and surveillance for superficial non-ampullary duodenal epithelial tumors. *Scand J Gastroenterol* 2021; 56: 342–350
- [13] Furukawa M, Mitoro A, Ozutumi T et al. Efficacy of underwater endoscopic mucosal resection for superficial non-ampullary duodenal epithelial tumor. *Clin Endosc* 2021; 54: 371–378
- [14] Yamasaki Y, Uedo N, Akamatsu T et al. Nonrecurrence rate of underwater EMR for ≤ 20 -mm nonampullary duodenal adenomas: a multicenter prospective study (D-UEMR study). *Clin Gastroenterol Hepatol* 2022; 20: 1010–1018
- [15] Okimoto K, Maruoka D, Matsumura T et al. Utility of underwater EMR for nonpolypoid superficial nonampullary duodenal epithelial tumors ≤ 20 mm. *Gastrointest Endosc* 2022; 95: 140–148
- [16] Yano T, Ohata A, Hiraki Y et al. Development of a gel dedicated to gel immersion endoscopy. *Endosc Int Open* 2021; 9: E918–E924
- [17] Yano T, Takezawa T, Hashimoto K et al. Gel immersion endoscopy: innovation in securing the visual field—clinical experience with 265 consecutive procedures. *Endosc Int Open* 2021; 9: E1123–E1127
- [18] Yano T, Nemoto D, Ono K et al. Gel immersion endoscopy: a novel method to secure the visual field during endoscopy in bleeding patients (with videos). *Gastrointest Endosc* 2016; 83: 809–811
- [19] Miyakawa A, Kuwai T, Miyauchi T et al. Gel immersion endoscopy-facilitated endoscopic mucosal resection of a superficial nonampullary duodenal epithelial tumor: a novel approach. *VideoGIE* 2021; 6: 422–426
- [20] Kato M, Takeuchi Y, Hoteya S et al. Outcomes of endoscopic resection for superficial duodenal tumors: 10 years’ experience in 18 Japanese high volume centers. *Endoscopy* 2022; 54: 663–670