

Noninvasive Evaluation of Clinically Significant Portal Hypertension in Patients with Liver Cirrhosis: The Role of Contrast-Enhanced Ultrasound Perfusion Imaging and Elastography

Nicht invasive Bewertung der klinisch signifikanten portalen Hypertonie bei Patienten mit Leberzirrhose: Die Rolle der kontrastverstärkten Ultraschall-Perfusionsbildgebung und der Elastografie

Authors

Maria Assunta Zocco^{1, 2}, Marco Cintoni³, Maria Elena Ainora², Matteo Garcovich², Andrea Lupascu², Roberto Iezzi⁴, Brigida Eleonora Annichiarico², Massimo Siciliano², Laura Riccardi², Gian Ludovico Rapaccini², Antonio Grieco², Maurizio Pompili², Antonio Gasbarrini²

Affiliations

- 1 Internal Medicine, Università Cattolica del Sacro Cuore, Rome, Italy
- 2 CEMAD Digestive Disease Center, Fondazione Policlinico Universitario A. Gemelli IRCCS, Rome, Italy
- 3 Clinical Nutrition, University of Rome Tor Vergata, Roma, Italy
- 4 Radiology, University Hospital Agostino Gemelli, Rome, Italy

Key words

liver stiffness, clinically significant portal hypertension, liver cirrhosis, dynamic contrast-enhanced ultrasound

received 01.10.2021

accepted 05.08.2022

published online 16.12.2022

Bibliography

Ultraschall in Med 2023; 44: 428–435

DOI 10.1055/a-1933-2847


ISSN 0172-4614

© 2022, Thieme. All rights reserved.

Georg Thieme Verlag KG, Rüdigerstraße 14,
70469 Stuttgart, Germany

Correspondence

Dr. Maria Assunta Zocco
Università Cattolica del Sacro Cuore
Internal Medicine, Largo Gemelli 8, 00168 Rome, Italy
mariaazocco@hotmail.com

 Additional material is available at <https://doi.org/10.1055/a-1933-2847>.

ABSTRACT

Background Hepatic venous pressure gradient (HVPG) is the gold standard for assessing the degree of portal hypertension

(PH), but it is not suitable for routine clinical use. The recently developed ultrasonography techniques, dynamic contrast-enhanced ultrasound (D-CEUS) and liver stiffness (LS), have expanded the possibilities for noninvasive evaluation.

Aims To investigate the usefulness of D-CEUS and elastographic parameters in assessing the presence and degree of PH.

Methods This is a prospective monocentric study. Patients with liver cirrhosis referred for HVPG measurements underwent hepatic Doppler ultrasound, LS measurement, and D-CEUS with a second-generation contrast agent. Pearson's correlation and a receiver operating characteristic (ROC) curve analysis were performed to assess the role of noninvasive findings in predicting clinically significant PH (CSPH) and severe PH (SPH).

Results 46 consecutive patients (31 men; mean age±SD: 57 ± 11 years) were enrolled. A significant positive correlation was noted between LS and HVPG ($r=0.809$, $p<0.0001$) with an area under the ROC curve of 0.923. A cut-off value of 24.2 kPa best predicted CSPH with a positive predictive value of 85%. Among the D-CEUS features, the area under the ROC curves of liver parenchyma peak intensity (PI-LP) was greater than the other indices both for CSPH and SPH (1.000 and 0.981, respectively). A PI-LP under 23.3 arbitrary units indicated the presence of CSPH with a sensitivity and a specificity of 100%.

Conclusion A multimodal ultrasound approach based on D-CEUS and LS might become a reliable predictor of CSPH and SPH and a useful alternative to HVPG.

ZUSAMMENFASSUNG

Hintergrund Der hepatische Venendruckgradient (HVPG) ist der Goldstandard zur Beurteilung des Schweregrads der portalen Hypertonie (PH), eignet sich jedoch nicht für den Einsatz in der klinischen Praxis. Die kürzlich entwickelten Ultraschall-techniken, der dynamische kontrastverstärkte Ultraschall

(D-CEUS) und die Lebersteifigkeit (LS), haben die Möglichkeiten der nicht invasiven Untersuchung erweitert.

Ziel Untersuchung des Nutzens von D-CEUS und elastografischen Parametern bei der Diagnose einer PH und Beurteilung ihres Schweregrads.

Methoden Dies ist eine prospektive monozentrische Studie. Bei Patienten mit Leberzirrhose, die zur HVPG-Messung überwiesen wurden, wurden hepatischer Doppler-Ultraschall, LS-Messung und D-CEUS mit einem Kontrastmittel der 2. Generation durchgeführt. Es wurden eine Pearson-Korrelation und eine ROC-Kurvenanalyse (Receiver Operating Characteristic) durchgeführt, um die Rolle nicht invasiver Befunde bei der Vorhersage einer klinisch signifikanten PH (CSPH) und der schweren PH (SPH) zu bewerten.

Ergebnisse Es wurden 46 konsekutive Patienten (31 Männer; Durchschnittsalter \pm SD: 57 \pm 11 Jahre) eingeschlossen. Eine

signifikante positive Korrelation wurde zwischen LS und HVPG ($r = 0,809$, $p < 0,0001$) mit einer Fläche unter der ROC-Kurve von 0,923 festgestellt. Ein Cut-Off-Wert von 24,2 kPa erlaubte die beste Vorhersage für CSPH mit einem positiven Vorhersagewert von 85 %. Unter den D-CEUS-Merkmalen war die Fläche unter den ROC-Kurven der Peak-Intensität des Leberparenchyms (PI-LP) sowohl für CSPH als auch für SPH größer (1,000 bzw. 0,981) als die anderen Indizes. Eine PI-LP unter 23,3 arbiträren Einheiten sprach für eine CSPH mit einer Sensitivität und einer Spezifität von 100 %.

Schlussfolgerung Ein multimodaler Ultraschallansatz, basierend auf D-CEUS und LS, könnte ein zuverlässiger Prädiktor für CSPH und SPH sowie eine nützliche Alternative zum HVPG werden.

Introduction

Portal hypertension (PH) is a nearly inevitable consequence of liver cirrhosis since between 80 % and 90 % of asymptomatic patients already have an elevated portal pressure gradient [1]. The increase in portal pressure can result in many other clinical complications that affect prognosis and the natural history of the disease and include variceal bleeding, ascites, spontaneous bacterial peritonitis, hepatorenal syndrome, and hepatic encephalopathy [2]. As a consequence, the precise grading of PH becomes essential for the treatment and follow-up of patients with cirrhosis.

Until now, the measurement of the hepatic venous pressure gradient (HVPG) has been recognized as the gold standard for classifying PH [3]. However, routine use of HVPG in the clinical setting is limited by its invasiveness and the needs for skilled expertise.

The recently developed contrast-enhanced ultrasound (CEUS) perfusion imaging has markedly expanded the possibilities for detailed hepatic hemodynamics [4]. It has been demonstrated that CEUS-based analysis of the transit time between the hepatic vein (HV) and hepatic artery (HA) or portal vein (PV), can be useful for predicting the grade of PH [5, 6, 7, 8].

A correlation has been reported between regional hepatic perfusion evaluated through the analysis of microbubble kinetics after CEUS and PH in patients with cirrhosis [9].

Since fibrosis is the main determinant of tissue stiffness and hepatic resistance to portal blood flow, liver stiffness (LS) measurement has been tested in recent years as a novel way of obtaining noninvasive evaluation of portal pressure.

Several lines of evidence have demonstrated that transient elastography (TE) is useful for assessing the severity of PH [10, 11, 12]. Moreover, noninvasive Baveno and expanded Baveno criteria based on platelet count and LS assessment have shown high applicability in identifying patients without high-risk gastroesophageal varices who had no need of endoscopic surveillance [3].

A recent study demonstrated that the combination of LS and perfusion parameters obtained with dynamic contrast-enhanced magnetic resonance imaging provides excellent accuracy for diagnosing PH since both hepatic fibrosis and altered hepatic blood flow are involved in the pathogenesis of this syndrome [13].

Hence, the present study will prospectively evaluate the diagnostic performance of perfusion parameters measured by D-CEUS and LS assessment by point shear wave elastography (pSWE) for the prediction of PH in patients with liver cirrhosis. The secondary aim was to identify the optimal cut-off of selected parameters for the diagnosis of CSPH and severe portal hypertension (SPH).

Patients and Methods

Patients

Between January 2017 and February 2019, all consecutive patients with liver cirrhosis who were scheduled for HVPG measurements in our Department of Internal Medicine and Gastroenterology were enrolled in this prospective study.

According to international guidelines, the indication for HVPG measurement was suspected advanced liver disease based on imaging and biochemical data [3].

Patients with liver cirrhosis were enrolled. Additional inclusion criteria were age > 18 years and consent to HVPG measurement. Patients were excluded if they had a history of decompensated liver disease (Child Pugh C or Child Pugh B with actual or previous detection of variceal bleeding, ascites, or overt hepatic encephalopathy), malignant liver tumor, portal vein thrombosis, cerebrovascular disease, sepsis, transjugular intrahepatic portosystemic shunt, liver transplantation, and treatment with vasoactive drugs within 2 weeks before enrollment.

Study protocol

During the enrollment period, 63 patients with liver cirrhosis underwent HVPG measurement. Among them, 15 participants did not enter the study because of ongoing treatment with vasoactive

drugs (5 patients), portal vein thrombosis (2 patients), ascites (6 patients), and a previous episode of gastrointestinal bleeding (2 patients). Two patients were not included in the final evaluation due to inadequate visualization of right liver lobe.

The enrolled patients underwent Doppler ultrasound, LS measurement, and D-CEUS on the same day of HVPG measurement.

HVPG measurement was performed as described elsewhere [3]. According to the Baveno consensus workshop, the patients were classified using a threshold of 10 mmHg for CSPH and 12 mmHg for SPH [3].

Liver cirrhosis severity was assessed by Child-Pugh [14] and MELD scores [15]. The size of gastroesophageal varices was classified into two groups: F0/F1: absent or small varices, F2/F3: moderately or marked enlarged varices.

The protocol was approved by our Institutional Review Board (approval number 13006). Written informed consent was obtained from all study participants.

After enrollment, patients were followed up every six months with laboratory exams, ultrasound, and clinical evaluation according to the standard surveillance program of our department. Any decompensation events were recorded.

Doppler ultrasound

Doppler ultrasound, LS, and D-CEUS studies were performed with an iU22 ultrasound system (Philips) equipped with a wideband C5–2 MHz convex probe by two trained operators (with 15 and 10 years of liver US experience) who were blinded to the clinical and hemodynamic data of the patients.

The examination included a color Doppler examination according to a standardized protocol in order to obtain portal vein blood velocity (PVV), hepatic venous (HV) waveforms and damping index (DI), hepatic artery (HA) resistivity index (RI), and splenic artery (SA) RI as described elsewhere [16, 17].

Point-shear wave elastography

The LS evaluation was performed with the ElastPQ technique. Measurements were obtained from the right hepatic lobe through intercostal spaces with the patient in supine position with suspended normal breathing and the right arm abducted. The operator selected the most appropriate area in the right liver lobe (usually 5th or 6th segment) free of large vessels and at least 2 cm below the liver capsule by moving the region of interest (ROI) perpendicular to the center of the transducer. The median value of 10 successful LS measurements was obtained from each patient. The results were expressed in kilopascals (kPa). Measurements were considered reliable if the interquartile range was less than 30 % of the median values.

Dynamic contrast-enhanced ultrasound (D-CEUS)

After Doppler ultrasound and LS evaluations, the operator obtained an intercostal scan of the right liver containing the right PV. Thereafter, a 2.4 mL solution of a second-generation ultrasound contrast agent (SonoVue, Bracco) was injected as an intravenous bolus followed by a flush of 10 ml normal saline. A dedicated, con-

trast-specific, low mechanical index technique (MI = 0.08) was used in order to study the whole vascular phase. The overall gain was set to obtain a complete anechoic image of the liver parenchyma for the basal phase and the depth was regulated on the bottom of the image.

Signal enhancement of the liver parenchyma (LP) and portal vein (PV) was evaluated in real time and a three-minute clip was registered on a hard disk.

Finally, digitized quantification of contrast uptake was performed on the recorded video clip using the quantitative analysis software package QLAB, version 7.0 (Philips Healthcare) as described elsewhere [4].

Five perfusion parameters were extracted from time-intensity curves: peak intensity (PI (in arbitrary units: AU)), time to PI (T_p (in seconds)), area under the time-intensity curve (AUC (in AU)), slope coefficient of wash in (P_w (in AU per second)), mean transit time (MTT (in seconds)). Finally delta PI (ΔPI) was determined by subtracting the LP-PI from the PV-PI.

Statistical analysis

Categorical variables were expressed as mean \pm standard deviation (SD) values and continuous data as percentages. The unpaired t-test or analysis of variance was applied for comparisons of normally distributed variables, while the Kruskal-Wallis' test or Wilcoxon's rank-sum (Mann-Whitney's) test was used for non-normally distributed parameters. Correlations between noninvasive parameters and invasive hemodynamic data were made by Pearson's test.

Linear regression analyses were performed according to the least-squares method. To assess the role of selected variables in predicting CSPH, receiver operating characteristic (ROC) curves with the area under the ROC curve (AUROC) were calculated, and DeLong's test was used for pairwise comparison of the AUROCs. Optimal cut-off values were selected on the basis of sensitivity, specificity, positive predictive value (PPV), and negative predictive value (NPV) using the Youden index.

General linear modeling with stepwise selection of one variable from each category (Doppler ultrasound, D-CEUS and LS) was employed to select the most predictive parameters for the assessment of CSPH. We calculated the estimated HVPG value based on the corresponding regression equation, and we further tested the agreement between the estimated and the measured HVPG value according to Cohen's K coefficient analysis.

Finally, parameters associated with clinical decompensation during follow-up were tested according to the Cox regression model.

The level of statistical significance was set at $P < 0.05$.

Statistical analysis was performed using Stata Software version 14.0.

Results

The study included 46 patients (31 men, 15 women; mean age \pm SD: 57 ± 11 years). Demographic and clinical data of the study population are provided in ► **Table 1**.

► **Table 1** Demographic and clinical data of the study population.

Characteristics	All patients (n = 46)	HVPG < 10 mmHg (n = 22)	HVPG ≥ 10 mmHg (n = 24)	p-value
Age, years Mean (SD)	57.3 (10.7)	59.1 (10.4)	55.6 (10.9)	0.69
Sex, n (%) Male/female	31 (67.4)/15 (32.6)	15 (68.2)/7 (31.8)	16 (66.7)/8 (33.3)	0.91
Etiology, n (%)				
Viral	22 (47.8)	13 (59.1)	9 (37.5)	
Alcoholic	9 (19.6)	3 (13.6)	6 (25.0)	0.64
Metabolic	11 (23.9)	4 (18.2)	7 (29.2)	
Autoimmune	4 (8.7)	2 (9.1)	2 (8.3)	
Laboratory values Mean (SD)				
Bilirubin (mg/dl)	1.63 (1.3)	1.20 (0.9)	1.40 (1.5)	0.68
Albumin (g/dL)	3.46 (0.5)	3.47 (0.5)	3.44 (0.4)	0.77
Creatinine (mg/dl)	0.87 (0.2)	0.89 (0.2)	0.86 (0.2)	0.54
AST (U/l)	40.1 (15.9)	35.7 (11.1)	44.0 (18.7)	0.07
ALT (U/l)	23.5 (15.2)	19.3 (11.3)	27.4 (17.5)	0.07
INR	1.23 (0.2)	1.23 (0.2)	1.23 (0.2)	0.91
PLT (10 ⁹ /l)	96.7 (32.9)	102.8 (33.5)	91.1 (32.1)	0.23
MELD, mean (SD)	9.8 (3.3)	9.6 (3.1)	9.9 (3.4)	0.77
Child Pugh class, n (%) (A/B/C)	37/9/0	18/4/0	19/5/0	0.56
Varices, n (%) F0-F1/F2-F3	31 (67.4)/15 (32.6)	19 (86.4)/3 (13.6)	12 (50.0)/ 12 (50.0)	0.03
HVPG Mean (SD)	11.3 (6.1)	5.7 (1.9)	16.3 (3.6)	<0.0001

Significant p-values are in bold. N: number of patients; SD: standard deviation, AST: aspartate aminotransferase; ALT: alanine aminotransferase; INR: international normalized ratio; PLT: platelet count; MELD: model for end stage liver disease; HVPG: hepatic venous pressure gradient

Linear regression analysis showed that there was an excellent significant correlation between LS and HVPG (► **Table 2**). Additionally, portal pressure was significantly correlated with all flow parameters from PV (► **Table 2**).

Among flow parameters derived from LP, the PI, P_w, and MTT were significantly correlated to HVPG: the correlation was substantial for PI and weak for P_w and MTT (► **Table 2**). Finally ΔPI was positively related to HVPG (► **Table 2**).

An excellent correlation was found between portal pressure and HV DI (► **Table 2**) and a moderate correlation between portal pressure and SA RI and HA RI (► **Table 2**).

Diagnostic accuracy for diagnosing clinically significant portal hypertension (HVPG ≥ 10 mmHg)

Among perfusion parameters, the PI, AUC, and P_w of both the LP and PV were significantly decreased, while ΔPI, PV-T_p, PV-MTT, and LP-MTT were increased in CSPH (► **Table 3**).

Clinical examples of the corresponding contrast uptake time-intensity curves from the LP and PV in patients with and without CSPH are shown in ► **Fig. 1**.

LS, HV DI, and RI of SA were all significantly higher in patients with CSPH (► **Table 3**).

Diagnostic accuracy for diagnosing severe portal hypertension (HVPG ≥ 12 mmHg)

In patients with SPH, the results of time-intensity curve analysis were significantly different in three of the five D-CEUS parameters extracted from the LP (PI, P_w, and MTT) and in all parameters from the PV (► **Table 3**). In particular, we found a significant decrease in the PI, AUC, and P_w and a significant increase in the ΔPI, MTT, and T_p in the SPH group.

Among Doppler parameters, HV DI, SA RI, and HA RI were increased in patients with SPH (► **Table 3**).

Finally, a significant increase in LS was also observed in patients with SPH (► **Table 3**).

► **Table 2** Correlation between imaging parameters and HVPG measurements.

	R (correlation coefficient)	p-value
Perfusion parameters		
<i>Liver parenchyma</i>		
PI (AU)	-0.797	<0.0001
AUC (AU)	-0.249	0.10
P _w (AU/sec)	-0.363	0.01
T _p (sec)	0.035	0.82
MTT (sec)	0.398	0.006
<i>Portal vein</i>		
PI (AU)	-0.762	<0.0001
AUC (AU)	-0.381	0.009
P _w (AU/sec)	-0.585	<0.0001
T _p (sec)	0.544	0.0001
MTT (sec)	0.588	<0.0001
Δ PI	0.572	<0.0001
Liver stiffness	0.809	<0.0001
Doppler parameters		
PVV (cm/sec)	-0.174	0.24
RI HA	0.319	0.03
HV DI	0.549	<0.0001
RI SA	0.461	0.001

Significant p-values are in bold. PI: peak intensity; AU: arbitrary units; AUC: area under the curve; P_w: slope coefficient of wash in; sec: seconds; T_p: time to peak; MTT: mean transit time; Δ PI: difference between PI of portal vein and PI of liver parenchyma; PVV: portal vein velocity; RI: resistivity index; HA: hepatic artery; HV DI: hepatic vein damping index; SA: splenic artery; cm: centimeters

Performance for diagnosis of CSPH and SPH

For the assessment of CSPH and SPH, the AUROC of LP-PI was greater than that of the other indices. For the diagnosis of CSPH, the AUROC was 1.000, and the optimal cut-off value of LP-PI was 23.3 AU with a sensitivity and a specificity of 100 % (**Supplementary Table 1**). For the diagnosis of SPH, the AUROC was 0.981, and the optimal cut-off value of LP-PI was 22.3 AU with a sensitivity of 92 % and a specificity of 100 % (Table 4). Excellent results were obtained also with the AUROCs of other perfusion parameters and in particular of PV-PI: ΔPI, PV-Pw for the assessment of CSPH (0.977, 0.888, and 0.848, respectively) (**Supplementary Table 1**) and PV-PI, ΔPI, PV-Pw, PV-Tp for the assessment of SPH (0.956, 0.853, 0.811, and 0.818, respectively) (**Supplementary Table 1**).

The AUROCs of LS for diagnosing CSPH and SPH were 0.923 and 0.894, respectively, with the optimal cut-off values of 24.2 for CSPH (sensitivity 91.7 %, specificity 81.8 %) (**Supplementary Table 1**) and 25.7 for SPH (sensitivity 80.9 %, specificity 84 %) (**Supplementary Table 1**).

In pairwise comparison of the AUROCs of Doppler parameters, HV DI allowed better assessment of CSPH compared with SA RI (AUROCs 0.824 and 0.761, respectively). Similar results were obtained for the evaluation of SPH (AUROCs 0.818, 0.733, 0.662, and 0.613 for HV DI, SA RI, HA RI, and PVV, respectively) (**Supplementary Table 1**).

Combination of noninvasive methods

In order to avoid the influence of perfusion features related to patient hemodynamics, among different D-CEUS parameters with excellent correlation with PH, we decided to use ΔPI for multivariate analysis.

According to linear regression modeling, only LS was significantly related to the presence of CSPH ($p < 0.0001$) with a coefficient of 0.82 (95 %CI: 0.64–1.05) (**Supplementary Table 2**) and optimal agreement between the estimated and the measured HVPG value (Cohen's K Coefficient 0.809; $p < 0.0001$) (► **Fig. 2**).

Prediction of clinical outcome

During a mean follow-up time of 34 months, 11 patients experienced clinical decompensation and 3 patients underwent orthotopic liver transplantation. The most frequent decompensation event was ascites (6 patients), followed by gastrointestinal bleeding (3 patients), and hepatic encephalopathy (2 patients).

As expected HVPG and MELD values were significantly higher in patients with clinical decompensation during follow-up (HR [95 % CI] 1.15 [1.04–1.28], $p = 0.009$ for HVPG and 1.25 [1.08–1.45], $p = 0.003$ for MELD) (**Supplementary Table 3**).

None of the ultrasound parameters were related to the occurrence of decompensation events except for two perfusion parameters extracted from the portal vein: T_p and MTT (HR [95 % CI] 1.09 [1.01–1.16], $p = 0.01$ and 1.06 [1.02–1.09], $p = 0.001$, respectively) (**Supplementary Table 3**).

Discussion

The complications of cirrhosis are mainly associated with the occurrence of CSPH, in particular in the early phases of the disease. In this context an accurate assessment of PH becomes relevant to allow optimization of individualized treatment.

The results of our study suggest that both LS and perfusion parameters had a high accuracy in the diagnosis of CSPH and SPH. We found three categories: D-CEUS-related perfusion parameters, LS, and Doppler values that independently predicted PH.

These noninvasive parameters mirror the two main pathogenetic components of PH, namely the liver architectural derangement and the impairment of hepatic perfusion.

With respect to the first aspect, liver elastography has provided a major advantage in the assessment of patients with compensated chronic liver disease [18]. Numerous previous studies have correlated TE with HVPG [13, 19, 20] and, according to the Baveno VII consensus report, this method is sufficiently accurate to evaluate PH with a cut-off value of 25 kPa to rule in and 15 kPa to rule out CSPH [3].

► **Table 3** Imaging parameters in patients without and with clinically significant portal hypertension (HVPG < 10 mmHg vs. ≥ 10 mmHg) and without and with severe portal hypertension (HVPG < 12 mmHg vs. ≥ 12 mmHg). Data are presented as mean±SD.

Parameters	CSPH			SPH		
	HVPG<10	HVPG≥10	p-value	HVPG<12	HVPG≥12	p-value
D-CEUS						
PI-LP	31.50±5.89	17.18±3.10	<0.0001	30.10±6.77	16.81±3.06	<0.0001
AUC-LP	1232.9±402.2	866.7±412.7	0.003	1154.2±434.7	908.1±425.8	0.06
P _w -LP	0.41±0.15	0.23±0.14	0.002	0.37±0.15	0.25±0.15	0.009
T _p -LP	46.63±20.94	50.17±13.61	0.49	48.70±20.50	48.18±13.27	0.91
MTT-LP	27.31±12.24	39.12±14.51	0.005	29.36±12.97	38.37±15.20	0.03
PI-PV	36.19±5.74	25.43±2.98	<0.0001	35.19±6.11	25.09±2.90	<0.0001
AUC-PV	1490.5±710.7	926.9±489.2	0.002	1374.4±738.3	984.6±497.1	0.04
P _w -PV	0.49±0.17	0.29±0.11	<0.0001	0.47±0.17	0.29±0.12	0.0002
T _p -PV	44.72±10.31	55.63±9.72	0.0006	44.77±9.69	57.13±9.41	0.0001
MTT-PV	30.37±9.28	50.72±24.66	0.0007	29.35±12.97	38.37±15.21	0.03
Δ PI	4.71±1.99	8.38±2.22	<0.0001	5.10±2.17	8.44±2.35	<0.0001
LS	22.18±2.82	30.76±5.08	<0.0001	22.85±3.31	31.19±5.24	<0.0001
Doppler						
PVV	25.11±4.75	25.13±5.94	0.99	26.12±5.75	23.93±5.75	0.16
RI-HA	0.66±0.05	0.69±0.06	0.14	0.65±0.04	0.70±0.06	0.04
HV DI	0.44±0.13	0.64±0.16	0.0001	0.46±0.13	0.64±0.16	<0.0001
RI-SA	0.61±0.04	0.65±0.03	0.005	0.61±0.04	0.64±0.04	0.009

Significant p-values are in bold. CSPH: clinically significant portal hypertension; SPH: severe portal hypertension; LP: liver parenchyma; PV: portal vein; PI: peak intensity; AUC: area under the curve; P_w: slope coefficient of wash in; T_p: time to peak; MTT: mean transit time; LS: liver stiffness; PVV: portal vein velocity; RI: resistivity index; HA: hepatic artery; HV DI: hepatic vein damping index; SA: splenic artery. **Unit of measurement.** PI, AUC, Δ PI: arbitrary units; T_p, MTT: seconds; P_w: arbitrary units per second; LS: kPa; PVV: centimeters per second

Preliminary results with SWE confirmed the significant correlation between LS and HVPG values [13, 21, 22, 23].

In regard to pSWE and in particular ElastPQ, it has been demonstrated that the combination of platelet count and LS values may be useful to select patients with chronic liver disease that can safely avoid screening endoscopy [24].

Our study provides relevant additional information regarding the noninvasive diagnosis of CSPH using this elastographic modality since the use of ElastPQ to determine the presence of CSPH has not been previously tested.

The finding of a correlation between HVPG and LS consolidates the close relationship between the progression of liver fibrosis and that of portal pressure. However, in parallel to an increase in LS, liver cirrhosis can cause hemodynamic changes associated with both raised hepatic resistance and the development of portosystemic collaterals [2].

In this context the association of an alternative method capable of evaluating liver perfusion could carefully reproduce the clinical background typical of PH.

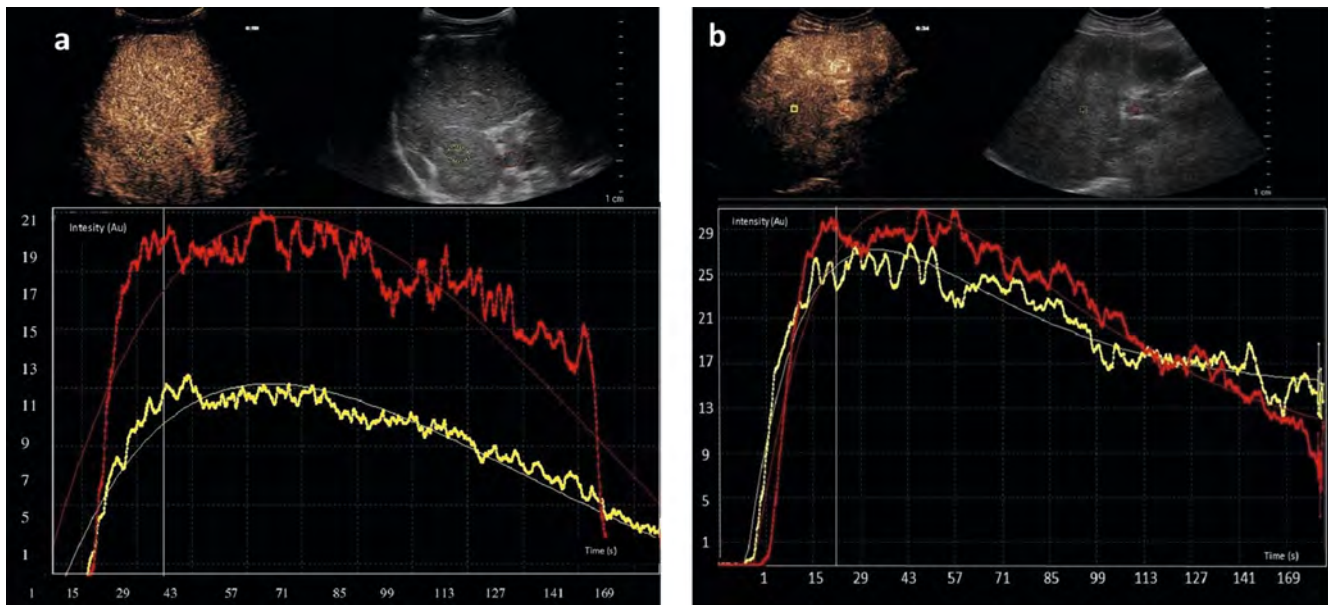
According to previous results, only weak correlations have been shown between Doppler parameters and the presence of

PH [25] except for HV DI, an established sign of high portal pressure and liver dysfunction [18].

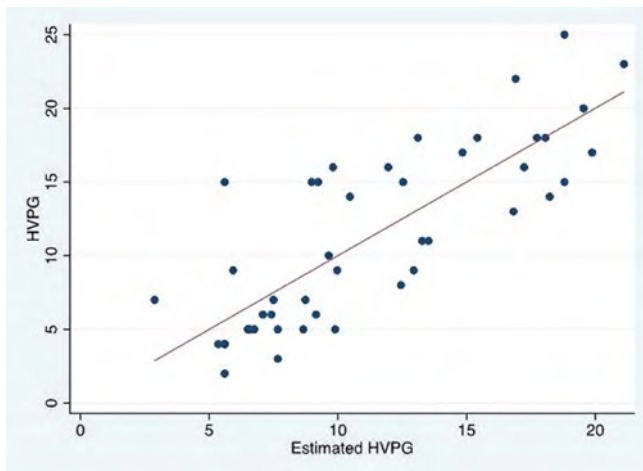
We demonstrated that liver perfusion evaluation by D-CEUS may exceed the limitations of Doppler measurement. In our series several perfusion parameters derived from time-intensity curves were closely correlated with HVPG values. Among them, PI-LP had the best diagnostic performance and was negatively correlated with HVPG with an AUROC of 1.000 for predicting the presence of CSPH and 0.992 for assessing SPH. We hypothesized that this CEUS parameter would be a measure of the liver blood content in the different stages of disease. Not only the increase in fibrosis and architectural changes but also the development of hyperdynamic circulation and arteriovenous shunts is associated with a reduction in portal perfusion and liver blood content that produces a decrease in signal intensity.

Our results confirm previously reported data obtained with MR which show that portal perfusion to the liver is inversely related to portal pressure and hepatic resistance [14].

The concomitant application of different ultrasound perfusion parameters could be very interesting since it not only reflects the entire pathogenetic process of PH, but also makes it possible to overcome the limitations of each single parameter.



► **Fig. 1** D-CEUS study. Regions of interest (ROI) were drawn on the portal vein (red circle) and liver parenchyma (yellow circle) to measure the corresponding time-intensity curves. **a** 51-year-old male patient with HVPG = 16 mmHg. **b** 55-year-old female patient with HVPG = 3 mmHg. Patient with severe portal hypertension had lower PI both on LP (11.9 vs. 26.9 AU) and PV (21 vs. 29.8 AU) and higher Delta PI (9.1 vs. 2.9 AU). PI: peak intensity; LP: liver parenchyma; PV: portal vein; Delta PI: difference between PI-PV and PI-LP.



► **Fig. 2** Scatter dot plot demonstrating the correlation between estimated and measured HVPG values. HVPG: hepatic venous pressure gradient.

In the multivariate logistic regression analysis, however, only LS showed good performance for the diagnosis of CSPH.

On the other hand, perfusion parameters related to PV flow were associated with the occurrence of decompensation events during follow-up together with standard parameters such as HVPG and MELD.

These findings suggest that D-CEUS might be a useful complement to a standard scoring system for monitoring the clinical course of the disease.

Our study has some limitations. First, the small number of patients enrolled means it is not possible to draw certain conclusions regarding the best noninvasive method to diagnose CSPH

and to predict decompensation events. Second, the study population was somewhat heterogeneous even if we excluded patients with very severe disease. Moreover, variability in measurements is an issue with these techniques, and the reproducibility of the results could be influenced by the specific equipment and setting employed. In particular, the identified cut-off may not be universally applicable. Future work should probably focus on the development of practical and widely accepted systems for the classification of PH based on D-CEUS and LS findings.

To conclude, our preliminary results suggest that both LS and perfusion parameters obtained by D-CEUS provide excellent accuracy for assessing the degree of PH. As a reliable and noninvasive procedure, these US-based techniques are a promising method for detecting CSPH and SPH in clinical practice. Further large studies are needed to prospectively validate these findings and also to determine whether LS and D-CEUS parameters can be used for monitoring the hemodynamic response to therapy.

Personalized medicine could benefit from this noninvasive approach, especially in high-risk situations, such as primary prophylaxis of liver decompensation.

Conflict of Interest

The authors declare that they have no conflict of interest.

References

- [1] Berzigotti A, Seijo S, Reverter E et al. Assessing portal hypertension in liver diseases. *Exp Rev Gastroenterol Hepatol* 2013; 7: 141–155. doi:10.1586/egh.12.83

- [2] D'Amico G, Garcia-Tsao G, Pagliaro L. Natural history and prognostic indicators of survival in cirrhosis: a systematic review of 118 studies. *J Hepatol* 2006; 44: 217–231. doi:10.1016/j.jhep.2005.10.013
- [3] De Franchis R, Bosch J, Garcia-Tsao G et al. Baveno VII – Renewing consensus in portal hypertension. *J Hepatol* 2022; 76: 959–974
- [4] Zocco MA, Garcovich M, Lupascu A et al. Early prediction of response to Sorafenib in patients with advanced hepatocellular carcinoma: the role of dynamic contrast enhanced ultrasound. *J Hepatol* 2013; 59: 1014–1021
- [5] Kim MY, Suk KT, Baik SK et al. Hepatic vein arrival time as assessed by contrast-enhanced ultrasonography is useful for the assessment of portal hypertension in compensated cirrhosis. *Hepatology* 2012; 56: 1053–1062. doi:10.1002/hep.25752
- [6] Zhang CX, Hu J, Hu KW et al. Noninvasive analysis of portal pressure by contrast-enhanced sonography in patients with cirrhosis. *J Ultrasound Med* 2011; 30: 205–211. doi:10.7863/jum.2011.30.2.205
- [7] Jeong WK, Kim TY, Sohn JH et al. Severe Portal Hypertension in Cirrhosis: Evaluation of Perfusion Parameters with Contrast-Enhanced Ultrasonography. *Plos One* 2015; 10: e0121601. doi:10.1371/journal.pone.0121601
- [8] Li J, Feng JC, Peng XY et al. Usefulness of Contrast-Enhanced Ultrasonography for Predicting Esophageal Varices in Patients with Hepatitis B Virus (HBV)-Related Cirrhosis. *Med Sci Monit* 2017; 23: 2241–2249. doi:10.12659/msm.904227
- [9] Berzigotti A, Nicolau C, Bellot P et al. Evaluation of regional hepatic perfusion (RHP) by contrast-enhanced ultrasound in patients with cirrhosis. *J Hepatol* 2011; 55: 307–314. doi:10.1016/j.jhep.2010.10.038
- [10] Abraldes JG, Bureau C, Stefanescu H et al. Noninvasive tools and risk of clinically significant portal hypertension and varice in compensated cirrhosis: The “Anticipate” study. *Hepatology* 2016; 64: 2173–2184. doi:10.1002/hep.28824
- [11] Castera L, Pinzani M, Bosch J. Noninvasive evaluation of portal hypertension using transient elastography. *J Hepatol* 2012; 56: 696–703. doi:10.1016/j.jhep.2011.07.005
- [12] Kim G, Kim MY, Baik SK. Transient elastography versus hepatic venous pressure gradient for diagnosing portal hypertension: a systematic review and meta-analysis. *Clin Mol Hepatol* 2017; 23: 34–41
- [13] Wagner M, Hectors S, Bane O et al. Non-invasive prediction of portal pressure with MR elastography and DCE-MRI of the liver and spleen: preliminary results. *J Magn Reson Imaging* 2018; 48: 1091–1103. doi:10.1002/jmri.26026
- [14] Child CG, Turcotte JG. Surgery and portal hypertension. *Major Probl Clin Surg* 1964; 1: 1–85
- [15] Kamath PS, Wiesner RH, Malinchoc M et al. A model to predict survival in patients with end-stage liver disease. *Hepatology* 2001; 33: 464–470
- [16] Kim MY, Baik SK, Park DH et al. Damping index of Doppler hepatic vein waveform to assess the severity of portal hypertension and response to propranolol in liver cirrhosis: a prospective nonrandomized study. *Liver Int* 2007; 27: 1103–1110. doi:10.1111/j.1478-3231.2007.01526.x
- [17] Sacerdoti D, Gaiani S, Buonamico P et al. Interobserver and interequipment variability of hepatic, splenic and renal arterial Doppler resistance indices in normal subjects and patients with cirrhosis. *J Hepatol* 1997; 27: 986–992. doi:10.1016/s0168-8278(97)80141-9
- [18] Vuille-Lessard E, Rodrigues SG, Berzigotti A. Non invasive detection of clinically significant portal hypertension in compensated advanced chronic liver disease. *Clin Liv Dis* 2021; 25: 253–289
- [19] Berzigotti A. Noninvasive evaluation of portal hypertension using ultrasound elastography. *J Hepatol* 2017; 67: 399–411. doi:10.1016/j.jhep.2017.02.003
- [20] Jindal A, Shaema S, Agarwal S et al. Liver stiffness can predict decompensation and need for beta-blockers in compensated cirrhosis: a step beyond Baveno-VI criteria. *Hepatol Int* 2022; 16: 89–98
- [21] Stefanescu H, Rusu C, Lupsor-Platon M et al. Liver Stiffness Assessed by Ultrasound ShearWave Elastography from General Electric Accurately Predicts Clinically Significant Portal Hypertension in Patients with Advanced Chronic Liver Disease. *Ultraschall in Med* 2020; 41: 526–533. doi:10.1055/a-0965-0745
- [22] Grgurevic I, Madir A, Trkulja V et al. Assessment of clinically significant portal hypertension by two-dimensional shear wave elastography. *Eur J Clin Invest* 2022; 18: 13750. doi:10.1111/eci.13750
- [23] Thiele M, Hugger MB, Kim Y et al. 2D shear wave liver elastography by Aixplorer to detect portal hypertension in cirrhosis: an individual patient data meta-analysis. *Liver Int* 2020; 40 (6): 1435–1446. doi:10.1111/liv.14439
- [24] Garcovich M, Di Stasio E, Zocco MA et al. Assessing Baveno VI criteria with liver stiffness measured using a new point-shear wave elastography technique (BAVElastPQ study). *Liver Int* 2020; 40: 1952–1960. doi:10.1111/liv.14558
- [25] Haag K, Rossle M, Ochs A et al. Correlation of duplex sonography findings and portal pressure in 375 patients with portal hypertension. *AJR Am J Roentgenol* 1999; 172: 631–635. doi:10.2214/ajr.172.3.10063849