



# Cranial Base Reconstruction and Secondary Frontal Advancement for Meningoencephalocele Following LeFort III Osteotomy in a Patient with Crouzon Syndrome: Case Report

Sungmi Jeon, MD<sup>1</sup> Yumin Kim, MD<sup>1</sup> Ji Hoon Phi, MD, PhD<sup>2</sup> Jee Hyuk Chung, MD, PhD<sup>1</sup>

<sup>1</sup>Division of Pediatric Plastic Surgery, Seoul National University Children's Hospital, Seoul National University College of Medicine, Seoul, Republic of Korea

<sup>2</sup>Division of Pediatric Neurosurgery, Seoul National University Children's Hospital, Seoul National University College of Medicine, Seoul, Republic of Korea

Address for correspondence Jee Hyeok Chung, MD, PhD, Division of Pediatric Plastic Surgery, Seoul National University Children's Hospital, 101 Daehak-ro, Jongno-gu, Seoul 03080, Republic of Korea (e-mail: 66012@snuh.org).

Arch Plast Surg 2023;50:54–58.

## Abstract

Patients with Crouzon syndrome have increased risks of cerebrospinal fluid rhinorrhea and meningoencephalocele after LeFort III osteotomy. We report a rare case of meningoencephalocele following LeFort III midface advancement in a patient with Crouzon syndrome. Over 10 years since it was incidentally found during transnasal endoscopic orbital decompression, the untreated meningoencephalocele eventually led to intermittent clear nasal discharge, frontal headache, and seizure. Computed tomography and magnetic resonance imaging demonstrated meningoencephalocele in the left frontal-ethmoid-maxillary sinus through a focal defect of the anterior cranial base. Through bifrontal craniotomy, the meningoencephalocele was removed and the anterior cranial base was reconstructed with a pericranial flap and split calvarial bone graft. Secondary frontal advancement was concurrently performed to relieve suspicious increased intracranial pressure, limit visual deterioration, and improve the forehead shape. Surgeons should be aware that patients with Crouzon syndrome have the potential for an unrecognized dural injury during LeFort III osteotomy due to anatomical differences such as inferior displacement and thinning of the anterior cranial base.

## Keywords

- ▶ LeFort osteotomy
- ▶ Crouzon syndrome
- ▶ meningo-encephalocele
- ▶ magnetic resonance imaging
- ▶ computed tomography

## Introduction

Crouzon syndrome is a craniofacial dysostosis characterized by a triad of premature craniosynostosis, exophthalmos, and midface hypoplasia.<sup>1</sup> The condition is estimated to occur in approximately 16 per million newborns and is the most

common craniosynostosis syndrome.<sup>2</sup> LeFort III advancements have been widely used to address several issues related to midfacial hypoplasia usually after 8 years of age, including ocular exposure, nasal airway obstruction, and class III malocclusion.<sup>3</sup> However, LeFort III osteotomy can

received

March 29, 2022

accepted after revision

August 11, 2022

accepted manuscript online

September 7, 2022

DOI <https://doi.org/10.1055/a-1938-0906>.

eISSN 2234-6171.

© 2023. The Korean Society of Plastic and Reconstructive Surgeons. All rights reserved.

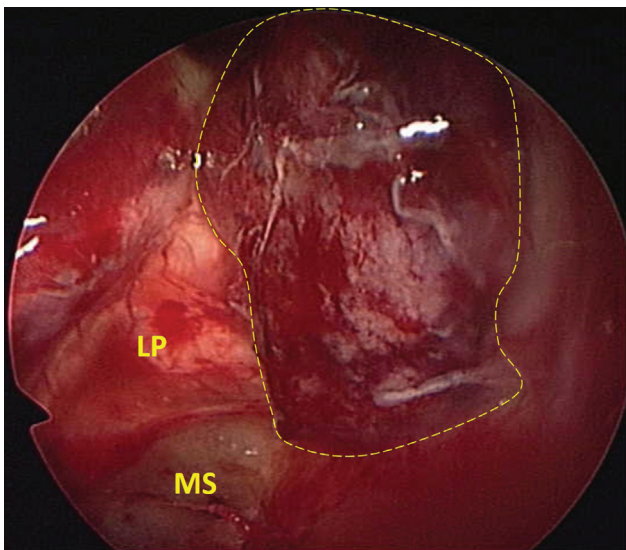
This is an open access article published by Thieme under the terms of the Creative Commons Attribution-NonDerivative-NonCommercial-License, permitting copying and reproduction so long as the original work is given appropriate credit. Contents may not be used for commercial purposes, or adapted, remixed, transformed or built upon. (<https://creativecommons.org/licenses/by-nc-nd/4.0/>)

Thieme Medical Publishers, Inc., 333 Seventh Avenue, 18th Floor, New York, NY 10001, USA

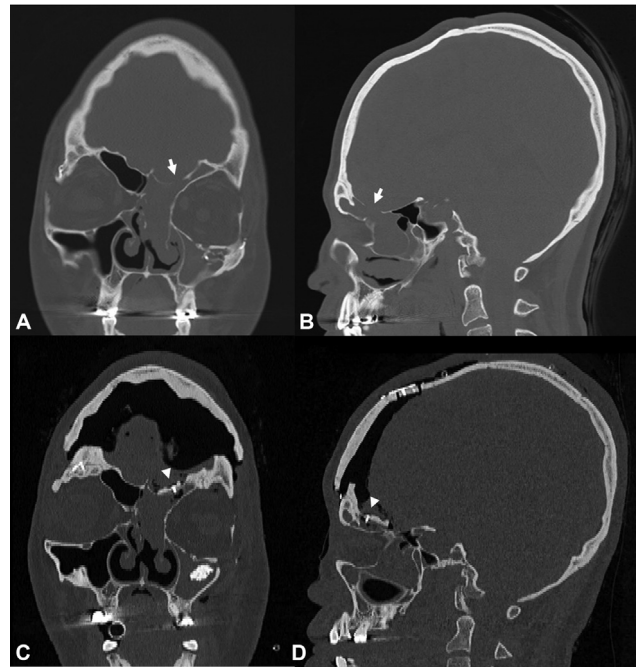
result in rare but life-threatening complications, including cerebrospinal fluid (CSF) rhinorrhea, meningitis, and meningoencephalocele.<sup>4</sup> Patients with Crouzon syndrome are at increased risk of tearing of the adherent dura, especially during midline separation through the nasofrontal suture in LeFort III osteotomy.<sup>5</sup> An undiagnosed defect of the anterior cranial base can lead to subsequent herniation of the CSF, meninges, or brain months to years after surgery. Herein, we report a rare case of transethmoidal meningoencephalocele that resulted in CSF rhinorrhea and seizure occurring 10 years after LeFort III midface advancement in a patient with Crouzon syndrome. Institutional review board approval (No. 2112-158-1287) was obtained for this case.

## Case

A 31-year-old woman with Crouzon syndrome had previously undergone primary fronto-orbital advancement (FOA) at 2 years of age and LeFort III halo distraction at 18 years at other hospitals. At 21 years of age, transnasal endoscopic orbital decompression was performed in the left nasal cavity by an otolaryngologist for proptosis and optic atrophy. However, the operation was terminated immediately after herniated brain tissue was identified on frozen biopsy during ethmoidectomy (►Fig. 1). Physical examination revealed intranasal mucopus on her left side; however, the view was limited due to synechia between the maxillary crest and nasal floor. Preoperative computed tomography (CT) showed a focal bony defect in the left anterior cranial base, which was considered insignificant (►Fig. 2A and B). After surgery, brain magnetic resonance imaging (MRI) confirmed meningoencephalocele in the left frontal-ethmoid sinus and nasal cavity (►Fig. 3A). Papilledema related to increased intracranial pressure (ICP) was not observed on fundus examination. The patient was referred to the department of neurosurgery for potential CSF leakage and meningitis because the granulation



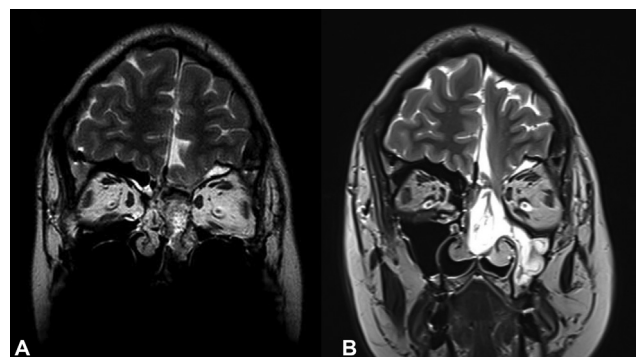
**Fig. 1** An intraoperative endoscopic image. The herniated brain tissue into ethmoidal sinus was delineated with a yellow dotted line. LP, lamina papyracea; MS, maxillary sinus.



**Fig. 2** Coronal and sagittal computed tomography scans (A, B) before and (C, D) after surgery. The white arrows indicate the focal bony defect of the left anterior cranial base (A, B). The white arrow heads indicate the split calvarial bone graft fixed with screw fixation (C, D).

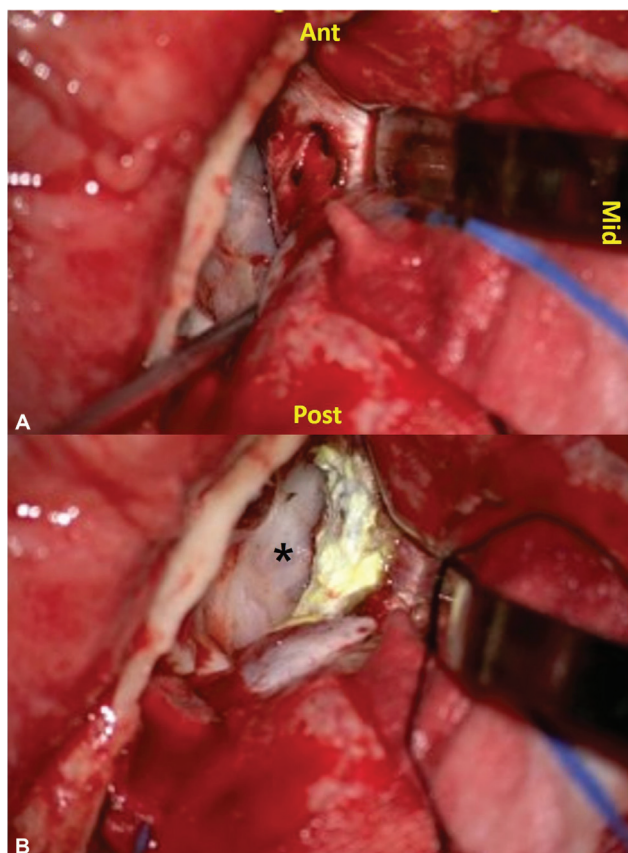
tissue was removed during the endoscopic procedure but refused further surgical treatment.

Ten years later, the patient visited the emergency room for a first-time generalized seizure. She had also experienced intermittent clear nasal discharge (three episodes lasting up to 1 month), which was suspected as CSF rhinorrhea but not verified by any tests. A recent headache localized to the supraorbital area was also noted. Chronic optic atrophy was stationary without recent deterioration of visual acuity and fundus examination was negative for papilledema findings. The interval progress of the meningoencephalocele into the left fronto-ethmoid-maxillary sinus was observed on 10-year follow-up brain MRI (►Fig. 3B). No active CSF leakage beyond the herniated sacs was observed.



**Fig. 3** Preoperative coronal T2-weighted magnetic resonance images demonstrating interval progress of the meningoencephalocele in the fronto-ethmoid-maxillary sinus. (A) 10 years prior, when the meningoencephalocele was first observed, and (B) before reconstruction of the anterior cranial base.

Surgical intervention using the transcranial approach was performed in tandem by a neurosurgeon and plastic surgeon. The meningoencephalocele was removed through a bifrontal craniotomy. The supraorbital craniotomy line was designed above the right frontal sinus based on the sagittal and coronal CT images. Burr hole trephination was first performed at the vertex (1 cm apart the midline), frontal region, and squamous part of the temporal bone on each side. After epidural dissection between these holes, bifrontal craniotomy was completed using a saw. The herniated frontal lobe below the cranial base was ligated and hemostasis was achieved using bipolar coagulation. A 6 × 8 mm-sized cranial defect was identified in the left anterior skull base (►Fig. 4A and B). Approximately 1 × 1 cm-sized pericranial flap was elevated and transferred to the skull base defect.<sup>6</sup> TachoSil (Takeda Pharma, Wien, Austria) was applied as a double layer (one outside of the dural defect before pericranial flap transfer, and the second one on the transferred flap margin inside the dura mater).<sup>7</sup> After dural repair, the Valsalva maneuver was performed by an anesthetist to confirm absence of CSF leak. For split calvarial grafting, a 4 × 6 cm-sized calvarial bone graft was harvested from the left parietal bone. The outer table of the bone graft was returned to its place. A 1 × 1 cm-sized split calvarial graft was placed over the cranial base defect and fixed using a 6-mm-sized titanium screw

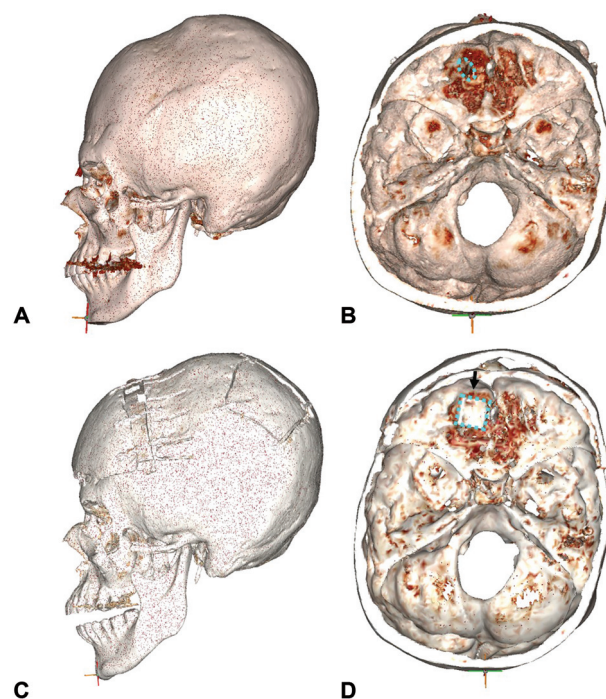


**Fig. 4** Intraoperative photographs of the anterior skull base. (A) Through bifrontal craniotomy, the skull base defect was identified after removal of the meningoencephalocele. (B) The pericranial flap (indicated with an asterisk) was transferred for dural repair. Ant, anterior; Post, posterior; Mid, midline.

(►Fig. 2C and D). Additionally, secondary frontal advancement was performed to expand the cranial vault, limit visual deterioration, and improve the forehead shape. The bifrontal bone flap was fixed using titanium miniplates and screws into approximately 1 cm anteriorly advanced position. Three pieces of 1 × 6 cm-sized split calvarial grafts were inserted into the coronal gap between the bifrontal bone flap and the parietal bones (►Fig. 5). An orbital bar was not made to avoid the risk of infection due to exposure of the frontal sinus on her right side. No complications were recorded and the headache resolved after surgery. There were no recurrences of meningoencephalocele or any symptoms at the 2-year follow-up (►Fig. 6).

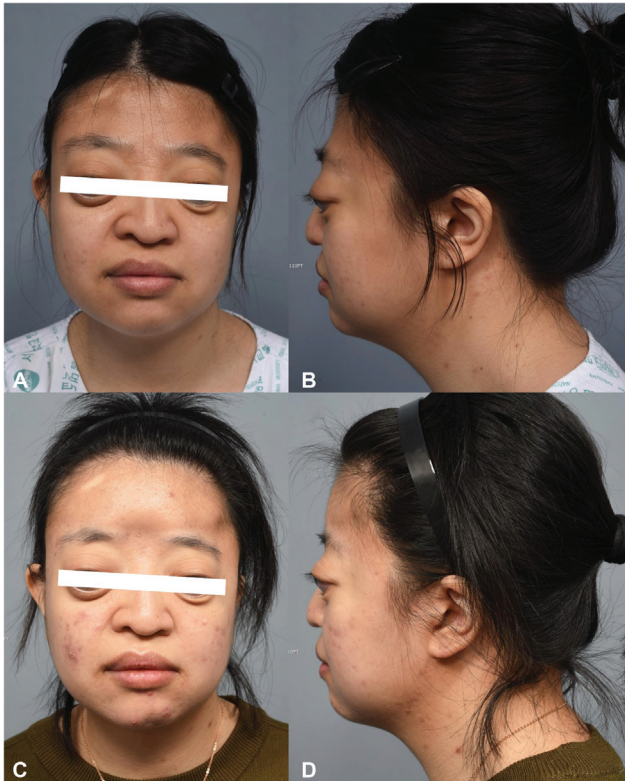## Discussion

Reported complications following LeFort III midface advancements include CSF leakage, meningitis, and meningoencephalocele.<sup>4</sup> Patients with Crouzon syndrome have an additional iatrogenic risk for developing dural tears and fractures of the cribriform plates, especially during the nasofrontoethmoidal osteotomy procedure in LeFort III osteotomy. There were few reports on meningoencephalocele in patients with Crouzon syndrome who had history of LeFort III osteotomy.<sup>5,8</sup> Panuganti et al reported a 19-year-old patient with Crouzon syndrome and Graves' disease who developed CSF rhinorrhea and frontal pain within 1 year after LeFort III midface osteotomy.<sup>8</sup> Ridgway et al reported a 14-year-old patient with Crouzon syndrome who presented



**Fig. 5** Sagittal and top-down endocranial views in three-dimensional renderings from computed tomography scans (A, B) before and (C, D) after surgery. The anterior cranial base defect (delineated with a blue dotted line, B) was reconstructed with a split calvarial bone graft (delineated with a blue dotted line, D). Additionally, secondary frontal advancement was performed (C, D).





**Fig. 6** Frontal and lateral profile photographs of the patient (A, B) before and (C, D) 1 year after secondary frontal advancement. Note the improvement in the contour of the forehead.

nasal obstruction, snoring, and nasal drainage 4 years after LeFort III advancement.<sup>5</sup> Next year, the authors reported complications of LeFort III osteotomy in 31 patients with syndromic coronal synostosis, including the earlier case who developed meningoencephalocele.<sup>5,9</sup> Among 31 patients, 2 patients had CSF rhinorrhea and 1 had meningoencephalocele. This can occur due to the anatomical abnormalities frequently observed in patients with Crouzon syndrome, such as inferior displacement and thinning of the anterior cranial base.<sup>8</sup> The current literature suggests that increased ICP might lead to the development of complications and relapse.<sup>8</sup> Furthermore, patients treated with primary FOA in infancy, as in our case, are reportedly at a higher risk, which may be attributed to significant scarring.<sup>9</sup>

In our case, the untreated meningoencephalocele eventually led to suspected CSF rhinorrhea, frontal headache, and seizure for 10 years after incidentally identified. Meningoencephaloceles are defined as a herniation of brain tissue within the CSF-filled sac and are classified according to their location.<sup>5</sup> Basal meningoencephaloceles account for only 1.5% of cases, and the transthemoidal type can cause intranasal obstruction and CSF rhinorrhea.<sup>10</sup> Meningitis from untreated CSF leaks occurs in approximately 20% of cases.<sup>11</sup> Hammer et al reported a case of temporo-sphenoidal encephalocele with CSF rhinorrhea and a first-time seizure in a middle-aged woman without any history of trauma or surgery.<sup>12</sup> Inflammatory reactions related to encephalitis led to the onset of epilepsy. Our case was not diagnosed with related meningitis or encephalitis.

The patient underwent bifrontal craniotomy to remove the meningoencephalocele and repair the defect of the anterior cranial base with a pericranial flap and split calvarial bone graft. Most traumatic CSF leaks resolve spontaneously within 7 days with conservative treatment, including bed rest, hydration, and steroids. However, if the leak persists, surgical intervention using an open transcranial or minimally invasive endoscopic approach is required.<sup>11</sup> The transcranial approach is an appropriate option for the definitive repair of skull base defects by offering direct visualization and the use of a pericranial flap or calvarial bone graft.<sup>13</sup> This approach is preferred in cases accompanied by meningoencephalocele and with histories of multiple surgical where significant scarring is expected.<sup>5</sup> In addition, secondary frontal advancement was performed in this case to relieve suspiciously increased ICP and improve the forehead contour. Supraorbital bar advancement was not performed to avoid the potential risk of CSF leakage or meningitis caused by frontal sinus exposure.<sup>13</sup> Despite apparent exophthalmos and lower eyelid retraction, complete eye closure was possible without management. Additional midface advancement or malar augmentation could be considered for more improved aesthetic outcomes.

Meningoencephalocele following LeFort III osteotomy is rare; however, early recognition and appropriate treatment can prevent fatal problems such as CSF rhinorrhea, meningitis, and seizure. Surgeons should be aware that patients with Crouzon syndrome have the potential for an unrecognized dural injury and subsequent meningoencephalocele after LeFort III osteotomy. CT is the imaging modality of choice for evaluating bone, especially thin cortical bone structure in the skull base.<sup>14</sup> If a skull base defect is suspected, brain MRI is recommended to confirm the intracranial connection and assess the components of the soft tissues.<sup>15</sup>

#### Author Contributions

S.J. collected data, drafted the initial manuscript, and critically reviewed and revised the manuscript. Y.K. collected data and critically reviewed and revised the manuscript. J.H.P. designed the study, and critically reviewed and revised the manuscript. J.H.C. conceptualized and designed the study, supervised the manuscript, and critically reviewed and revised the manuscript. All authors approved the final manuscript as submitted and agree to be accountable for all aspects of the work.

#### Patient Consent

Patients provided informed consent for the publication and the use of their images.

#### Conflict of Interest

None declared

#### References

- Katzen JT, McCarthy JG. Syndromes involving craniosynostosis and midface hypoplasia. *Otolaryngol Clin North Am* 2000;33(06):1257-1284, vi

- 2 Cohen MM Jr, Kreiborg S. Birth prevalence studies of the Crouzon syndrome: comparison of direct and indirect methods. *Clin Genet* 1992;41(01):12–15
- 3 Engel M, Berger M, Hoffmann J, et al. Midface correction in patients with Crouzon syndrome is Le Fort III distraction osteogenesis with a rigid external distraction device the gold standard? *J Craniomaxillofac Surg* 2019;47(03):420–430
- 4 Saltaji H, Altalibi M, Major MP, et al. Le Fort III distraction osteogenesis versus conventional Le Fort III osteotomy in correction of syndromic midfacial hypoplasia: a systematic review. *J Oral Maxillofac Surg* 2014;72(05):959–972
- 5 Ridgway EB, Ropper AE, Mulliken JB, Padwa BL, Goumnerova LC. Meningoencephalocele: a late complication of Le Fort III midfacial advancement in a patient with Crouzon syndrome. *J Neurosurg Pediatr* 2010;6(04):368–371
- 6 Safavi-Abbasi S, Komune N, Archer JB, et al. Surgical anatomy and utility of pedicled vascularized tissue flaps for multilayered repair of skull base defects. *J Neurosurg* 2016;125(02):419–430
- 7 George B, Matula C, Kihlström L, Ferrer E, Tetens V. Safety and efficacy of TachoSil (absorbable fibrin sealant patch) compared with current practice for the prevention of cerebrospinal fluid leaks in patients undergoing skull base surgery: a randomized controlled trial. *Neurosurgery* 2017;80(06):847–853
- 8 Panuganti BA, Leach M, Antisdell J. Bilateral meningoencephaloceles with cerebrospinal fluid rhinorrhea after facial advancement in the Crouzon syndrome. *Allergy Rhinol (Providence)* 2015;6(02):138–142
- 9 Ridgway EB, Robson CD, Padwa BL, Goumnerova LC, Mulliken JB. Meningoencephalocele and other dural disruptions: complications of Le Fort III midfacial osteotomies and distraction. *J Craniofac Surg* 2011;22(01):182–186
- 10 Elster AD, Branch CL Jr. Transalar sphenoidal encephaloceles: clinical and radiologic findings. *Radiology* 1989;170(1 Pt 1):245–247
- 11 Mathias T, Levy J, Fatakia A, McCoul ED. Contemporary approach to the diagnosis and management of cerebrospinal fluid rhinorrhea. *Ochsner J* 2016;16(02):136–142
- 12 Hammer A, Baer I, Geletneky K, Steiner HH. Cerebrospinal fluid rhinorrhea and seizure caused by temporo-sphenoidal encephalocele. *J Korean Neurosurg Soc* 2015;57(04):298–302
- 13 Murai Y, Mizunari T, Kobayashi S, Teramoto A. Surgical technique for the prevention of cerebrospinal fluid leakage after bifrontal craniotomy. *World Neurosurg* 2014;81(02):344–347
- 14 Kelly HR, Curtin HD. Imaging of skull base lesions. *Handb Clin Neurol* 2016;135:637–657
- 15 Alonso RC, de la Peña MJ, Caicoya AG, Rodriguez MR, Moreno EA, de Vega Fernandez VM. Spontaneous skull base meningoencephaloceles and cerebrospinal fluid fistulas. *Radiographics* 2013;33(02):553–570