

# Acute care diagnostics in children for general radiologists – not alone in the hospital at night

## Akutdiagnostik Kinder für AllgemeinradiologInnen – nachts nicht allein im Krankenhaus

### Authors

Meinrad Beer<sup>1</sup>, Hans-Joachim Mentzel<sup>2,3</sup>, Marc Steinborn<sup>4</sup>, Matthias Cornelius Schaal<sup>1</sup>

### Affiliations

- 1 Department of Diagnostic and Interventional Radiology, University Hospital Ulm, Germany
- 2 Department of Radiology/Division of Paediatric Radiology, Jena University Hospital, Jena, Germany
- 3 President, German Society for Pediatric Radiology, Jena, Germany
- 4 Institute for Diagnostic and Interventional Radiology and Pediatric Radiology, Munich Municipal Hospital Group, München, Germany

### Key words

children, injuries, imaging sequences, decision analysis

received 25.02.2022

accepted 18.08.2022

published online 19.10.2022

### Bibliography

Fortschr Röntgenstr 2023; 195: 205–216

DOI 10.1055/a-1948-1380

ISSN 1438-9029

© 2022, Thieme. All rights reserved.

Georg Thieme Verlag KG, Rüdigerstraße 14,  
70469 Stuttgart, Germany

### Correspondence

Prof. Meinrad Beer

Abteilung für Diagnostische und Interventionelle Radiologie,  
Universitätsklinikum Ulm, Albert-Einstein-Allee 23,  
89081 Ulm, Germany

Tel.: +49/7 31/50 06 10 01

Fax: +49/7 31/50 06 10 02

meinrad.beer@uniklinik-ulm.de

### ABSTRACT

**Background** Radiologic care for children and adolescents during night and weekend shifts is challenging. This is especially true when a dedicated pediatric radiology front or back-ground service is not available.

**Methods** The purpose of this review is to present the approach, the most relevant diagnoses, and their differential diagnoses based on four common example cases – abdominal pain, respiratory/chest pain, headache, and refusal to walk. Essentials such as clinical classification (e. g., disease dynamics) and practical instructions (e. g., necessity of acute cross-sectional imaging) are presented.

**Results and Conclusion** For the abdomen, appendicitis ranks first among acute diseases. Other important diseases are intussusception and volvulus. Far more frequently, however, gastroenteritis is the cause of abdominal pain. Usually no imaging is required in this case. In unclear clinical situations, ultrasound may be indicated. In suspected pulmonary infections, chest imaging is limited to inconclusive cases and suspicion of complications such as pleural empyema. Major emergencies include (spontaneous) pneumothorax and aspiration. Headache is a common symptom. Immediate imaging is only necessary in cases of suspected acute inflammatory (meningitis/encephalitis) or vascular disease (e. g., hemorrhage due to vascular malformations). MRI is the primary imaging modality in these cases. Restricted walking/refusal to walk is a classic nonspecific sign, particularly of acute musculoskeletal disease, especially in younger children. Clinical examination is essential to narrow down the field of investigation. Besides the frequent and symptomatic coxitis fugax, the rare but serious (septic) arthritis/osteomyelitis must not be overlooked.

### Key Points:

- Radiological care of children and adolescents is challenging, especially during night and weekend shifts.
- However, in close cooperation with the referring colleagues/clinics, the appropriate approach can be effectively determined even if the symptoms are not clear.
- The selection of the optimal imaging method is based on guidance and guidelines, but also on the condition of the child/adolescent.
- A silent or whimpering child is cause for alarm.

### Citation Format

- Beer M, Mentzel H, Steinborn M et al. Acute care diagnostics in children for general radiologists – not alone at night in the hospital. Fortschr Röntgenstr 2023; 195: 205–216

## ZUSAMMENFASSUNG

**Hintergrund** Die radiologische Versorgung während des Nacht- und Wochenenddienstes von Kindern und Jugendlichen ist herausfordernd. Dies gilt insbesondere dann, wenn ein dedizierter kinderradiologischer Vorder- oder Hintergrunddienst nicht verfügbar ist.

**Methode** Die vorliegende Übersicht soll anhand von 4 häufigen Fallkonstellationen – Bauchschmerzen, Atem-/Brustschmerzen, Kopfschmerzen und Gehverweigerung – die Herangehensweise, die relevantesten Diagnosen und deren Differenzialdiagnosen vorstellen. Anhang von Merksätzen werden klinische Einordnung (z. B. Dynamik von Erkrankungen) und praktische Handlungsanweisungen (z. B. Notwendigkeit einer akuten Schnittbilddiagnostik) thematisiert.

**Ergebnisse und Schlussfolgerung** Für den Bauchbereich steht die Appendizitis an erster Stelle akuter Erkrankungen. Weitere wichtige Erkrankungen sind die Invagination und der Volvulus. Weit häufiger ist jedoch eine Gastroenteritis die Ursache der Bauchschmerzen. Diese bedarf im Regelfall keiner Bildgebung, in unklaren klinischen Situationen kann

der Ultraschall angezeigt sein. Für den Brustbereich erfolgt bei den häufig vorkommenden pulmonalen Infekten in den wenigsten Fällen eine Bildgebung. Nur bei nicht konklusiven Fällen und bei Verdacht auf Komplikationen wie einem Pleuraempyem wird die Bildgebung durchgeführt. Wichtige thorakale Notfälle sind der (Spontan-) Pneumothorax und die Aspiration. Kopfschmerzen sind häufig. Nur im Einzelfall ist bei Verdacht auf akut entzündliche (Meningitis/Enzephalitis) oder vaskuläre Erkrankungen (z. B. bei Blutung aufgrund von Gefäßmalformationen) eine umgehende Bildgebung erforderlich. Die MRT ist hier primäre Bildgebungsmethode. Geheinschränkung/Gehverweigerung ist ein klassisches unspezifisches Zeichen insbesondere bei kleinen Kindern für akute Erkrankungen im muskuloskelettalen Bereich. Die klinische Untersuchung ist essenziell um das Untersuchungsfeld einzugrenzen. Neben der häufigen und symptomatisch zu behandelnden Coxitis fugax darf die seltene, aber mit gravierenden Folgen vergesellschaftete (septische) Arthritis/Osteomyelitis keinesfalls übersehen werden.

It is challenging to perform radiological imaging in children and adolescents, particularly in very young children. This is especially true with regard to care provided during night and weekend shifts when doctors on duty are often on their own, the clinical data is vague, and the symptoms can be broad and confusing.

It is advisable to maintain close contact with the referring physician, pediatrician, or pediatric surgeon. Together the correct diagnosis can often be made, and the suitable treatment can be selected. This requires good clinical collaboration, which should be valued and maintained accordingly.

The purpose of the following review is to present some of the most important diseases based on clinical vignettes followed by systematic presentation of the important aspects of diagnosis, differential diagnosis, and recommended further clinical action by radiology and pediatric radiology.

Initially, we would like to make *four comments regarding ultrasound examination of children*:

1. Crying children are challenging, they are demanding, they can be irritating. Thankfully, there is typically no life-threatening danger and often no serious disease. The quieter a child is, the greater the threat.
2. Children's crying is often the result of uncertainty and fear due to the examination situation. Distraction ranging from cell phones to books and music is helpful for the physician, the child, and the parents.
3. Children of kindergarten and primary school age are often uncooperative. Encouragement only helps to a certain extent. Emanate calm and confidence (even if you don't necessarily feel that way). Allow the child to sit or be held by the parents. Ultimately, the correct diagnosis is the only thing that matters.
4. Adopt a uniform approach for abdominal ultrasound examination. The entire abdomen should always be examined if possible. Particularly in young children, the examination should be-

gin at the level of the bladder because spontaneous urination as often occurs in young children can make it difficult to sufficiently evaluate the lesser pelvis. The most painful part of the examination should not be performed until the end of the examination.

### Note

A silent or whimpering child is cause for alarm.

## Vignette 1: Abdominal pain

Abdominal pain is common in children and is a frequent reason for a visit to the doctor [1]. A child presenting at the emergency department with acute abdominal pain often has a common case of gastroenteritis. Based on the age of the child, the cause of abdominal pain can be narrowed slightly under consideration of common causes (► **Table 1** according to [2]). The primary and usually only necessary imaging examination in the case of abdominal pain is ultrasound. A child with clinically definitive gastroenteritis does not need to undergo ultrasound. In the case of uncertainty and unclear clinical symptoms, ultrasound is primarily used to rule out diseases or complications requiring treatment like ileocolic intussusception. Always bear in mind that pneumonia can also result in significant abdominal pain [3]. Therefore, in the case of unclear abdominal pain, it is essential also to perform an ultrasound examination for pleural effusion or signs of pneumonia which can initially be expressed in children only as fever and abdominal pain [4].

### Note

Pneumonia in children and adolescents can present as abdominal pain and should be considered as a differential diagnosis.

► **Table 1** Common causes of acute abdominal pain in children and adolescents in the different age groups.

Birth to one year	Two to five years	Six to 11 years	Adolescents
<ul style="list-style-type: none"> <li>▪ Infantile colic</li> <li>▪ Gastroenteritis</li> <li>▪ Constipation</li> <li>▪ Urinary tract infection</li> <li>▪ Intussusception</li> <li>▪ Volvulus</li> <li>▪ Incarcerated hernia</li> <li>▪ Hirschsprung's disease</li> </ul>	<ul style="list-style-type: none"> <li>▪ Gastroenteritis</li> <li>▪ Constipation</li> <li>▪ Urinary tract infection</li> <li>▪ Intussusception</li> <li>▪ Appendicitis</li> <li>▪ Pneumonia</li> <li>▪ Volvulus</li> <li>▪ Henoch-Schönlein purpura</li> <li>▪ Mesenteric lymphadenitis</li> </ul>	<ul style="list-style-type: none"> <li>▪ Gastroenteritis</li> <li>▪ Appendicitis</li> <li>▪ Constipation</li> <li>▪ Functional pain</li> <li>▪ Urinary tract infection</li> <li>▪ Pneumonia</li> <li>▪ Henoch-Schönlein purpura</li> <li>▪ Mesenteric lymphadenitis</li> </ul>	<ul style="list-style-type: none"> <li>▪ Appendicitis</li> <li>▪ Gastroenteritis</li> <li>▪ Constipation</li> <li>▪ Dysmenorrhea</li> <li>▪ Ovarian/testicular torsion</li> <li>▪ Ectopic pregnancy</li> </ul>

The workup of abdominal pain should concentrate on the main points and rule out the top 3 acute differential diagnoses. In descending order these are appendicitis, intussusception, and volvulus.

Acute appendicitis has a relatively high incidence and prevalence in children and adolescents with an age peak of 10–19 years [5]. Ultrasound plays an important role in diagnosis and differential diagnosis [6]. The classic sonographic signs of appendicitis are enlargement of the transverse diameter to more than 6 millimeters, hypoechoic thickening of the wall, echogenic reaction in the surrounding tissue, and surrounding free fluid. The presence of an appendicolith is not a definitive sign of significant appendicitis. In addition, gentle sonopalpation should be used to determine the site of the greatest pain so that a targeted examination can be performed (► Fig. 1a) [7]. The tip of the appendix should always be imaged when possible so that any inflammation or perforation in the region of the tip (also in the case of a retrocecal position or a cranial deviation of the vermiform appendix in the retrohepatic space) is not overlooked. Moreover, the additional color-coded duplex sonography examination shows increased vascularization. In the case of perforated appendicitis, the appendix can appear relatively thin but the perityphlitic abscess appears as a hypoechoic formation (► Fig. 1b) [8]. Since perforated appendicitis in young children is often associated with paralytic ileus, the clinical presentation can be similar to that of gastroenteritis.

#### Note

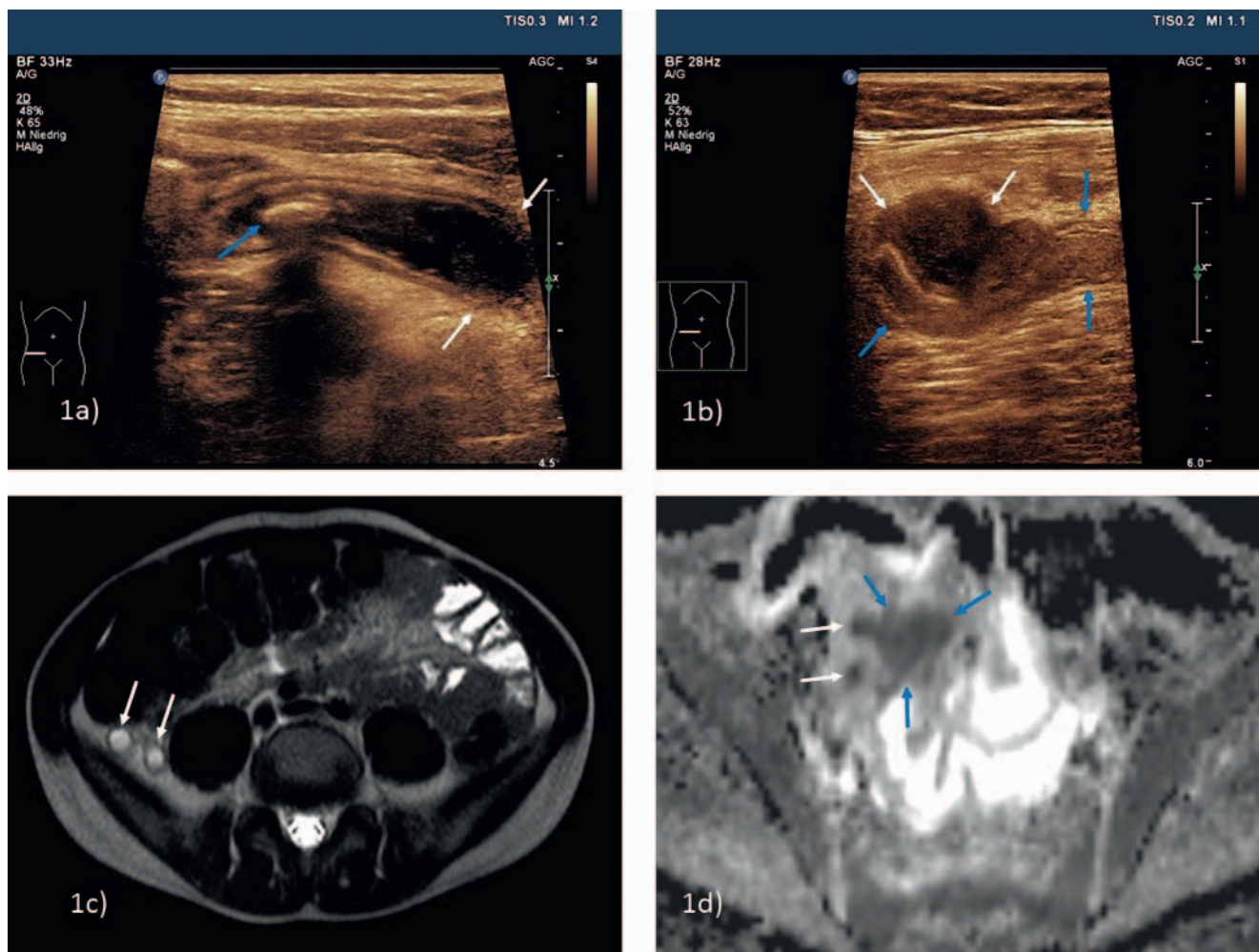
**Unremarkable images of parts of the appendix do not rule out appendicitis. The entire appendix must be reliably imaged to rule out appendicitis.**

In the case of insufficient ultrasound conditions (reduced compliance, obesity, or retrocecal position of the appendix) and corresponding clinical suspicion, cross-sectional imaging may be necessary in individual cases. MRI should be given preference in children and adolescents with a non-contrast examination being sufficient [9]. The combination of T2-weighted imaging and diffusion-weighted imaging is usually adequate. Ensure sufficient image quality of the T2 sequences and review the ADC images closely (► Fig. 1c, d).

In infants and toddlers, acute appendicitis is a significantly rarer cause of acute abdominal pain. One of the most common

causes of acute abdomen in children under the age of 2 years is ileocolic intussusception [10]. This is caused by invagination of the terminal ileum into the cecum/colon possibly resulting in intestinal ischemia. It presents clinically as recurrent screaming fits and vomiting or as stool with blood and mucous if present for a longer period. Diagnosis is made based on ultrasound. The classic target or bullseye sign is seen in the right middle or lower abdomen. In the case of a long intussusception, the invaginate can come to rest in the upper abdomen or possibly in the left hemiabdomen and look like a kidney on the longitudinal image (“pseudo kidney sign”). Lymph nodes are often visible within the bullseye. There is no risk of missing the invaginate due to overlying intestinal gas. There is no air at the location of the intussusception and the bullseye typically has a diameter of at least 2 cm (► Fig. 2a). The significantly smaller and typically asymptomatic small bowel intussusception (significantly smaller diameter, less recognizable, no lymph nodes included, often short, and not in the right lower to middle abdomen) can typically be easily differentiated from the clinically significant ileocolic intussusception on ultrasound [11]. During night and weekend shifts, it is important to rule out complications under consideration of the clinical history (duration of pain) to make a decision regarding conservative treatment (hydrostatic disinvagination under ultrasound guidance (► Fig. 2b) or possibly fluoroscopy) [12]. Signs of necrosis of the bowel wall (lack of vascularization on color-coded duplex sonography) or peritonitis (surrounding free fluid) and clinical signs of shock require a surgical approach.

A much rarer but highly relevant differential diagnosis for an acute abdomen primarily in newborns and babies is volvulus. Volvulus is defined as torsion of the vascular and mesenteric pedicle including multiple bowel segments. This is typically caused by a disorder of intestinal rotation which is not necessarily symptomatic but can result in a volvulus. Volvulus is most commonly seen in newborns and infants but can also occur in toddlers and school-age children [13]. Also in this case, diagnosis is typically made via ultrasound. Pay attention to the position of the artery with respect to the superior mesenteric vein in the upper abdomen. If the vein is not in the 11 o'clock position in relation to the artery, there is urgent suspicion of a disorder of intestinal rotation (► Fig. 2c) [14]. If you follow these vessels caudally, the typical whirlpool sign with twisting of the vein around the artery can be



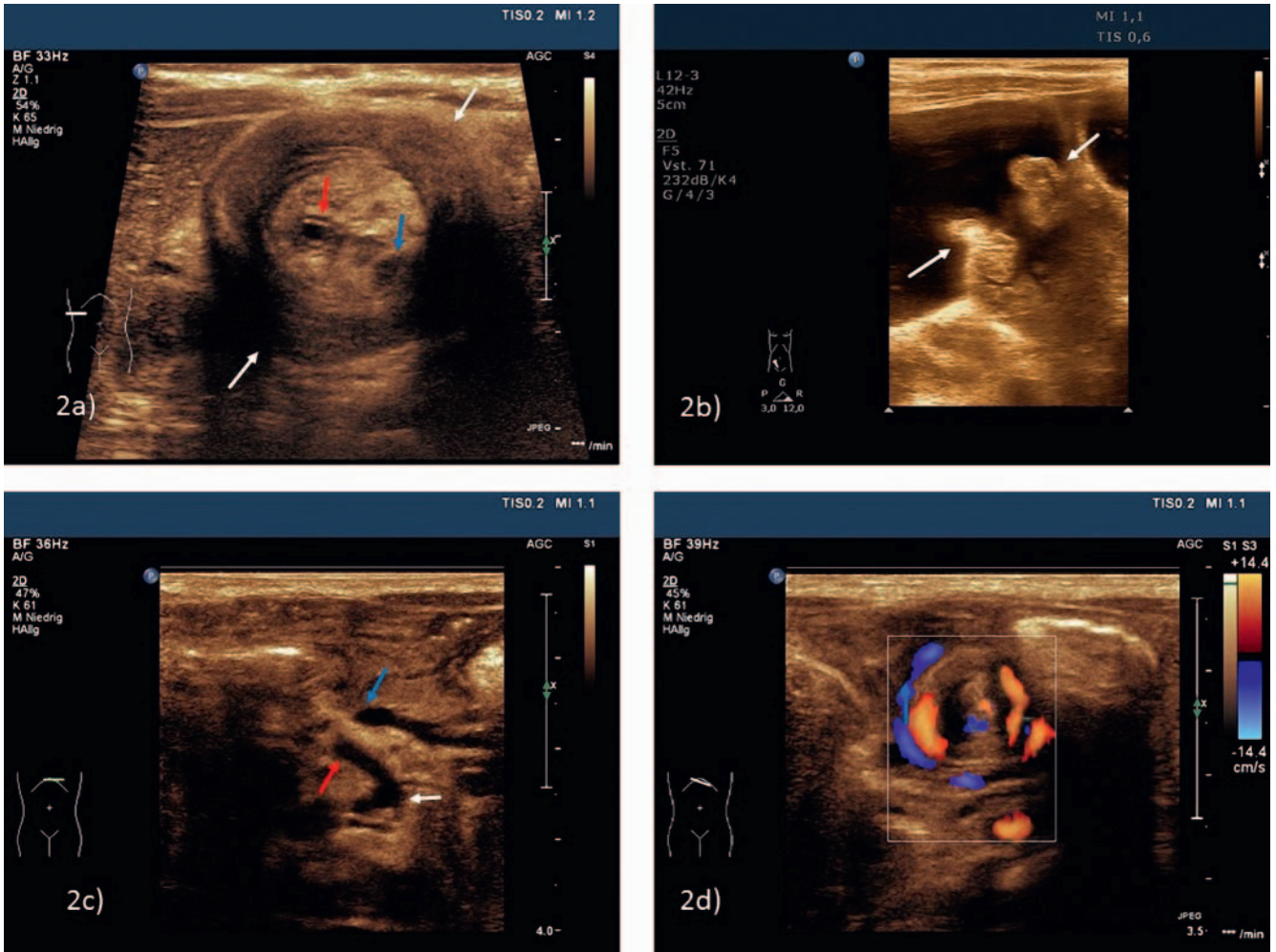
► **Fig. 1 1a)** 11-year-old girl with clinical suspicion of appendicitis. Sonographically clear thickening of the appendix especially at the tip (white arrows), echogenic surrounding reaction. Additionally, fecolith (blue arrow) with dorsal acoustic shadow. Histology: phlegmonous appendicitis. **1b)** 13-year-old patient with pain in the right lower abdomen for several days. After a short symptom-free interval, significant increase in pain and fever. Sonographic presentation of a perforated appendicitis with a small hypoechoic perityphlitic abscess (white arrows) at the level of the tip; the appendix itself only slightly thickened after perforation (blue arrows). **1c)** 8-year-old patient with clinical suspicion of appendicitis. Sonographically, the appendix vermiformis could not be visualized. Thickened and fluid-filled appendix (white arrows) in retrocecal position on MRI (T2 weighted). Histology: ulcerophlegmonous appendicitis. **1d)** 15-year-old patient with initial signs of gastroenteritis. Now acute deterioration with acute abdomen, sonographic signs of ileus. On MRI in the diffusion weighting/ADC map slightly thickened appendix vermiformis (white arrows) in the pelvis with perityphlitic abscess (blue arrows).

seen in the case of a volvulus. Color-coded duplex sonography is helpful here (► **Fig. 2 d**).

Ovarian torsion in girls (primarily in adolescents) must also be considered as a differential diagnosis of an acute abdomen [15]. Therefore, the internal reproductive organs should always also be examined on ultrasound, ideally with a full bladder.

The ingestion of a foreign object is common, particularly among young children. To evaluate whether a radiopaque foreign object was swallowed, how many foreign objects were swallowed, and where these foreign objects are located, the entire esophagus and gastrointestinal tract must be visualized. An X-ray image starting at the mandible/palate and extending to the symphysis is typically acquired here. In small children this can be achieved with a single scan, while two scans may be necessary in larger children. Ingestion of sharp objects like needles is less dangerous for

the intestines than ingestion of objects like magnets and button batteries [16]. If at least 2 magnets are ingested, adherence of adjacent intestinal loops or clamping of the intestinal mucosa can occur resulting in pressure necrosis and perforation (► **Fig. 3a, b**). The current flow of a swallowed button battery can result in necrosis of the mucosa which can result in a perforation relatively quickly (► **Fig. 3c**). This is primarily the case when a battery gets stuck in the esophagus [17]. In such cases, immediate esophagoscopy recovery is necessary. If the button battery is located in the stomach and the child is asymptomatic, it is not considered an emergency situation. However, the button battery should be recovered within 24–48 hours [18]. X-ray control images are first acquired again to ensure that the battery has not passed through the pylorus. In the case of a post-pyloric position, wait for the battery to be expelled via natural elimination.



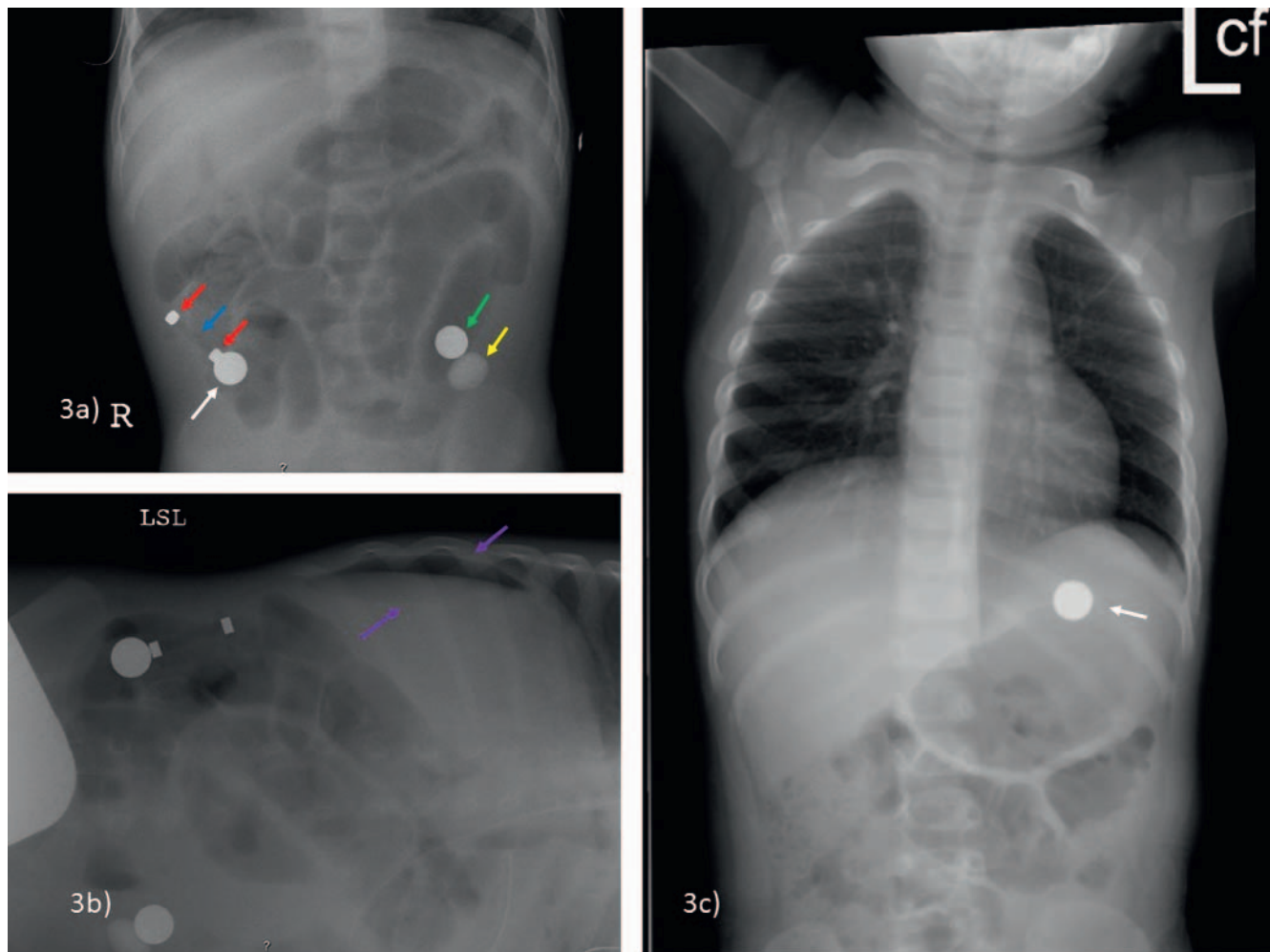
► **Fig. 2 2a)** 3-year-old female patient with recurrent crying episodes and clinical suspicion of intussusception. Sonographic classic finding of an extended ileocecal intussusception (white arrows) at the inferior border of the liver. Within the invagination, in addition to hyperechoic mesenteric fat tissue, small lymph nodes (blue arrow) and the fluid-filled appendix vermiformis (red arrow). **2b)** Sonographically assisted successful hydrostatic disinvagination: the intussusception has already resolved, and the rectally applied fluid passes through the swollen ileocecal valve (white arrows). **2c)** 2-month-old infant with recurrent vomiting and tense abdomen, increasing deterioration of general condition. Sonographically atypical mesenteric vessels: the superior mesenteric artery (red arrow) runs to the right after leaving the abdominal aorta (white arrow); the superior mesenteric vein/the portal confluence (blue arrow) is not at the 11 o'clock position in relation to the artery. Suspected disorder of intestinal rotation. **2d)** Same child as in 2c); if the vessel axis is followed caudally, torsion of the mesenteric pedicle around the artery, so-called “whirlpool sign”; color duplex imaging is usually helpful. Intraoperative confirmation of a volvulus based on nonrotation.

## Vignette 2: Difficulty breathing and chest pain

Pulmonary infections are common. In a few cases, chest X-ray is performed as performed in adults. However, clinical examination and laboratory testing are usually sufficient. In inconclusive cases or suspicion of (complicated) pneumonia, imaging is performed. In peripheral findings, ultrasound acts as an excellent supplement or alternative to X-ray examination [19] (► Fig. 4a, b). It is essential to diagnose complications of a pulmonary infection, e. g., pleural empyema, during night and weekend shifts. Ultrasound can also be effectively used here since non-anechoic or loculated empyema can be differentiated with high certainty from anechoic effusion based on the echogenicity (► Fig. 4c). Additional cross-sectional imaging may be necessary to determine the further therapeutic procedure (e. g. placement of a drainage tube) [20].

In the case of poor clinical condition of the child, a dose-adjusted CT examination that is suitable for children should be performed. Low-dose protocols are typically used here. Equipment manufacturers also provide various pediatric protocols (weight and/or age-adapted). To achieve the greatest possible dose reduction (see dose reference values of the German Federal Agency for Radiation Protection [21]), iterative image reconstruction methods should be used [22]. Further information is available from various Internet portals (e. g. [23]). Alternatively, MRI can be performed depending on the clinical setting and available equipment.

Pneumothorax is second important differential diagnosis. Spontaneous pneumothoraces can occur in asthenic adolescents. The imaging standard remains chest X-ray. Analogous to current recommendations in adults [24], examination during inspiration should be given preference over examination during expiration



► **Fig. 3 3a, 3b)** 1.5-year-old infant with acute abdomen; initially vomiting, increasing dehydration, deterioration of general condition, increasing peritonism. No memory of foreign body ingestion. On ultrasound, ileus signs and free fluid (image not shown). In the abdominal overview radiograph distended intestinal loops and several radiopaque foreign bodies, in left lateral position free abdominal air (purple arrows). In the laparotomy evidence of a perforation in the preterminal ileum, detection of a roundish metal ball (white arrow) with adherent rod-shaped magnet: between the two magnetic parts (red arrows) radiolucent connection of plastic (blue arrow); additionally, detection of another metal ball (green arrow) and a glass marble (yellow arrow) from the sigmoid. **3c)** 2-year-old child, unobserved ingestion of a button battery is suspected by the parents. In the plain radiograph (height of mandible to iliac crests) detection of the roundish radiopaque foreign body in projection to the stomach. The button battery has not yet passed the pylorus, in case of an asymptomatic child removal of the foreign body should be done within 24–48 h, in symptomatic child immediately.

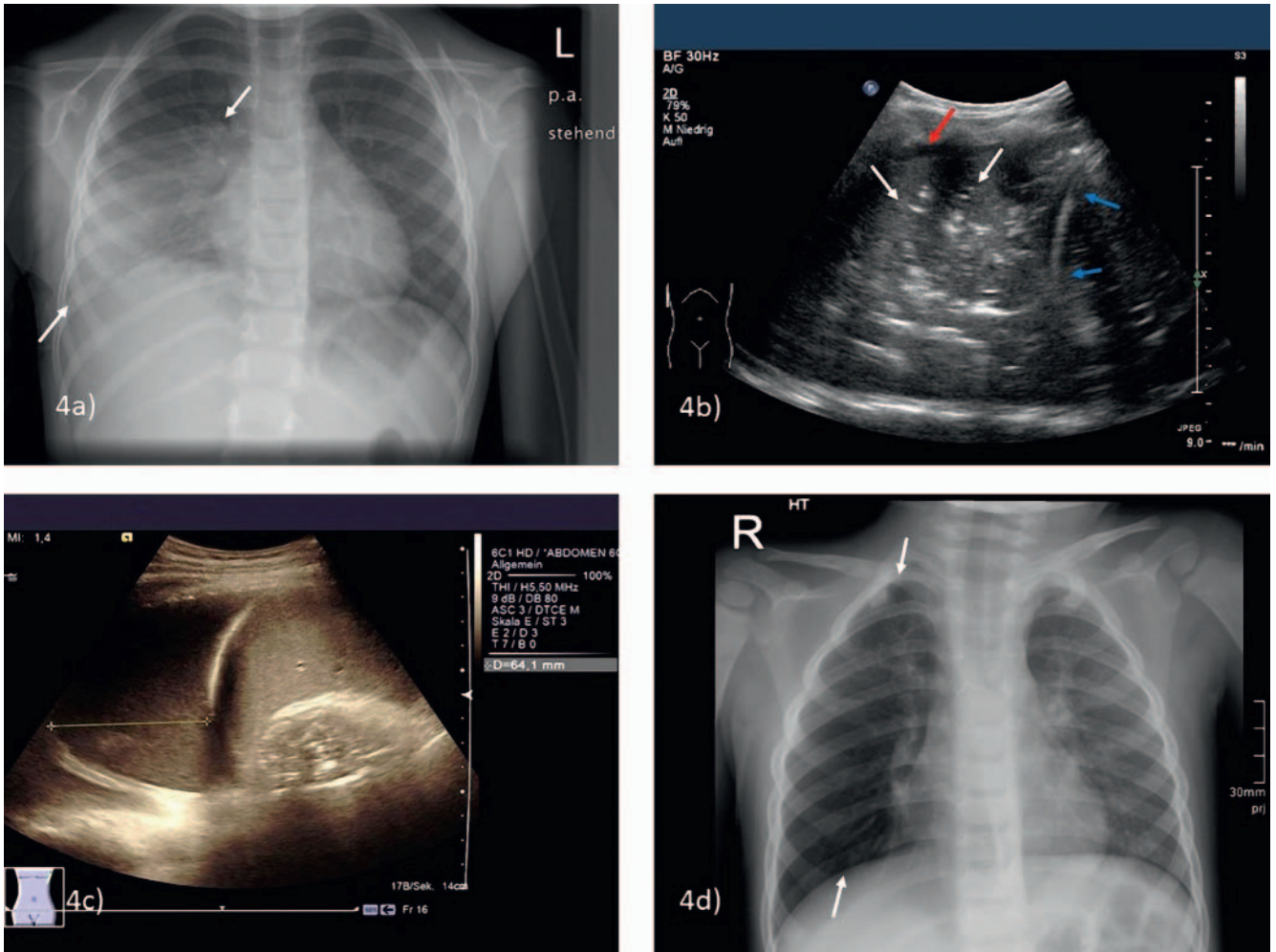
for children and adolescents. Although acquisitions during inspiration and expiration do not seem to differ significantly from one another regarding the detection of a pneumothorax, in the case of a basal pneumothorax, pleuropulmonary dehiscence appears to be slightly wider when imaged in inspiration [25]. In the case of a tension pneumothorax with mediastinal shift, immediate action is necessary.

A third important differential diagnosis in the case of thoracic symptoms is aspiration of a foreign object. Young children are primarily affected [26]. Common objects include pieces of apple, carrot, or nut that are aspirated resulting in a possible obstruction of the tracheobronchial system (► **Fig. 4 d**). Clinical symptoms can vary greatly. Imaging is only a piece in the verification of the diagnosis and is useful for planning bronchoscopy [27]. It is desirable to perform lung imaging during expiration to show air trapping. It

is definitely useful to create dynamic pulsed low-dose fluoroscopy images of the respiratory tract. Images of the patient lying on the right and left side can be helpful [28]. 3 pulses/second are typically sufficient. An indication of chronic aspiration can be pneumonia or atelectasis recurring in the same location.

#### Note

**In the case of aspiration of a foreign object, X-ray is typically used not for direct detection of the foreign object (aspirated food is not radiopaque) but rather for indirect detection of a valve mechanism caused by the foreign object.**



► **Fig. 4** **4a)** 6-year-old female patient with cough and fever for several days, now deterioration of general condition. On chest X-ray, opacity in the right lower and middle field as in lobar pneumonia (right lower lobe). **4b)** Same child as in 4a). On ultrasound, extensive consolidated infiltrate in the right lower lobe of the lung with multiple air bronchograms (white arrows) cranial to the right diaphragmatic crest (blue arrows). Only minimal accompanying effusion (red arrow). **4c)** 10-year-old patient with confirmed pneumonia on the left side, clinical deterioration. On ultrasound, large pleural effusion on the left with multiple internal echoes as in beginning pleural empyema, confirmed by subsequent chest drainage. **4d)** 4-year-old boy, anamnestic and clinical suspicion of aspiration of a peanut. On the chest X-ray, overinflation of the right lung (white arrows) was visible already on the inspiratory image, with emphasis of the lower field as in a valve mechanism. Subsequently, bronchoscopic extraction of the peanut from the right lower lobe bronchus.

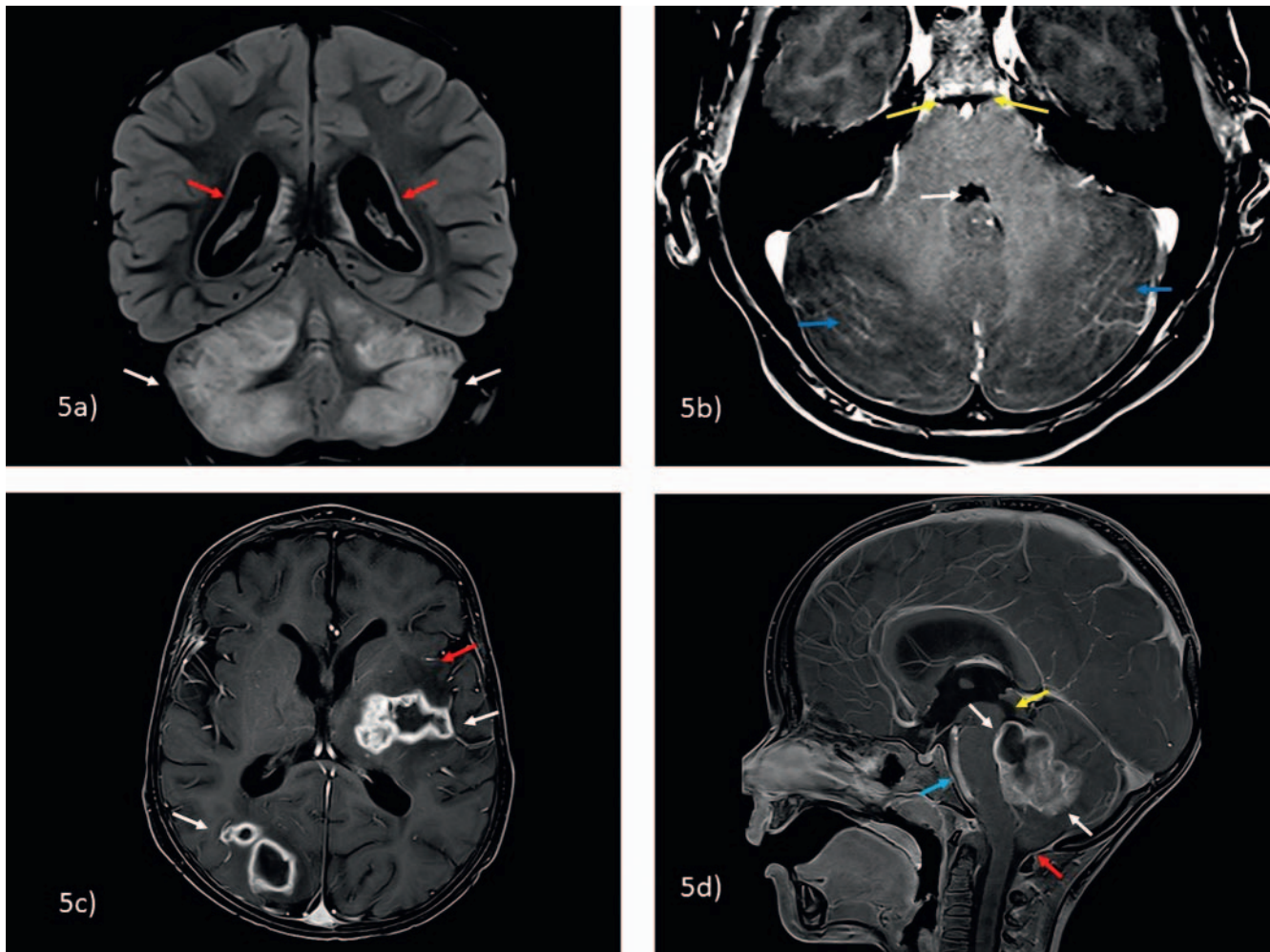
### Vignette 3: Headache

Headaches are common in children and adolescents. They can result from a variety of stress situations and can also be caused by migraines. However, in rare cases, relevant diseases can manifest as headaches and these diseases must be detected. To determine whether emergency imaging on a weekend or at night is necessary, a neuropaediatric evaluation should also be performed if possible. However, emergency brain MRI performed in children and adolescents often does not show any acute pathology [29].

During regular hours, imaging is often performed prior to a possible lumbar puncture to rule out meningitis/encephalitis (to first rule out elevated intracranial pressure). We initially perform non-contrast MRI (T2- and T1-weighted sequences, FLAIR = fluid-attenuated inversion recovery and diffusion weighting; in young and possibly unsettled children fast T2 sequences can also be per-

formed as “exploratory sequences” or the short protocols of the various manufacturers are suitable). If the non-contrast MRI scan shows abnormalities, additional sequences with contrast administration should be considered [30]. Therefore, the non-contrast images must be reviewed before the patient is moved from the scanner (► Fig. 5a–c).

A second important differential diagnosis is acute vascular disease or intracranial hemorrhage. Even though strokes in children and adolescents are rare, they are not as rare as previously often thought (approximately 5 in 100 000 children) [31]. Almost half of strokes in children and adolescents are caused by bleeding [32], e. g., due to a preexisting vascular malformation (AV malformation, cavernous malformation) [31] or a sinus thrombosis (► Fig. 6a). In contrast to the situation in adults, ischemic strokes are not in the foreground. However, newborns and patients with vascular disease or sickle cell disease are particularly affected



► **Fig. 5 5a)** 5-year-old girl with severe headache, multiple vomiting, no meningism. Coronary FLAIR, marked distension and signal enhancement of the cerebellar hemispheres (white arrows). In addition, CSF accumulation with transependymal CSF diapedesis (red arrows). **5b)** Same child as in 5a). ce fs T1-GRE, diffuse infratentorial leptomenigeal enhancement (blue arrows), constriction of 4<sup>th</sup> ventricle (white arrow) and prepontine cistern (yellow arrows). Evidence of Mycoplasma antibodies in cerebrospinal fluid, clinical and radiological improvement after clarithromycin. **5c)** 3-year-old boy with underlying oncological disease. Fever in aplasia, weakness of the right arm, increasing drowsiness. ce fs T1-GRE, multiple central necrotic and ring-enhancing bihemispheric lesions (white arrows), plus perifocal edema (red arrow). Biopsy with microbiological detection of Aspergillus. **5d)** 4-year-old boy, progressive gait unsteadiness, headache symptoms, now fasting vomiting. ce fs T1-GRE, large polylobulated partly enhancing and partly cystic mass in the 4<sup>th</sup> ventricle (white arrows). Consecutive protrusion of the cerebellar tonsils (red arrow), displacement of the brainstem (blue arrow) and congestion of CSF (yellow arrow). Resection, histology: anaplastic medulloblastoma.

► **Fig. 6b).** With an incidence of approx. 0.4–0.7 in 100 000 children, sinus thromboses [33] often occur in association with a primary ENT infection (► **Fig. 6c, d).**

A very rare differential diagnosis for headache during night and weekend shifts is the primary detection of previously unknown primary brain tumors [34] (► **Fig. 5c)** or the extremely rare detection of intracranial metastases in children and adolescents.

In children and adolescents with hydrocephalus treated with a shunt, MRI imaging is required also during regular hours in the case of headache, suspected shunt dysfunction, or overdrainage. Short T2 sequences are sufficient [35].

#### Note

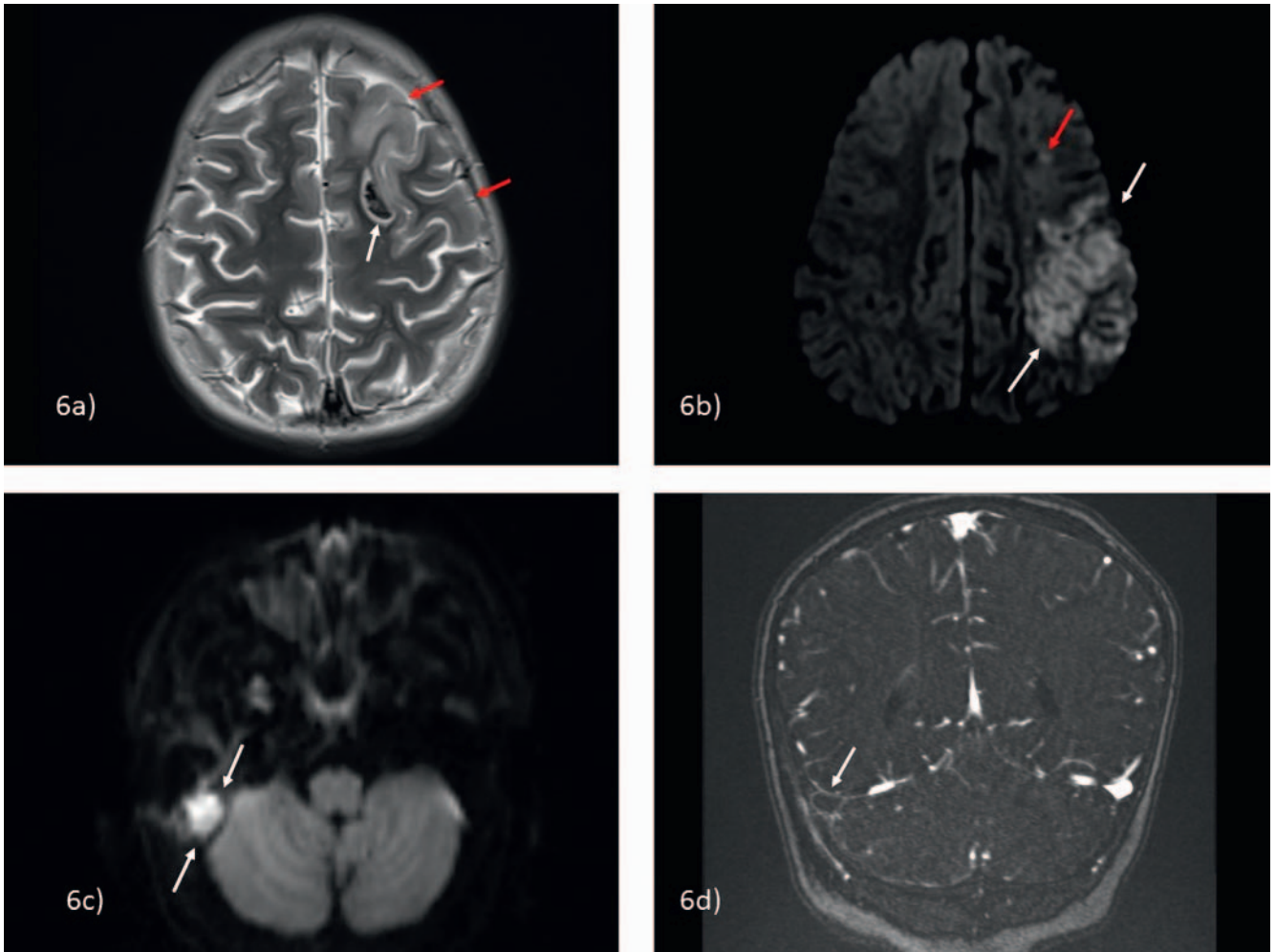
In the case of clinical indication of an intracranial vascular problem (often presenting as seizures in newborns and infants

that can be difficult to detect, and as focal neurology or severe headache in older children), prompt MRI examination with diffusion weighting and angio sequences (non-contrast time-of-flight sequences and in case of doubt contrast-enhanced angio and post-contrast sequences) are obligatory also during night and weekend shifts.

#### Vignette 4: Refusal to walk

Children with restriction of motion are most often seen in the radiology department during night and weekend shifts following a trauma. Conventional X-ray performed on 2 planes remains the standard imaging method here. In the case of a classic clinical scenario (e. g., after jumping on a trampoline) and clinical symptoms (e. g., pain in the knee region or the spine) but unremarkable con-





► **Fig. 6 6a)** 6-year-old female patient with underlying oncological disease. Acute onset right body weakness followed by focal seizures. Transverse T2 turbo spin-echo sequence, acute intracerebral hemorrhage in the left frontal lobe (white arrow) on the basis of thrombosis of the superior sagittal sinus (not shown); additional edematous distension of the adjacent cortex (red arrows). **6b)** 2.5-year-old boy with known sickle cell disease. Hemiparesis on the right side since the day before. Transverse diffusion weighting (b-value 1000), acute territorial infarction in the left middle cerebral artery area (white arrows), additional border zone infarctions (red arrow). **6c)** 10-year-old female patient with mastoiditis on the right side, persistent severe headache after mastoidectomy (at external clinic). Transverse diffusion weighting (b-values 1000), focal diffusion restriction in the right posterior fossa (white arrows) in terms of an epidural abscess. **6d)** Same patient as in 6c). Coronary contrast-enhanced sinus angiography, prior to the epidural abscess lack of contrast of the right transverse sinus (white arrow) as in sinus thrombosis.

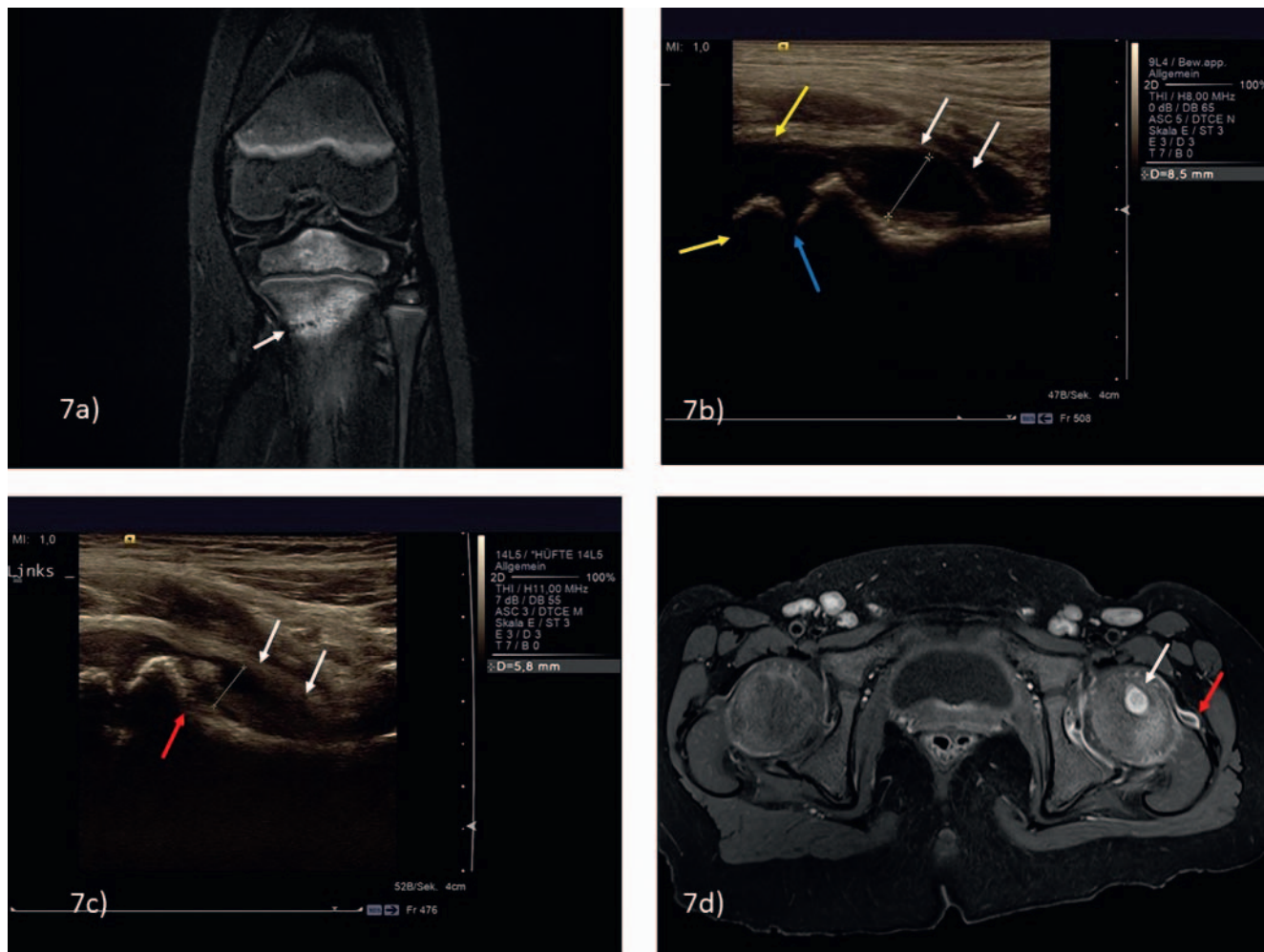
ventional imaging, non-contrast MRI is useful on an individual basis for further diagnostic workup (► **Fig. 7a**).

A diagnostic problem in young children with refusal to walk is that they cannot say where it hurts. Causes include fractures (toddler's fracture or fractures of the metatarsalia) or other pathologies of the spine (e.g. discitis or tumor). Good clinical examination is essential here in order to determine the location of the problem and then to perform a targeted search in the corresponding region of the body. A prior sonographic examination can often help to focus the X-ray or cross-sectional imaging examination.

#### Note

The younger the child, the greater the importance of the prior clinical examination to localize the problem and thus plan subsequent imaging.

A common and harmless cause of hip pain and refusal to walk in young children is coxitis fugax, a type of reactive arthritis that often occurs after viral infection [36]. Ultrasound shows typically anechoic hip effusion (► **Fig. 7b**). There is usually no fever and inflammatory markers are not elevated. An important differential diagnosis that must not be overlooked is septic arthritis/osteomyelitis, which is usually associated with fever. Particularly in young children, if the disease is not diagnosed, necrosis of the femoral head can occur, resulting in rapid and irreversible destruction of the joint [37]. Ultrasound imaging (which often shows joint effusion with internal echoes) is essential. If contrast-enhanced MRI is necessary due to clinical suspicion of osteomyelitis, it should be performed as promptly as possible even during night and weekend shifts (► **Fig. 7c, d**).



► **Fig. 7 7a)** 4-year-old girl with severe pain of the left knee after trampolining. Plain radiograph inconclusive (not shown), a TIRM sequence was obtained. Bone marrow edema of the proximal left tibia with recognizable non-displaced fracture line of the metaphysis. Conservative therapy. **7b)** 1.5-year-old boy with coxitis fugax. A few days ago upper respiratory tract infection, now refusal to walk, no fever, negative laboratory infection parameters. Anechoic effusion in the right hip joint with detachment of the joint capsule (white arrows, distance measurement 9 mm). Physiologically, incomplete ossification of the femoral head (yellow arrows) and growth plate (blue arrow). **7c)** 2-year-old boy, fever and posture/limping of the left leg for 2 days, elevated erythrocyte sedimentation rate. Sonographic findings: effusion in the left hip joint with internal echoes (white arrows, distance measurement 6 mm), additional slight irregularity of the bone contour of the proximal metaphysis (red arrow). **7d)** Same patient as in 7c). ce fs T1-GRE. Osteomyelitis of the left proximal femoral metaphysis (white arrow), additionally small effusion and synovialitis (red arrow).

#### Note

**Septic arthritis/osteomyelitis must not be overlooked because irreversible (joint) damage can quickly occur.**

Further rare differential diagnoses are autoimmune inflammatory diseases like juvenile idiopathic arthritis (JIA) and non-bacterial osteomyelitis (NBO, CNO, CRMO). These can also be seen during night and weekend shifts in individual cases. Conventional X-ray examination is almost always negative at least in the early stage [38]. Further diagnostic imaging via MRI is relevant and should be performed as soon as possible [39] but is usually not an emergency that needs to be performed during the night shift.

The present list of differential diagnoses makes no claim of being comprehensive. Rather it is intended to provide some of the main differential diagnoses that must not be overlooked. It is equally important to keep less serious diseases that can be symptomatic

and are often seen during night and weekend shifts in the back of your mind. It is essential to remain calm even in complex situations and to remain professional. Think about the important role that radiology in general and pediatric radiology in particular play in shaping the further clinical treatment decisions for these children and adolescents and their parents. When selecting the examination modality it is helpful to use the orientation aids of the German Commission on Radiological Protection [40] and the various guidelines of the Association of the Scientific Medical Societies in Germany and the German Society for Pediatric Radiology that are available on the Internet and provide symptom-based recommendations regarding the diagnostic approach. In addition, there is a possibility to consult with pediatric radiologists (chart of the German Society for Pediatric Radiology: <https://www.kinder-radiologie.org/>). And remember the statement made at the beginning of this article – a silent or whimpering child is cause for alarm.

## Conflict of Interest

The authors declare that they have no conflict of interest.

## References

- [1] Zeiter DK. Abdominal Pain in Children: From the Eternal City to the Examination Room. *Pediatr Clin North Am* 2017; 64 (3): 525–541. doi:10.1016/j.pcl.2017.01.012
- [2] Leung AK, Sigalet DL. Acute abdominal pain in children. *Am Fam Physician* 2003; 67 (11): 2321–2326
- [3] Moustaki M, Zeis PM, Katsikari M et al. Mesenteric lymphadenopathy as a cause of abdominal pain in children with lobar or segmental pneumonia. *Pediatr Pulmonol* 2003; 35 (4): 269–273. doi:10.1002/ppul.10254
- [4] Ravichandran D, Burge DM. Pneumonia presenting with acute abdominal pain in children. *Br J Surg* 1996; 83 (12): 1707–1708. doi:10.1002/bjs.1800831214
- [5] Buckius MT, McGrath B, Monk J et al. Changing epidemiology of acute appendicitis in the United States: study period 1993–2008. *J Surg Res* 2012; 175 (2): 185–190. doi:10.1016/j.jss.2011.07.017
- [6] Rentea RM, Peter SDS, Snyder CL. Pediatric appendicitis: state of the art review. *Pediatr Surg Int* 2017; 33 (3): 269–283. doi:10.1007/s00383-016-3990-2
- [7] Gongidi P, Bellah RD. Ultrasound of the pediatric appendix. *Pediatr Radiol* 2017; 47 (9): 1091–1100. doi:10.1007/s00247-017-3928-4
- [8] Riedesel EL, Weber BC, Shore MW et al. Diagnostic performance of standardized ultrasound protocol for detecting perforation in pediatric appendicitis. *Pediatr Radiol* 2019; 49 (13): 1726–1734. doi:10.1007/s00247-019-04475-5
- [9] Lyons GR, Renjen P, Askin G et al. Diagnostic utility of intravenous contrast for MR imaging in pediatric appendicitis. *Pediatr Radiol* 2017; 47 (4): 398–403. doi:10.1007/s00247-016-3775-8
- [10] Mandeville K, Chien M, Willyerd FA et al. Intussusception: clinical presentations and imaging characteristics. *Pediatr Emerg Care* 2012; 28 (9): 842–844. doi:10.1097/PEC.0b013e318267a75e
- [11] Lioubashevsky N, Hiller N, Rozovsky K et al. Ileocolic versus small-bowel intussusception in children: can US enable reliable differentiation? *Radiology* 2013; 269 (1): 266–271. doi:10.1148/radiol.13122639
- [12] Edwards EA, Pigg N, Courtier J et al. Intussusception: past, present and future. *Pediatr Radiol* 2017; 47 (9): 1101–1108. doi:10.1007/s00247-017-3878-x
- [13] Aboagye J, Goldstein SD, Salazar JH et al. Age at presentation of common pediatric surgical conditions: Reexamining dogma. *J Pediatr Surg* 2014; 49 (6): 995–999. doi:10.1016/j.jpedsurg.2014.01.039
- [14] Youssfi M, Goncalves LF. Ultrasound for malrotation and volvulus – point. *Pediatr Radiol* 2021. doi:10.1007/s00247-021-05154-0
- [15] Dasgupta R, Renaud E, Goldin AB et al. Ovarian torsion in pediatric and adolescent patients: A systematic review. *J Pediatr Surg* 2018; 53 (7): 1387–1391. doi:10.1016/j.jpedsurg.2017.10.053
- [16] Schmid MB, Posovszky C, Neuwirth F et al. Diagnostisches und therapeutisches Vorgehen bei Fremdkörperingestionen im Kindesalter [Foreign body ingestion in children: recommendation for the diagnostic and therapeutic procedure]. *Laryngorhinotologie* 2010; 89 (2): 73–76. doi:10.1055/s-0029-1241168
- [17] Mubarak A, Benninga MA, Broekaert I et al. Diagnosis, Management, and Prevention of Button Battery Ingestion in Childhood: A European Society for Paediatric Gastroenterology Hepatology and Nutrition Position Paper. *J Pediatr Gastroenterol Nutr* 2021; 73 (1): 129–136. doi:10.1097/MPG.0000000000003048
- [18] S2k-Leitlinie der AWMF: Interdisziplinäre Versorgung von Kindern nach Fremdkörperaspiration und Fremdkörperingestion (Dezember 2015, derzeit in Überarbeitung). Im Internet: Handlungsempfehlung/Leitlinie zur interdisziplinären Versorgung von Kindern nach Fremdkörperaspiration und Fremdkörperingestion (awmf.org) Stand: 20.04.2022.
- [19] Balk DS, Lee C, Schafer J et al. Lung ultrasound compared to chest X-ray for diagnosis of pediatric pneumonia: A meta-analysis. *Pediatr Pulmonol* 2018; 53 (8): 1130–1139. doi:10.1002/ppul.24020
- [20] de Benedictis FM, Kerem E, Chang AB et al. Complicated pneumonia in children. *Lancet* 2020; 396: 786–798. doi:10.1016/S0140-6736(20)31550-6
- [21] Bundesamt für Strahlenschutz – Bekanntmachung der aktualisierten diagnostischen Referenzwerte. Im Internet: BfS – Diagnostische Referenzwerte Stand: 20.04.2022.
- [22] Nagayama Y, Oda S, Nakaura T et al. Radiation Dose Reduction at Pediatric CT: Use of Low Tube Voltage and Iterative Reconstruction [published correction appears in *Radiographics*. 2019 May-Jun; 39(3): 912]. *Radiographics* 2018; 38 (5): 1421–1440. doi:10.1148/rg.2018180041
- [23] Image Gently, Radiology Safety – What can I do? Im Internet: Radiology Safety – What can I do? – Image Gently Stand: 20.04.2022.
- [24] S3-Leitlinie der AWMF: Diagnostik und Therapie von Spontanpneumothorax und postinterventionellem Pneumothorax (März 2018). Im Internet (Stand 22.02.2022): [https://www.awmf.org/uploads/tx\\_szleitlinien/010-0071\\_S3\\_Spontanpneumothorax-postinterventioneller-Pneumothorax-Diagnostik-Therapie\\_2018-03\\_01.pdf](https://www.awmf.org/uploads/tx_szleitlinien/010-0071_S3_Spontanpneumothorax-postinterventioneller-Pneumothorax-Diagnostik-Therapie_2018-03_01.pdf)
- [25] Thomsen L, Natho O, Feigen U et al. Value of digital radiography in expiration in detection of pneumothorax. *Fortschr Röntgenstr* 2014; 186 (3): 267–273. doi:10.1055/s-0033-1350566
- [26] Lima JA, Fischer GB. Foreign body aspiration in children. *Paediatr Respir Rev* 2002; 3 (4): 303–307. doi:10.1016/s1526-0542(02)00265-8
- [27] Foltran F, Ballali S, Rodriguez H et al. Inhaled foreign bodies in children: a global perspective on their epidemiological, clinical, and preventive aspects. *Pediatr Pulmonol* 2013; 48 (4): 344–351
- [28] Wunsch R, Glöbl H. Fremdkörper der unteren Luftwege. In: Benz-Bohm G, Hrsg. *Kinderradiologie. 2., erweiterte und vollständig überarbeitete Auflage* Stuttgart: Thieme; 2005
- [29] Dao JM, Qubty W. Headache Diagnosis in Children and Adolescents. *Curr Pain Headache Rep* 2018; 22 (3): 17. doi:10.1007/s11916-018-0675-7
- [30] Dünger D, Krause M, Gräfe D et al. Do we need gadolinium-based contrast medium for brain magnetic resonance imaging in children? *Pediatr Radiol* 2018; 48 (6): 858–864. doi:10.1007/s00247-017-3999-2
- [31] Johns C, Kolla S, Hart A et al. A pictorial review of imaging in paediatric stroke. *Postgrad Med J* 2016; 92: 545–553. doi:10.1136/postgradmedj-2015-133409
- [32] Boulouis G, Blauwblomme T, Hak JF et al. Nontraumatic Pediatric Intracerebral Hemorrhage. *Stroke* 2019; 50 (12): 3654–3661. doi:10.1161/STROKEAHA.119.025783
- [33] Dlamini N, Billinghurst L, Kirkham FJ. Cerebral venous sinus (sinovenous) thrombosis in children. *Neurosurg Clin N Am* 2010; 21 (3): 511–527. doi:10.1016/j.nec.2010.03.006
- [34] Avula S, Peet A, Morana G et al. European Society for Paediatric Oncology (SIOPe) MRI guidelines for imaging patients with central nervous system tumours. *Childs Nerv Syst* 2021; 37 (8): 2497–2508. doi:10.1007/s00381-021-05199-4
- [35] Patel DM, Tubbs RS, Pate G et al. Fast-sequence MRI studies for surveillance imaging in pediatric hydrocephalus. *J Neurosurg Pediatr* 2014; 13 (4): 440–447. doi:10.3171/2014.1.PEDS13447
- [36] Yagdiran A, Zarghooni K, Semler JO et al. Hip Pain in Children. *Dtsch Arztebl Int* 2020; 117 (5): 72–82. doi:10.3238/arztebl.2020.0072

- [37] Gigante A, Coppa V, Marinelli M et al. Acute osteomyelitis and septic arthritis in children: a systematic review of systematic reviews. *Eur Rev Med Pharmacol Sci* 2019; 23 (2): 145–158. doi:10.26355/eurrev\_201904\_17484
- [38] Zhao Y, Ferguson PJ. Chronic Nonbacterial Osteomyelitis and Chronic Recurrent Multifocal Osteomyelitis in Children. *Pediatr Clin North Am* 2018; 65 (4): 783–800. doi:10.1016/j.pcl.2018.04.003
- [39] Hedrich CM, Morbach H, Reiser C et al. New Insights into Adult and Paediatric Chronic Non-bacterial Osteomyelitis CNO. *Curr Rheumatol Rep* 2020; 22 (9): 52. doi:10.1007/s11926-020-00928-1
- [40] Orientierungshilfe für bildgebende Verfahren – Empfehlung der Strahlenschutzkommission (Juni 2019). Im Internet (Stand: 22.02.2022): [https://www.ssk.de/SharedDocs/Beratungsergebnisse\\_PDF/2019/2019-06-27Orientie.pdf?\\_\\_blob=publicationFile](https://www.ssk.de/SharedDocs/Beratungsergebnisse_PDF/2019/2019-06-27Orientie.pdf?__blob=publicationFile)