

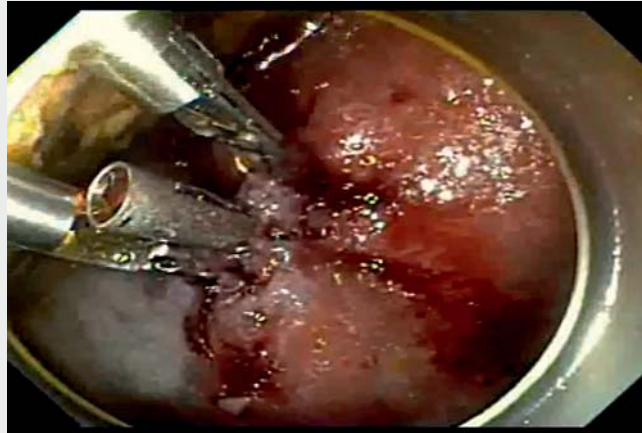Closure of a gastric endoscopic resection defect with a novel closure device



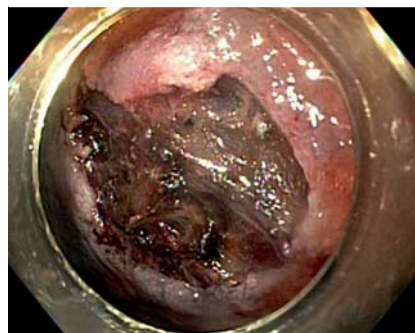
Closure of mucosal defects after endoscopic mucosal resection or endoscopic submucosal dissection (ESD) has been shown to reduce the risk of delayed bleeding and perforation [1–4]. Defect closure can be achieved using over-the-scope (OTS) clips, through-the-scope (TTS) clips, or endoscopic suturing [4]. The Dual Action Tissue (DAT) clip (Micro-Tech Endoscopy, Ann Arbor, Michigan, USA) is a novel TTS clip closure device with one center post and two jaws that function independently to approximate tissue margins. It has a 15-mm opening width and is compatible with endoscopes with a working channel diameter of 3.2 mm. Given its recent Food and Drug Administration approval in January 2022, literature is scarce surrounding its use. In this video report (▶ **Video 1**), we demonstrate its use for defect closure after a hybrid gastric ESD.

A 75-year-old man with diffuse gastric intestinal metaplasia was found to have a 15-mm gastric polyp. Biopsies showed a tubular adenoma and he was referred for endoscopic resection. The polyp had oozing with minimal contact and did not lift adequately with submucosal injection, hence hybrid ESD was performed (▶ **Fig. 1**). Defect closure was then successfully achieved using a combination of two DAT clips and one TTS endoclclip (▶ **Fig. 2**, ▶ **Video 1**).

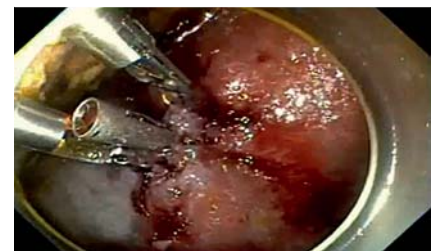One of the main advantages of the DAT device is the presence of two independent jaws which allow tissue approximation across larger defects, making defect closure more efficient. The device could also be a useful tool in scenarios where OTS clips or suturing devices cannot be advanced due to luminal stenosis or acute angulations in the colon. One device limitation is the inability to rotate the clips. Long-term data are needed regarding efficacy of closure, cost effectiveness, and follow-up information regarding the time frame the clip remains in place and



▶ **Video 1** Closure of a gastric endoscopic resection defect with a novel closure device.



▶ **Fig. 1** Mucosal defect after polyp resection with hybrid endoscopic submucosal dissection.



▶ **Fig. 2** Successful closure of defect using two novel clips and one through-the-scope endoclclip.

whether it has any impact on surveillance examinations after endoscopic resection.

Endoscopy_UCTN_Code_TTT_1AQ_2AJ

Competing interests

The authors declare that they have no conflict of interest.

The authors

Natalie Wilson¹ , Long B. Le², Mohamed Abdallah² , Mohammad Bilal³

- 1 University of Minnesota Medical Center, Department of Internal Medicine, Minneapolis, Minnesota, USA
- 2 University of Minnesota Medical Center, Division of Gastroenterology and Hepatology, Minneapolis, Minnesota, USA
- 3 Minneapolis Veterans Affairs Health Care System, Minneapolis, Minnesota, USA

Corresponding author

Mohammad Bilal, MD

Division of Gastroenterology and
Hepatology, Minneapolis VA Medical Center,
1 Veterans Drive, Minneapolis, MN 55417,
USA
billa17@hotmail.com

References

- [1] Osada T, Sakamoto N, Ritsuno H et al. Closure with clips to accelerate healing of mucosal defects caused by colorectal endoscopic submucosal dissection. *Surg Endosc* 2016; 30: 4438–4444
- [2] Kobara H, Tada N, Fujihara S et al. Clinical and technical outcomes of endoscopic closure of post-endoscopic submucosal dissection defects: a literature review over one decade. *Dig Endosc* 2022. doi:10.1111/den.14397
- [3] Lee BI, Kim BW, Kim HK et al. Routine mucosal closure with a detachable snare and clips after endoscopic submucosal dissec-

tion for gastric epithelial neoplasms: a randomized controlled trial. *Gut Liver* 2011; 5: 454

- [4] v. Kantsevov S. Closure methods and devices. *Tech Innov Gastrointest Endosc* 2019; 21: 33–37

Bibliography

Endoscopy 2023; 55: E181–E182

DOI 10.1055/a-1960-3151

ISSN 0013-726X

published online 11.11.2022

© 2022. The Author(s).

This is an open access article published by Thieme under the terms of the Creative Commons Attribution-NonDerivative-NonCommercial License, permitting copying and reproduction so long as the original work is given appropriate credit. Contents may not be used for commercial purposes, or adapted, remixed, transformed or built upon. (<https://creativecommons.org/licenses/by-nc-nd/4.0/>)

Georg Thieme Verlag KG, Rüdigerstraße 14,
70469 Stuttgart, Germany



ENDOSCOPY E-VIDEOS

<https://eref.thieme.de/e-videos>



Endoscopy E-Videos is an open access online section, reporting on interesting cases

and new techniques in gastroenterological endoscopy. All papers include a high quality video and all contributions are freely accessible online. Processing charges apply (currently EUR 375), discounts and waivers acc. to HINARI are available.

This section has its own submission website at

<https://mc.manuscriptcentral.com/e-videos>