

# Endoscopic resection of upper gastrointestinal lesions using the colonic Ovesco full-thickness resection device: Retrospective observational case series of 22 cases



## Authors

Jan-Erick Nilsson<sup>1</sup>, Wilmar de Graaf<sup>2</sup>, Arjun Dave Koch<sup>2</sup>

## Institutions

- 1 University of Alberta, Edmonton, Alberta, Canada
- 2 Erasmus MC, Rotterdam, South Holland, Netherlands

submitted 29.4.2022

accepted after revision 19.10.2022

published online 25.10.2022

## Bibliography

Endosc Int Open 2023; 11: E19–E23

DOI 10.1055/a-1967-2835

ISSN 2364-3722

© 2022. The Author(s).

This is an open access article published by Thieme under the terms of the Creative Commons Attribution-NonDerivative-NonCommercial License, permitting copying and reproduction so long as the original work is given appropriate credit. Contents may not be used for commercial purposes, or adapted, remixed, transformed or built upon. (<https://creativecommons.org/licenses/by-nc-nd/4.0/>)

Georg Thieme Verlag KG, Rüdigerstraße 14,  
70469 Stuttgart, Germany

## Corresponding author

Jan-Erick Nilsson, University of Alberta, 8440 112 St,  
Edmonton, Alberta, T6G 2B7, Canada  
Fax: +1-780-496-1387  
janerick@ualberta.ca

## ABSTRACT

**Background and study aims** The endoscopic full-thickness resection (EFTR) device (FTRD) has been shown to have acceptable outcomes in regard to efficacy and safety

in the resection of colorectal lesions. Data on its use in the upper gastrointestinal tract are limited to small case series. **Patients and methods** All consecutive patients undergoing endoscopic full-thickness resection of gastric or duodenal lesions at our institutions were analyzed retrospectively for a primary endpoint of technical success.

**Results** A total of 22 patients with duodenal and gastric lesions underwent EFTR between June 2018 and February 2022. Technical success was achieved in 20 of 22 (91%) of the procedures. Indications for EFTR were: subepithelial tumor (n=14), mucosal lesion (n=5), scar resection (n=2), and EFTR of endoscopic submucosal dissection (ESD) resection base (n=1). The FTRD could be advanced to the lesion in all 22 cases (100%). No dilation of the upper esophageal sphincter (UES) or pylorus was required to pass the device. There were 14 cases of gastric lesions and eight duodenal. One subepithelial lesion was too big for the cap and one scar could not be sucked into the cap. One lesion (gastrointestinal stromal tumor) was removed at second procedure with the ESD technique, including over-the-scope clip. The R0 resection rate for deployed clips was 90% (18 of 20). There were two superficial esophageal tears from FTRD insertion that required no therapy. No bleeding occurred during the postoperative period.

**Conclusions** Upper gastrointestinal EFTR using the colonic Ovesco FTRD is feasible without pre-dilation of the upper esophageal sphincter or pylorus. This study further confirms acceptable efficacy and safety in upper gastrointestinal use.

## Introduction

Management of subepithelial lesions and scarring with residual tissue after endoscopic resection has traditionally been problematic. The removal of subepithelial lesions is often required due to symptoms such as bleeding, or suspected malignancy such as in the case of neuroendocrine tumors (NETs). Surgical resection has traditionally been required for subepithelial lesions in both the stomach and duodenum. Submucosal dissec-

tion can be attempted but lesions involving the muscularis propria are usually not amenable to endoscopic submucosal dissection (ESD) techniques. Scarred tissue occasionally cannot be re-resected with endoscopic mucosal resection (EMR) even using a cap-and-snare technique.

Endoscopic full-thickness resection (EFTR) using the full-thickness resection device (FTRD, Ovesco Endoscopy AG, Tuebingen, Germany) has been well reported in the colon as both a safe and effective therapeutic option [1–4]. EFTR using the

FTRD is a promising technique for management of upper gastrointestinal lesions, and has been reported in small case series [5, 6]. Prior series have reported pre-dilation of both the upper esophageal sphincter (UES) and pylorus. We present a retrospective case series investigating the feasibility of advancement of the colonic FTRD without pre-dilation as well as efficacy of the FTRD in the stomach and duodenum.

## Patients and methods

### Study design and patient characteristics

Patients were referred after an initial esophagogastroduodenoscopy (EGD) for subsequent assessment of concerning mucosal/subepithelial lesions for consideration of resection. Informed consent was obtained for endoscopic resection, including EMR, ESD, and EFTR. Institutional Review Board approval was obtained. All lesions were reassessed by visual inspection at EGD for suitability of endoscopic removal via FTRD. Patients were selected for EFTR based on assessment by one of the three paper authors. If a lesion was felt to be removable by use of the FTRD, that was attempted first. Mucosal lesions were not biopsied to maintain a complete specimen/reduce submucosal fibrosis which could limit tissue inversion into the cap. Decision for resection of both mucosal and subepithelial lesions was based on visual inspection. If the lesion was felt to be too large or fibrotic for FTRD, the procedure was not attempted. Known benign pathology was only removed for lesion-related complications such as bleeding.

### FTRD and resection method

All EFTR cases were prospectively registered and information on them was collected in a database. All procedures were scheduled under sedation using propofol and remifentanyl. After initial endoscopic assessment of the target lesion, circumferential markings around the lesions were made using coagulation current with the high-frequency probe that accompanies the FTRD. The FTRD was mounted on a short Olympus colonoscope well lubricated with gel, without the protective sheath that accompanies the FTRD kit. With neck extension, the mounted FTRD was passed through the UES, and pylorus if necessary, without dilation. A combination of tissue grasper and suction was used to pull the lesions into the cap. Ideally after the entire visual field is obscured by lesion tissue the FTRD clip was deployed and the lesion immediately resected using pure cut current through the preloaded snare. All resected specimens were retrieved and pinned onto cork for pathologic analysis; resection size was estimated by pathology. Clip site was inspected post resection to assess for local complications from clip deployment or mucosal lacerations from the cap. Patients did not receive antibiotic prophylaxis.

### Outcome measurements and follow-up

The primary outcome in our series was the procedural technical success rate. This was defined as both reaching the target lesion with the mounted FTRD, and successful application of the FTRD clip to the target lesion with subsequent resection and retrieval. Secondary endpoints were success of passing the FTRD without

pre-dilation of the UES or pylorus, rate of esophageal tearing, en bloc and R0 resection rate. En bloc resection was determined by visual assessment of resected specimen at time of pinning to cork. Complete resection (R0) was determined by a clear histologic margin. Follow-up endoscopy was not routinely done, unless required for another indication. Resection size and tumor size was reported by the pathologist.

## Results

A total of 22 patients (8 female, 14 male) were scheduled for EFTR of an upper gastrointestinal lesion between June 2018 and February 2022. Mean patient age was 59 years (range 34–76). Procedural technical success was achieved in 20 of 22 cases (91%). All outpatients were discharged the same day after recovery and one inpatient was discharged on postoperative Day 2. Individual scope times were not recorded and all cases were completed within a 45-minute procedure booking time.

In all 22 cases, we were successful in advancing the FTRD to the target lesion. No pre-dilation of the UES or pylorus was required. Lesion location was gastric in 14 cases, and duodenal in eight. A wide variety of lesion etiology was encountered during our case series. The reasons for EFTR referral were: subepithelial tumor (n=14), mucosal lesion (n=5), scar resection (n=2), EFTR of recent ESD resection base (n=1). In two antral lesions we were unsuccessful in using the FTRD. One subepithelial tumor was too large to suck into the cap and the second lesion was a planned resection of an ESD scar that would not suck into the cap. Follow-up surgical excision of the subepithelial tumor revealed a 2.3-cm diameter ectopic pancreas. The clip was not deployed in either case, and the device removed without incident.

In the 20 cases with clip deployment, there was 100% technical success. We encountered no difficulty with use of the integrated snare in our cases. All of the resected specimens were histologically full-thickness, with muscularis propria and serosa. Pathology of resected cases was varied, with final diagnosis of: gastrointestinal stromal tumor (n=1), lipoma (n=2), leiomyoma (n=1) hamartoma (n=1), inflammatory fibroid polyp (n=1), neuroendocrine tumor (n=7), gastric adenocarcinoma (n=1), mucosal low-grade dysplasia (n=2), ectopic pancreas (n=1), scar (n=1), ESD base (muscularis propria) (n=1), and negative pathology (n=1). All of the lesion resections appeared en bloc endoscopically. Microscopically one neuroendocrine tumor had lateral margin positivity (R1). Tumor size was reported by pathology with a mean of 11.6 mm (range 6–19) (► **Table 1**).

In all cases, luminal integrity was confirmed by passing the endoscope to the third portion of the duodenum after clip deployment without difficulty. On endoscope withdrawal, two superficial esophageal mucosal tears (<5 mm) were seen that required no therapy (► **Fig. 1**). There was no post-procedure bleeding, and no perforations. One patient with a peri-ampullary hemorrhagic subepithelial tumor had ligation of the bile duct associated with clip deployment. Subsequent endoscopic retrograde cholangiopancreatography with precut access was successful in achieving biliary drainage. One patient had mild pancreatitis after duodenal clip placement (► **Table 2**).

► **Table 1** Resection location and pathology.

Lesion location	Success	Resection size (L×W×H) (cm)	Lesion size (mm) (pathology specimen)	Diagnosis
Antrum	Yes	2.2×1.5×1.6	11	GIST – R0
Antrum	No	NA	NA	SMT too large (2.4-cm ectopic pancreas on resection)
Antrum	Yes	3.5×2.0×1.0	15	Hamartoma
Antrum	Yes	3.4×2.5×0.2	11	Fibroid polyp
Antrum	No	NA	NA	ESD scar – Failed to suction
Antrum	Yes	1.5×1.4×0.7	10	ESD base – success
Antrum	Yes	2.9×2.1×1.1	20	Ectopic pancreas
Body	Yes	3.5×1.9×0.3	8	Lipoma – 4 <sup>th</sup> layer
Body	Yes	2.0×1.8×1.4	11	NET Type III – R1
Body	Yes	4.1×3.0×0.3	19	Leiomyoma
Body	Yes	2.6×2.2×0.9	15	pT1m2G1LVI adenocarcinoma – R0
Body	Yes	2.6×1.9×0.3	14	NET type I – R0
Body	Yes	2.5×2.5×0.3	22 @ ESD	No pathologic tissue
B1 anastomosis	Yes	1.4×1.2×0.6	12	Low-grade dysplasia
Duodenum	Yes	2.9×2.6×0.4	8	Gastrinoma – R0
Duodenum	Yes	1.5×1.4×0.4	10	ESD scar – success
Duodenum	Yes	1.9×1.5×1.3	19	NET – Grade 1 – R0
Duodenum	Yes	1.3×0.9×0.9	9	NET – Grade 1 – R0
Duodenum	Yes	3.2×2.1×0.2	13	Tubular adenoma (LGD)
Duodenum	Yes	2.5×1.8×1.0	6	Gastrinoma
Periampullary	Yes	2.5×1.0×0.5	25	Gastrinoma
Periampullary	Yes	2.5×1.3×1.1	11	Hemorrhagic Lipoma

GIST, gastrointestinal stromal tumor; ESD, endoscopic submucosal dissection; NET, neuroendocrine tumor; LGD, low-grade dysplasia

No patients required antibiotics before or after the procedure. Twenty-one of 22 patients were sent home the day of their procedure and did not require hospital admission in the post-procedure period. One patient was an inpatient admitted with life-threatening hemorrhage from duodenal NET was discharged on postoperative Day 2 (► **Fig. 2**).

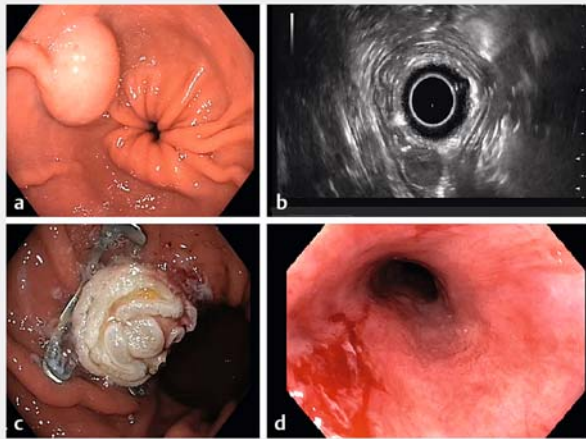
## Discussion

EFTR offers an opportunity for minimally invasive management of lesions previously quite difficult, or impossible to remove with EMR or ESD. This is especially apparent in the duodenum, where ESD has been shown to have unacceptably high rates of perforation, reported as high as 30% to 35% [7–9]. In high-volume ESD centers in Japan, duodenal ESD intraoperative perforation rates of 9.3% and delayed adverse event rates of 6.8% were reported [10]. ESD techniques are also hindered by submucosal fibrosis, or invasion into the muscularis propria, which can limit lesion resectability. This leaves a large gap in the man-

agement of duodenal and gastric subepithelial tumors, as well as superficial malignancies.

Literature from colonic EFTR supports its use in superficial cancers, subepithelial lesions, and difficult-to-remove polyps [3]. The safety and efficacy profile has been acceptable [1, 3, 6]. A recent prospective trial of 181 cases using the FTRD on colonic lesions revealed technical success in 89.5% and R0 resection rates of 76.9%. Complication rates in that study were considerably higher than our cohort at 9.9%, most notably with six perforations, one acute appendicitis, an enterocolonic fistula, and four episodes of bleeding [3]. The thicker gastric wall and retroperitoneal location of the duodenum likely reduce the risk of entrapment of other deeper structures as compared to the thin colonic wall. The risk of perforation with adequate clip deployment should be theoretically low, as resection with the preloaded snare is only above the deployed clip. Larger sample sizes are likely needed to make definitive statements in regard to safety in the upper gastrointestinal tract.

Another study of 20 retrospective duodenal EFTR cases using the same FTRD (Bauder et al.) revealed an overall techni-



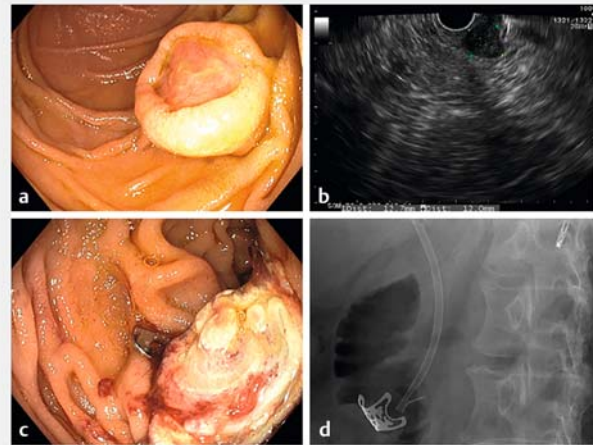
► **Fig. 1** a Antral GIST – endoscopic view. b EUS appearance. c Post-FTRD clip placement. d Small mucosal tear.

► **Table 2** Outcomes and complications.

Outcome	
▪ Lesion reached with FTRD without predilation	22/22 (100%)
▪ Technical success (reach lesion with FTRD and resect)	20/22 (91%)
▪ En bloc resection	20/20 (100%)
▪ Microscopic – R0 resection	18/20 (90%)
▪ Complete success rate (FTRD attempted and full thickness R0 resection)	18/22 (81.8%)
Adverse events	
▪ Superficial mucosal tear	2/22 (9%)
▪ Bleeding	0/22
▪ Perforation	0/22
▪ Papillary orifice ligation	1/22
▪ Pancreatitis	1/22
FTRD, full-thickness resection device.	

cal success of 85% and R0 resection rate of 63.2%. There was a large burden of non-lifting adenomas pretreated with EMR, which likely reduced their R0 resection rates. Significant fibrosis in the submucosa with adherence to the muscularis propria limits the ability of tissue to invaginate into the FTRD cap, especially if the diameter is close to the internal cap diameter of 13mm.

A recent study using the gastric FTRD by Meier et al. (RESET trial) reported en bloc resection rates 89.7% and histologic R0 resections of 76% in 29 gastric EFTRs [11]. Lesions larger than 15mm were excluded and an average tumor size of 11mm was reported. Despite use of a gastric FTRD, pre-dilation was used in 24% of cases.



► **Fig. 2** a Hemorrhagic duodenal NET – endoscopic appearance. b EUS appearance c Post-FTRD clip placement. No luminal obstruction present. d Radiograph of clip post-procedure. Prophylactic biliary stent in place.

Use of the colonic FTRD has the advantage of a larger internal cap diameter of 13mm, compared to the 12.1mm of the gastric FTRD, potentially allowing for larger resection specimens. A reduction in inner cap diameter by 1mm lowers maximum lesion volume by nearly 15% to 2.6cm [3]. The upper bounds of resectability of superficial mucosa lesions with EFTR using the colonic FTRD is likely between 35 and 40mm, although increased R1 resection rates are seen above 20mm [6, 12, 13]. In our cohort, the average tumor size reported by pathology was a mean of 12.9mm (range: 6–25mm, interquartile range 7mm). Our technical success rate of 91% (20/22) is in line with previous published experience. The R0 resection rate of 90% (18/20) in our series is likely a result of selection bias for smaller lesions that would be amenable to EFTR. Nonetheless, our findings reinforce that with appropriate patient selection, acceptable R0 resection rates can be expected.

A quoted limitation of the colonic FTRD is the wide diameter at the base (21mm), which can prevent passage through narrow lumens such as sigmoid strictures and the UES or the pylorus [6]. To overcome this limitation, Bauder et al. pre-dilated the sphincters with a balloon to facilitate passage. We managed to advance past the UES and pylorus without dilation, using the FTRD mounted on a short Olympus colonoscope. In order to pass the UES, it was required to position the FTRD in line with the axis of the UES and apply gentle constant pressure with minimal torque. The protective sheath was removed from the device in all cases and aids the passing of these sphincters. In all patients we were able to pass the sphincter without difficulty using this technique. Proceeding without pre-dilation potentially allows for shorter procedure times and less steps for upper EFTR using the FTRD. Given the care that is required to pass the current FTRD, we speculate that the outer diameter likely cannot exceed the current diameter (21mm) in order to pass these sphincters without the need for pre-dilation.

One of the major limitations of duodenal EFTR is clip placement along the medial wall of the second portion of the duodenum near the papilla. The one major complication in our case series was due to inadvertent capture of papillary tissue with subsequent biliary obstruction. The initial lesion (a hemorrhagic subepithelial tumor) was distal to the papilla by at least 10 mm. There was subsequent jaundice in the post-procedure period that required ERCP. A precut fistulotomy above the clip directly into the common bile duct was successful and there was no pancreatic obstruction. Our inadvertent capture of the papilla in this case underscores the extreme caution required for clip deployment along the medial duodenal wall. In subsequent peri-ampullary cases, elective CBD stent insertion pre-procedure was done for biliary protection. Our study is limited by its retrospective nature and relatively small sample size. Our low complication rate for advancement of the FTRD suggests that the device can be used without pre-dilation, although care must be taken for appropriate lesion choice and clip deployment.

## Conclusions

The over-the-scope FTRD is a novel and valuable tool to facilitate EFTR. The role of this technique for management of upper gastrointestinal subepithelial lesions is promising. From our experience with the current-generation colonic FTRD is that it can be advanced with minimal risk to the stomach or duodenum without the need for pre-dilation of the UES or pylorus.

## Competing interests

The authors declare that they have no conflict of interest.

## References

- [1] Schmidt A, Bauerfeind P, Gubler C et al. Endoscopic full-thickness resection in the colorectum with a novel over-the-scope device: First experience. *Endoscopy* 2015; 47: 719–725
- [2] Richter-Schrag H-J, Walker C, Thimme R et al. Full-thickness resection device (FTRD). *Der Chir* 2016; 87: 316–325
- [3] Schmidt A, Beyna T, Schumacher B et al. Colonoscopic full-thickness resection using an over-the-scope device: a prospective multicentre study in various indications. *Gut* 2018; 67: 1280–1289
- [4] Fährdrich M, Sandmann M. Endoscopic full-thickness resection for gastrointestinal lesions using the over-the-scope clip system: a case series. *Endoscopy* 2014; 47: 76–79
- [5] Schmidt A, Meier B, Cahyadi O et al. Duodenal endoscopic full-thickness resection (with video). *Gastrointest Endosc* 2015; 82: 728–733
- [6] Bauder M, Schmidt A, Caca K. Endoscopic full-thickness resection of duodenal lesions—a retrospective analysis of 20 FTRD cases. *United Eur Gastroenterol J* 2018; 6: 1015–1021
- [7] Jung J, Choi K, Ahn J et al. Endoscopic submucosal dissection for sessile, nonampullary duodenal adenomas. *Endoscopy* 2013; 45: 133–135
- [8] Honda T, Yamamoto H, Osawa H et al. Endoscopic submucosal dissection for superficial duodenal neoplasms. *Dig Endosc* 2009; 21: 270–274
- [9] Hoteya S, Yahagi N, Iizuka T et al. Endoscopic submucosal dissection for nonampullary large superficial adenocarcinoma/adenoma of the duodenum: feasibility and long-term outcomes. *Endosc Int Open* 2014; 1: 2–7
- [10] Kato M, Takeuchi Y, Hoteya S et al. Outcomes of endoscopic resection for superficial duodenal tumors: 10 years' experience in 18 Japanese high-volume centers. *Endoscopy* 2022; 54: 663–670
- [11] Meier B, Schmidt A, Glaser N et al. Endoscopic full-thickness resection of gastric subepithelial tumors with the gFTRD-system: a prospective pilot study (RESET trial). *Surg Endosc* 2020; 34: 853–860
- [12] von Renteln D, Kratt T, Rösch T et al. Endoscopic full-thickness resection in the colon by using a clip-and-cut technique: an animal study. *Gastrointest Endosc* 2011; 74: 1108–1114
- [13] Schurr MO, Baur F, Ho CN et al. Endoluminal full-thickness resection of GI lesions: A new device and technique. *Minim Invasive Ther Allied Technol* 2011; 20: 189–192