



# Subungual Osteochondromas of the Toe: Two Case Reports for Diagnosis and Treatment

Myung Chul Lee, MD, PhD<sup>1</sup> Chan Eol Seo, MD<sup>1</sup> Wook Youn Kim, MD, PhD<sup>2</sup>  
Wan Seop Kim, MD, PhD<sup>2</sup> Jeenam Kim, MD, PhD<sup>1</sup> Donghyeok Shin, MD, PhD<sup>1</sup>  
Hyungon Choi, MD, PhD<sup>1</sup>

<sup>1</sup> Department of Plastic and Reconstructive Surgery, Konkuk University School of Medicine, Seoul, South Korea

<sup>2</sup> Department of Pathology, Konkuk University School of Medicine, Seoul, South Korea

Address for correspondence Hyungon Choi, MD, PhD, Department of Plastic and Reconstructive Surgery, Konkuk University School of Medicine, 120-1 Neungdong-ro, Gwangjin-gu, Seoul 05030, South Korea (e-mail: 20040059@kuh.ac.kr).

Arch Plast Surg 2023;50:101–105.

## Abstract

Benign cartilaginous tumors, known as chondrogenic tumors, show cartilage components in the microscopic diagnosis. We present two clinical cases with cartilaginous tumors of the toes showing distinctive clinical manifestations. Two juvenile patients visited our outpatient clinic due to tumors with toenail deformities. A 10-year-old girl presented with a palpable mass with a nail deformity on the left third toe. The initial pathology report was soft tissue chondroma until complete resection. Another 15-year-old male patient visited the dermatology department with a toenail deformity and underwent a punch biopsy. The pathology report was fibrosis with myxoid degeneration. Excisional biopsies were performed for both patients. In the operative field, we observed exophytic tumors connected to the distal phalangeal bones. The final pathology reports were subungual osteochondroma on both patients. The specimen exhibited mature bone trabeculae with a focal cartilaginous cap. Benign cartilaginous tumors have a slow, progressive course and do not show significant symptoms. However, tumors in subungual areas are accompanied by toenail deformities and they can cause pain. Their clinical characteristics lead to a delayed diagnosis. Surgeons can be confused between soft tissue and chondrogenic tumors. When they conduct physical examinations, these categories should be considered in the differential diagnosis.

## Keywords

- ▶ osteochondroma
- ▶ toe

## Introduction

Benign cartilaginous tumors, known as chondrogenic tumors, show cartilage components in the microscopic diagnosis and can be subdivided by their origins. Enchondroma and osteochondroma arise in bone, and soft tissue chondroma develops in soft tissue. Periosteal chondroma occurs from the surface of the cortex beneath the periosteum.<sup>1</sup> A

tumor of cartilaginous origin with myxoid and fibrous components is called chondromyxoid fibroma.<sup>2</sup>

Our two cases describe cartilaginous tumors with similar clinical manifestations and exhibited histologically distinctive characteristics in the diagnostic process. They were subungual masses located at the distal extremities. The morphology of tumors was accompanied by toenail

received

October 2, 2022

accepted

November 14, 2022

accepted manuscript online

November 23, 2022

DOI <https://doi.org/10.1055/a-1985-1324>.

10.1055/a-1985-1324.

eISSN 2234-6171.

© 2023. The Korean Society of Plastic and Reconstructive Surgeons. All rights reserved.

This is an open access article published by Thieme under the terms of the Creative Commons Attribution-NonDerivative-NonCommercial-License, permitting copying and reproduction so long as the original work is given appropriate credit. Contents may not be used for commercial purposes, or adapted, remixed, transformed or built upon. (<https://creativecommons.org/licenses/by-nc-nd/4.0/>)

Thieme Medical Publishers, Inc., 333 Seventh Avenue, 18th Floor, New York, NY 10001, USA

deformities, resulting in delayed diagnosis regardless of the subtype. Our patients do not show the final diagnosis of a rare entity. Nonetheless, the diagnostic and treatment processes provide useful information for managing comparable patients. The study was approved by the Institutional Review Board of our institute (IRB No. 2022-08-039), and performed in accordance with the principles of the Declaration of Helsinki. Written informed consent was obtained from the patients.

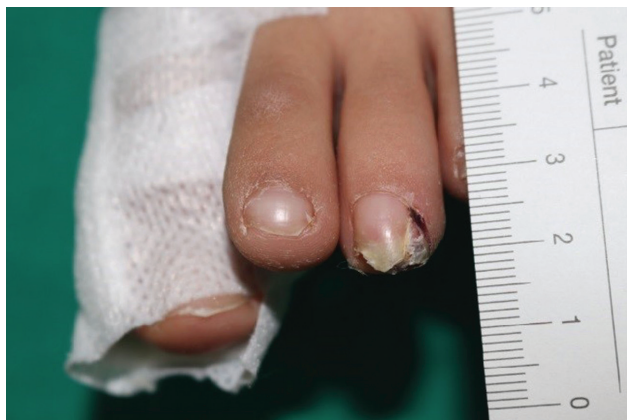
## Cases

### Case 1: Osteochondroma on the left 3rd toe

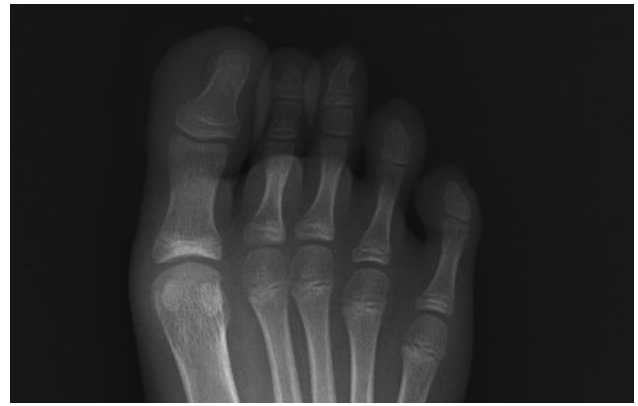A 10-year-old female patient visited a primary outpatient clinic with a nail deformity on the left third toe. Her nail deformity was initially considered as a simple nail distortion caused by excessive pressure from the shoes. After 7 months, her nail deformity became worse with severe pain and a protruding mass was noted under the edge of toenail (▶Fig. 1). The dermatology clinic carried out a punch biopsy, and the initial pathology report was subungual soft tissue chondroma.

On a physical examination, the tumor was not defined prominently since it was covered with a hyperkeratinized toenail. An anteroposterior X-ray of the toe revealed an exostotic mass of the distal phalanx suspicious for a primary bone tumor (▶Fig. 2). The preliminary diagnosis of soft tissue chondroma was made and definitive treatment with surgical excision was planned. In the operative field, we could observe a 0.5-cm well-demarcated granulating round mass after extracting the deformed toenail (▶Fig. 3). The cartilaginous tumor was located on the lateral dorsal aspect of the distal phalanx connected to the periosteum. The round mass was removed cautiously using an osteotome, and the open wound on the nailbed was repaired with absorbable sutures. We covered the nailbed using a synthetic nail and applied anchoring sutures. In postoperative X-ray, the exostotic lesion was removed appropriately, showing a natural contour on the distal phalanx.

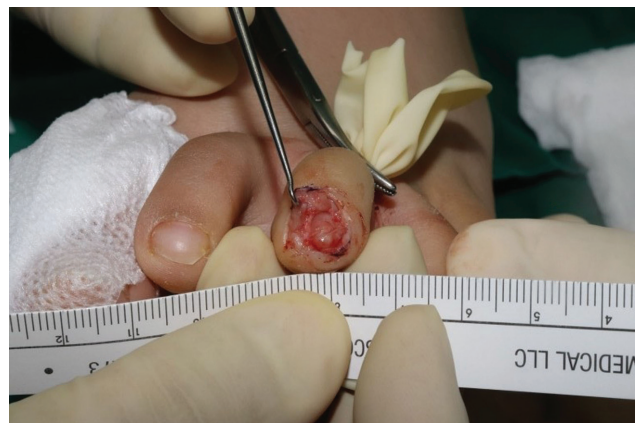The final pathology report after surgery confirmed subungual osteochondroma that showed a cartilaginous cap



**Fig. 1** Preoperative clinical photograph of the 10-year-old female patient. A nail deformity was noted on the left third toe.

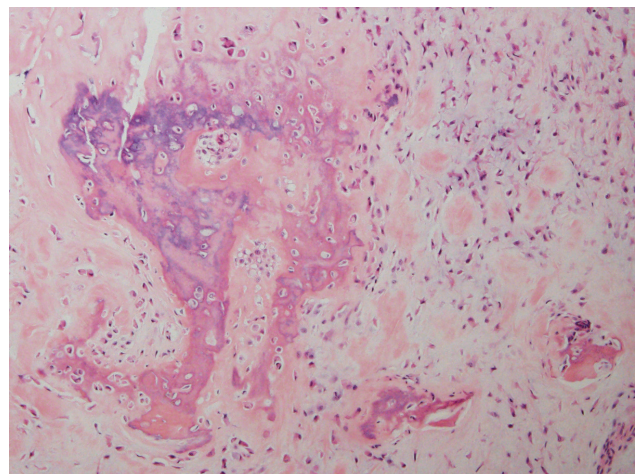


**Fig. 2** Preoperative anteroposterior view X-ray image. An exophytic lesion was noted on the left third toe.

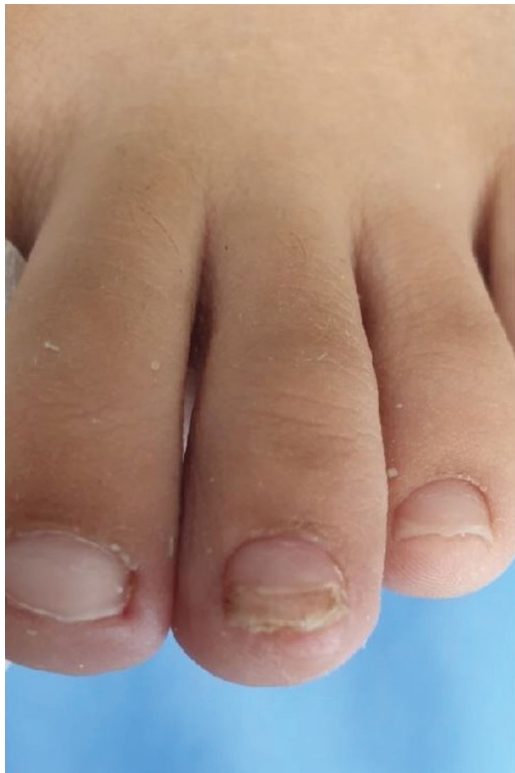

**Fig. 3** Intraoperative clinical photograph including the surgical specimen.

composed of mature hyaline cartilage and fragments of bone trabeculae with endochondral ossification (▶Fig. 4). The initial pathology report was subungual soft tissue chondroma showing a lobular architecture with islands of hyaline



**Fig. 4** Histopathological findings of subungual osteochondroma. The lesion showed a cartilaginous cap composed of mature hyaline cartilage and fragments of bone trabeculae with endochondral ossification. The chondrocytes were observed within mature hyaline cartilage (hematoxylin–eosin stain, original magnification  $\times 200$ ).



**Fig. 5** Postoperative clinical photograph at the 3-month follow-up visit.

cartilage. An additional excisional biopsy including cartilage and bony components changed the final diagnosis.

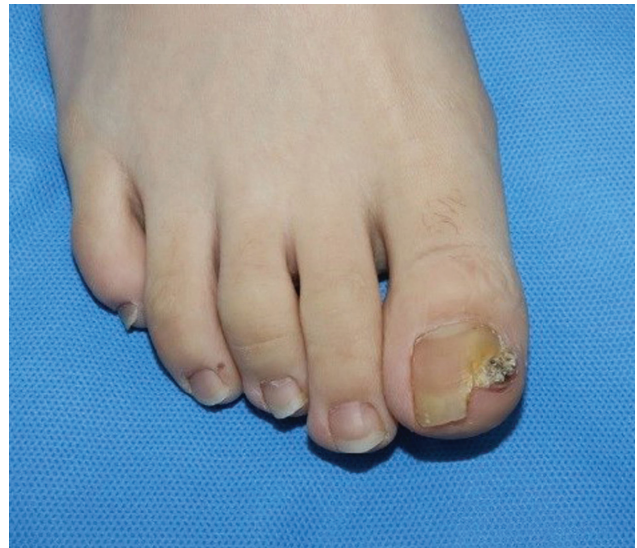After 3 weeks, we released the anchor of the artificial toenail. The patient returned for a regular follow-up visit 4 months after surgery without tumor recurrence, showing an intact toenail (►Fig. 5).

### Case 2: Osteochondroma on the right great toe

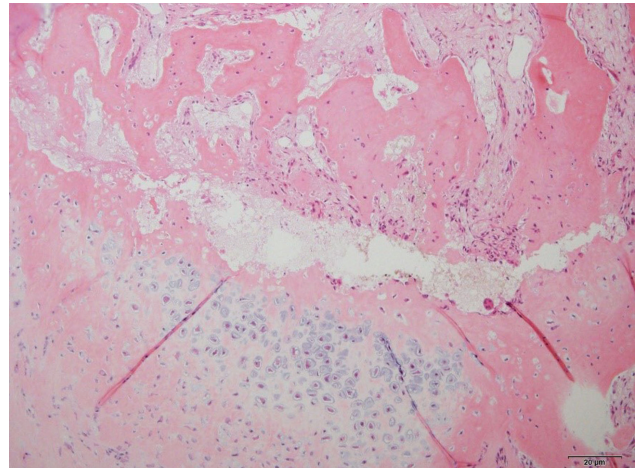
A 15-year-old male patient visited the dermatology department of our hospital with a toenail deformity on the great toe that had appeared 1 year ago. At the initial primary clinic, the deformity was diagnosed as an ingrown nail. About 6 months later, his nail deformity progressed, showing mass formation under the toenail (►Fig. 6).

After partially cutting off the nail, a punch biopsy was performed at the dermatology department. The initial pathology report was fibrosis with myxoid degeneration. He was transferred to the department of plastic and reconstructive surgery for curative excision. Based on the pathology report, various tumorous conditions were considered, including superficial acral fibromyxoma.<sup>3</sup> We planned definitive treatment with surgical excision. In the operative field, a 1.5-cm exophytic tumor was noted, and located on the medial dorsal aspect of the distal phalanx. The tumor was unexpectedly connected to the bone tissue. After complete excision, the distal phalangeal bone was exposed. Then, we placed an acellular dermal matrix (CGPaste; CGBio, Seongnam-Si, Gyeonggi-Do, Korea) to restore the open wound.

The final pathology report from surgery was changed to subungual osteochondroma without a fibromyxomatous



**Fig. 6** Preoperative clinical photograph of the 15-year-old male patient. A nail deformity was noted on the great toe of the right foot.

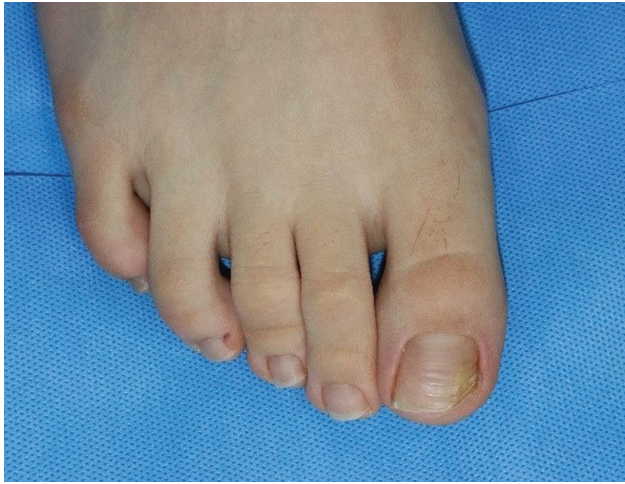

**Fig. 7** Histologic findings showed an osteochondroma. The pathologic lesion is composed of a cartilage cap and mature bony trabeculae (hematoxylin–eosin stain, original magnification  $\times 100$ ).

area. The specimen had mature bone trabeculae with a focal cartilaginous cap and fibrous tissue, consistent with subungual osteochondroma (►Fig. 7). The nail bed underwent epithelization throughout 4 weeks postoperatively, and an additional skin graft was not necessary to replace the excised sterile matrix. The healing process assisted adequate nail growth, and intact perionychium was observed at the 6-month postoperative follow-up (►Fig. 8).

### Discussion

Tumors covered with a hyperkeratinized nail deformity can be confusing or lead to a delayed diagnosis, as noted in our cases. The leading cause of delay was the invisible subungual mass combined with a nail deformity at the initial visit.<sup>4</sup> It can be considered as a traumatic lesion or an ingrown nail until the deformity deteriorates with a definitive mass presentation or severe pain.



**Fig. 8** Postoperative clinical photograph at the 6-month follow-up visit.

Both cases had common clinical courses in several aspects. First, they had been misdiagnosed as nail dystrophy. The delayed diagnosis was made after the problem was not solved for several months. Cartilaginous tumors with nail deformity have been reported occasionally, and can easily be misdiagnosed by clinical examination alone with a lack of suspicion. Surgeons should consider various chondrogenic or osteogenic tumors, such as periosteal chondroma, soft tissue chondroma, osteochondroma, and chondromyxoid fibroma.<sup>5,6</sup> Our clinical report included two teenage patients. If patients are middle-aged or senior, we should consider not only benign cartilaginous tumors but also achromic melanoma, malignant melanoma, cutaneous metastasis of squamous cell carcinoma, or osteosarcoma.<sup>7-10</sup>

In the first patient, the initial pathology report was soft tissue chondroma until complete resection. The patient underwent a punch biopsy, and was transferred to our department for further evaluation. The exostotic characteristic could not be exhibited at the initial stage. Subungual soft tissue chondroma with nail deformity is not common, and has been described in previous case reports. Eun et al demonstrated a juvenile patient with a soft tissue chondroma on the left fifth finger. The lesion involved the nail lunula adjacent to the germinal matrix.<sup>11</sup> Connolly et al also presented a middle-aged man showing protrusion and redness of the lunula on the left middle finger.<sup>12</sup> Diagnosed as soft tissue chondroma, the tumor consisted of a cartilage component without connection to the skeletal tissues. These tumors are usually asymptomatic and their slow growth leads to difficulties in an early diagnosis. In case of the second patient, the initial pathology report was fibrosis with myxoid degeneration. To diagnose osteochondroma, bony trabeculae and cartilaginous cap should be confirmed in microscopic observation. It is hard to harvest the two components thoroughly with a punch biopsy. A broad consideration is necessary for accurate diagnosis based on multiple modalities.

With regard to subungual osteochondroma, the definite etiology is uncertain. A congenital origin has been suggested,

in which a small lesion during infancy gradually evolves into a prominent mass during puberty, undergoing accelerated growth with endochondral ossification.<sup>13</sup> Other causes, such as microtrauma resulting in reactive metaplasia, chronic irritation, and a hereditary abnormality are possible reasons.<sup>6,14</sup>

The key message of our cases is that we should consider the possibility of soft tissue or cartilaginous tumors if a patient presents with subungual mass. Benign soft tissue tumors, such as mucoid cyst and glomus tumor, are also common at the perionychium. In order to confirm tumor size and primary location, an imaging study such as plain radiography can be implemented first in the majority of cases. Baek et al suggested a clinicopathological correlation with various imaging studies.<sup>15</sup> Ultrasonography and magnetic resonance images provide complementary information, helping to avoid a misdiagnosis. Various characteristics including tumor size, shape, location, and vascularity can be valuable data at the preoperative stage.<sup>16</sup>

Benign cartilaginous tumors mostly have a slowly progressive course and do not show significant symptoms. However, they are occasionally located in the subungual area and are accompanied by toenail deformities. A delayed diagnosis due to the clinical course leads to patients' prolonged pain, although the treatment is curative excision. When a surgeon comes across these clinical signs at the outpatient clinic, they should consider the category of cartilaginous tumors in their differential diagnosis.

#### Authors' Contributions

M.C.L and C.E.S conceptualized the study. W.Y.K. and W.S. K. were involved in data curation. C.E.S. contributed to the investigation. J.K. and D.S. supervised the study. M.C.L. and C.E.S. were involved in writing – the original draft. H.C. contributed to writing – review and editing.

#### Ethical Approval

The study was approved by the Institutional Review Board of Konkuk University Hospital (IRB No. KUH 2022-08-039) and performed in accordance with the principles of the Declaration of Helsinki. Written informed consent was obtained from the patient.

#### Patient Consent

Patients provided written informed consent for the publication and the use of their images.

#### Financial Disclosure

None of the authors has a financial interest in any of the products, devices, or drugs mentioned in this manuscript.

#### Conflict of Interest

D.S. is an editorial board member of the journal but was not involved in the peer reviewer selection, evaluation, or decision process of this article. No other potential conflicts of interest relevant to this article were reported.

## References

- 1 Hunter AM, Farnell C, Doyle JS. Extraskeletal osteochondroma of the great toe in a teenager. *J Foot Ankle Surg* 2019;58(04):807–810
- 2 Vasudeva N, Shyam Kumar C, Ayyappa Naidu CR. Chondromyxoid fibroma of distal phalanx of the great toe: a rare clinical entity. *Cureus* 2020;12(02):e7133
- 3 Sundaramurthy N, Parthasarathy J, Mahipathy SR, Durairaj AR. Superficial acral fibromyxoma: a rare entity - a case report. *J Clin Diagn Res* 2016;10(09):PD03–PD05
- 4 Rodriguez LE, Rodriguez JE, Delgadillo L, et al. Delayed diagnosis of subungual osteochondroma. *J Pediatr Surg Case Rep* 2018;36:1–2
- 5 Schnirring-Judge M, Visser J. Resection and reconstruction of an osteochondroma of the hallux: a review of benign bone tumors and a description of an unusual case. *J Foot Ankle Surg* 2009;48(04):495–505
- 6 Lee SK, Jung MS, Lee YH, Gong HS, Kim JK, Baek GH. Two distinctive subungual pathologies: subungual exostosis and subungual osteochondroma. *Foot Ankle Int* 2007;28(05):595–601
- 7 Nam KW, Bae YC, Nam SB, Kim JH, Kim HS, Choi YJ. Characteristics and treatment of cutaneous melanoma of the foot. *Arch Plast Surg* 2016;43(01):59–65
- 8 Yamashita Y, Hashimoto I, Abe Y, et al. Effect of biopsy technique on the survival rate of malignant melanoma patients. *Arch Plast Surg* 2014;41(02):122–125
- 9 Bae YC, Jeong DK, Kim KH, et al. Adequacy of sentinel lymph node biopsy in malignant melanoma of the trunk and extremities: clinical observations regarding prognosis. *Arch Plast Surg* 2020;47(01):42–48
- 10 Mardanpour K, Rahbar M. Subcutaneous extraskeletal osteosarcoma of foot: a case report. *Int J Surg Case Rep* 2020;75:403–407
- 11 Eun YS, Kim MR, Cho BK, Yoo G, Park HJ. Subungual soft tissue chondroma with nail deformity in a child. *Pediatr Dermatol* 2015;32(01):132–134
- 12 Connolly M, Intzedy L, Collins C, de Berker DA. Lateral views and subungual soft-tissue chondromas. *J Am Acad Dermatol* 2008;58(suppl 2):S58–S59
- 13 Ricardo JW, Chikeka I, Umans H, Lipner SR. Subungual osteochondroma in a pediatric patient. *Dermatol Surg* 2021;47(06):886–887
- 14 Tiwari A, Agrawal N, Verma T, Lal H. Subungual osteochondroma: nail sparing excision. *J Clin Orthop Trauma* 2016;7(Suppl 1):72–75
- 15 Baek HJ, Lee SJ, Cho KH, et al. Subungual tumors: clinicopathologic correlation with US and MR imaging findings. *Radiographics* 2010;30(06):1621–1636
- 16 Negenborn VL, Moerman E, Ham SJ. Autologous fat grafting as a last resort for unsustainable pain in a woman with multiple osteochondromas. *Arch Plast Surg* 2017;44(02):162–165