

Endoscopic vacuum-assisted closure therapy for leakage of the lower gastrointestinal tract: multicenter experiences



Authors

Thorsten Book^{*1}, Carsten Engelke^{*2}, Raphael Brüggerhoff³, Markus Winny⁴, Martin Kraus², Claudia Benecke⁵, Markus Zimmermann⁵, Ulf Trostorf⁶, Heiner Wedemeyer¹, Jens U. Marquardt², Torsten Voigtländer¹, Jochen Wedemeyer^{*3}, Martha M. Kirstein^{*2}

Institutions

- 1 Department of Gastroenterology, Hepatology and Endocrinology, Hannover Medical School, Hannover, Germany
- 2 1st Department of Medicine, University Medical Center Schleswig-Holstein, Campus Luebeck, Luebeck, Germany
- 3 Department of Internal Medicine, Robert Koch Hospital Gehrden, Gehrden, Germany
- 4 Department of General, Visceral and Transplantation Surgery, Hannover Medical School, Hannover, Germany
- 5 Department of Surgery, University Medical Center Schleswig-Holstein, Campus Luebeck, Luebeck, Germany
- 6 Clinic for General, Visceral, and Vascular Surgery, Robert Koch Hospital Gehrden, Gehrden, Germany

submitted 16.2.2022

accepted after revision 29.9.2022

Bibliography

Endosc Int Open 2023; 11: E212–E217

DOI 10.1055/a-1990-0392

ISSN 2364-3722

© 2023. The Author(s).

This is an open access article published by Thieme under the terms of the Creative Commons Attribution-NonDerivative-NonCommercial License, permitting copying and reproduction so long as the original work is given appropriate credit. Contents may not be used for commercial purposes, or adapted, remixed, transformed or built upon. (<https://creativecommons.org/licenses/by-nc-nd/4.0/>)

Georg Thieme Verlag KG, Rüdigerstraße 14,
70469 Stuttgart, Germany

Corresponding author

Prof. Dr. med. Martha Kirstein, 1st Department of Medicine, University Medical Center Schleswig-Holstein, Campus Luebeck, Ratzeburger Allee 160, 23538 Lübeck, Germany
Phone: +4945150044147
martha.kirstein@uksh.de

ABSTRACT

Background and study aims Only a few studies are available regarding endoscopic vacuum-assisted closure (E-VAC) therapy for the post-surgery leakage of the lower gastrointestinal tract.

Patients and methods In this multicenter German study, we retrospectively analyzed patients treated with E-VAC therapy due to post-surgery leakage of the lower gastrointestinal tract from 2000–2020 at Hannover Medical School, University Medical Center Schleswig-Holstein, Campus Luebeck, and Robert Koch Hospital Gehrden.

Results Overall, 147 patients were included in this study. Most patients had undergone tumor resections of the lower gastrointestinal tract ($n=88$; 59.9%). Median time to diagnosis of leakage was 10 days (interquartile range [IQR] 6–19). Median duration of E-VAC therapy was 14 days (IQR 8–27). Increase of C-reactive protein (CRP) levels significantly correlated with first diagnosis of leakage ($P<0.001$). E-VAC therapy led to closure or complete epithelialization of leakage in the majority of patients ($n=122$; 83.0%) and stoma reversal was achieved in 60.0%. Stoma reversal was significantly more often achieved in patients with CRP levels ≤ 100 mg/L at first diagnosis compared to patients with CRP levels > 100 mg/L (78.4% vs. 52.7%; $P=0.012$). Odds ratio for failure of stoma reversal was 3.36 in cases with CRP values > 100 mg/L ($P=0.017$). In total, leakage- and/ or E-VAC therapy-associated complications occurred in 26 patients (17.7%). Minor complications included recurrent E-VAC dislocations and subsequent stenosis. Overall, 14 leakage- or E-VAC-associated deaths were observed most often due to sepsis.

Conclusions E-VAC therapy due to post-surgery leakage of the lower gastrointestinal tract is safe and effective. High levels of CRP are a negative predictor of E-VAC therapy success.

* These authors contributed equally.

Introduction

Anastomotic leakage following colorectal surgery is a serious complication and associated with early and long-term morbidity and mortality [1, 2]. Anastomotic leakage occur in up to 30% of patients after colorectal surgery requiring surgical or endoscopic treatment [2]. Endoscopic vacuum-assisted closure (E-VAC) has proven to be a well-tolerated and effective therapeutic option for the treatment of major leaks after rectal anastomoses in small retrospective cohorts [3–5].

A recent review delineated that treatment success of E-VAC for anastomotic leakage varies from 60% to 100% but these results have to be interpreted with caution due to variable definition of treatment success in the different studies [6]. These considerations prompted us to analyze patients from three referral centers undergoing E-VAC regarding indication, treatment success and complications of this procedure within a large, real-life cohort.

Patients and methods

Patient population and data selection

Medical and endoscopic records were retrospectively screened for patients treated with E-VAC for the lower gastrointestinal tract between 2000 and 2020 at three German institutions (Hannover Medical School, Hannover, University Medical Center Schleswig-Holstein, Campus Luebeck, and Robert Koch Hospital, Gehrden). Patients who were treated with E-VAC due to post-surgery leakage that had become apparent within the first-year post-surgery were included. Patient data were retrospectively evaluated for baseline and laboratory characteristics and type and purpose of surgery. The study protocol conformed to the ethical guidelines of the 1975 Declaration of Helsinki as reflected in a priori approval by the appropriate institutional review committees.

Endoscopic procedures

Placement and removal of the E-VAC system was performed as following: A polyurethane foam sponge (pore size 400–600 µm; KCI, Wiesbaden Germany, Smith & Nephew, Hamburg, Germany) was adapted to the particular wound size as estimated by the endoscopist. The sponge size was required to be smaller than the wound cavity to promote collapse and subsequent closure of the fistula. The sponge was fixed to the tip of a duodenal tube with a mersilene suture (Freka Tube, 15 Ch; Fresenius Kabi, Bad Homburg, Germany; 0.35 mm; Johnson & Johnson, St-Stevens-Woluwe, Belgium). The sponge was grasped with grasping forceps (Olympus, Hamburg, Germany; Boston Scientific, Marlborough, Massachusetts, United States) and introduced either into the necrotic cavity or in the colonic lumen under vision using a regular orthograde endoscope (Gif-Q165, Gif-Q180H, Gif-Q190; Olympus). Continuous or intermittent suction of 50 to 100 mm Hg was applied using a vacuum pump (KCI, Smith & Nephew). For sponge removal the suction was discontinued and the tube was grasped with grasping forceps close to the distal end pulled out of the wound cavity. The sponge was exchanged approximately twice a week until the base of the cav-

ity appeared to be firmly closed or the cavity was completely epithelialized/granulated. All procedures were performed by or in the presence of an experienced endoscopist (>200 colonoscopies/year).

Laboratory analysis

Where obtainable, C-reactive-protein (CRP) and a complete blood count were evaluated before surgery, upon detection of the leakage and after completion of E-VAC therapy.

Statistical analysis

Statistical analyses were performed using SPSS 26.0 (SPSS Inc., Chicago, Illinois, United States). Continuous variables were represented as medians and interquartile ranges (IQRs). Differences between categorical variables were calculated using Pearson's Chi-squared test. Medians were compared using the Wilcoxon signed-rank test. $P < 0.05$ was considered significant. Overall survival (OS) was assessed using the Kaplan-Meier estimation. Binary logistic regression was performed to assess correlation of plausible risk factors toward failure of stoma relocation. Risk subgroups were defined as follows: elevated CRP above 100 mg/dL at time of leakage diagnosis, prior neoadjuvant therapy and age above median (66 years).

Results

Demographics

Overall, 147 patients treated with E-VAC for post-surgery leakage of the lower gastrointestinal tract between 2000 and 2020 were included in this study (Robert Koch Hospital, Gehrden: $n = 69$; University Medical Center Schleswig-Holstein, Campus Luebeck: $n = 68$; Hannover Medical School: $n = 10$). Majority of patients were male ($n = 99/147$; 67.3%), of advanced age (median 66 years [55–74]) and underwent tumor resections of the lower gastrointestinal tract before ($n = 88/147$; 59.9%). All of these patients presented with either adenocarcinoma of the rectum or the sigmoid. One patient was diagnosed with synchronous adenocarcinoma of the sigmoid and adenocarcinoma of the right colonic flexure. Among the patients with adenocarcinomas of the rectum, 23 of 88 patients (26.1%) received neoadjuvant therapy with combined radiochemotherapy in most cases ($n = 18/23$; 78.3%). Other indications for surgery included complicated diverticulitis ($n = 23/147$; 15.6%), re-anastomosis ($n = 11/147$; 7.5%), inflammatory bowel diseases ($n = 8/147$; 5.4%), among others. Deep anterior rectum resection was the most common surgery ($n = 71/147$; 48.3%) followed by resection of the sigmoid and Hartmann's operation ($n = 23/147$; 15.6%). Discontinuity resection including permanent stoma was performed in 32/147 (21.8%) patients. Among the patients with continuity resection ($n = 115/147$; 78.2%), 78/147 patients (53.1%) received a temporary, diverting stoma. In total, therefore, 110 of 147 patients (74.8%) received primarily an enterostoma. Further 17 of 147 patients (11.6%) received a temporary, secondary stoma after first diagnosis of leakage (further referred to as rescue stoma). In the remaining 20 of 147 patients (13.6%) without stoma, E-VAC therapy was performed during

► **Table 1** Demographics of total population.

Factor		n/total (%)
Total		147/147 (100)
Hospital	Gehrden	69/147 (46.9)
	Hannover	10/147 (6.8)
	Luebeck	68/147 (46.3)
Gender	Male	99/147 (67.3)
	Female	48/147 (32.7)
Median age (yr)		66 [55–74]
Purpose of surgery	Malignancy	88/147 (59.9)
	Diverticulitis	23/147 (15.6)
	Re-anastomosis	11/147 (7.5)
	Colitis ulcerosa	5/147 (3.4)
	Crohn's disease	3/147 (2.0)
	Perforation	3/147 (2.0)
	Adenoma	2/147 (1.4)
	Ileus	2/147 (1.4)
	Stenosis	2/147 (1.4)
	Other ¹	8/147 (4.8)
Neoadjuvant therapy (in case of malignancy)	Any	23/88 (26.1)
	▪ CTX	4/23 (17.4)
	▪ RCTX	18/23 (78.3)
	▪ RTX	1/23 (4.3)
	None	65/88 (73.9)
Surgery	Discontinuity	32/147 (21.8)
	Continuity	115/147 (78.2)
	▪ Rectum resection	71/147 (48.3)
	▪ Sigma resection	23/147 (15.6)
	▪ Other ²	53/147 (36.1)
Stoma	Primary	110/147 (74.8)
	▪ Temporary	78/110 (70.9)
	▪ Ileostoma	45/78 (57.7)
	▪ Colostoma	33/78 (42.3)
	▪ Permanent	32/110 (29.1)
	▪ Ileostoma	4/32 (12.5)
	▪ Colostoma	28/32 (87.5)
	Secondary (rescue)	17/147 (11.6)
	▪ Ileostoma	13/17 (76.5)
	▪ Colostoma	4/17 (23.5)
	None	20/147 (13.6)

CTX, chemotherapy; RCTX, radiochemotherapy; RTX, radiotherapy.

¹ Including adhesiolysis, abscess, ischemia.

² Including hemicolecotomy, proctoclectomy, re-anastomosis, rectum extirpation.

parenteral nutrition as the patients had contraindications for re-surgery such as co- or multi-morbidities.

Demographics are summarized in ► **Table 1**.

Endoscopic procedures

Median time to diagnosis of leakage after initial surgery was 10 days (IQR 6–19). In all patients, leakage became clinically apparent with fever, pain and/ or increase of laboratory inflammation parameters. Diagnosis of leakage had been confirmed with flexible endoscopy of the lower gastrointestinal tract as described above. In most cases, E-VAC therapy was performed at the same time in sedation in the endoscopy unit. Application of the E-VAC-system was successful in all patients. Median time of E-VAC changes was 4 days (IQR 2–6). Duration of E-VAC therapy was median 14 days (IQR 8–27). Median time of hospitalization after first diagnosis of leakage was 31 days (IQR 20–48). Median time of intensive care treatment was very short with 1 day (IQR (1–4,5)).

Laboratory values

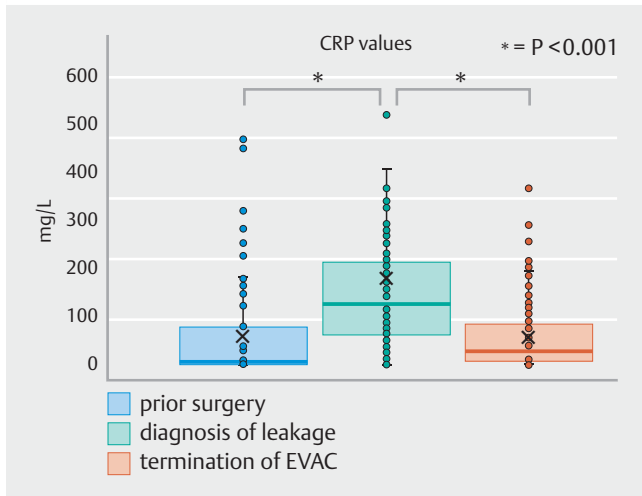
Dynamics of white blood cell count (WBC) and CRP was significantly associated with leakage dynamics. CRP levels significantly increased at first diagnosis of leakage with 127.2 mg/L (IQR 64.8–210.4) compared to 7.9 mg/L (IQR 3.3–76.5) before surgery ($P < 0.001$, ► **Fig. 1**). At termination of E-VAC therapy, CRP levels significantly decreased again (66.5 mg/L [IQR 18.3–131.8]); $P < 0.001$). Accordingly, WBC count significantly decreased from 10.7 thsd/ μ L (IQR 7.9–14.4) to 7.7 thsd/ μ L (IQR 6–9.9) ($P < 0.001$). In contrast, levels of hemoglobin and platelets did not change significantly.

Safety

In total, leakage- and/ or E-VAC therapy-associated complications occurred in 26 of 147 patients (17.7%) (► **Table 2**). Minor complications mainly included recurrent E-VAC dislocations ($n = 4$) and the development of subsequent stenosis, which required treatment with dilatations in the further course ($n = 3$). Bleeding complications occurred in two patients and could be managed by endoscopic intervention. Each one patient developed a fistula, a small perforation of the small intestine, and a pneumoperitoneum, which all could be treated conservatively. Overall, 14 of 147 deaths (9.5%) occurred in the E-VAC-treated patients due to sepsis in seven patients, colonic ischemia and necrosis in three patients and due to cardiopulmonary events and bleeding complications in another four patients.

Efficacy and outcome

The 1-year survival rate was 94%, whereas median overall survival (mOS) was 12 years. In most patients ($n = 122/147$; 83.0%) E-VAC therapy led to closure or complete epithelialization of the leakage (► **Fig. 2**). In 25 patients (17.0%) E-VAC therapy alone was not successful. Overall, 16 of 147 patients underwent re-surgery due to permanent leakage (10.9%). In three patients, closure of the remaining leakage was finally achieved with an over-the-scope-clip (OTSC, 2.0%). One patient elected to stop E-VAC therapy (0.7%). The other five patients were dis-



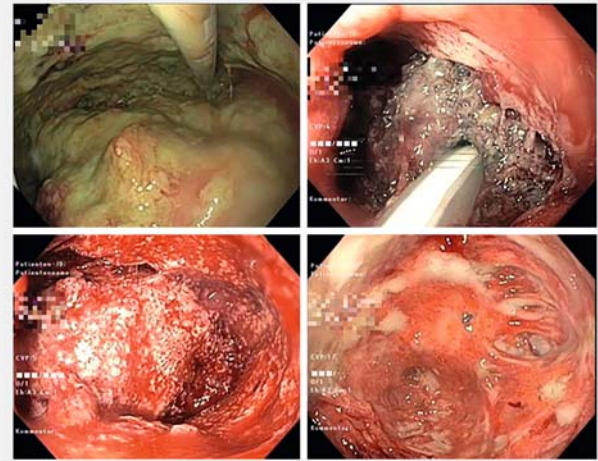
► **Fig. 1** Development of CRP values.

► **Table 2** Leakage- and/ or EVAC therapy-associated complications.

Complication	n/total (%)
None	121/147 (82.3)
Any	26/147 (17.7)
▪ Minor	12/147 (8.2)
▪ Recurrent dislocation	4/12 (33.3)
▪ Stenosis	3/12 (25.0)
▪ Bleeding	2/12 (16.7)
▪ Pneumonoperitoneum	1/12 (8.3)
▪ Fistula	1/12 (8.3)
▪ Perforation	1/12 (8.3)
▪ Major (death)	14/147 (9.5)
▪ Sepsis	7/14 (50.0)
▪ Colonic ischemia	3/14 (21.4)
▪ Cardiopulmonary insufficiency	2/14 (14.3)
▪ Myocardial infarction	1/14 (7.1)
▪ Bleeding	1/14 (7.1)

charged from hospital with permanent leakage and stoma (3.4%).

Among 95 patients who received a temporary stoma either during the initial surgery or as a rescue stoma, stoma could subsequently be closed in 57 of 95 patients (60.0%) (► **Table 3**). Patients with CRP levels ≤ 100 mg/L at first diagnosis of leakage underwent significantly more often stoma closure compared to patients with CRP levels ≥ 100 mg/L ($n = 29$ (78.4%) vs. $n = 29$ (52.7%); $P = 0.012$). Within regression analysis CRP value > 100 mg/L at time of leakage diagnosis was the only significant factor among advanced age and neoadjuvant treatment, which was associated with failure of stoma reversal (odds ratio 3.36 [1.24–9.25], $P = 0.017$) (► **Fig. 3**).



► **Fig. 2** Fifty-four-year-old male patient who suffered from leakage of the rectal stump after low anterior resection (LAR) and cystectomy due to colorectal cancer (G2 pT4b pN0 (0/15) L0 V0 Pn0 R0). **a** Endoscopic findings at diagnosis with leakage and a deep superinfected cavity into which a pigtail drainage had been introduced in beforehand. **b** E-VAC therapy was applied. After 18 days of therapy, which included five exchanges of the E-VAC system the patient showed adequate response resulting in cessation of therapy. **c** Granularized cavity as a sign of therapeutic response. **d** Final result with increasing closure of the leakage.

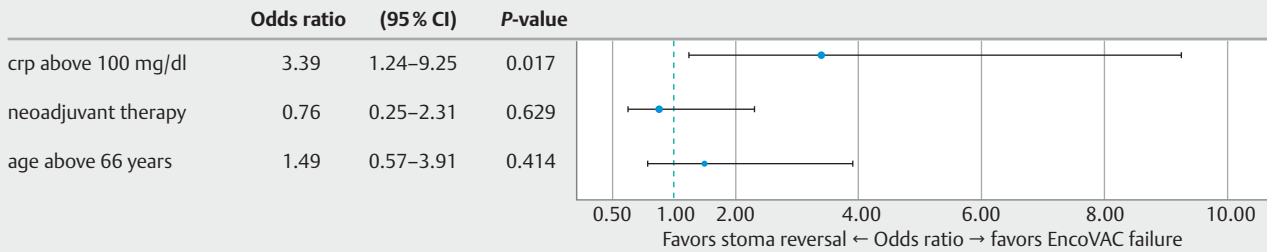
► **Table 3** Stoma closures.

	Total	Yes		No	
		n	%	n	%
Stoma reversal	95	57	60.0	38	40.0
▪ Primary (temporary) stoma	78	48	61.5	30	38.5
▪ Secondary (rescue) stoma	17	9	52.9	8	47.1

Discussion

Anastomotic leakage after colorectal surgery remains a serious complication which may be addressed by reoperation and/or endoscopic interventions. The use of E-VAC has augmented the therapeutic armamentarium in post-surgery leakage and is increasingly used in specialized centers [6, 7]. Its efficacy has recently been shown even in the outpatient setting [8]. E-VAC has replaced placement of self-expanding metal stents (SEMS) for leakage of the upper gastrointestinal tract in many centers due to highly effective results [9, 10]. In contrast to the management of upper gastrointestinal leakage, treatment with SEMS is not considered a promising endoscopic treatment option for lower gastrointestinal tract leakage due to higher complication rates emphasizing the need for a better understanding of E-VAC.

In this study, we investigated the clinical practice of E-VAC of the lower gastrointestinal tract in the largest multi-center co-



► **Fig. 3** Forest plot of risk groups to failure of stoma reversal.

hort, so far. We demonstrate a high primary efficacy of E-VAC extending 80% to achieve closure and complete epithelization of the leakage. Combination with other endoscopic methods such as OTSC placement even increased the rate of closure of leakage underlining the potential of endoscopic approaches for this severe post-operative complication. Previous studies suggested that 60% to 100% of anastomotic leakage of the lower gastrointestinal tract heal with E-VAC [6, 8]. However, definition of success varied among studies and, therefore, a more objective definition seems necessary to conclusively assess the efficacy of the procedure. In addition to closure and complete epithelization of the defect, stoma reversal has been discussed as an additional and clinically important parameter of treatment success [11]. In our cohort, most patients (74.8%) received a primary enterostoma. Previous studies could show that patients with a primary stoma have a significantly reduced risk for leakage following rectal surgery [12]. Impressively, only 11.6% of the patients received a rescue stoma in our cohort underlining the appropriate selection of patients for a primary stoma in our centers. Stoma reversal was achieved in 60% of patients with protective or rescue stoma in our cohort. Efficacy rates are in concordance with the published data ranging from 31% to 100% [6, 13]. Of note, our cohort involves patients from three large referral centers and, thus, comprises a more selected and difficult to treat patient cohort emphasizing the high treatment success of 80% for leakage closure and 60% for stoma closure, respectively.

Patients with CRP values ≤ 100 mg/L at first diagnosis of leakage underwent significantly more often stoma reversal compared to patients with CRP values >100 mg/L. This result indicates that these patients represent a subgroup with a favorable outcome and in whom an early stop of E-VAC therapy might be evaluated. CRP is one surrogate parameter of inflammation and is widely used to detect infections or infectious complications after surgery, respectively [14]. The predictive value of CRP varies among studies, however, its potential use to detect inflammation and/or infection is generally accepted [14]. Elevation of CRP levels reflect an activation of immune responses which are often triggered by infections in critically ill patients leading to worse outcome [15]. Consequently, CRP is a useful marker for the prediction of treatment success in E-VAC for anastomotic leakage of the lower gastrointestinal tract and may be used for risk stratification of the patients and possible early switch from endoscopic to surgical treatment.

Overall, our data clearly support that E-VAC of anastomotic leakage is a safe procedure. In our cohort, E-VAC-associated complications occurred in 18% of patients and could be managed conservatively in the majority of cases. However, 14 leakage- or E-VAC-associated deaths were observed accentuating the limits of this interventional approach in these vulnerable and critically ill patients. Nevertheless, the long-term outcome is encouraging with a mOS of 12 years and even the 1-year survival rate of 94% is comparable to in-hospital mortality of patients who underwent colorectal surgery within large observational cohorts ranging 95% to 96% [16].

A major limitation of our study is its retrospective nature with all its potential confounders including incomplete data such as procedure time. Moreover, diverging therapeutic approaches of the centers represent possible bias. However, we thoroughly screened the patient data bases and validated our data independently by two physicians reducing this bias. Additionally, significant clinical endpoints are hard to define, as most definitions of E-VAC success are highly dependent on the endoscopist's interpretation. Even stoma reversal as an endpoint independent of the endoscopist's interpretation has been discussed controversially, as it underestimates the success rate in patients with severe co-morbidity, insufficiency of the anal sphincter, chronic pre-sacral sinus or local recurrence [11]. Kühn et al defined E-VAC success as granulating closure of the cavity, more than 90% clean and granulating tissue, decreasing wound secretion, reduction of fibrinous tissue and no interventional or surgical procedure required in further course [8]. This rather strict and technical definition however resulted in a median therapy duration of 25 days, which seems long compared to 14 days in our cohort. As stoma reversal rate (68% vs. 60%) and treatment success (91% vs. 80%) was comparable to our cohort, a more clinical E-VAC termination trigger might be more appropriate.

Conclusions

In summary, here we present data from a large cohort of patients treated with E-VAC for leakage of the lower gastrointestinal tract, in three independent centers. We show promising data for both the, clinically meaningful endpoints, leakage and stoma reversal. We provide evidence that E-VAC due to post-surgery leakage of the lower gastrointestinal tract is safe and

effective in the majority of patients. High levels of CRP are a negative predictor of E-VAC therapy success.

Competing interests

The authors declare that they have no conflict of interest.

References

- [1] Lee WS, Yun SH, Roh YN et al. Risk factors and clinical outcome for anastomotic leakage after total mesorectal excision for rectal cancer. *World J Surg* 2008; 32: 1124–1129
- [2] Glitsch A, von Bernstorff W, Seltrecht U et al. Endoscopic transanal vacuum-assisted rectal drainage (ETVARD): an optimized therapy for major leaks from extraperitoneal rectal anastomoses. *Endoscopy* 2008; 40: 192–199
- [3] Nagell CF, Holte K. Treatment of anastomotic leakage after rectal resection with transrectal vacuum-assisted drainage (VAC). A method for rapid control of pelvic sepsis and healing. *Int J Colorectal Dis* 2006; 21: 657–660
- [4] Jimenez-Rodriguez RM, Araujo-Miguez A, Sobrino-Rodriguez S et al. A new perspective on vacuum-assisted closure for the treatment of anastomotic leak following low anterior resection for rectal cancer: Is it worthy? *Surg Innov* 2018; 25: 350–356
- [5] Weidenhagen R, Gruetzner KU, Wiecken T et al. Endoscopic vacuum-assisted closure of anastomotic leakage following anterior resection of the rectum: a new method. *Surg Endosc* 2008; 22: 1818–1825
- [6] Sharp G, Steffens D, Koh CE. Evidence of negative pressure therapy for anastomotic leak: a systematic review. *ANZ J Surg* 2021; 91: 537–545
- [7] Loske G, Müller CT. Tips and tricks for endoscopic negative pressure therapy. *Chirurg* 2019; 90: 7–14
- [8] Kühn F, Wirth U, Zimmermann J et al. Endoscopic vacuum therapy for in- and outpatient treatment of colorectal defects. *Surg Endosc* 2021; 35: 6687–6695
- [9] Brangewitz M, Voigtländer T, Helfritz FA et al. Endoscopic closure of esophageal intrathoracic leaks: stent versus endoscopic vacuum-assisted closure, a retrospective analysis. *Endoscopy* 2013; 45: 433–438
- [10] Book T, Wortmann N, Winkler M et al. Endoscopic vacuum assisted closure (E-VAC) of upper gastrointestinal leakages. *Scand J Gastro* 2021; 56: 1376–1379
- [11] Vignali A, De Nardi P. Endoluminal vacuum-assisted therapy to treat rectal anastomotic leakage: A critical analysis. *World J Gastroenterol* 2022; 14: 1394–1404
- [12] Warps AK, Tollenaar RAEM, Tanis PJ et al. Time-interval between rectal cancer resection and reintervention for anastomotic leakage and the impact of a defunctioning stoma: a Dutch population-based study. *Colorectal Dis* 2021; 23: 2937–2947
- [13] Kühn F, Schardey J, Wirth U et al. Endoscopic vacuum therapy for the treatment of colorectal leaks – a systematic review and meta-analysis. *Int J Colorectal Dis* 2022; 37: 283–292
- [14] Kumar A. Optimizing antimicrobial therapy in sepsis and septic shock. *Crit Care Clin* 2009; 25: 733–51
- [15] Vincent JL, Donadello K, Schmit X. Biomarkers in the critically ill patient: C-reactive protein. *Crit Care Clin* 2011; 27: 241–251
- [16] Diers J, Wagner J, Baum P et al. Nationwide in-hospital mortality rate following rectal resection for rectal cancer according to annual hospital volume in Germany. *BJS Open* 2020; 4: 310–319