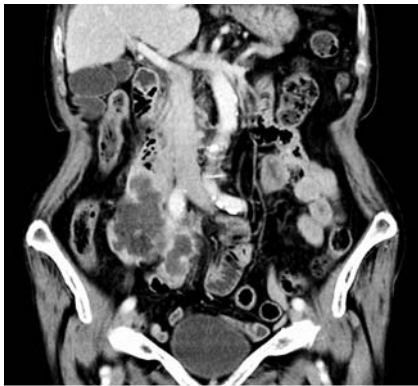


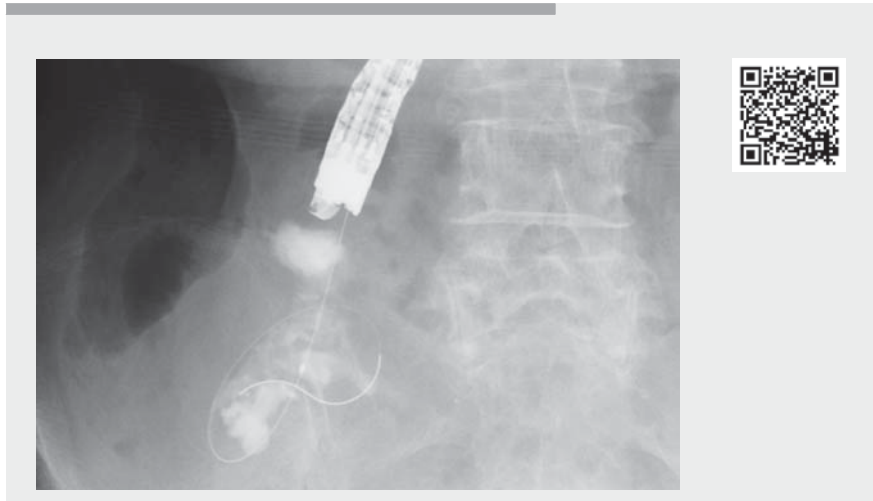
## Endoscopic ultrasound-guided transduodenal drainage using forward-viewing echoendoscope for appendiceal abscess

OPEN  
ACCESS

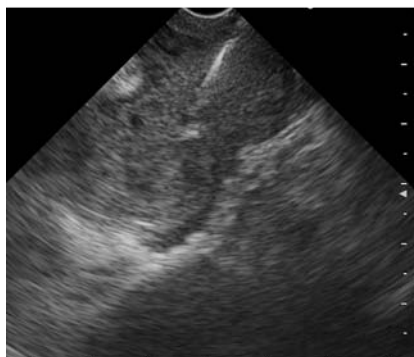


► **Fig. 1** Computed tomography on hospital Day 10 showing a 10-cm appendiceal abscess extending around the transverse part of the duodenum.

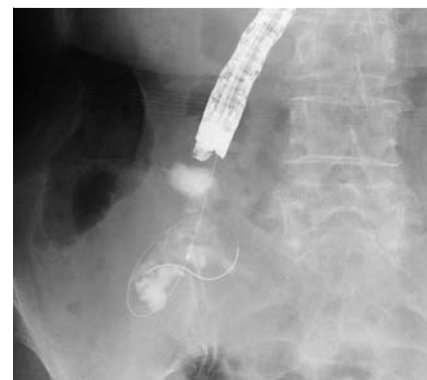Appendiceal abscesses sometimes require percutaneous drainage [1]. Recently, endoscopic ultrasound (EUS)-guided drainage through the intestinal tract has become possible, even in cases of pelvic or intra-abdominal abscesses resulting from lower gastrointestinal tract disease. However, this approach is usually performed through the rectum or sigmoid colon [2–5], and its use is challenging for appendiceal abscesses because of their location. Herein, we report a case of appendiceal abscess successfully treated by EUS-guided transduodenal drainage using a forward-viewing echoendoscope. A 93-year-old woman presented to our hospital with high fever and abdominal pain. Computed tomography (CT) showed appendiceal swelling with surrounding inflammation, prompting initial conservative treatment with antibiotics. However, CT on hospital Day 10 showed a 10-cm appendiceal abscess extending around the transverse part of the duodenum (► **Fig. 1**). Percutaneous drainage was challenging due to the surrounding organs. Although the abscess was due to appendicitis, it was in proximity to the duodenum. Therefore, we attempted



► **Video 1** Endoscopic ultrasound-guided transduodenal drainage using a forward-viewing echoendoscope for appendiceal abscess.



► **Fig. 2** Endoscopic ultrasound image. The appendiceal abscess is punctured by a 22-gauge needle through the inferior duodenum angle using a forward-viewing echoendoscope.

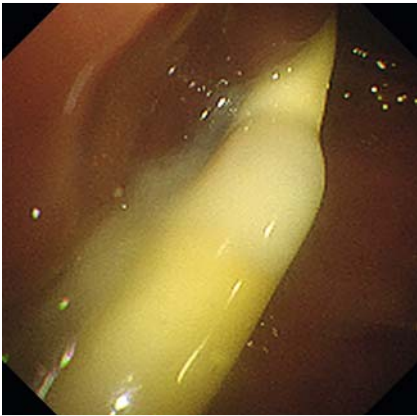


► **Fig. 3** Fluoroscopic image. The appendiceal abscess is confirmed fluoroscopically by injection of contrast medium. A 0.018-inch guidewire is advanced into the abscess, and a catheter is inserted over the guidewire to dilate the puncture site and aspirate pus.

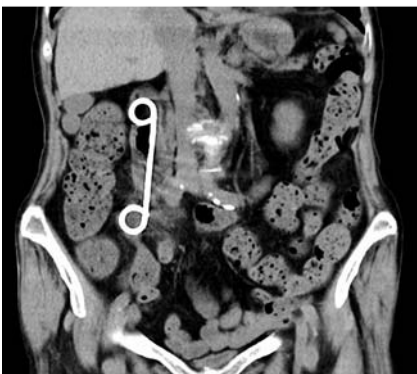EUS-guided transduodenal drainage (► **Video 1**).

In order to puncture the abscess from the deeper part of the duodenum, we used a forward-viewing echoendoscope (TGF-UC260; Olympus Medical Systems, Tokyo, Japan). The abscess was visualized from the inferior duodenal angle before being punctured with a 22-gauge needle

under EUS guidance (► **Fig. 2**). Contrast medium was injected to confirm that it was an abscess and its extent. A 0.018-inch guidewire (Fielder 0.018; Olympus Medical Systems) was advanced into the abscess (► **Fig. 3**). A catheter was inserted over the guidewire to dilate the



► **Fig. 4** A 7-Fr double-pigtail plastic stent is placed using a forward-viewing echo endoscope, and effective pus drainage is observed.



► **Fig. 5** Outpatient computed tomography on postprocedural Day 9 shows a remarkable reduction of the abscess cavity volume.

needle tract and aspirate pus. However, minimal specimen was aspirated due to its high viscosity. A 7-Fr double-pigtail plastic stent was then placed, which subsequently drained the pus (► **Fig. 4**). The patient quickly recovered and was discharged 6 days after the procedure. Outpatient CT on postprocedural Day 9 showed a remarkable reduction of the abscess cavity volume (► **Fig. 5**).

Endoscopy\_UCTN\_Code\_CPL\_1AM\_2AH

## Competing interests

The authors declare that they have no conflict of interest.

## The authors

**Kazuya Koizumi**<sup>1</sup>, **Sakue Masuda**<sup>1</sup>, **Makomo Makazu**<sup>1</sup>, **Haruto Hirose**<sup>1</sup>, **Ryuhei Jinushi**<sup>1</sup>, **Kento Shionoya**<sup>1</sup>, **Yuma Suno**<sup>2</sup>

- 1 Gastroenterology Medicine Center, Shonan Kamakura General Hospital, Kamakura, Kanagawa, Japan
- 2 Department of General Surgery, Shonan Kamakura General Hospital, Kamakura, Kanagawa, Japan

## Corresponding author

**Kazuya Koizumi, MD**

Gastroenterology Medicine Center, Shonan Kamakura General Hospital, 1370-1 Okamoto, Kamakura, Kanagawa 247-8533, Japan  
kizm2010@gmail.com

## References

- [1] Darwazeh G, Cunningham SC, Kowdley GC. A systematic review of perforated appendicitis and phlegmon: interval appendectomy or wait-and-see? *Am Surg* 2016; 82: 11–15
- [2] Giovannini M, Bories E, Moutardier V et al. Drainage of deep pelvic abscesses using therapeutic echo endoscopy. *Endoscopy* 2003; 35: 511–514
- [3] Varadarajulu S, Drelichman ER. EUS-guided drainage of pelvic abscess (with video). *Gastrointest Endosc* 2007; 66: 372–376
- [4] Trevino JM, Drelichman ER, Varadarajulu S. Modified technique for EUS-guided drainage of pelvic abscess (with video). *Gastrointest Endosc* 2008; 68: 1215–1219
- [5] Monino L, Piessevaux H, Denis MA et al. Management of pelvic abscess complicating a rectoanal fistula using endoscopic ultrasound-guided drainage with an electrocautery-enhanced lumen-apposing metal stent. *Endoscopy* 2021; 53: E409–E410

## Bibliography

*Endoscopy* 2023; 55: E384–E385

DOI 10.1055/a-1996-0657

ISSN 0013-726X

© 2023. The Author(s).

This is an open access article published by Thieme under the terms of the Creative Commons Attribution-NonDerivative-NonCommercial License, permitting copying and reproduction so long as the original work is given appropriate credit. Contents may not be used for commercial purposes, or adapted, remixed, transformed or built upon. (<https://creativecommons.org/licenses/by-nc-nd/4.0/>)

Georg Thieme Verlag KG, Rüdigerstraße 14, 70469 Stuttgart, Germany



## ENDOSCOPY E-VIDEOS

<https://eref.thieme.de/e-videos>



*Endoscopy E-Videos* is an open access online section, reporting on interesting cases

and new techniques in gastroenterological endoscopy. All papers include a high quality video and all contributions are freely accessible online. Processing charges apply (currently EUR 375), discounts and waivers acc. to HINARI are available.

This section has its own submission website at

<https://mc.manuscriptcentral.com/e-videos>