



Clinical Outcome of Pedicle-Sparing Transfacet Diskectomy and Fusion with Segmental Instrumentation for Thoracic Disc Herniation

Keyvan Eghbal¹  Saber Zafarshampour^{1,2}  Mohammadamin Sookhklari³ Arash Saffarian¹
Reza Taheri¹

¹Department of Neurosurgery, Shiraz University of Medical Sciences, Shiraz, Iran

²Department of Surgery, Rafsanjan University of Medical Sciences, Kerman, Iran

³Student Research Committee, Shiraz University of Medical Sciences, Shiraz, Iran

Address for correspondence Saber Zafarshampour, MD, Department of Surgery, Rafsanjan University of Medical Sciences, Rafsanjan, Kerman, Iran (e-mail: saberzsp@gmail.com).

J Neurol Surg A Cent Eur Neurosurg 2024;85:240–245.

Abstract

Background Thoracic disk herniations (TDHs) are relatively rare compared with their cervical and lumbar counterparts. Posterior approaches allow for a simpler and less invasive surgery than anterior and lateral approaches. A pedicle-sparing transfacet approach was initially described in 1995, and modified in 2010. A few clinical series have reported the outcome of this procedure in patients with TDH. This study aimed to evaluate the outcomes and complications of pedicle-sparing transfacet diskectomy with interbody fusion and segmental instrumentation in patients with TDH.

Methods Twenty-one consecutive patients with symptomatic TDH referred to our tertiary care center were included in this retrospective study. All patients underwent a pedicle-sparing transfacet diskectomy with polyetheretherketone (PEEK) cage interbody fusion and short segmental instrumentation. Distribution of TDH, operative duration, blood loss, Visual Analog Scale (VAS) pain scores, Nurick grades, modified Japanese Orthopaedic Association (mJOA) scores, and fusion rate were assessed.

Results All patients had single-level herniations. The most common location was T12–L1 (38.1%), followed by T11–T12 (33.3%). All patients were successfully operated on with no cerebrospinal fluid (CSF) leaks or wrong-level surgery. The VAS scores significantly diminished from 4.9 (preoperatively) to 2 (18 months after surgery). The average mJOA score increased from 4.6 to 8.5, and the average Nurick grade decreased from 3.1 to 1.6. All patients reported significant improvement in quality of life relative to their preoperative status.

Conclusion A modified pedicle-sparing transfacet diskectomy combined with PEEK cage interbody fusion and segmental instrumentation offers a safe and less invasive approach for the treatment of TDHs.

Keywords

- ▶ thoracic disk herniation
- ▶ interbody fusion
- ▶ PEEK cage
- ▶ pedicle-sparing transfacet diskectomy
- ▶ thoracic instrumentation

received

May 15, 2022

accepted after revision

December 27, 2022

accepted manuscript online

December 30, 2022

article published online

May 11, 2023

© 2023, Thieme. All rights reserved.
Georg Thieme Verlag KG,
Rüdigerstraße 14,
70469 Stuttgart, Germany

DOI <https://doi.org/10.1055/a-2005-0620>.
ISSN 2193-6315.

Background

Thoracic disk herniations (TDHs) are uncommon compared with cervical or lumbar disk herniations and comprise ~0.15 to 4.0% of all disk herniations.^{1,2} Men are more likely than women to develop a TDH, and the highest prevalence is in 40- and 50-year-olds. The majority of TDHs occur at the lower thoracic levels, with over 75% located below T8, primarily at T11–T12.^{3,4} Similar to cervical and lumbar disk herniations, spontaneous resorption of herniated disk material has been observed, and thus, conservative management is preferred unless persistent axial back pain, intractable radiculopathy, and myelopathy exist.^{1–5}

Surgical treatment is aimed primarily at alleviation of pain, decompression of neural elements, improvement of functional status, prevention of progressive instability, and correction of deformity.⁶ Decompression with laminectomy has been associated with a high rate of morbidity. Thus, multiple surgical techniques with anterior, lateral, and posterior approaches have been developed and investigated.^{1–3} Transthoracic approaches have been the mainstay of treatment,¹ especially for central, giant, and calcified TDHs due to their superior efficacy in decompression of the ventral spinal cord.⁷ However, limitations exist when respiratory comorbidities are present.⁸ Posterior approaches offer a simpler and less invasive surgery than their transthoracic or lateral extracavitary counterparts.

Pedicle-sparing transfacet approach was first described by Stillerman and colleagues in 1995, and modified by Bransford et al, to allow for a safe access to thoracic disk space without the need for rib excision or exploration of the pleural cavity, hence avoiding long-term respiratory effects.⁶ This procedure enables anterior column reconstruction with a bone graft or interbody cage. Segmental fixation with pedicle screws ensures rigid fixation,^{7–15} enables correction of the deformity, and maintains spinal stability until bony fusion occurs.⁹

A few clinical series have reported the outcome of the pedicle-sparing transfacet discectomy and fusion in patients with TDH. The aim of this study was to evaluate the outcome and complications of pedicle-sparing transfacet discectomy and fusion in a consecutive series of patients.

Materials and Methods

Patient Population

After approval by the institutional review board (ethics review board approval ID: IR.SUMS.MED.REC.1400.027), medical records of our tertiary referral center were reviewed to identify patients with TDHs who underwent pedicle-sparing transfacet thoracic discectomy with segmental instrumentation, between March 2015 and March 2019. Twenty-seven consecutive patients were enrolled in this retrospective study. Patients who had undergone previous cervical or lumbar spinal surgery, with medical and neurologic comorbidities and with inconsistent follow-up and inadequate records, were excluded from the study. Age, sex, presence of neurologic involvement (radiculopathy,

myelopathy, and involvement of the bladder and bowel), duration of symptoms, duration of surgery, blood loss, and intraoperative and postoperative complications were noted. Visual Analog Scale (VAS) for pain, Nurick grade, and the modified Japanese Orthopaedic Association (mJOA) scoring system for thoracic myelopathy for objective assessment of functional disability were assessed preoperatively and after 18 months of follow-up.

Surgical Technique

The same surgeon performed all the operations. An open technique was used. The surgical technique has been described previously by Bransford et al.⁶ A summary of the surgical procedure is presented below. Surgery was performed with the patient in the prone position. Each patient received 2 g of intravenous cefazolin about half an hour before skin incision. Intraoperative neuromonitoring increases the surgical costs and was not routinely used. Subperiosteal dissection of the posterior elements of the target level was performed up to the tips of the transverse processes in a standard midline fashion. Pedicle screws were placed under fluoroscopic guidance, and a unilateral rod (opposite to the site of facetectomy) was inserted with a slight distraction to allow better disk space opening, discectomy, and interbody cage placement. A bilateral laminectomy was performed to relieve the local stenosis. Unilateral complete facetectomy (from pedicle to pedicle) was performed for most cases, which were lateral-type herniations (→Fig. 1). In case of a central-type herniation, bilateral complete facetectomy and slight tilt of the operating table are generally necessary for better visualization and access to the disk space. The upper and lower nerve roots were preserved and need not be sacrificed. The posterolateral annulus was incised and complete discectomy with endplate preparation was performed using endplate shavers, curettes, and rongeurs. Reverse-angle curettes were used to push

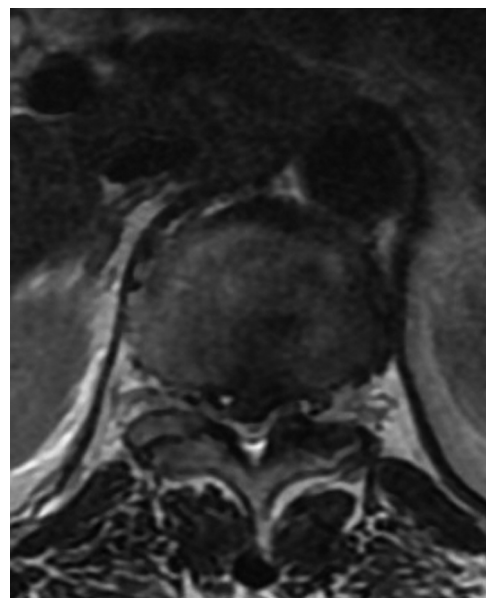


Fig. 1 Preoperative axial T2-weighted (T2W) magnetic resonance imaging of a 46-year-old male patient with right paracentral T12/L1 disk herniation and cord compression.

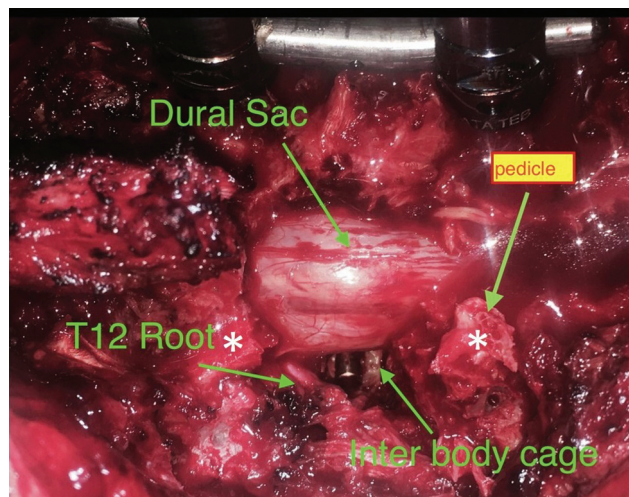


Fig. 2 Intraoperative image of a T12/L1 disk herniation. Pedicle screws were inserted with unilateral rod insertion and slight distraction to allow better disk space access. Bilateral discectomy was performed to relieve local stenosis. Unilateral complete facetectomy (from pedicle to pedicle [white asterisks]) was performed. After complete discectomy and disk space preparation, an interbody cage was inserted. The upper and lower nerve roots were preserved.

down the centrally located disk fragments and osteophytes. After proper discectomy, a polyetheretherketone (PEEK) cage, filled with local bone graft, was inserted under C-arm fluoroscopy guidance. Finally, the other rod was inserted, and short segmental instrumentation was performed (► **Fig. 2**).

Postoperative Care

Each patient received postoperative antibiotic therapy until their drains were removed (usually 48 hours). Patients were mobilized early postoperatively. If necessary, a postoperative computed tomography (CT) scan with a sagittal reconstruction to evaluate the level of decompression, appropriate placement of instrumentation, and adequacy of decompression was performed. Anteroposterior and lateral radiographs were requested within 24 hours of the surgery to evaluate instrumentation. During follow-up visits, flexion–extension radiographs and CT scan were obtained to evaluate for arthrodesis.

Results

Twenty-seven patients with symptomatic TDHs were identified. Six patients were excluded because of previous lumbar surgery for stenosis (1 patient), previous cervical surgery for cervical spondylotic myelopathy (1 patient), multiple sclerosis (1 patient), rheumatoid arthritis (1 patient), and loss to follow-up (2 patients). Twenty-one individuals were included with a mean age of 44 ± 15.7 years (range: 16–69 years). Sixteen patients (76.2%) were males and 5 patients were females (23.8%).

All patients had single-level herniation. Disk herniation was located in 95.2% of patients between T10 and L1. The most common location was T12–L1 (8 patients, 38.1%), followed by T11–T12 (7 patients, 33.3%), T10–T11 (5 patients, 23.8%), and T4–T5 (1 patient, 4.8%). Disk herniation

Table 1 Frequency of symptoms in patients

Symptoms/signs	Proportion (%)	Cases
Lower extremity weakness	61.9	13
Paresthesia/numbness	23.8	5
Difficulty walking	47.6	10
Urinary dysfunction	47.6	10
Radicular pain	76.1	16
Myelopathy	71.4	15

was lateral in 13 patients (61.9%) and central in 8 patients (38.0%). The herniated fragment was calcified in 10 patients (7 lateral vs. 3 central).

The average duration of symptoms was 6.45 months (<1–60 months). All patients complained of axial back pain. A neurologic examination revealed myelopathy and long tract signs in 71.4% of patients (15 patients). The most common symptoms were radicular pain (16 patients, 76.1%) and lower extremity weakness (13 patients, 61.9%), followed by difficulty walking (10 patients, 47.6%) and urinary dysfunction (10 patients, 47.6%). Five patients complained of saddle hypesthesia (23.8%). Urinary retention was observed in 7 of 10 patients with urinary dysfunction (► **Table 1**).

The average operation time was 265.9 ± 43.1 minutes (range: 180–345 minutes). The average estimated blood loss was 680 ± 403.5 mL (100–1,500 mL; $\leq 1,000$ mL in 81.0% of cases; ► **Table 2**). No dural tears or cerebrospinal fluid (CSF) leaks were encountered in our cases. Following surgery, most patients were transferred to the ward (90.4%); only two patients were transferred to the intensive care unit for an overnight observation due to previous history of cardiac disease and postanesthetic precautions. The average length of postoperative hospital stay was 4.41 days (range: 2–7 days). Drains were kept on average for 2.7 days during hospitalization (1–5 days).

Preoperatively, 10 patients (47.6%) had difficulty walking and were unable to walk without help with 3 patients using a wheelchair. However, 1 to 150 days following surgery (mean: 35.08 days), all patients could walk either independently or with minimal help.

Preoperative axial back pain and radicular symptoms, as assessed by the VAS scores, were improved in all patients. No neurologic deterioration was observed. The VAS scores diminished from 4.9 ± 2.3 (range: 1–7) preoperatively to 2 ± 1.8 (range: 0–5) 18 months after surgery ($p < 0.001$; ► **Fig. 3a**; ► **Table 2**). Functional disability was assessed with Nurick and mJOA criteria preoperatively and 18 months after surgery. Both scores improved significantly 18 months after surgery. The average mJOA score increased from 4.6 ± 2.3 to 8.5 ± 1.8 ($p < 0.001$), and the average Nurick grade decreased from 3.1 ± 1.2 to 1.6 ± 1.2 ($p < 0.001$; ► **Figs. 3b & 3c**; ► **Table 2**). There were no cases of pseudarthrosis or hardware failure and successful fusion was observed in all cases (► **Fig. 4**).

Table 2 Summary of patient demographic and clinical characteristics

N	Age/sex	Level	Operative time (min)	Blood loss (mL)	Follow-up (mo)	Nurick		mJOA		pain	
						Pre-op	Final	Pre-op	Final	Pre-op	Final
1	47/M	T11/T12	250	350	34.5	4	1	6	10	1	0
2	22/M	T12/L1	270	400	50.4	1	0	9	11	7	0
3	20/M	T4/T5	255	900	37.5	5	1	0	8	5	5
4	61/M	T10/T11	180	400	27	4	4	3	5	1	1
5	16/M	T11/T12	345	350	44.5	3	1	5	9	3	1
6	47/M	T12/L1	270	1,500	59.3	4	1	3	10	7	0
7	32/F	T11/T12	270	600	15.3	2	1	8	10	6	5
8	40/M	T12/L1	240	600	70.4	4	3	4	7	7	4
9	53/M	T10/T11	270	750	51.5	2	1	6	10	7	4
10	62/F	T10/T11	280	1,300	29	5	4	1	6	4	0
11	35/M	T10/T11	315	600	47.4	2	1	6	10	3	0
12	46/M	T11/T12	210	450	67	3	3	5	8	7	4
13	63/M	T11/T12	195	500	40.5	4	1	5	8	6	2
14	35/M	T11/T12	225	300	32.9	3	3	5	5	5	3
15	59/M	T10/T11	225	450	49.2	2	1	7	10	7	3
16	24/M	T12/L1	315	100	35.9	2	1	7	9	1	1
17	46/M	T11/T12	300	500	33.2	2	1	7	10	1	1
18	69/F	T12/L1	315	500	46.2	4	4	3	6	5	4
19	53/F	T12/L1	315	1,350	31.3	2	0	3	10	6	3
20	60/F	T12/L1	270	1,400	30.3	4	1	3	10	7	0
21	34/M	T12/L1	270	1,000	47.6	5	1	2	8	7	2
Mean	44 ± 15.7	-	265 ± 43.1	680 ± 403.5	41.9 ± 13.5	3.1 ± 1.2	1.6 ± 1.2	4.6 ± 2.3	8.5 ± 1.8	4.9 ± 2.3	2 ± 1.8

Abbreviation: mJOA, modified Japanese Orthopaedic Association.

Discussion

TDHs have a very low incidence relative to cervical and lumbar disk disease, and controversy still remains as to the best way to manage them.^{2,6,8} Multilevel TDHs occur much less commonly than single-level herniations. Asymptomatic and small TDHs with minimal symptoms are managed

conservatively; however, surgery management is recommended for patients with persistent axial back pain, intractable radiculopathy, and myelopathy. In our experience, 21 patients with symptomatic TDHs were included. All patients had single-level TDHs, and 95.2% were located between T10 and L1 in the thoracolumbar region, with T12–L1 (38.1%) and T11–T12 (33.3%) being the most common sites. Our findings

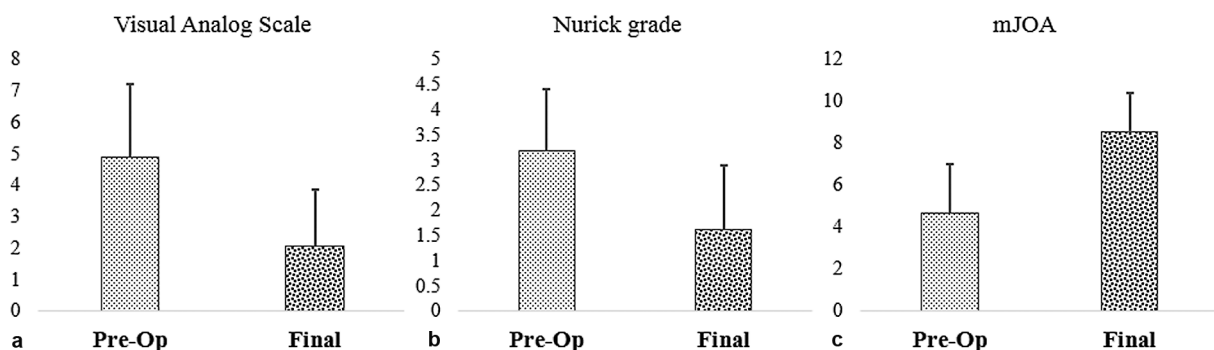


Fig. 3 The average preoperative and final values of (a) Visual Analog Scale, (b) Nurick’s grade, and (c) modified Japanese Orthopaedic Association (mJOA) score.

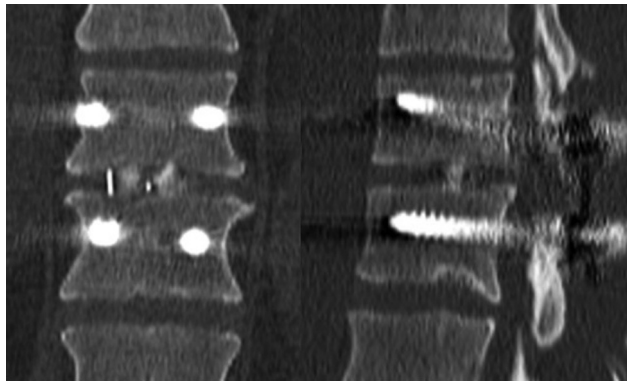


Fig. 4 Sagittal and coronal reconstructions of spinal T12/L1 computed tomography (CT) scan depicting successful interbody fusion 18 months after surgery.

were consistent with previous studies by Yamasaki et al¹ (T10–T11 and T12–L1), Machino et al¹⁴ (T11–T12), Kim et al¹⁶ (T11–T12), Ibrahim et al⁹ (T11–T12), and Krishnan et al¹⁷ (T11–T12). The presenting neurologic symptoms and deficits of our patients were similar to those reported in previous case series, and consisted of axial back pain, radicular pain, difficulty walking, lower extremity weakness, myelopathy, and urinary dysfunction.

Decompression with laminectomy alone is associated with less-than-ideal results and major morbidity.^{2,8} Removing disk material anterior to the thoracic spinal cord is difficult and mechanical damage with resulting neurologic injury, such as increased paresis or paralysis, is inevitable. Therefore, transthoracic approaches were developed for the management of TDHs, especially calcified TDHs in patients with myelopathy. The lateral extracavitary and the costo-transversectomy approaches were originally developed for the surgery of traumatic fractures or Pott's disease, and intended to overcome the limitations of posterior and posterolateral approaches.^{2,6,8} Although these approaches provide an excellent exposure of the ventral aspect of the spinal cord, these procedures are limited by high complication rates, considerable blood loss, and long postoperative hospital stay. Mulier and Debois reported a higher pulmonary complication rate of 7% following transthoracic approach versus 0% in those treated with a posterolateral approach, and concluded that a posterolateral approach was a reasonable option in patients with pulmonary comorbidities. In our series of 21 cases, we had no pulmonary complications.²

Posterior approaches allow for a simpler and less invasive surgery than their transthoracic or lateral extracavitary counterparts. These procedures provide access to ventral neural decompression with relatively low morbidity, have improved clinical outcomes, and require less specialized facilities than anterior approaches. Pedicle-sparing transfacet approach was first described by Stillerman and colleagues in 1995, and modified by Bransford et al.⁶ The modified approach includes complete uni- or bilateral facetectomies (from pedicle to pedicle), and provides adequate access to the thoracic intervertebral disk space. However, a bilateral transfacet approach greatly augments visualization

of the ventral thecal sac and ensures a safe and complete decompression.

The need for a fusion following thoracic discectomy remains controversial. In the absence of preexisting deformity, symptomatic spinal instability following either anterior or posterior procedures is a rare occurrence. Patients with previous laminectomy, severe thoracic axial pain, kyphotic deformity, osteoporosis, Scheuermann's disease, multilevel discectomies, and discectomy at the thoracolumbar area may need fusion to prevent further deterioration.^{18,19} However, the final decision regarding the need for fusion rests with the surgeon. In our experience, we performed unilateral complete facetectomies for lateral-type herniations and bilateral complete facetectomies for central-type herniations with segmental instrumentation. We agree with other authors that segmental fusion prevents long-term progressive instability, minimizes postoperative axial back pain, and facilitates early patient mobilization.⁶ No long-term complications of instrumentation (hardware failure or malpositioning) occurred in this study. To date, a few clinical series have been published to report the outcome of this procedure in patients with TDH.

Consistent with previous reports by Machino et al¹⁴ and Krishnan et al,¹⁷ arthrodesis was achieved in all patients. Our findings demonstrate that the pedicle-sparing transfacet approach, when combined with a transforaminal interbody and segmental fusion, offers a high fusion rate and good postoperative stability.

The goal of any surgical procedure is to reduce patients' pain, improve their functional status, and, ultimately, improve patients' quality of life. In our case series, no postoperative neurologic deterioration was observed. The VAS scores diminished and the functional status, as assessed with Nurick and mJOA criteria, significantly improved 18 months after surgery. All patients reported significant improvement in their quality of life. These findings were consistent with previous reports in the literature.

The most common complications reported in previous reports were postoperative infections and CSF leaks. No major complications such as surgical site infection, CSF leak, wrong-level surgery, and pedicle screw requiring revision were observed in our case series of 21 patients.

We acknowledge that the current study presents a small number of successfully treated central calcified TDHs, and the limitations of posterior techniques in providing adequate ventral access for these cases should not be underestimated. A relatively small cohort size derived from a single institution and the retrospective design of the study were our major limitations. Although the majority of patients were referred to our center, there were similarities between our surgically treated patients and patients in previous studies regarding outcome and distribution of TDHs. Future trials with bigger sample sizes are recommended.

Conclusion

The current series reports excellent clinical outcome with the transfacet approach and provides greater evidence that

this approach can be applied to a much broader morphologic and anatomic range of TDHs. Based on previous reports and our findings, pedicle-sparing transfacet thoracic discectomy, combined with transforaminal interbody and segmental fusion, offers an acceptable surgical approach in patients with symptomatic TDH with favorable clinical outcome and few complications.

Conflict of Interest

None declared.

References

- 1 Yamasaki R, Okuda S, Maeno T, Haku T, Iwasaki M, Oda T. Surgical outcomes of posterior thoracic interbody fusion for thoracic disc herniations. *Eur Spine J* 2013;22(11):2496–2503
- 2 Mulier S, Debois V. Thoracic disc herniations: transthoracic, lateral, or posterolateral approach? A review. *Surg Neurol* 1998;49(06):599–606, discussion 606–608
- 3 Arce CA, Dohrmann GJ. Herniated thoracic disks. *Neurol Clin* 1985;3(02):383–392
- 4 Okada Y, Shimizu K, Ido K, Kotani S. Multiple thoracic disc herniations: case report and review of the literature. *Spinal Cord* 1997;35(03):183–186
- 5 Haro H, Domoto T, Maekawa S, Horiuchi T, Komori H, Hamada Y. Resorption of thoracic disc herniation. Report of 2 cases. *J Neurosurg Spine* 2008;8(03):300–304
- 6 Bransford R, Zhang F, Bellabarba C, Konodi M, Chapman JR. Early experience treating thoracic disc herniations using a modified transfacet pedicle-sparing decompression and fusion. *J Neurosurg Spine* 2010;12(02):221–231
- 7 Hott JS, Feiz-Erfan I, Kenny K, Dickman CA. Surgical management of giant herniated thoracic discs: analysis of 20 cases. *J Neurosurg Spine* 2005;3(03):191–197
- 8 Fessler RG, Sturgill M. Review: complications of surgery for thoracic disc disease. *Surg Neurol* 1998;49(06):609–618
- 9 Ibrahim F, Elkhateeb TM, Abd El-Rady A, Zayan M. Transforaminal posterior approach is effective for treatment of lower thoracic spine spondylodiscitis. *HSS J* 2020;16(2, Suppl 2):515–520
- 10 Blume H. Unilateral lumbar interbody fusion (posterior approach) utilizing dowel grafts. Experience in over 200 patients. *J Neurol Orthopaed Surg* 1981;2(03):171–175
- 11 Harris BM, Hilibrand AS, Savas PE, et al. Transforaminal lumbar interbody fusion: the effect of various instrumentation techniques on the flexibility of the lumbar spine. *Spine* 2004;29(04):E65–E70
- 12 Lowe TG, Tahernia AD, O'Brien MF, Smith DA. Unilateral transforaminal posterior lumbar interbody fusion (TLIF): indications, technique, and 2-year results. *J Spinal Disord Tech* 2002;15(01):31–38
- 13 Taneichi H, Suda K, Kajino T, Matsumura A, Moridaira H, Kaneda K. Unilateral transforaminal lumbar interbody fusion and bilateral anterior-column fixation with two Brantigan I/F cages per level: clinical outcomes during a minimum 2-year follow-up period. *J Neurosurg Spine* 2006;4(03):198–205
- 14 Machino M, Yukawa Y, Ito K, Nakashima H, Kato F. A new thoracic reconstruction technique "transforaminal thoracic interbody fusion": a preliminary report of clinical outcomes. *Spine* 2010;35(19):E1000–E1005
- 15 Jaslow IA. Intercorporeal bone graft in spinal fusion after disc removal. *Surg Gynecol Obstet* 1946;82:215–218
- 16 Kim M, Oh SK, Choi I, Seo DK, Roh SW, Jeon SR. Clinical outcomes of posterior thoracic cage interbody fusion (PTCIF) to treat trauma and degenerative disease of the thoracic and thoracolumbar junctional spine. *J Clin Neurosci* 2019;60:117–123
- 17 Krishnan A, Degulmadi D, Mayi S, et al. Transforaminal thoracic interbody fusion for thoracic disc prolapse: surgicoradiological analysis of 18 cases. *Global Spine J* 2020;10(06):706–714
- 18 Krauss WE, Edwards DA, Cohen-Gadol AA. Transthoracic discectomy without interbody fusion. *Surg Neurol* 2005;63(05):403–408, discussion 408–409
- 19 Bouthors C, Benzakour A, Court C. Surgical treatment of thoracic disc herniation: an overview. *Int Orthop* 2019;43(04):807–816