

Personalized endoscopic surveillance and intervention protocols for patients with familial adenomatous polyposis: the European FAP Consortium strategy



Authors

Arthur S. Aelvoet^{1,2,3}, Maria Pellisé⁴, Barbara A.J. Bastiaansen^{1,2,3}, Monique E. van Leerdam^{5,6}, Rodrigo Jover⁷, Francesc Balaguer⁴, Michal F. Kaminski⁸, John G. Karstensen^{9,10}, Jean-Christophe Saurin¹¹, Roel Hompes^{2,12}, Patrick M.M. Bossuyt¹³, Luigi Ricciardiello^{14,15}, Andrew Latchford^{16,17}, Evelien Dekker^{1,2,3}; European FAP Consortium

Institutions

- 1 Amsterdam UMC location University of Amsterdam, Department of Gastroenterology and Hepatology, Amsterdam, the Netherlands
- 2 Cancer Center Amsterdam, Amsterdam, the Netherlands
- 3 Amsterdam Gastroenterology Endocrinology Metabolism, Amsterdam, the Netherlands
- 4 Department of Gastroenterology, Hospital Clínic de Barcelona, Institut d'Investigacions Biomèdiques August Pi i Sunyer (IDIBAPS), Centro de Investigación Biomédica en Red de Enfermedades Hepáticas y Digestivas (CIBEREHD), University of Barcelona, Barcelona, Spain
- 5 Department of Gastrointestinal Oncology, Netherlands Cancer Institute, Amsterdam, the Netherlands
- 6 Department of Gastroenterology and Hepatology, Leiden University Medical Center, Leiden, the Netherlands
- 7 Servicio de Medicina Digestiva, Hospital General Universitario de Alicante, Instituto de Investigación Biomédica ISABIAL, Universidad Miguel Hernández, Alicante, Spain
- 8 Department of Oncological Gastroenterology and Department of Cancer Prevention, Maria Skłodowska-Curie National Research Institute of Oncology, Warsaw, Poland
- 9 Danish Polyposis Registry. Gastrounit, Copenhagen University Hospital – Amager and Hvidovre, Hvidovre, Denmark
- 10 Department of Clinical Medicine, University of Copenhagen, Copenhagen, Denmark
- 11 Gastroenterology Unit, Hospices Civils de Lyon, Hôpital E. Herriot, Lyon, France.
- 12 Amsterdam UMC location University of Amsterdam, Department of Surgery, Amsterdam, the Netherlands.
- 13 Amsterdam UMC location University of Amsterdam, Department of Epidemiology and Data Science, Amsterdam, the Netherlands
- 14 Department of Medical and Surgical Sciences, University of Bologna, Bologna, Italy

- 15 IRCCS Azienda Ospedaliero-Universitaria di Bologna, Policlinico di Sant'Orsola, Bologna, Italy
- 16 Polyposis Registry, St Mark's Hospital, Harrow, United Kingdom
- 17 Department of Surgery and Cancer, Imperial College, London, United Kingdom

submitted 28.11.2022

accepted after revision 29.12.2022

published online 11.1.2023

Bibliography

Endosc Int Open 2023; 11: E386–E393

DOI 10.1055/a-2011-1933

ISSN 2364-3722

© 2023. The Author(s).

This is an open access article published by Thieme under the terms of the Creative Commons Attribution-NonDerivative-NonCommercial License, permitting copying and reproduction so long as the original work is given appropriate credit. Contents may not be used for commercial purposes, or adapted, remixed, transformed or built upon. (<https://creativecommons.org/licenses/by-nc-nd/4.0/>)

Georg Thieme Verlag KG, Rüdigerstraße 14, 70469 Stuttgart, Germany

Corresponding author

Prof. Dr. Evelien Dekker, MD, PhD, Department of Gastroenterology and Hepatology, Amsterdam University Medical Centers, location Academic Medical Center, Meibergdreef 9, 1105 AZ Amsterdam, the Netherlands
Fax: +31 20 6917033
e.dekker@amsterdamumc.nl

ABSTRACT

Background and study aims Patients with familial adenomatous polyposis (FAP) undergo colectomy and lifelong endoscopic surveillance to prevent colorectal, duodenal and gastric cancer. Endoscopy has advanced significantly in recent years, including both detection technology as well as treatment options. For the lower gastrointestinal tract, current guidelines do not provide clear recommenda-

tions for surveillance intervals. Furthermore, the Spigelman staging system for duodenal polyposis has its limitations. We present a newly developed personalized endoscopic surveillance strategy for the lower and upper gastrointestinal tract, aiming to improve the care for patients with FAP. We aim to inform centers caring for FAP patients and encourage the discussion on optimizing endoscopic surveillance and treatment in this high-risk population.

Methods The European FAP Consortium, consisting of endoscopists with expertise in FAP, collaboratively developed new surveillance protocols. The proposed strategy was consensus-based and a result of several consortium meetings, discussing current evidence and limitations of

existing systems. This strategy provides clear indications for endoscopic polypectomy in the rectum, pouch, duodenum and stomach and defines new criteria for surveillance intervals. This strategy will be evaluated in a 5-year prospective study in nine FAP expert centers in Europe.

Results We present a newly developed personalized endoscopic surveillance and endoscopic treatment strategy for patients with FAP aiming to prevent cancer, optimize endoscopic resources and limit the number of surgical interventions. Following this new strategy, prospectively collected data in a large cohort of patients will inform us on the efficacy and safety of the proposed approaches.

Introduction

Familial adenomatous polyposis (FAP) is an inherited autosomal dominant disorder caused by a constitutional pathogenic variant of the APC gene. In a minority of the patients with a classical phenotype however, no constitutional pathogenic variant is found [1]. Patients with FAP typically develop hundreds to thousands colorectal adenomas from teenage years, inevitably causing colorectal cancer at a median age of 35 to 45 years, if left untreated [2]. Therefore, these patients require prophylactic (procto)colectomy usually at young adult age. Patients most commonly undergo either (sub)total colectomy with ileosigmoidal or ileorectal anastomosis (ISA/IRA) or restorative proctocolectomy with ileal pouch-anal anastomosis (IPAA), mainly depending on the severity of rectal polyposis at time of surgery [3].

Obviously, patients with ISA/IRA stay at risk of developing adenomas and cancer in the retained rectum/rectosigmoid. Reported risks of rectal cancer after ISA/IRA vary between 0.5% to 11.2% during a median follow-up of 8.6 to 17.1 years [4–7]. Although overall 5.2% to 11.7% [4,7] undergo secondary proctectomy after ISA/IRA due to severe rectal polyposis or rectal cancer, one study in a historic series showed that at age 60 only in half of patients the rectum was still preserved [5]. At 5, 10 and 15 years after IPAA, 7% to 16%, 35% to 42% and 75% of patients will develop adenomas in the pouch, respectively [8]. Nonetheless, the risk of developing cancer after IPAA appears to be low at 1% to 2% [6,9,10] and most of these cancers (75%) develop in the retained rectal cuff rather than in the ileal pouch body itself [11]. Patients might require pouch excision for severe pouch polyposis or cancer [12], but data on the actual long-term risk and risk factors are currently lacking. To prevent cancer and proctectomy/pouch excision, current guidelines advice one, two or three yearly endoscopic surveillance of the rectum and pouch including polypectomy of adenomas >5mm [13–15]. However, no recommendation is provided on choosing the most appropriate interval.

Nearly all patients with FAP will also develop adenomas in the duodenum, but only 4% to 10% duodenal cancer [16–20].

Duodenal cancer generally has a poor prognosis and is one of the most common FAP-related causes of death [21]. Regular endoscopic surveillance is advised to prevent duodenal and ampullary cancer but also to prevent total duodenectomy as this procedure is associated with high morbidity rates (Clavien-Dindo Grade III/IV in 16% to 53% of cases) [22,23]. Most current guidelines recommend a surveillance interval predominantly based on the Spigelman staging of duodenal disease (► **Table 1**), which has been shown to correlate with duodenal cancer risk [13–15,20,24,25]. Over the past decade however, concerns rise regarding several aspects of the Spigelman staging system that was developed three decades ago [24].

First of all, Spigelman stage IV is an imperfect predictor for duodenal cancer and poor predictor for ampullary cancer [26,27]. Second, the quality of endoscopy has improved over the years and high-definition endoscopes are different from the endoscopes used when the Spigelman system was developed. Detecting more adenomas with high quality endoscopes nowadays might result in higher Spigelman stages [28] while this may not reflect a higher associated cancer risk. Overestimation of Spigelman stage may also result in choosing shorter surveillance intervals potentially causing overtreatment. The Spigelman system does not provide clear indications for interventions

► **Table 1** Spigelman staging system for duodenal polyposis in FAP.

Criterion	Points		
	1	2	3
Polyp number	1–4	5–20	>20
Polyp size (mm)	1–4	5–10	>10
Histology	Tubular	Tubulovillous	Villous
Dysplasia	Mild	Moderate	Severe

Stage 0: 0 points; stage 1: 4 points; stage II: 5–6 points; stage IV: 9–12 points. Data from Spigelman et al. [24].

other than Spigelman stage IV for which it is recommended to consider endoscopic polypectomy or duodenal surgery. Although endoscopic polypectomy of duodenal adenomas has been shown to be effective in downstaging disease, there is no strong evidence that endoscopic interventions are effective in terms of reducing the actual risk of cancer and surgery. Large collaborative prospective studies with a long follow-up are needed to study the real efficacy of frequent endoscopic surveillance with polypectomies.

Moreover, the surveillance interval for the upper gastrointestinal tract should not be solely based on polyp burden in the duodenum. Gastric adenomas and cancer are a more recently recognized challenge in the management of FAP. Martin et al. found that in a cohort of 726 patients, 14% had developed one or more gastric adenomas [29]. These lesions may be challenging to detect, especially in the proximal stomach where they are often growing in between or on top of extensive fundic gland polyposis [30]. A recent study showed an alarming increase in the number of FAP patients with gastric cancer over the past years [31]. These cancers are described to develop most often in proximal stomachs carpeted with fundic gland polyps and Leone et al. reported that most of them (8/10) were not visualized at endoscopy [32].

There is a clear need for an evidence based and personalized endoscopic surveillance strategy in FAP, taking into account current literature, guidelines and limitations of existing systems. International collaboration is needed to establish and study new strategies in this rare condition. The European FAP Consortium, consisting of experts in FAP, developed consensus-based personalized endoscopic surveillance and interventions strategies for IRA/ISA, IPAA and the duodenum and stomach. We share these protocols to inform centers treating patients with FAP and to encourage discussion regarding optimization of endoscopic surveillance and treatment in FAP.

Methods

In 2019, the European FAP Consortium was established. This group exists of experts in the field of FAP including endoscopists who participated in the ESGE committee for the guideline on polyposis syndromes [13], surgeons and a statistician/epidemiologist. All recommendations on endoscopic surveillance in FAP in the ESGE guideline had a level of agreement >89% but a low quality of evidence [13]. One of the aims of this consortium is to conduct prospective studies in a large cohort of FAP patients, providing high quality evidence which is needed since most recommendations in current guidelines are based on expert opinion and small, mainly retrospective and single-center studies.

Several consortium meetings were organized in order to develop new surveillance protocols for FAP. In the first year of using the new protocols, several adjustments have been made until consensus was reached on two definitive protocols; one for the lower gastrointestinal tract for patients with IRA/ISA and IPAA and one for the upper gastrointestinal tract for duodenal and gastric polyposis. These protocols will be evaluated

in a 5-year prospective study, funded by KWF Dutch Cancer Society (NCT04678011 and NCT04677998).

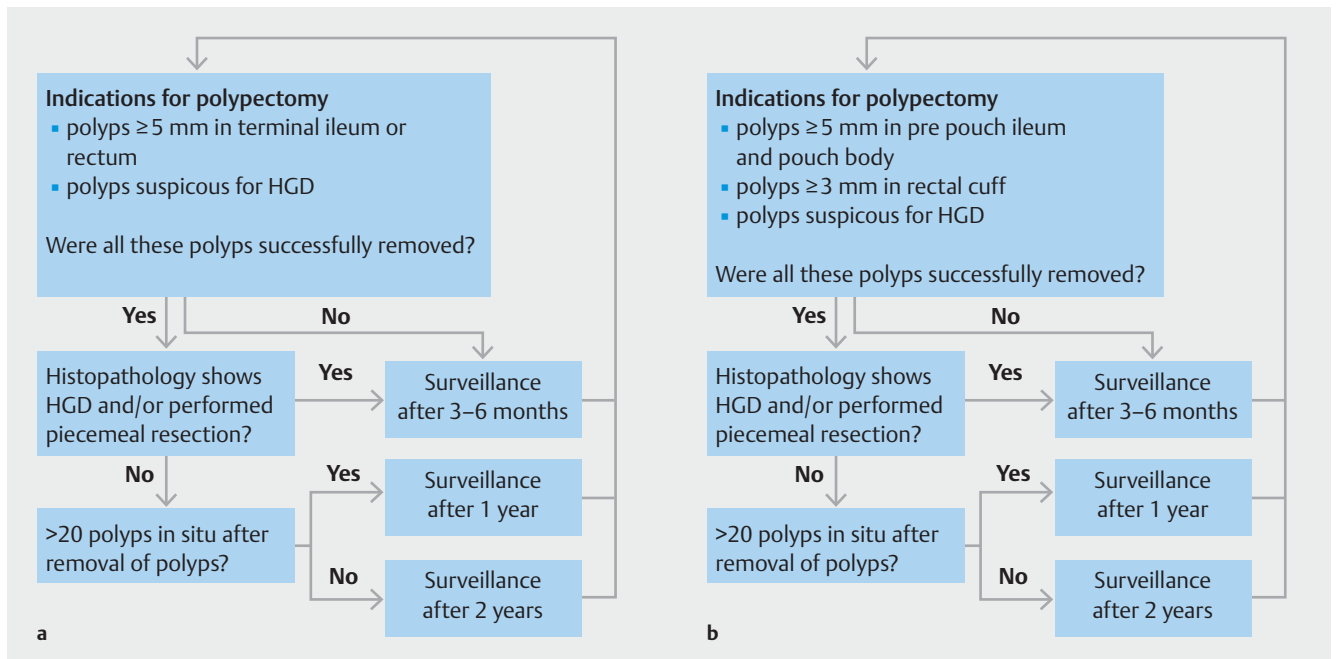
Lower gastrointestinal tract

All procedures are performed on dedicated FAP lists performed by endoscopists with expertise in FAP using high-definition endoscopes. Patients are prepared according to local policy with oral bowel preparation schedule or enema. When the Boston Bowel Preparation Score (BBPS) for one segment (rectum/pouch) is lower than two, the endoscopy is rescheduled within 6 months. A meticulous assessment is performed of the neo-terminal ileum and rectum/rectosigmoid in patients with IRA/ISA and pre-pouch ileum, pouch body and rectal cuff in patients with IPAA, including retroflexion to assess the distal rectum or rectal cuff. White-light endoscopy (WLE), virtual chromoendoscopy, such as narrow band imaging (NBI, TXI) and blue laser imaging (BLI, LCI), and dye-based chromoendoscopy may be used at the discretion of the endoscopist. Indications for polypectomy include ileal/rectal adenomas ≥ 5 mm and adenomas suspicious for containing high-grade dysplasia (HGD). As rectal cuff adenomas might be technically more difficult to remove when they grow larger, adenomas ≥ 3 mm in the rectal cuff of patients having an IPAA are removed. Cold snare polypectomy is an appropriate resection technique for most rectal/ileal adenomas but endoscopic mucosal resection (EMR), en bloc or piecemeal, and even endoscopic submucosal dissection (ESD) can be considered for larger or suspicious lesions.

Two to 4 weeks after endoscopy, an outpatient clinic or telephone appointment is scheduled to discuss findings of endoscopy/pathology and any possible adverse event with the patient and to determine the next surveillance interval. ► **Fig. 1** represents the flowcharts used for choosing the appropriate interval, which varies between 3 to 6 months and 2 years. Factors influencing the interval are degree of dysplasia, whether the resection was performed piecemeal and the number of adenomas that were left in situ after removal of polyps.

Upper gastrointestinal tract

Gastroduodenoscopy is performed with a forward-viewing endoscope, gastroscope or pediatric colonoscope, with a transparent plastic cap at the distal end. If the ampulla is not completely visualized despite using a cap, the endoscopist should also use a side-viewing endoscope [33]. Next to high-definition WLE, advanced imaging techniques may be used at the discretion of the endoscopist. However, in case of extensive gastric fundic glands, it is strongly recommended to use NBI or BLI to better distinguish adenomas from fundic gland polyps, especially in the proximal stomach [30]. NBI/BLI can facilitate delineation of the more whitish adenomas in between/on top of fundic gland polyps [30]. Indications for endoscopic polypectomy or papillectomy include: duodenal and ampullary adenomas ≥ 10 mm, an ampullary adenoma progressive in size, gastric adenomas ≥ 5 mm and any adenomas in which advanced histology is suspected based on endoscopic imaging. Moreover, when duodenal polyposis with more than 20 duodenal adenomas is present, polypectomy should be considered for duodenal adenomas ≥ 5 mm to prevent unmanageable disease in the



► **Fig. 1** a Flowchart for endoscopic surveillance of patients with IRA/ISA. b Flowchart for endoscopic surveillance of patients with IPAA.

future with too many large adenomas. With current evidence, specific recommendations on the preferred resection techniques in the duodenum and stomach cannot be provided. There are emerging data regarding the use of cold snare polypectomy to suggest that it may have a role in addition to conventional EMR [34–36]. For gastric adenomas, conventional EMR seems more appropriate since the gastric wall is thicker, especially in patients with FAP. ESD may be considered in the stomach for large adenomas or adenomas with suspicious aspect [29]. However, larger adenomas are mostly located in the proximal stomach and the co-existence of multiple fundic gland polyps may result in a challenging and long-lasting procedure that might not always be technically feasible. Prophylactic clipping and post-endoscopy admission for observation after removal of large adenomas, i. e. >20 mm, may be considered. Random biopsies are not routinely taken from the duodenum, neither from the ampulla or stomach. Biopsies are only indicated in case of a suspicion of cancer or when the lesion is not amenable to endoscopic resection, to support decision making for the right type and timing of duodenal surgery.

Surveillance intervals are chosen based on the new flowchart shown in ► **Fig. 2**. The next interval is determined based on whether polypectomy or papillectomy was performed, the grade of dysplasia, whether there are still lesions in situ with an indication for removal, the presence of gastric adenomas and the number and size of duodenal adenomas that are left in situ. As mentioned earlier, the number and the villous component of duodenal adenomas are not predictors for duodenal cancer. Therefore, the villous component is removed in our strategy. However, the number of duodenal adenomas may still influence the surveillance interval, as we aim to prevent endo-

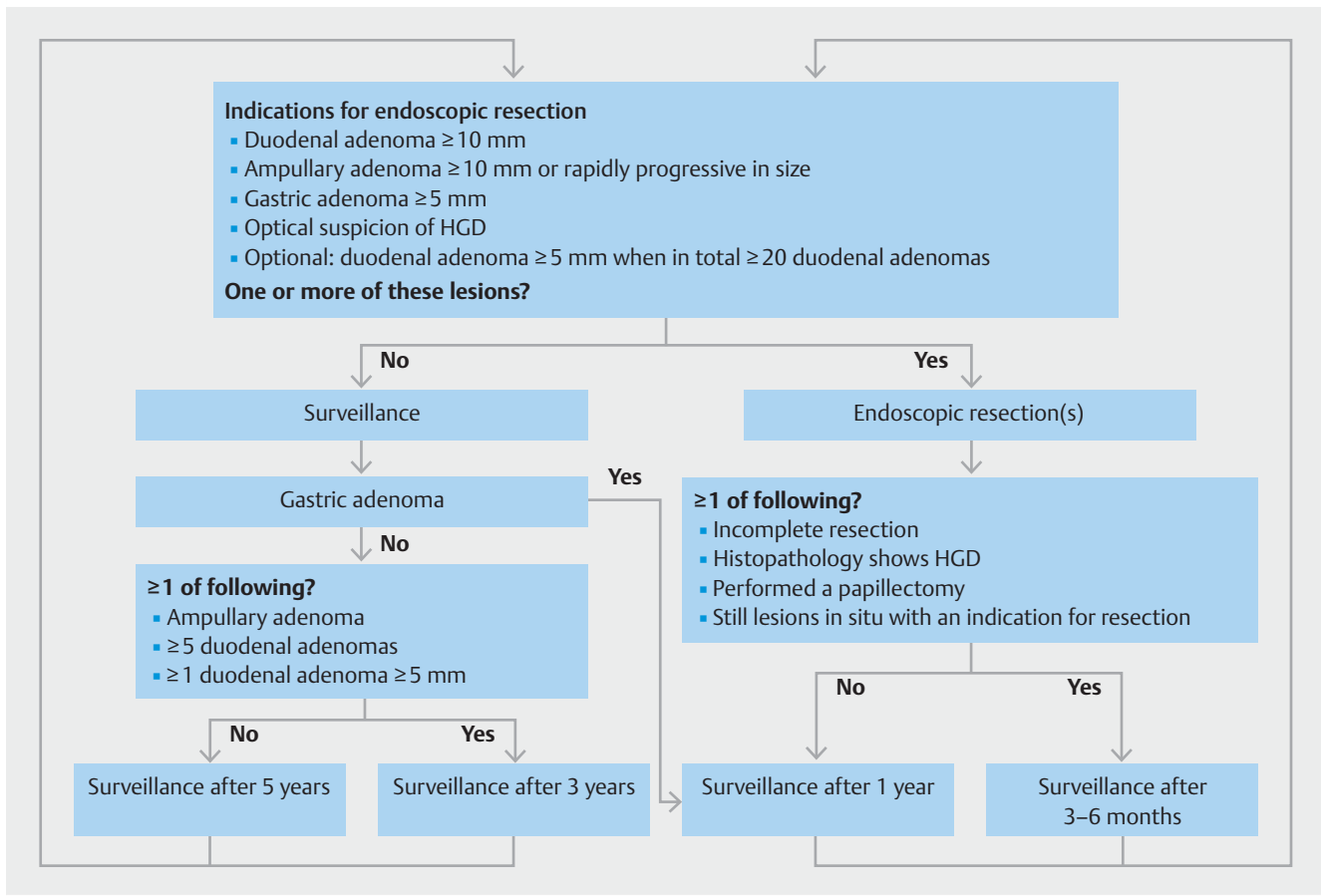
scopically unmanageable disease in the future due to the presence of too many large adenomas.

Evaluation

This new endoscopic surveillance strategy will be prospectively evaluated within the affiliated centers of the European FAP Consortium. An online database (Castor EDC) is used to collect endoscopic findings, collect outcomes of polypectomies and papillectomies and keep track of complications. To evaluate the efficacy of this new endoscopic surveillance strategy, we will report the incidence of HGD, cancer and indication for surgery due to unmanageable polyposis after 5 years as the primary outcome. All adenomatous lesions containing HGD and all cancers will be centrally revised by an expert gastrointestinal pathologist in Amsterdam UMC. The new surveillance strategy will be considered effective when $<5\%$ of patients develop HGD/cancer or have an indication for surgery due to unmanageable polyposis within 5 years. Secondly, data on the size and location of adenomas will be collected as well as outcomes of different endoscopic resection techniques.

Discussion

We present a newly developed consensus-based personalized endoscopic surveillance strategy for patients with FAP, aiming to reduce the incidence of cancer as well as the number of surgical interventions. This strategy was established based on current literature and guidelines, outcomes of existing staging systems and opinions and consensus of experts in the field of FAP. The efficacy and safety will be evaluated in a 5-year prospective study.



► Fig. 2 Flowchart for endoscopic surveillance of the duodenum and stomach.

Traditionally, most guidelines advised yearly endoscopic surveillance of the rectum/pouch after colectomy. This was pushed toward 1 to 2 yearly in more recent guidelines, and to 1 to 3 yearly in the British guideline [13–15]. While phenotypes vary greatly between individuals with FAP, no recommendations are provided on choosing the right surveillance interval of these options for an individual. To our knowledge, the only validated staging system for the lower gastrointestinal tract is the InSiGHT polyposis staging system (IPSS) for both pre- and post-colectomy patients [37]. Based on the number and size of polyps, the grade of dysplasia and the possibility for complete removal, patients will be allotted a stage from 0 to 4. For every stage, there are different management advices. The IPSS was developed after a statement of the US Food and Drug Administration stating that chemoprevention studies in FAP require endpoints measuring a clinical benefit of the treatment. As such, the IPSS was developed for chemoprevention trial purposes and may be less suitable for daily clinical practice, for which currently no staging systems/protocols exist.

In our protocol we did not choose for intervals longer than 2 years. Patients with ISA/IRA typically require regular polypectomies and a longer interval (>2 years) between endoscopies might result in surveillance procedures with multiple (piecemeal) polypectomies with higher complication risk, longer procedures and potentially a higher risk of secondary proctectomy

due to endoscopically unmanageable disease. A concern in patients with IPAA is the risk of missing lesions during endoscopy, both in the pouch body and in the rectal cuff in patients with a stapled anastomosis. Ileal adenomas may more often have a flat morphology and Friederich et al. showed that carcinomas were detected even after a recent surveillance endoscopy in patients with IPAA [8]. In this study, the median time between the diagnosis of pouch carcinoma and previous surveillance endoscopy was 25 months [9]. Therefore, we chose 2 years as longest interval between surveillance endoscopies, also for patients with IPAA.

We decided to advise to use high-definition WLE, and leave the use of advanced imaging techniques for the rectum, pouch, stomach and duodenum to the discretion of the endoscopist. Using chromoendoscopy may lead to better detection of small adenomas in the rectum, pouch and duodenum [9, 38–41]. Detecting more tiny adenomas may not be clinically relevant in a condition like FAP. However, in a recent study, dye-based chromoendoscopy resulted in higher detection rates of duodenal adenomas > 10 mm compared to WLE [39]. The additive value of virtual chromoendoscopy (such as NBI, TXI, BLI and LCI), which might be a suitable less time-consuming alternative to dye-based chromoendoscopy, was not evaluated in this study. This is why we chose to not recommend routine use of dye-

based chromoendoscopy in upper and lower gastrointestinal endoscopies but to leave it to the discretion of the endoscopist.

Concerning the removal of rectal and pouch polyps, we do not provide specific guidance on when to use cold snare polypectomy and when EMR. Cold snare polypectomy is the preferred technique for small colorectal adenomas and therefore widely used in patients with FAP [42]. Since there is an indication for polypectomy from 5 mm, we expect most polyps to be suitable for CSP. EMR can be considered especially when lesions are larger than 10 mm or those with a suspicion of advanced histology.

Endoscopic polypectomy in the duodenum is associated with a considerable complication risk (delayed bleeding 13% to 20%; perforation 2% to 3%) [43, 44]. Endoscopic papillectomy has an additional 15% risk of pancreatitis [45]. The risk of polypectomy in the stomach seems lower, with complications in 5% of patients [29]. Recent guidelines recommend to endoscopically resect duodenal and ampullary adenomas > 10 mm [13] and Martin et al. advises to remove gastric adenomas > 5 mm [29]. The risk of complications may be related to the resection technique. Due to the lack of studies and absence of randomized studies, we do not provide a clear recommendation on the preferred resection technique for duodenal polyps. In two studies in FAP patients, different techniques for removal of duodenal polyps such as cold snare polypectomy, conventional EMR, argon plasma coagulation (APC) and laser therapy were used but not compared [43, 44]. In another study in 10 patients with FAP, 332 cold snare polypectomies were performed for adenomas mostly < 10 mm. Whereas one patient had an intra-procedural arterial bleeding managed directly with hemoclips, no serious adverse events occurred [34]. Another study in 43 patients with sporadic duodenal adenomas with size ranging from 10 to 70 mm confirmed the safety of cold snare polypectomy as only one patient had a postprocedural bleeding [35]. Trivedi et al. showed that delayed bleedings more often occurred after hot snare polypectomy than after cold snare polypectomy [36]. Based on this evidence, we believe that (piecemeal) cold snare polypectomy with or without submucosal injection is a suitable resection technique for most duodenal polyps, especially in patients with FAP in which often multiple polyps are removed during the same procedure. We discourage the use of APC or other ablative techniques as primary treatment in the colon and duodenum due to the high recurrence rate [47–48]. To provide more firm and clear recommendations on the preferred endoscopic resection technique for duodenal adenomas, larger and randomized studies are needed.

Latchford et al. studied eleven patients with ampullary cancer and demonstrated a median Spigelman stage of only II [26] in these patients, and Thiruvengadam et al. showed that 6/9 (66.7%) of patients with duodenal cancer had a history of Spigelman stage IV, which was only in 2/8 (25%) for those with ampullary cancer [27]. In these studies, size and grade of dysplasia of duodenal/ampullary adenomas were found to be predictive for cancer, rather than the number and villosity of polyps. Currently, many endoscopists do not include ampullary findings in the Spigelman stage, which might explain the development of ampullary cancer in patients with lower Spigelman

stages. Therefore, we believe that ampullary findings should be incorporated in the new surveillance strategy. In our protocol, indications for endoscopic papillectomy include an ampulla ≥ 10 mm and/or an ampulla rapidly progressive in size. Our policy is not to routinely perform biopsies from the ampulla. Although the risk of pancreatitis following biopsies of the ampulla is low at 0.73% [49], the clinical consequences can be vast. Besides, an optical assessment of the ampulla seems to be accurate in the majority of cases and the risk of HGD or cancer, which might have clinical consequences, very low. For 546 biopsies of normal appearing ampullas, pathology showed indeed normal ampullary tissue in 92.1%, LGD in 7.7% and focal HGD in only 0.18%. Of the 226 abnormal-appearing ampullas, 94.2% indeed had dysplasia including 5.44% containing HGD and 0.44% carcinoma [50]. The risk of HGD or cancer will probably be even lower in lesions < 10 mm, which do not have an indication for resection as per protocol. Moreover, the accuracy of ampullary biopsies varies between 38–85% with underestimation as well as overestimation and therefore biopsies are quite unreliable for decision making in treatment strategies [50, 51].

We also do not advise to routinely biopsy duodenal polyps to require histopathology during every endoscopy, as is currently the case to be able to calculate the Spigelman score. Repeatedly taking biopsies may cause fibrosis which might hamper future polypectomy. Moreover, HGD and cancer is rare in duodenal adenomas < 10 mm, as all resected duodenal adenomas < 10 mm in Roos et al. contained low-grade dysplasia only [44]. Therefore, we presume it is safe to refrain from taking biopsies until there is an indication for polypectomy based on size.

By developing surveillance protocols for rectal, pouch, duodenal and gastric polyposis, we cover the endoscopic management of most FAP patients. However, we have not yet developed protocols for patients with a colon in situ or for patients who have undergone total duodenectomy. The upper gastrointestinal protocol might still be used for patients after segmental duodenal resection, but the altered anatomy after pancreatoduodenectomy or pancreas-preserving total duodenectomy might require a different strategy for the management of jejunal polyps. Moreover, to be able to evaluate the efficacy of our protocols we only include patients in which it is possible to resect all polyps with an indication for polypectomy at baseline. Thereby, patients with severe rectal, pouch or duodenal polyposis which is not amenable for endoscopic clearing will not be included in this study as they already reached the primary endpoint at the start of the study.

We will prospectively assess the safety and effectiveness of our strategies in a single-arm study and consider the surveillance protocol effective when < 5% of patients develop HGD, cancer or have an indication for surgery due to unmanageable polyposis within 5 years. The single-arm design does not allow us to compare the new strategy to the current standard of care. For the lower gastrointestinal tract, there is no existing protocol for daily care. For the upper gastrointestinal tract, we could potentially compare our new protocol to the existing Spigelman protocol. However, because we developed our new strategy based on pros and cons of the Spigelman system and it, there-

fore, could be seen as an updated Spigelman system, we chose not to withhold our patients from the new strategy. If our strategy is considered safe and effective after 5 years, we aim to continue evaluating the protocols to obtain longer term data.

Conclusions

By systematically collecting findings of endoscopic surveillance in a large, prospective cohort of FAP patients, we will be able to study the safety and efficacy of our new surveillance and intervention strategy. Besides, we will learn more about the natural course of lower and upper gastrointestinal polyposis and outcomes of different endoscopic resection techniques. We believe that these findings will be of value for future, more personalized guidelines on surveillance and treatment of patients with FAP.

Competing interests

Arthur S. Aelvoet: none to declare. Maria Pellise: endoscopic equipment on loan of Fujifilm, research grant from Fujifilm, ZiuZ and Casen Recordati, consultancy for Fujifilm, Olympus and speakers' fee from Olympus, Medtronic and Fujifilm. Barbara A.J. Bastiaansen: speakers' fee from Olympus, Tillotts Pharma AG and Ovesco Endoscopy AG. Monique van Leerdam: none to declare. Rodrigo Jover: consultancy for CPP Pharmaceuticals. Francesc Balaguer: FB has received an honorarium for consultancy from Sysmex and CPP Pharmaceuticals, speaker's fees from Norgine, and editorial fee from Elsevier. Michal Kaminski: speaker's fee from Olympus, Fujifilm, Boston Scientific, Medtronic, AlfaSigma, IPSEN, consultancy fee from Olympus, ERBE, AlfaSigma. John G. Karstensen: JGK received honorarium from SNIPR BIOME and AMBU and speakers fee from Norgine. Jean-Christophe Saurin: Consultancy for Janssen Pharmaceuticals. Roel Hompes: none to declare. Patrick M.M. Bossuyt: none to declare. Luigi Ricciardiello: consultancy and unrestricted research grant from SLA Pharma AG. Andrew Latchford: non to declare. Evelien Dekker: endoscopic equipment on loan of Fujifilm and Olympus, research grant from Fujifilm, consultancy for Fujifilm, Olympus, Tillotts, GI Supply, CPP-FAP, PAION and Ambu, and speakers' fee from Olympus, Roche, GI Supply, Norgine, IPSEN, PAION and Fujifilm.

Funding

KWF Kankerbestrijding 13676
<http://dx.doi.org/10.13039/501100004622>

Clinical trial

ClinicalTrials.gov
 NCT04678011
 ClinicalTrials.gov
 NCT04677998

TRIAL REGISTRATION: Prospective multi-center study NCT04678011 and NCT04677998 at ClinicalTrials.gov (<http://www.clinicaltrials.gov/>)

References

- [1] Grover S, Kastrinos F, Steyerberg EW et al. Prevalence and phenotypes of APC and MUTYH mutations in patients with multiple colorectal adenomas. *JAMA* 2012; 308: 485–492
- [2] Bussey HJR. *Familial polyposis coli: family studies, histopathology, differential diagnosis and results of treatment.* Baltimore: John Hopkins University Press; 1975
- [3] Tudyka VN, Clark SK. Surgical treatment in familial adenomatous polyposis. *Ann Gastroenterol* 2012; 25: 201–206
- [4] Church J, Burke C, McGannon E et al. Risk of rectal cancer in patients after colectomy and ileorectal anastomosis for familial adenomatous polyposis: a function of available surgical options. *Dis Colon Rectum* 2003; 46: 1175–1181
- [5] Sinha A, Tekkis PP, Rashid S et al. Risk factors for secondary proctectomy in patients with familial adenomatous polyposis. *Br J Surg* 2010; 97: 1710–1715
- [6] Pasquer A, Benech N, Pioche M et al. Prophylactic colectomy and rectal preservation in FAP: systematic endoscopic follow-up and adenoma destruction changes natural history of polyposis. *Endosc Int Open* 2021; 9: E1014–e1022
- [7] Anele CC, Xiang J, Martin I et al. Regular endoscopic surveillance and polypectomy is effective in managing rectal adenoma progression following colectomy and ileorectal anastomosis in patients with familial adenomatous polyposis. *Colorectal Dis* 2021; 24: 277–283
- [8] Tajika M, Niwa Y, Bhatia V et al. Risk of ileal pouch neoplasms in patients with familial adenomatous polyposis. *World J Gastroenterol* 2013; 19: 6774–6783
- [9] Friederich P, de Jong AE, Mathus-Vliegen LM et al. Risk of developing adenomas and carcinomas in the ileal pouch in patients with familial adenomatous polyposis. *Clin Gastroenterol Hepatol* 2008; 6: 1237–1242
- [10] Aelvoet AS, Roos VH, Bastiaansen BAJ et al. Development of ileal adenomas after ileal pouch-anal anastomosis versus end ileostomy in patients with familial adenomatous polyposis. *Gastrointest Endosc* 2023; 97: 69–77.e1
- [11] Smith JC, Schäffer MW, Ballard BR et al. Adenocarcinomas after prophylactic surgery for familial adenomatous polyposis. *J Cancer Ther* 2013; 4: 260–270
- [12] Worley GHT, Patsouras D, Sahnun K et al. Ileal pouch excision: a contemporary observational cohort. *Dis Colon Rectum* 2019; 62: 454–462
- [13] van Leerdam ME, Roos VH, van Hooft JE et al. Endoscopic management of polyposis syndromes: European Society of Gastrointestinal Endoscopy (ESGE) Guideline. *Endoscopy* 2019; 51: 877–895
- [14] Monahan KJ, Bradshaw N, Dolwani S et al. Guidelines for the management of hereditary colorectal cancer from the British Society of Gastroenterology (BSG)/Association of Coloproctology of Great Britain and Ireland (ACPGBI)/United Kingdom Cancer Genetics Group (UKCGG). *Gut* 2020; 69: 411–444
- [15] Yang J, Gurudu SR, Koptiuch C et al. American Society for Gastrointestinal Endoscopy guideline on the role of endoscopy in familial adenomatous polyposis syndromes. *Gastrointest Endosc* 2020; 91: 963–982.e962
- [16] Björk J, Akerbrant H, Iselius L et al. Periampullary adenomas and adenocarcinomas in familial adenomatous polyposis: cumulative risks and APC gene mutations. *Gastroenterology* 2001; 121: 1127–1135
- [17] Bülow S, Christensen IJ, Højen H et al. Duodenal surveillance improves the prognosis after duodenal cancer in familial adenomatous polyposis. *Colorectal Dis* 2012; 14: 947–952
- [18] Lepistö A, Kiviluoto T, Halttunen J et al. Surveillance and treatment of duodenal adenomatosis in familial adenomatous polyposis. *Endoscopy* 2009; 41: 504–509

- [19] Wallace MH, Phillips RK. Upper gastrointestinal disease in patients with familial adenomatous polyposis. *Br J Surg* 1998; 85: 742–750
- [20] Groves CJ, Saunders BP, Spigelman AD et al. Duodenal cancer in patients with familial adenomatous polyposis (FAP): results of a 10 year prospective study. *Gut* 2002; 50: 636–641
- [21] Ghorbanoghli Z, Bastiaansen BA, Langers AM et al. Extracolonic cancer risk in Dutch patients with APC (adenomatous polyposis coli)-associated polyposis. *J Med Genet* 2018; 55: 11–14
- [22] Walsh RM, Augustin T, Aleassa EM et al. Comparison of pancreas-sparing duodenectomy (PSD) and pancreatoduodenectomy (PD) for the management of duodenal polyposis syndromes. *Surgery* 2019; 166: 496–502
- [23] Aelvoet AS, Bastiaansen BAJ, Fockens P et al. Pancreas-preserving total duodenectomy for advanced duodenal polyposis in patients with familial adenomatous polyposis: short and long-term outcomes. *HPB (Oxford)* 2022; 24: 1642–1650
- [24] Spigelman AD, Williams CB, Talbot IC et al. Upper gastrointestinal cancer in patients with familial adenomatous polyposis. *Lancet* 1989; 2: 783–785
- [25] Bulow S, Bjork J, Christensen IJ et al. Duodenal adenomatosis in familial adenomatous polyposis. *Gut* 2004; 53: 381–386
- [26] Latchford AR, Neale KF, Spigelman AD et al. Features of duodenal cancer in patients with familial adenomatous polyposis. *Clin Gastroenterol Hepatol* 2009; 7: 659–663
- [27] Thiruvengadam SS, Lopez R, O'Malley M et al. Spigelman stage IV duodenal polyposis does not precede most duodenal cancer cases in patients with familial adenomatous polyposis. *Gastrointest Endosc* 2019; 89: 345–354.e342
- [28] Mathus-Vliegen EM, Boparai KS, Dekker E et al. Progression of duodenal adenomatosis in familial adenomatous polyposis: due to ageing of subjects and advances in technology. *Fam Cancer* 2011; 10: 491–499
- [29] Martin I, Roos VH, Anele C et al. Gastric adenomas and their management in familial adenomatous polyposis. *Endoscopy* 2021; 53: 795–801
- [30] Roos VH, Bastiaansen BAJ, Dekker E. Gastric adenomas in familial adenomatous polyposis: you only see them when you know what to look for. *Gastrointest Endosc* 2018; 88: 403–405
- [31] Mankaney G, Leone P, Cruise M et al. Gastric cancer in FAP: a concerning rise in incidence. *Fam Cancer* 2017; 16: 371–376
- [32] Leone PJ, Mankaney G, Sarvapelli S et al. Endoscopic and histologic features associated with gastric cancer in familial adenomatous polyposis. *Gastrointest Endosc* 2019; 89: 961–968
- [33] Kallenberg FGJ, Bastiaansen BAJ, Dekker E. Cap-assisted forward-viewing endoscopy to visualize the ampulla of Vater and the duodenum in patients with familial adenomatous polyposis. *Endoscopy* 2017; 49: 181–185
- [34] Hamada K, Takeuchi Y, Ishikawa H et al. Safety of cold snare polypectomy for duodenal adenomas in familial adenomatous polyposis: a prospective exploratory study. *Endoscopy* 2018; 50: 511–517
- [35] Dang DT, Suresh S, Vance RB et al. Outcomes of cold snare piecemeal EMR for nonampullary small-bowel adenomas larger than 1 cm: a retrospective study. *Gastrointest Endosc* 2022; 95: 1176–1182
- [36] Trivedi M, Klapheke R, Youssef F et al. Comparison of cold snare and hot snare polypectomy for the resection of sporadic nonampullary duodenal adenomas. *Gastrointest Endosc* 2022; 96: 657–664.e652
- [37] Lynch PM, Morris JS, Wen S et al. A proposed staging system and stage-specific interventions for familial adenomatous polyposis. *Gastrointest Endosc* 2016; 84: 115–125.e114
- [38] Hurley JJ, Thomas LE, Walton SJ et al. The impact of chromoendoscopy for surveillance of the duodenum in patients with MUTYH-associated polyposis and familial adenomatous polyposis. *Gastrointest Endosc* 2018; 88: 665–673
- [39] Hüneburg R, Heling D, Kaczmarek DJ et al. Dye chromoendoscopy leads to a higher adenoma detection in the duodenum and stomach in patients with familial adenomatous polyposis. *Endosc Int Open* 2020; 8: E1308–E1314
- [40] Dekker E, Boparai KS, Poley JW et al. High resolution endoscopy and the additional value of chromoendoscopy in the evaluation of duodenal adenomatosis in patients with familial adenomatous polyposis. *Endoscopy* 2009; 41: 666–669
- [41] Matsumoto T, Esaki M, Fujisawa R et al. Chromoendoscopy, narrow-band imaging colonoscopy, and autofluorescence colonoscopy for detection of diminutive colorectal neoplasia in familial adenomatous polyposis. *Dis Colon Rectum* 2009; 52: 1160–1165
- [42] Shinozaki S, Kobayashi Y, Hayashi Y et al. Efficacy and safety of cold versus hot snare polypectomy for resecting small colorectal polyps: Systematic review and meta-analysis. *Dig Endosc* 2018; 30: 592–599
- [43] Moussata D, Napoleon B, Lepilliez V et al. Endoscopic treatment of severe duodenal polyposis as an alternative to surgery for patients with familial adenomatous polyposis. *Gastrointest Endosc* 2014; 80: 817–825
- [44] Roos VH, Bastiaansen BA, Kallenberg FGJ et al. Endoscopic management of duodenal adenomas in patients with familial adenomatous polyposis. *Gastrointest Endosc* 2021; 93: 457–466
- [45] Ramai D, Facciorusso A, Singh J et al. Endoscopic management of ampullary adenomas in familial adenomatous polyposis syndrome: a systematic review with pooled analysis. *Dig Dis Sci* 2022; 67: 3220–3227
- [46] Jaganmohan S, Lynch PM, Raju RP et al. Endoscopic management of duodenal adenomas in familial adenomatous polyposis – a single-center experience. *Dig Dis Sci* 2012; 57: 732–737
- [47] Moss A, Bourke MJ, Williams SJ et al. Endoscopic mucosal resection outcomes and prediction of submucosal cancer from advanced colonic mucosal neoplasia. *Gastroenterology* 2011; 140: 1909–1918
- [48] Navaneethan U, Lourdasamy D, Mehta D et al. Endoscopic resection of large sporadic non-ampullary duodenal polyps: efficacy and long-term recurrence. *Surg Endosc* 2014; 28: 2616–2622
- [49] Mehta NA, Shah RS, Yoon J et al. Risks, benefits, and effects on management for biopsy of the papilla in patients with familial adenomatous polyposis. *Clin Gastroenterol Hepatol* 2021; 19: 760–767
- [50] Laleman W, Verreth A, Topal B et al. Endoscopic resection of ampullary lesions: a single-center 8-year retrospective cohort study of 91 patients with long-term follow-up. *Surg Endosc* 2013; 27: 3865–3876
- [51] Kimchi NA, Mindrul V, Broide E et al. The contribution of endoscopy and biopsy to the diagnosis of periampullary tumors. *Endoscopy* 1998; 30: 538–543