

Aesthetic Surgical Pathway in Permanent Facial Filler Removal

Michele Pascali, MD, PhD¹ Fabrizio Chirico, MD, MSc² Luigi Rugge, MD³ Raffaele Rauso, MD, PhD, MSc⁴

¹Department of Plastic and Reconstructive Surgery, University of Rome Tor Vergata, Roma, Lazio, Italy

²Department of Maxillo Facial Surgery, University of Rome La Sapienza, Rome, Lazio, Italy

³Private Practice - Maxillo Facial Unit, Naples, Italy

⁴Department of Cranio-maxillo Facial Surgery, Private Hospital 'L. Cobellis', Vallo Della Lucania (SA), Italy

Address for correspondence Fabrizio Chirico, MD, MSc, Department of Maxillo Facial Surgery, University of Rome La Sapienza, Rome, Lazio, Italy (e-mail: fabriziochirico@hotmail.com).

Facial Plast Surg 2024;40:19–30.

Abstract

Although permanent fillers have been introduced in order to get long-lasting results, many studies have shown numerous severe and disfiguring complications. Nonsurgical procedures may mitigate those adverse events but the only way to remove the filler previously injected is represented by surgical excision. We present a pathway of facial surgical accesses to be performed achieving two goals: permanent filler removal and restore facial aesthetic balance. The proposed surgical accesses are already standardized in aesthetic surgical practice in order to avoid direct excision and unpleasant facial scar. A total of 231 patients underwent surgery for permanent filler removal and aesthetic restoration of the involved facial area, represented by forehead, glabella, nose, cheeks, eyelids, chin, jawline, and lips. Magnetic resonance evaluation was performed with the exception of lip patients who were evaluated with ultrasound. Postoperative follow-up was 12 months to 6 years. Subjective and objective methods were used for outcome evaluation according to the FACE-Q questionnaire. Functional and aesthetic correction was scored using the patient-graded Global Aesthetic Improvement Scale (GAIS), overall patient satisfaction was assessed by a five-point scale questionnaire. Functional and aesthetic restoration was globally recognized as improved according to the GAIS. Patients reported high levels of satisfaction assessed by a five-point scale questionnaire. A very good satisfaction level was registered in both subjective and objective judgment scores. To the best of our knowledge, we present the largest case series regarding surgical removal of permanent facial fillers. A proper preoperative evaluation, filler removal followed by restorative facial aesthetic surgery technique is paramount to approach challenging cases.

Keywords

- ▶ permanent filler
- ▶ filler removal
- ▶ filler complications
- ▶ facial reconstruction
- ▶ aesthetic surgery

Soft tissue augmentation with fillers has become increasingly popular for restoration of facial folds, wrinkles, volume, and contour. Several nonbiodegradable fillers, such as silicone oil, polyacrylamide hydrogel, and polymethylmethacrylate (PMMA), have been introduced in order to get long-lasting results.¹ The main reason for patients asking permanent fillers instead of resorbable

ones, such as hyaluronic acid (HA), is related to the willingness to avoid repeated injections, although it has been clearly shown in literature that the only fillers than can be reversed by the use of an antidote are the HA-based ones.^{1,2} Even though some studies have indicated permanent fillers as well tolerated with desirable aesthetic results and few complications, conversely many case

reports have shown numerous adverse events.³ Erythema, edema, bruising, infection, hypersensitivity, discoloration, and vascular occlusion can be detected with all type of fillers as HA, calcium hydroxyapatite, PMMA, and poly-L-lactic acid, however, a feature not often considered and underestimated related to permanent substances, is the unpleasant appearance that may be achieved after some years after implantation.^{4,5} Aging process modify facial anatomy, skeleton resorption, and fat pads atrophy induces progressive tissue ptosis. For the same reason, also a permanent filler injected with transitory good result, years after implantation may induce a worsening of facial appearance during the aging process, creating a drooping/bulging effect.^{5,6} In addition to the aging process of facial structures, permanent fillers may also develop delayed complications such as migration, granuloma, lumps, and/or abscesses.^{3,5} For these reasons, many patients are not satisfied with the long-term results following nonresorbable filler injections and years after implantation request removal of the products.^{3,5,7-11} The use of permanent fillers is totally or partially forbidden in some European countries such as the Netherland and Poland, especially for the challenge to face their surgical removal.¹² Several nonsurgical managements have been introduced to treat permanent filler complications, as systemic antibiotic therapy, intralesional injections of corticosteroid, and/or 5-fluorouracil, needle aspiration, surgical drainage, and laser therapy,⁷⁻¹¹ although none of those techniques is able to totally remove previously injected permanent fillers. The mainstay for a proper preoperative filler-removal evaluation is magnetic resonance imaging (MRI).¹³ Ultrasonographic evaluation may give information related to the facial location of the filler and regarding the type of filler injected, although only the MRI let the surgeon to clearly evaluate the relationship between the fillers and the surrounding tissues such as muscles, fat compartments, and fascia layers.^{13,14} A careful preoperative evaluation is mandatory to reduce the risk of facial nerve damaging, a main issue why surgeons usually refuse to perform these surgical procedures. Although nonsurgical procedures may solve and/or mitigate permanent fillers complications, the only way to remove the filler previously injected is represented by surgical excision.^{8,15-19} A very poor literature is present about this topic, only some reports of permanent filler surgical removal have been published, especially focusing on lips area.^{3,5,18,19} Permanent filler removal with direct excision induce visible and unpleasant scar. We present a pathway of facial surgical accesses to be performed in order to remove permanent fillers previously injected with hidden access achieving two goals: permanent filler removal and facial aesthetic balance restoration. The proposed surgical accesses are already widely accepted and standardized in aesthetic surgical practice²⁰⁻²⁵ and guarantee the possibility of filler removal with no need of a “direct approach” cutting “over the filler.” This allows to have a minimal donor site and contextually lets to perform a lifting of the area “loaded” by the previously injected filler.

Table 1 Amount of filling treatment performed among the champion pool

Type of treatment	Male	Female
Lip filling	0	124
Tear trough filling	13	146
Forehead filling	3	78
Zygoma filling	0	90
Chin filling	5	6
Mandible filling	5	34
Rhinofilling	17	136

Methods

Patients and Clinical Data

Between January 2010 and January 2021, 231 patients underwent surgery for permanent filler removal and aesthetic restoration. Mean age was 45 years (range, 29–63 years), 90% (208 patients) were women, and 10% (23 patients) were men. All patients showed bulging of previously injected area, sometimes with tissutal induration. The involved areas were represented by forehead, glabella, nose, cheeks, eyelids, nasolabial folds, chin, jawline, and lips (► **Table 1**). Many of these 231 patients had multiple injected sites. A total of 134 patients (58%) were referred to us after being treated elsewhere with laser treatment claiming no improvement of the aesthetic balance of the area.

This study has been performed in accordance with the Declaration of Helsinki ethical standards or comparable ethical standards. Written consent was provided to the use and analysis of patient data. Smoker patients (35%, 81 patients) were asked to quit for at least 1 month, before and after surgery. Position, facial expression, focal distance, and camera settings were standardized. Most of the patients were evaluated with MRI examination to retrieve information about type, amount, and location of the product. Fifty-two cases, only lips cases, were operated on just following ultrasound (US) examination. The purpose of all the operations was not just filler removal: the surgery was performed to get both filler removal and restore the aesthetic balance of the previously injected area performing facial plastic surgery procedures (► **Table 2**). All patients gave informed consent for the treatment performed. The postoperative follow-up was 12 months to 6 years (average 24 months).

Radiological Evaluation

MRI was performed with a 1.5-T unit (Intera 1.5T; Philips Medical Systems, Best, the Netherlands). The scan protocol, excluding 52 patients investigated with US examination for lip filler removal, comprised axial and sagittal T1-weighted fast spin-echo images; axial and sagittal T2-weighted fast spin-echo images with fat-selective presaturation (T2 spectral presaturation with inversion recovery [SPIR]); and delayed contrast-enhanced axial and sagittal T1-weighted fast spin-echo images with fat saturation (T1 SPIR) after

Table 2 Surgical procedures performed per anatomical region

Anatomical region	Surgical procedure
Forehead	81 Forehead lift
	45 Frontal myotomy
Upper eyelid	64 Upper blepharoplasty
	39 Brow lift
Lower eyelid	109 Lower blepharoplasty
	84 Adamson's flap
	56 Canthopexy
	28 Canthoplasty
	95 Lipofilling
Nose	132 Rhinoplasty
Lips	75 Lip lift
	15 V-Y frenuloplasty
	60 Cheiloplasty
Cheeks	105 Facelifts
	19 Midface lift
Chin	11 Genioplasty
Lower jaw	105 Necklifts
	76 Platysmoplasty
	15 Digastric muscle reduction

intravenous administration of gadolinium. T2-weighted images were used to demonstrate the location of the filler material. Both before and after gadolinium administration, T1-weighted images were used to visualize possible abscess-

Table 3 FACE-Q questionnaire

Question	Answer
Age	Age
Satisfaction with facial appearance overall ^a	0 (very bad) to 10 (very good)
Satisfaction with cheeks ^a	0 (very bad) to 10 (very good)
Appraisal of nasolabial folds ^a	0 (very bad) to 10 (very good)
Satisfaction with lower face and jaw line ^a	0 (very bad) to 10 (very good)
Satisfaction with nose appearance ^a	0 (very bad) to 10 (very good)
Appraisal of area under chin ^a	0 (very bad) to 10 (very good)
Appraisal of the neck ^a	0 (very bad) to 10 (very good)
Social function	0 (very bad) to 10 (very good)
Psychological well-being	0 (very bad) to 10 (very good)
Satisfaction with functional outcome	0 (very bad) to 10 (very good)
Satisfaction with aesthetic outcome	0 (very bad) to 10 (very good)
Aging appraisal VAS (y)	Age
Satisfaction with decision	0 (very bad) to 10 (very good)
Satisfaction with scar quality ^a	0 (very bad) to 10 (very good)
Scar extension correspond to expectations ^a	0 (opposite to expectation) to 10 (equal to expectations)

Abbreviation: VAS, visual analogue scale.

^aSimilar question to the expert jury.

es or phlegmonous inflammation. Filler deposits were visible as hyperintense collections on T2-weighted images.

Outcome Measures

Subjective and objective methods were used to evaluate the results of the operations. The subjective method was self-assessment questionnaire 12 months postoperatively, once the surgical results were considered stable. The objective method was instead a questionnaire for the evaluation of preoperative and postoperative photographs by an expert jury. Nine questions were asked about the overall facial appearance. The authors considered the FACE-Q as a valid tool for the evaluation of patient satisfaction and outcomes by both patients and a four-member jury consisting of one plastic surgeon and three maxillofacial surgeons (► **Table 3**). Furthermore, considering the focus of this article, a specific section was added to assess the postoperative aesthetic appearance and functional outcomes following surgery. Twelve months following last treatment, aesthetic correction, patient satisfaction, and adverse events were evaluated. Aesthetic and functional correction (volume replacement, scarring, and atrophy) was scored using the patient-graded Global Aesthetic Improvement Scale (GAIS) (► **Table 4**), overall patient satisfaction was evaluated using a questionnaire with a five-point scale (► **Table 5**).

Adverse events including pain, edema, bruising, infection, nodule formation, calcification, and persistent asymmetry were recorded.

Surgical Approach Related to the Injected Area

Upper Third

When the fillers have been injected in the forehead, glabella and/or temples, surgical approach, in order to hide the scar

Table 4 Global Aesthetic Improvement Scale

Score	State
1	Very much improved
2	Much improved
3	Moderately improved
4	No change
5	Worse

Table 5 Patient satisfaction 5-point scale

Score	State
0	Very satisfied
1	Satisfied
2	Average
3	Unsatisfied
4	Very unsatisfied

and have a good visibility of surgical field, can be represented by hairline incision or coronal incision. Hairline incision allows to get a direct visibility of the surgical field and let to perform, once the filler is removed, an upper third lifting if necessary.

It is mandatory a proper preoperative imaging evaluation to know the anatomical layer where the filler has been injected. To minimize deformities as depression and irregularities in forehead contour that could appear after filler removal, a forehead lift is performed following filler removal.

The coronal incision is designed in a gull-winged pattern. We prefer to use hair perimeter incisions only in extremely high forehead (►Fig. 1A). The best quality scar is achieved without hair shaving because post-hairline incisions must be beveled to parallel the hair follicles to maximize peri-incisional hair growth and minimize postoperative alopecia. Subgaleal loose areolar plane is entered and the anteriorly based flap is elevated in posterior-to-anterior direction. Laterally, the flap must be completely freed from the supra-orbital rim. Centrally, the flap must be elevated off of glabella and proximal nasal dorsum for proper mobilization. The flap is everted and draped over the eyes, which must be protected from pressure and corneal injury. Flap undersurface is exposed to reveal forehead musculature. At this step, filler is identified, usually can be found both in periosteal and muscular layer (►Fig. 1B). Filler removal is performed and the resulting skin depression is to be refined. The frontalis is treated by fashioning two bipedicle myofascial flaps that are

incised horizontally with cautery through galea and muscle. The surgeon must be careful not to cut too deep in order to avoid subcutaneous or dermal layer incision preventing dimpling and skin necrosis. The lateral extent of these flaps is represented by vertical supraorbital neurovascular pedicle which should not be injured. A single lateral bipedicle flap can be fashioned lateral to this pedicle and at least 2 cm superior to the supraorbital rim, avoiding injuring the frontal branch of the facial nerve. Corrugator and procerus muscles are also mobilized; their central bellies are excised and both origin and insertion are cauterized. Scalp resection must be conservative but adequate. However, the final decision is on surgeon's professional judgment. Skin marker aid scalp excision assessment. Failure to perform this maneuver may result in inadequate excision. Closure is quite rapid but must be precise to ensure optimal scar quality (►Fig. 1C). In the temporal area, fillers usually are injected subcutaneously or between the superficial and the deep temporal fascia. In order to avoid injury of the temporal branch of the facial nerve, it is mandatory a surgical dissection respecting fascia's layers.

Upper Eyelid

In these cases, a surgical approach such as the one performed for an upper blepharoplasty, let the surgeon to identify the filler (►Fig. 2A), remove it, and perform upper blepharoplasty in order to achieve upper eyelid aesthetic balance restoration and filler removal. Mandatory is to pay attention not to

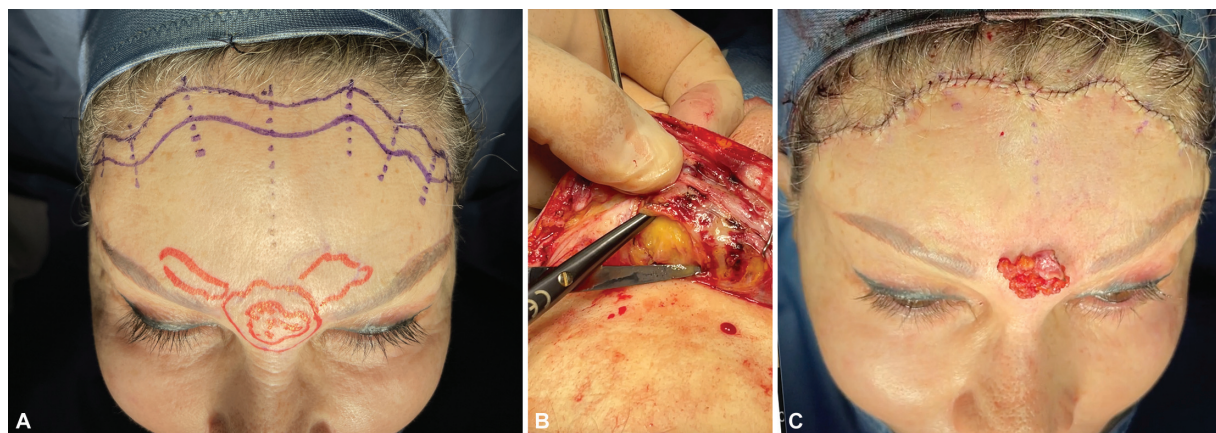


Fig. 1 Filler removal in the forehead region followed by restorative facial aesthetic surgery approach in a 63-year-old Caucasian female patient. (A) Hair perimeter incision designed in a gull-winged pattern. Permanent filler area of infiltration is marked. (B) Permanent filler is identified both in periosteal and muscular layer. (C) Intraoperative view of surgical access outcome. The localization of the removed filler is emphasized.

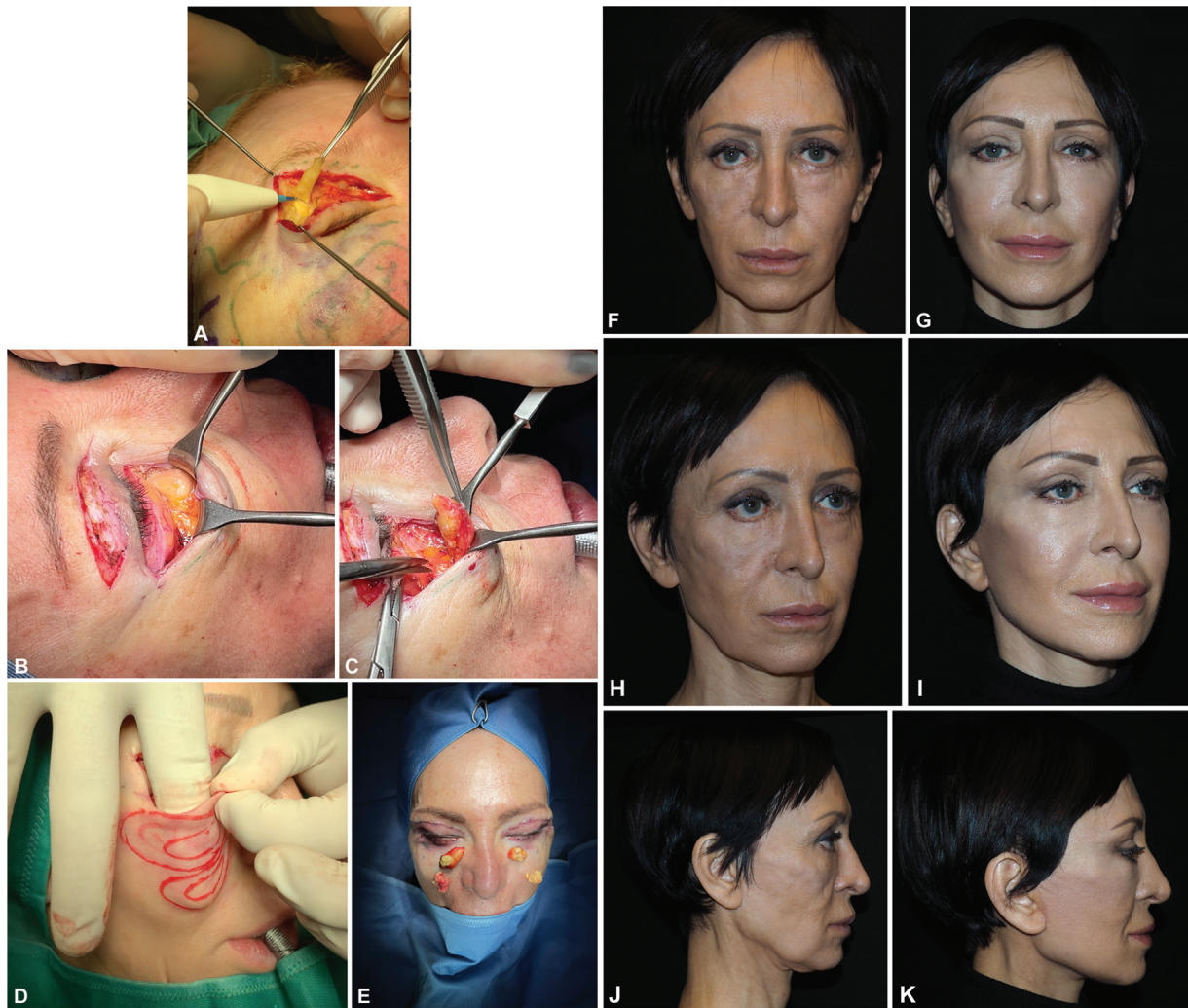

Fig. 2 Filler removal in the upper eyelid region followed by restorative facial aesthetic surgery approach in a 55-year-old Caucasian female patient and filler removal in lower eyelid/submalar area followed by restorative facial aesthetic surgery approach in a 48-year-old Caucasian female patient. (A) Upper blepharoplasty approach in order to identify permanent filler. (B) A careful soft tissue dissection performed reaching the inferior orbital rim, in order to remove the previously injected filler in the submalar region. (C) Filler removal in the submalar region. (D) Surgical dissection reaches the nasolabial fold according to the reconstructive approach. (E) Overcorrection of the lifting maneuvers performed in order to prevent scleral show or skin retraction during the healing process when wide dissections are necessary to remove fillers previously injected. (F) A 48-year-old Caucasian female patient with sequelae of permanent filler infiltration in the lower eyelid/submalar area, frontal view. (G) A 48-year-old Caucasian female patient 24 months after filler removal and restorative facial aesthetic surgery, frontal view. (H) A 48-year-old Caucasian female patient with sequelae of permanent filler infiltration in the lower eyelid/submalar area, 3/4 view. (I) A 48-year-old Caucasian female patient 24 months after filler removal and restorative facial aesthetic surgery, 3/4 view. (J) A 48-year-old Caucasian female patient with sequelae of permanent filler infiltration in the lower eyelid/submalar area, lateral view. (K) A 48-year-old Caucasian female patient 24 months after filler removal and restorative facial aesthetic surgery, lateral view.

damage the levator palpebral muscle when the filler has been injected deeply, behind the orbicularis.

Lower Eyelid/Submalar Area

When fillers have been injected into lower eyelid or in the submalar region, a subciliar lower eyelid incision can be performed. Once the incision is performed, if the filler has been wrongly placed into the lower eyelid fat bags, surgical dissection can be performed as for a cosmetic lower blepharoplasty respecting the orbicularis muscle integrity. If filler is present into the lid cheek junction or in the submalar region, once the inferior orbital rim is reached, a carefully soft tissue dissection is performed in order to remove the previously

injected filler (► **Fig. 2B, C**). Surgical dissection can reach the nasolabial fold (► **Fig. 2D**). Once the filler has been removed, a dissection of mid-facial soft tissues can be performed in order to lift the area, allowing a good restoration of the area depleted by filler removal. A key stone for a safe approach is to identify and preserve the infraorbital pedicle when the filler has been injected in the submalar area. After releasing the orbital retaining ligament and tear trough ligament, the dissection plane may be superficial into the prezygomatic space and above major and minor zygomatic muscles, or deep, directly at the subperiosteal level. With both these dissection layers it is possible to lift the tissue once set free by the filler (► **Video 1**); in order to avoid lower eyelid

complication in mid-face lifting, it is mandatory to harvest a muscle flap from the orbicularis and anchor it by some sutures to the periosteum of the superolateral orbital rim; dynamic canthopexy is mandatory in order to prevent a lower eyelid displacement. When wide dissections are necessary to remove previously injected fillers, especially when fillers have been injected superficially in the subcutaneous tissue, during the healing process scar tissue may induce strong skin retraction. In order to avoid scleral show or side effect secondary to scarring, it is mandatory an overcorrection of the lifting maneuvers performed (►Fig. 2E). A representative case of this approach is shown in ►Fig. 2F–M.

Video 1

After releasing the orbital retaining ligament and tear trough ligament, the dissection plane is superficial into the prezygomatic space and above major and minor zygomatic muscles, or deep, directly at the subperiosteal level. With both these dissection layers is possible to lift the tissue once set free by the filler. Online content including video sequences viewable at: <https://www.thieme-connect.com/products/ejournals/html/10.1055/a-2019-5131>.

Preauricular Area, Malar Area, Cheeks, Lower Jaw, and Neck

A face-lift incision is suitable to remove fillers injected into the malar area, gonial angle, or cheeks. Fillers injected subcutaneously can be easily removed with a subcutaneous dissection. If fillers are placed up to the bones or deep into the cheeks, a meticulous dissection is mandatory, preserving facial nerve course (►Video 2). Following filler removal, aesthetic balance of the face can be restored performing a deep plane face lift. Unfortunately, fillers are often injected in multiple layers, deeper than the subcutaneous one. When injected into the superficial musculoaponeurotic system (SMAS) area, the filler may have close relationship with anatomical structures such as facial nerve branches, Stensen's duct, and elevator muscles of the cheek. Thus, it is useful to remove the filler by a progressive approach, removing first the most superficial filler injected into the subcutaneous layer harvesting a skin flap, and then a SMAS-platysma flap has to be harvested in order to remove deeper filler. A SMAS-platysma flap is mandatory not only to achieve a better aesthetic result after filler removal, but especially to have a direct vision of noble structures such as peripheral facial nerve branches (►Fig. 3A). This progressive surgical approach allows a more radical approach for filler removal avoiding damaging important anatomical structures. At the end of the removal, the repositioning of the SMAS-platysma flap is performed according to the criteria codified in the extended deep plane lift technique. In selected cases, following preoperative MRI evaluation, a surgical intraoral approach into the cheek

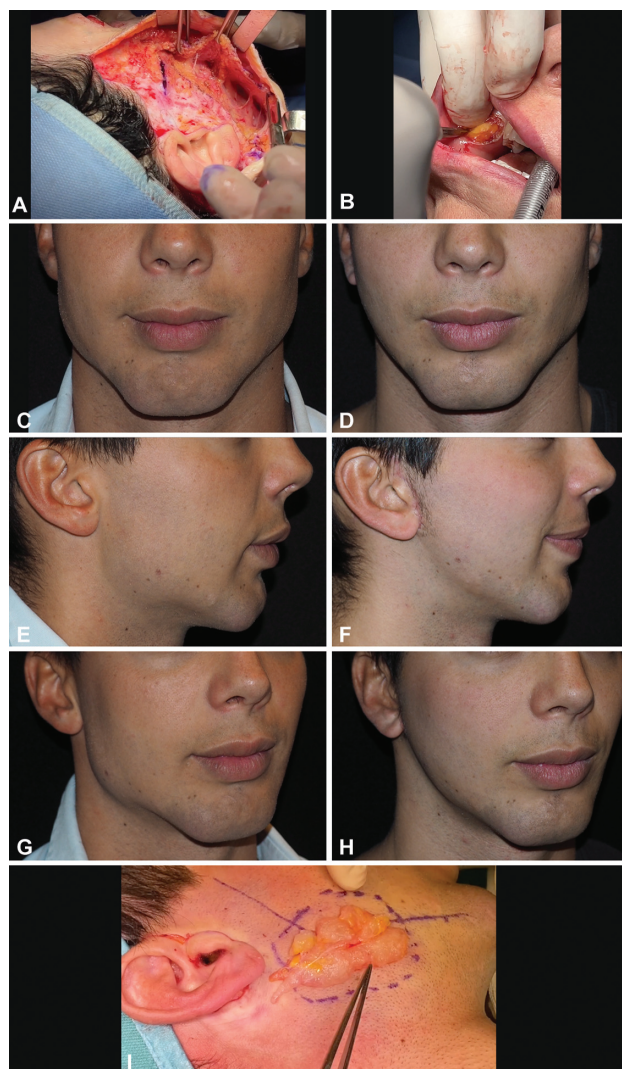


Fig. 3 Filler removal in the preauricular area, malar area, cheeks, and lower jaw region followed by restorative facial aesthetic surgery approach in a 35-year-old Caucasian male patient. (A) Superficial musculoaponeurotic system (SMAS)-platysma flap harvested in order to remove deeper filler and to have a direct vision of the noble structures present at the level of this anatomical area, especially peripheral facial nerve branches. (B) Bichat fat pad removal in order to remove deeply injected filler. (C) A 35-year-old Caucasian male patient with sequelae of permanent filler infiltration in the preauricular area, malar area, cheeks, and lower jaw region, frontal view. (D) A 35-year-old Caucasian male patient 36 months after filler removal and restorative facial aesthetic surgery, frontal view. (E) A 35-year-old Caucasian male patient with sequelae of permanent filler infiltration in the preauricular area, malar area, cheeks, and lower jaw region, lateral view. (F) A 35-year-old Caucasian male patient 36 months after filler removal and restorative facial aesthetic surgery, lateral view. (G) A 35-year-old Caucasian male patient with sequelae of permanent filler infiltration in the preauricular area, malar area, cheeks, and lower jaw region, 3/4 view. (H) A 35-year-old Caucasian male patient 36 months after filler removal and restorative facial aesthetic surgery, 3/4 view. (I) Intraoperative view of surgical access outcome. The localization of the removed filler is emphasized.

mucosa, as for the one performed to remove the Bichat fat pad, could be useful to remove deeply injected filler (►Fig. 3B). A representative case of this approach is shown in ►Fig. 3C–I.

Video 2

Permanent fillers injected deep into the cheeks: in these case a meticulous dissection, taking in mind facial nerve course, is mandatory. Online content including video sequences viewable at: <https://www.thieme-connect.com/products/ejournals/html/10.1055/a-2019-5131>.

Lips Mucosa

An incision between dry and wet mucosa allows the surgeon to “open” the lip, identify, and remove the filler (►**Video 3**). When lip filler removal is performed, it is mandatory to perform contextually a cheiloplasty in order achieve not only the filler removal but to restore also the aesthetic appearance of the lip itself. A key stone in this kind of surgery is represented by the “appearance” of the orbicularis oris muscle after the filler removal. To avoid postoperative lip irregularities following the edema resorption, the thickness of the orbicularis muscle must be uniform and symmetrical to avoid the formation of unsightly depressions. Trimming of muscular tissue following lip filler removal is mandatory. Another issue to deal in this kind of surgery, especially when large amounts of filler are removed, is the management of the hyper-expanse lip mucosa. In this scenario, it is necessary to remove a strip of mucosa, from a few millimeters up to 8 to 10 mm wide. Mucosa removal is performed in the inner side in order to avoid visible scar. Least but not the last, when filler is removed both from the upper and the lower lip, it is mandatory to avoid the connection between the upper and the lower incision. These surgical accesses, if connected or also too close to the commissura, may induce mouth opening reduction due to scarring. A “back cut” next to oral commissura, as previously proposed in literature,³ is mandatory to avoid this complication (►**Fig. 4A**). A representative case of this approach is shown in ►**Fig. 4B–G**.

Video 3

Permanent fillers injected into the lips. An incision between dry and wet mucosa allow the surgeon to “open” the lip, identify the filler, and remove it. Online content including video sequences viewable at: <https://www.thieme-connect.com/products/ejournals/html/10.1055/a-2019-5131>.

Nasolabial Folds and Upper Lip (Cutaneous Part)

In order to access to nasolabial folds or upper lip, a subcutaneous lip-lift access is preferable. After identifying three vertical reference lines at the medio-columellar sulcus and the sills of the nostrils bilaterally, a subnasal incision is delineated according to the “buffalo-hornlike” method,²⁰ starting from the columella and proceeding laterally over the subnasal sulcus to the wing base.

From this surgical approach, we can widely dissect subcutaneously the upper lip up to the nasolabial folds in order to remove previously injected filler (►**Fig. 4H**). Once the filler has been removed, it is possible to perform lip lifting in order to restore the aesthetic balance of the area. A second incision is outlined 3 to 10 mm (average: 6.5 mm) caudal to the first. A wedge resection of the lower tissues down to the orbicularis muscle, which is kept intact, is performed. This wedge resection is responsible of the rolling effect on the upper lip. The sutures further define the narrowed and raised filter columns. A representative case of this approach is shown in ►**Fig. 4I–N**.

Chin

Surgical approach can be performed both intraorally and extraorally. Intraoral approach is suitable when fillers have been injected deep to the symphysis. If fillers have been injected subcutaneously, an extraoral approach along the submental crease is to prefer in order to avoid damaging mentalis nerve branches. Through the extraoral approach, it is possible not only to remove subcutaneous fillers placed in symphyseal and parasymphyseal area but also to combine an aesthetic improvement of the neck, operating on the platysmatic medial fibers following filler removal. Sometimes, it may be useful to combine the removal maneuver with remodeling/redefinition surgery of the middle region of the neck and the cervical angle.

Nose

The surgical approach, in order to remove previously injected filler, can be performed with open or closed technique. Open technique is performed with bilateral rim incision connected at the columella with a step or W-shaped incision (►**Fig. 5**). When closed approach is chosen, bilateral intercartilaginous incision is necessary when filler is located on the nasal bridge or over the radix. On the other hand, if filler has been placed over the nasal tip, a bilateral rim incision, in order to control the nasal tip, is mandatory.

Results

Functional and aesthetic restoration was recognized (according to GAIS) as very much improved in 195 patients, as much improved in 23 patients, and as moderately improved in 13 patients. Improvement in atrophic and scarred tissues (with an apparent thickening of the skin or even elimination of scars) was also assessed, with the following results: 88 patients were very much improved, 84 much improved, 36 were moderately improved, and 23 noticed no improvement in scarred tissues after surgery. Patients reported high levels of satisfaction; 92% of the patients (212 patients) defined themselves as score 0 (very satisfied), 6% (14 patients) as score 1 (satisfied), and 2% (5 patients) as score 2 (average). The high overall patient satisfaction is evident in patient willingness to undergo the procedure again. No patient reported worsening of the appearance compared to the baseline. There were no reported infections. In 10% of patients operated for malar/cheek/lower eyelid filler removal (22 patients), a subcutaneous fat graft was performed in

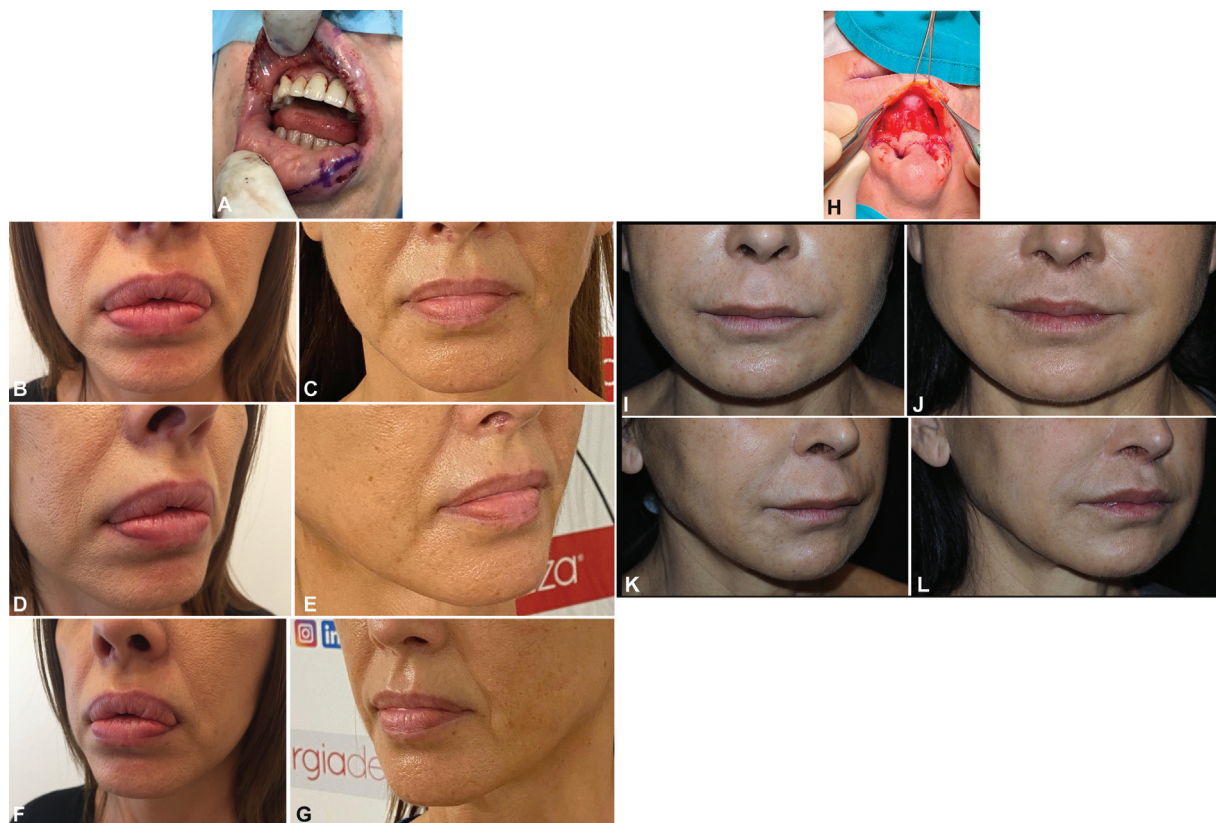

Fig. 4 Filler removal in the lips mucosa region followed by restorative facial aesthetic surgery approach in a 38-year-old Caucasian female patient and filler removal in nasolabial folds and cutaneous part of the upper lip followed by restorative facial aesthetic surgery approach in a 44-year-old Caucasian female patient. (A) Intraoperative view of the incision created next to the oral commissure in a 38-year-old Caucasian female patient with sequelae of permanent filler lip infiltration. Approximately 5 mm from the oral commissure, the incision is extended medially for 1 cm to avoid mouth opening limitation due to postsurgical scarring. (B) A 38-year-old Caucasian female patient with sequelae of permanent filler lip infiltration, frontal view. (C) A 38-year-old Caucasian female patient 12 months after filler removal and restorative facial aesthetic surgery, frontal view. (D) A 38-year-old Caucasian female patient with sequelae of permanent filler lip infiltration, right 3/4 view. (E) A 38-year-old Caucasian female patient 12 months after filler removal and restorative facial aesthetic surgery, right 3/4 view. (F) A 38-year-old Caucasian female patient with sequelae of permanent filler lip infiltration, left 3/4 view. (G) A 38-year-old Caucasian female patient 12 months after filler removal and restorative facial aesthetic surgery, left 3/4 view. (H) Intraoperative view of a subcutaneous lip-lift approach to access both nasolabial folds and upper lip in a 44-year-old Caucasian female patient with sequelae of permanent filler lip infiltration. (I) A 44-year-old Caucasian female patient with sequelae of permanent filler infiltration in nasolabial folds and cutaneous part of the upper lip, frontal view. (J) A 44-year-old Caucasian female patient 12 months after filler removal and restorative facial aesthetic surgery, frontal view. (K) A 44-year-old Caucasian female patient with sequelae of permanent filler infiltration in nasolabial folds and cutaneous part of the upper lip, right 3/4 view. (L) A 44-year-old Caucasian female patient 12 months after filler removal and restorative facial aesthetic surgery, right 3/4 view.

order to improve postoperative superficial irregularities; 50% (10 patients) of these patients required a second fat graft performed 6 to 8 months after the first surgery. Some minor asymmetries were recorded following lip filler removal and 3 cases required localized mucosa trimming (always upper lip) performed under local anesthesia. No other complications were detected.

A very good satisfaction level was registered with this type of surgical approach in both subjective and objective judgment scores. The results of subjective and objective assessment were similar, with very high scores for all the questions in both cases (–Table 6). The highest score was awarded by both the patients (mean, 8.71) and the expert jury (mean, 8.94) to the “neck,” followed by “cheeks” (mean, 8.56 recorded from patients; mean, 8.70 from expert jury), “lower face and jaw line” (mean, 8.53 recorded from patients; mean, 8.34 from expert jury), “nose” (mean 8.33 recorded from patients; mean 8.54 from expert jury), “area under the

chin” (mean 8.23 recorded from patients; mean 8.88 from expert jury), and “nasolabial folds” (mean 7.67 recorded from patients; mean 7.97 recorded from expert jury). All evaluations are therefore clearly above sufficiency. This result is also found in “satisfaction with facial appearance overall” reporting a mean value of 8.45 ± 1.26 for the subjective evaluation and a mean of 8.58 ± 1.44 for the objective evaluation. Comparing the answers to each question for both groups in terms of the Pearson’s coefficient, a positive correlation between overall satisfaction with facial appearance (0.81) and overall quality of scars (0.87) was found. Lower correlations are also registered in evaluations of the specific parts of the face. No patient expressed regret about deciding to undergo this type of surgery. According with the FACE-Q questionnaire, all the registered results reported values above sufficiency, with scores of 8 to 10 in 8% of the cases and the maximum in 36% (67 patients). A high score for this question also implies that other people could not

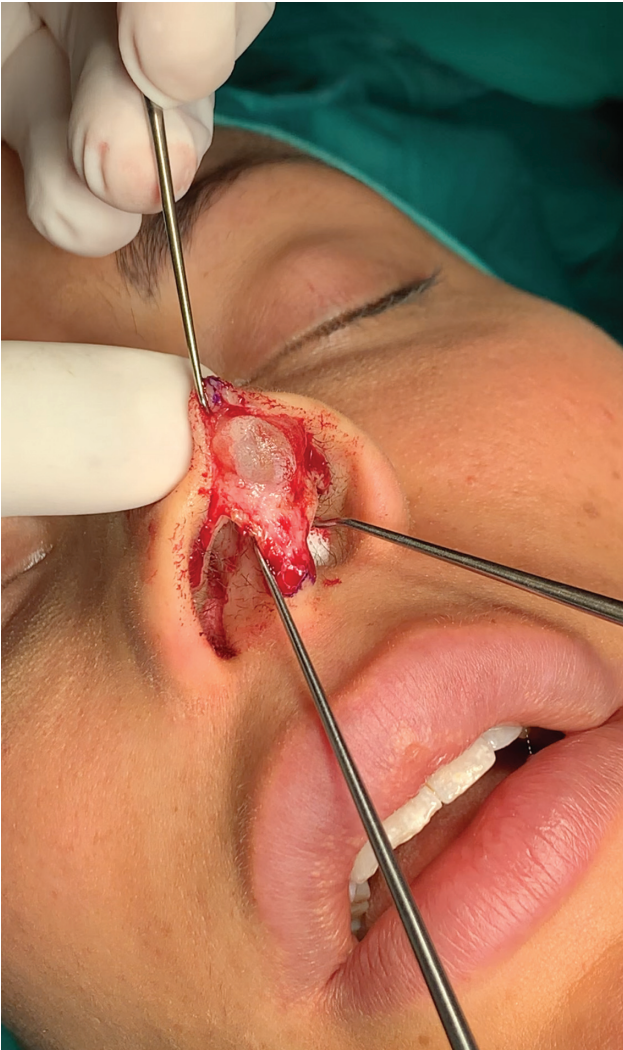

Fig. 5 Intraoperative view of a 35-year-old Caucasian female patient with sequelae of permanent filler nasal infiltration. Bilateral rim incision connected at the columella with a W-shaped incision is performed in order to remove permanent filler everywhere from the nose.

understand that an aesthetic plastic surgery had been carried out. In the subjective judgment (►Fig. 6A), only 5% of cases report an average improvement of functional outcome (score 6), 15% of patients reported a score 7, whereas the remaining 64% report a quite high improvement of the function (score 8); 10% a great improvement (score 9) and 6% a very great improvement (score 10). About satisfaction with aesthetic outcome (►Fig. 6B), 7% of the patients show an average improvement of aesthetic outcome (score 6), 59% report a quite high improvement (score 8) and 7% a very great improvement of the aesthetic outcome (score 10).

There were no major complications such as skin necrosis. Two patients presented hematomas 12 hours after surgery. One required surgical drainage and the other was drained by the use of a microcannula. Eight patients presented a transient palsy (buccal branch): two patients resolved spontaneously in 1 week and six patients in 3 months, respectively. Five patients developed hypertrophic scars: two retroauricular, one along the temporal hairline, one along the submental crease, and one

following lip lift approach. In two cases, the retroauricular ones, satisfactory improvement was obtained with injections of triamcinolone in accordance with the standard protocols. In the other cases, scar tissue was excised to obtain a new good-quality scar. In three cases, monolateral lower eyelid retraction was recorded a few weeks following surgery: two cases were self-resolved with daily at-home massages within 3 months, in one case a surgical canthopexy was performed 8 months following surgery. In one case, local infection in the cheeks area, treated by oral antibiotics and intraoral wound drainage, was recorded, respectively, 20 days after surgery on the right and 30 days later on the left side. This complication could be related to some persistence of permanent filler not removed due to the close relationship with peripheric branches of facial nerve. In this series, there were no cases of postoperative dog-ears, because all patients underwent careful preoperative evaluation and selection. It should be nonetheless noticed that this is a possible complication, when the extra skin to be resected exceeds the possibility of being treated with a short-scar technique.

Discussion

Permanent facial filler removal is challenging, it is a niche topic and medical literature is still lacking: there is no consensus about treatment modalities.²⁶ In cases of complications following nonabsorbable facial filler injections in general, two treatment regimens are advised: systemic drugs and surgical removal of the material. Drugs can be useful to suppress the adverse reactions toward the filler material but they do not remove filler itself.^{5,16–18} Surgical excision may remove the material but it is considered a challenging surgery, often with tissue damage and scarring as a cosmetically undesirable result.^{27,28} During last years, intralesional laser treatment (ILT),¹¹ has been proposed in medical literature as an alternative to surgical approach in order to treat permanent filler complications. Nevertheless, as shown by Schelke et al in 2018, resolution of the complication was achieved only in 9% of the cases over 242 patients treated with ILT: in most patients (835) just an improvement was recorded.²⁹ In the present case series, almost 40% of lips operated on already received one or more laser treatments, performed by other physicians, with no improvements. Outcomes published in medical literature regarding laser treatments for permanent lip filler removal has not shown satisfactory results.^{8,11,15} Moreover, in our experience we noticed that patients who already performed laser treatment in the lip area before surgery showed hardening of the tissues and the persistence of the permanent filler. Quite often patients claimed depressions and irregularities developed following lip laser treatments (►Fig. 7).

Rauso et al, in a recent article,³ focused their attention on surgical lip remodeling after injection of permanent filler. They stated that intraoperatively, none of their patients demonstrated a well-defined fibrous capsule separating the implant from the surrounding scar tissue, but rather general fibrosis and a diffuse distribution of the product within all the three layers of the lips. This finding, in general, is the problem related to all nonabsorbable facial fillers,

Table 6 FACE-Q patient and jury scores

Question	Patient score from 0–10 (mean ± SD)	Jury score from 0–10 (mean ± SD)
Age	54 ± 9.43	/
Satisfaction with facial appearance overall	8.45 ± 1.26	8.58 ± 1.44
Satisfaction with cheeks	8.56 ± 0.84	8.70 ± 0.91
Appraisal of nasolabial folds	7.67 ± 0.45	7.97 ± 0.67
Satisfaction with lower face and jaw line	8.53 ± 0.81	8.34 ± 1.08
Satisfaction with nose appearance	8.33 ± 1.65	8.54 ± .,97
Appraisal of area under chin	8.23 ± 0.3	8.88 ± 0.62
Appraisal of the neck	8.71 ± 0.54	8.94 ± 0.76
Social function	8.90 ± 0.92	/
Psychological well-being	8.97 ± 0.44	/
Satisfaction with functional outcome	8.34 ± 0.76	/
Satisfaction with aesthetic outcome	8.30 ± 0.87	/
Aging appraisal VAS (y)	9.44 ± 2.17	/
Satisfaction with decision	8.29 ± 0.24	/
Satisfaction with scar quality	8.91 ± 0.15	9.01 ± 0.36
Scar extension correspond to expectations	8.32 ± 0.65	/

Abbreviations: SD, standard deviation; VAS, visual analogue scale.

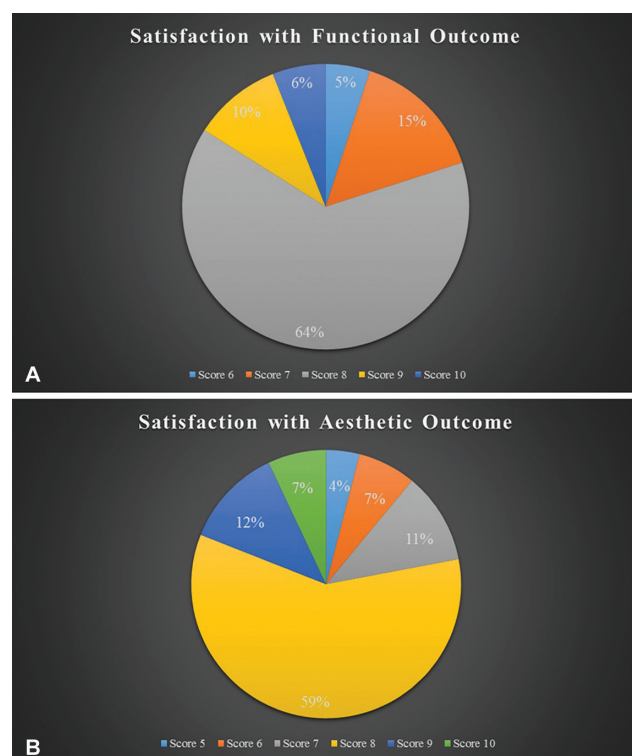


Fig. 6 (A) Subjective judgment of functional outcome. (B) Subjective judgment of aesthetic outcome.

especially when they have been injected in areas where peripheric branches of the facial nerve are present: tissue damage and scarring are the main factors why surgeons often prefer not to perform surgery in this patient population. Direct excision of a previously injected area may avoid to injury noble anatomical structure, although induce a

visible scar with unpleasant aesthetic result.^{18,27} In the present cases, we paid attention on aesthetic surgical approach, already used for facial aesthetic surgery or surgical rejuvenation, in order to remove facial filler, restore aesthetic balance of the area, and hide the scar needed for the surgical access (→Fig. 8A, B). A main factor to consider, before performing surgery, is an extensive imaging evaluation. MRI evaluation is absolutely necessary in order to exactly identify previously injected fillers and their relationship with facial layers. When filler is in the cheek area, a safe approach, in order to avoid peripheric facial nerve branches, is represented by a progressive removal of the filler instead of “en bloc” resection. In others areas, such as periorbital, it is necessary to preserve muscular structure to avoid excessive postsurgical tissue retraction and unpleasant aesthetic results. Proper preoperative evaluation let the surgeon to have a safe surgical pathway^{13,14,30} and MRI is able to give such exhaustive information. Only in cases when filler is located in the lip area, ultrasonographic evaluation may be performed instead of MRI. This is due to the lip’s anatomy, represented just by mucosa, orbicularis muscle, and skin, although dedicated probe are necessary to have a proper evaluation: if small probes, useful for lip’s ultrasonographic evaluation, are not available, it is better to perform an MRI. A key point in permanent facial filler removal is represented by a wide surgical dissection, in order to remove all the filler or as much as possible. Because of the need of a wide surgical dissection, it is mandatory also to perform an overcorrection of the area at the end of surgery: this will face the retraction induced by the postoperative scarring. Another important point with this kind of surgery is to be aware that filler injected superficially, in the subcutaneous layer, once removed may induce irregularities that need to be restored

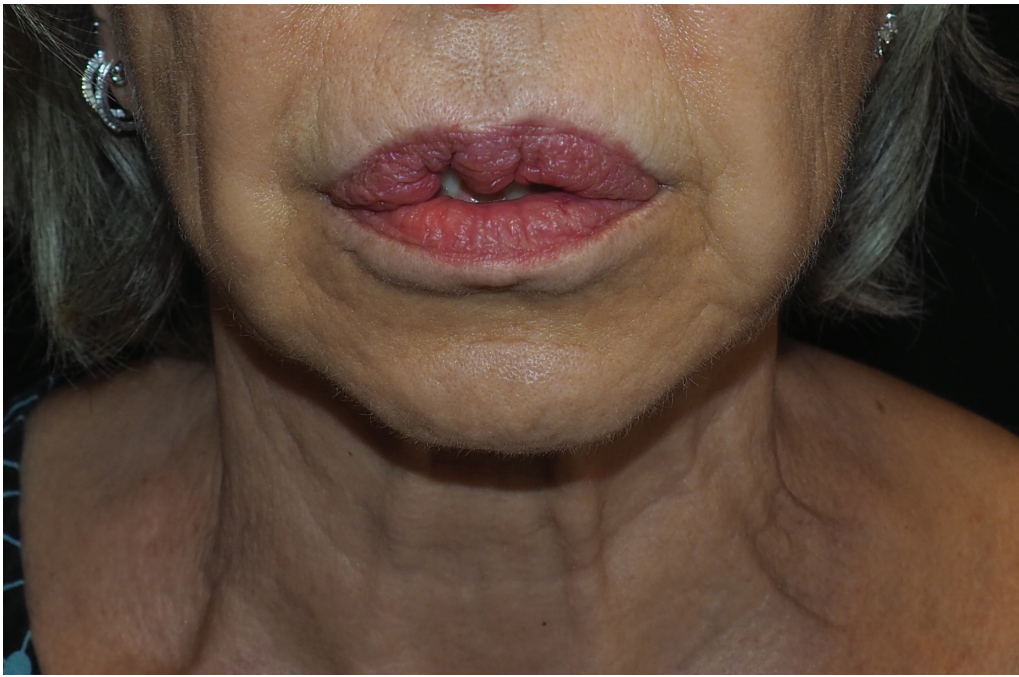

Fig. 7 A 64-year-old Caucasian female patient with sequelae of permanent lip filler infiltration who already performed laser treatment in the lip area before surgery, showing depressions, irregularities, and hardening of the tissues and the persistence of the permanent filler.

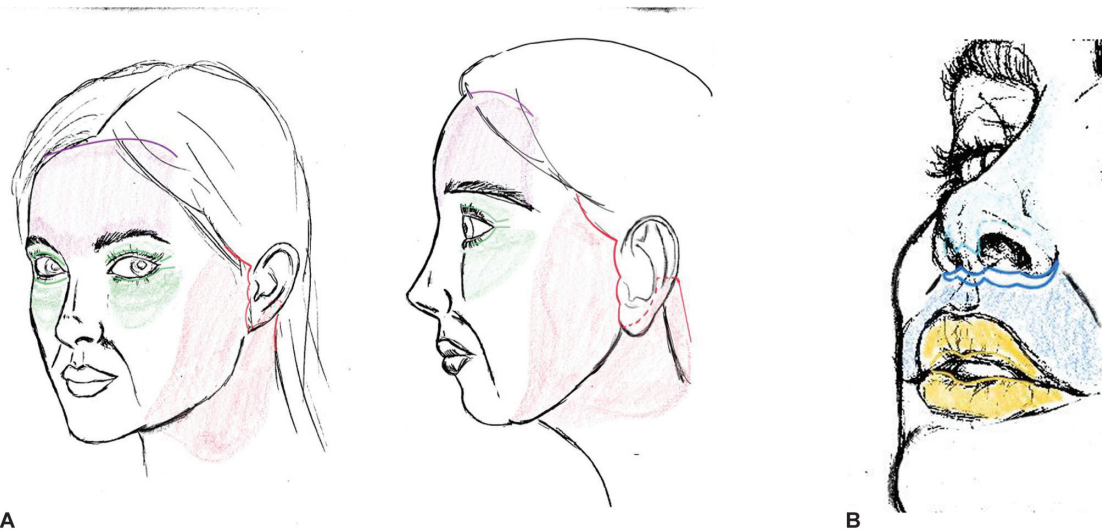

Fig. 8 Incision and area of dissection of the aesthetic surgical approaches used in order to remove facial filler, restore the aesthetic balance of the area, and hide the scar needed for the surgical access. (A) Forehead and glabella region: dark violet color. Periorbital and submalar region: dark green color. Preauricular, malar cheeks, lower jaw, and neck area: light violet color. (B) Nasal region: light green color. Nasolabial folds and cutaneous part of upper lip region: blue color. Lips mucosa: yellow color.

with fat graft. Fat graft can be performed contextually with filler removal, but often a second fat graft performed a few months later is necessary. The surgical approach performed in all the cases was represented by choosing a standardized facial aesthetic surgical incision area per area in order to remove previously injected fillers. Moreover, in all the cases a lifting surgical technique was associated in order to tighten the facial tissue emptied by the filler removal. This combined approach was necessary to get both pleasant aesthetic result and filler removal; otherwise ptotic tissue would develop following surgical facial filler removal. In the present cases,

in a time lapse of 11 years, 231 consecutive patients presenting permanent facial fillers were operated on. No patients reported worsening of the appearance compared to the baseline. The aesthetic and functional outcomes, scored by GAIS, were satisfactory for almost all patients: 84.4% rated very much improved, 8.6% as moderately improved, and 3.9% as improved. Complication rate was low, we recorded 2 hematomas, 8 transient monolateral facial palsy, 5 unpleasant scars, and 1 postoperative infection case. Twenty-five patients required a postsurgical touch up: 22 fat graft in order to correct superficial irregularities of area such as malar/cheek/

lower eyelid, 3 patients required lip mucosa trimming in order to improve small postoperative asymmetries.

Conclusion

To the best of our knowledge, we present the largest case series regarding surgical removal of permanent facial fillers, representing by 231 patients. In all the cases, we approached with surgical accesses already described in facial aesthetic surgery in order to avoid direct excision and unpleasant facial scar. All the patients, with the exception of lip patients, were evaluated with MRI to exactly identify the relationship of the filler with facial layer; lip patients were evaluated with ultrasonographic examination performed with small probe. Complications rate was low and similar with others facial aesthetic procedures. We conclude that a proper preoperative evaluation, facial esthetic surgery approaches, filler removal followed by restorative aesthetic surgery of the treated area, may solve challenging cases represented by patients previously injected with permanent facial filler, although it is mandatory to explain preoperatively that it is not possible to assure to patient the complete removal of the filler.

Conflict of Interest
None declared.

References

- Goldberg DJ, Bass LM, Fitzgerald R, Graivier MH, Lorenc ZP. Expanding treatment options for injectable agents. *Aesthet Surg J* 2018;38(Suppl 1):S1-S7
- Fitzgerald R, Bass LM, Goldberg DJ, Graivier MH, Lorenc ZP. Physiochemical characteristics of poly-L-lactic acid (PLLA). *Aesthet Surg J* 2018;38(Suppl 1):S13-S17
- Rauso R, Califano L, Ruge L, Chirico F, Tartaro G. Surgical lip remodeling after injection of permanent filler. *Aesthet Surg J* 2019;39(05):565-571
- Rauso R, Zerbini N, Franco R, et al. Cross-linked hyaluronic acid filler hydrolysis with hyaluronidase: different settings to reproduce different clinical scenarios. *Dermatol Ther* 2020;33(02):e13269
- Rauso R, Califano L, Ruge L, Chirico F, Tartaro G. Late onset complications secondary to polyacrylamide hydrogel-based filler for rehabilitation of HIV-related facial lipoatrophy. *Aesthet Surg J* 2018;38(11):NP170-NP174
- Fitzgerald R, Graivier MH, Kane M, et al. Update on facial aging. *Aesthet Surg J* 2010;30(Suppl):11S-24S
- Christensen L, Breiting V, Janssen M, Vuust J, Hogdall E. Adverse reactions to injectable soft tissue permanent fillers. *Aesthetic Plast Surg* 2005;29(01):34-48
- De Santis G, Pinelli M, Benanti E, Bacarani A, Starnoni M. Lipo-filling after Laser-Assisted Treatment for Facial Filler Complication: Volumetric and Regenerative Effect. *Plast Reconstr Surg* 2021;147(03):585-591
- Zaccaria G, Cassuto D, Bacarani A, Lusetti IL, Santis G. Filler-induced complications of the lips: 10 years experience with intralesional laser treatment and refinements. *J Plast Reconstr Aesthet Surg* 2022;75(03):1215-1223
- Oranges CM, Brucato D, Schaefer DJ, Kalbermatten DF, Harder Y. Complications of nonpermanent facial fillers: a systematic review. *Plast Reconstr Surg Glob Open* 2021;9(10):e3851
- Cassuto D, Pignatti M, Pacchioni L, Boscaini G, Spaggiari A, De Santis G. Management of complications caused by permanent fillers in the face: a treatment algorithm. *Plast Reconstr Surg* 2016;138(02):215e-227e
- van Dam D, van der Lei B, Cromheecke M. Statements on the safety of permanent soft tissue fillers in Europe. *Aesthetic Plast Surg* 2009;33(04):479-481
- Kadouch JA, Tutein Nolthenius CJ, Kadouch DJ, van der Woude HJ, Karim RB, Hoekzema R. Complications after facial injections with permanent fillers: important limitations and considerations of MRI evaluation. *Aesthet Surg J* 2014;34(06):913-923
- Ginat DT, Schatz CJ. Imaging features of midface injectable fillers and associated complications. *AJNR Am J Neuroradiol* 2013;34(08):1488-1495
- Goldman A, Wollina U. Intralesional neodymium YAG laser to treat complications of polymethylmethacrylate. *Open Access Maced J Med Sci* 2018;6(09):1636-1641
- Wilson YL, Ellis DA. Large needle suction aspiration of permanent fillers. *Laryngoscope* 2011;121(10):2146-2149
- Carella S, Ruggeri G, La Russa R, Volonnino G, Frati P, Onesti MG. Clinical management of complications following filler injection. *Aesthetic Plast Surg* 2022;46(02):886-894
- Kästner S, Gonser P, Paprottka F, Kaye KO. Removal of polyacrylamide gel (Aquamid®) from the lip as a solution for late-onset complications: our 8-year experience. *Aesthetic Plast Surg* 2018;42(03):791-797
- Rauso R, Albani G, Salini C, Ruge L, Chirico F, Tartaro G. Continuum: late onset complications secondary to polyacrylamide hydrogel-based filler for rehabilitation of HIV-related facial lipoatrophy. *Aesthet Surg J* 2019;39(05):NP152-NP155
- Botti C, Botti G, Pascali M. Facial aging surgery: healing time, duration over the years, and the right time to perform a facelift. *Aesthet Surg J* 2021;41(11):NP1408-NP1420
- Pascali M, Gentile P, Di Pasquali C, Bocchini I, Cervelli V. The auricular cartilage in 197 secondary and tertiary rhinoplasties. *J Craniofac Surg* 2016;27(02):339-344
- Pascali M, Botti C, Cervelli V, Botti G. Midface rejuvenation: a critical evaluation of a 7-year experience. *Plast Reconstr Surg* 2015;135(05):1305-1316
- Jacono AA, Stong BC. Anatomic comparison of the deep-plane face-lift and the transtemporal midface-lift. *Arch Facial Plast Surg* 2010;12(05):339-341
- Romo T III, Jacono AA, Sclafani AP. Endoscopic forehead lifting and contouring. *Facial Plast Surg* 2001;17(01):3-10
- Bertossi D, Albanese M, Nocini R, Mortellaro C, Kumar N, Nocini PF. Osteotomy in genioplasty by piezosurgery. *J Craniofac Surg* 2021;32(03):e317-e321
- Steffen N, Goldenberg DC. Re: Brazilian Consensus Recommendation on the Use of Polymethylmethacrylate Filler in Facial and Corporal Aesthetics by Túlio Armanini Blanco Souza, Leticia Marques Colomé, Eduardo André Bender, Gottfriede Lemperle. *Aesthetic Plastic Surgery* 2018; 42(5): 1244-51. *Aesthetic Plast Surg* 2019;43(04):1126-1127
- Zeltzer AA, Craggs B, Van Thielen J, Hendrickx B, Seidenstuecker K, Hamdi M. Massive hemi-facial edema after permanent filler removal in an HIV-positive patient. Precautions and patient information. *Aesthetic Plast Surg* 2015;39(03):425-427
- Wolter TP, Pallua N. Removal of the permanent filler polyacrylamide hydrogel (aquamid) is possible and easy even after several years. *Plast Reconstr Surg* 2010;126(03):138e-139e
- Schelke LW, Velthuis PJ, van Dijk MR. Polyalkylimide: a nonstable filler over time. *Dermatol Surg* 2018;44(04):563-567
- Mandy S, Del Campo R. Commentary on polyalkylimide. *Dermatol Surg* 2018;44(04):568