



# Use of Intraoperative Neuromonitoring in Surgical Treatment of Acute Presentation of Chiari I Malformation: A Case Report

Christina Ng<sup>1</sup> Sima Vazquez<sup>1</sup> Rose Auerbach-Tash<sup>2</sup> Alexandria F. Naftchi<sup>1</sup> Jose F. Dominguez<sup>2</sup>  
Aalok R. Singh<sup>3</sup> Philip Overby<sup>4</sup> Carrie R. Muh<sup>5</sup>

<sup>1</sup>School of Medicine, New York Medical College, Valhalla, New York, United States

<sup>2</sup>Department of Neurosurgery, Westchester Medical Center, Valhalla, New York, United States

<sup>3</sup>Division of Pediatric Critical Care, Maria Fareri Children's Hospital, New York Medical College, Valhalla, New York, United States

<sup>4</sup>Division of Pediatric Neurology, Westchester Medical Center, Maria Fareri Children's Hospital, Valhalla, New York, United States

<sup>5</sup>Division of Pediatric Neurosurgery, Westchester Medical Center, Maria Fareri Children's Hospital, New York Medical College, Valhalla, New York, United States

**Address for correspondence** Jose F. Dominguez, MD, Department of Neurosurgery, Westchester Medical Center, 100 Woods Road, Valhalla, NY 10595, United States  
(e-mail: Jose.Dominguez@wmchealth.org).

J Neurol Surg Rep 2023;84:e26–e30.

## Abstract

Intraoperative neuromonitoring (IONM) has been used in neurosurgical procedures to assess patient safety and minimize risk of neurological deficit. However, its use in decompressive surgeries of Chiari malformation type I (CM-I) remains a topic of debate. Here we present the case of a 5-year-old girl who presented with acute right lower extremity monoplegia after accidental self-induced hyperflexion of the neck while playing. Imaging revealed 15 mm of tonsillar ectopia with cervical and upper thoracic spinal cord edema. She was taken to surgery for a suboccipital decompression with expansile duraplasty. IONM demonstrated improvement in motor evoked potentials during the decompression. Postoperatively, she had full recovery of strength and mobility. This is a case of acute weakness after mild trauma in the setting of previously asymptomatic CM-I that showed close correlation with IONM, clinical findings, and imaging. IONM during decompressive surgery for CM-I may be useful in patients who present acutely with cervical cord edema.

## Keywords

- ▶ acute chiari
- ▶ intraoperative neuromonitoring
- ▶ decompression
- ▶ chiari I malformation

## Introduction

Chiari malformation type I (CM-I) is a congenital malformation of tonsillar herniation of at least 5 mm below the foramen magnum.<sup>1,2</sup> Most cases of CM-I are diagnosed radiographically with magnetic resonance imaging (MRI) and may be asymp-

tomatic or present with varied symptomatology including headache, neck pain, unsteady gait, poor coordination, sleep apnea, and dysphagia.<sup>1–4</sup> Severe cases of herniation may result in compression of the cervical spinal cord and subsequent hyperreflexia, urinary incontinence, muscle weakness and wasting, ataxia, and paresthesias.<sup>5</sup>

received

July 4, 2022

accepted

January 26, 2023

accepted manuscript online

February 4, 2023

DOI <https://doi.org/10.1055/a-2028-6419>.

ISSN 2193-6358.

© 2023. The Author(s).

This is an open access article published by Thieme under the terms of the Creative Commons Attribution-NonDerivative-NonCommercial-License, permitting copying and reproduction so long as the original work is given appropriate credit. Contents may not be used for commercial purposes, or adapted, remixed, transformed or built upon. (<https://creativecommons.org/licenses/by-nc-nd/4.0/>)

Georg Thieme Verlag KG, Rüdigerstraße 14, 70469 Stuttgart, Germany

Acute paresis, acute respiratory failure, sudden visual loss, and sudden truncal ataxia have been described following neck injury or trauma in the setting of CM-I.<sup>6-8</sup> Most cases in the literature show drastic improvement of acute symptomatology upon posterior fossa decompression.<sup>6-10</sup>

Intraoperative neuromonitoring (IONM) is often used in spine surgeries to assess patient safety and minimize risk of deficit.<sup>11-13</sup> IONM in decompressive surgeries for CM-I have been reported, but its use remains a topic of debate.<sup>14-16</sup>

Here we present the case of a 5-year-old girl who presented with acute right lower extremity monoplegia after accidental self-induced hyperflexion of the neck while playing. Imaging revealed 15 mm of tonsillar ectopia with cervical and upper thoracic spinal cord edema. She was taken to surgery for a suboccipital decompression with expansile duraplasty and extra-pial electrocautery to shrink the right tonsil. IONM demonstrated improvement in motor evoked potentials (MEPs) during the bony decompression. Postoperatively, she very quickly had full recovery of strength and mobility.

## Case Presentation

### Presentation

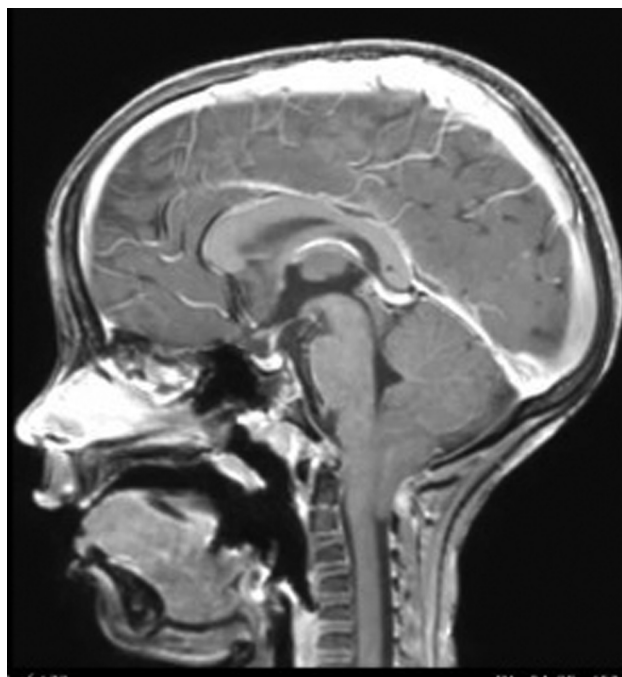A 5-year-old girl with no significant past medical history was brought to an outside hospital due to abnormal gait. She reported that she was rolling on the couch and put her legs over her head, then suddenly felt a pop in her neck and back. She acutely felt “clumsy” and “twisty” and she fell when trying to walk. The next morning, her right leg remained very weak, she was unable to ambulate without assistance, and she was unable to void or have a bowel movement.

Upon arrival at our institution, she was awake and alert, but remained unable to ambulate or stand without assistance. Motor examination revealed 3/5 strength in the right hip and plantar flexion, and 2/5 dorsiflexion. She had no other focal neurological deficits. MRI of the cervical spine showed a 15-mm CM-I with cervical cord edema and mass effect on the brain stem (►Fig. 1). Spinal cord edema extended into the upper thoracic region to the level of T7 (►Fig. 2). Given her acute right lower extremity weakness and imaging findings, she was started on steroids as recommended by the neurology team, followed by urgent decompressive surgery.

### Operation

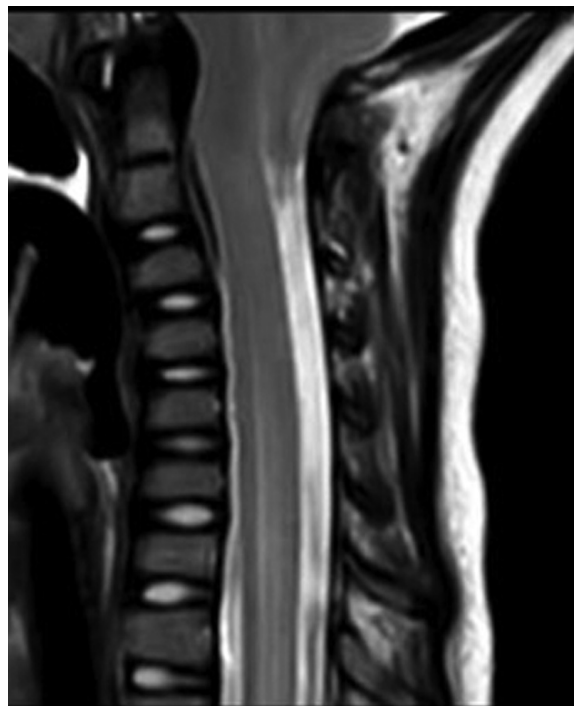
The patient was brought to the operating room, anesthetized, and intubated. Neuromonitoring electrodes were placed for continuous monitoring of MEPs and somatosensory evoked potentials (SSEPs). Initial MEPs showed small-amplitude responses from the left abductor hallucis, as well as small and inconsistent responses from the left tibialis anterior. The right tibialis anterior and abductor hallucis responses were absent or unreliable at prepositioning baseline. The patient was positioned prone with no change in the signals.

A suboccipital craniectomy and C1 laminectomy were performed. Almost immediately after bony decompression, the patient had mild improvement in the left upper extremity MEPs as well as an 827% increase in the amplitude of the



**Fig. 1** Magnetic resonance imaging (MRI) showing Chiari malformation type I (CM-I).

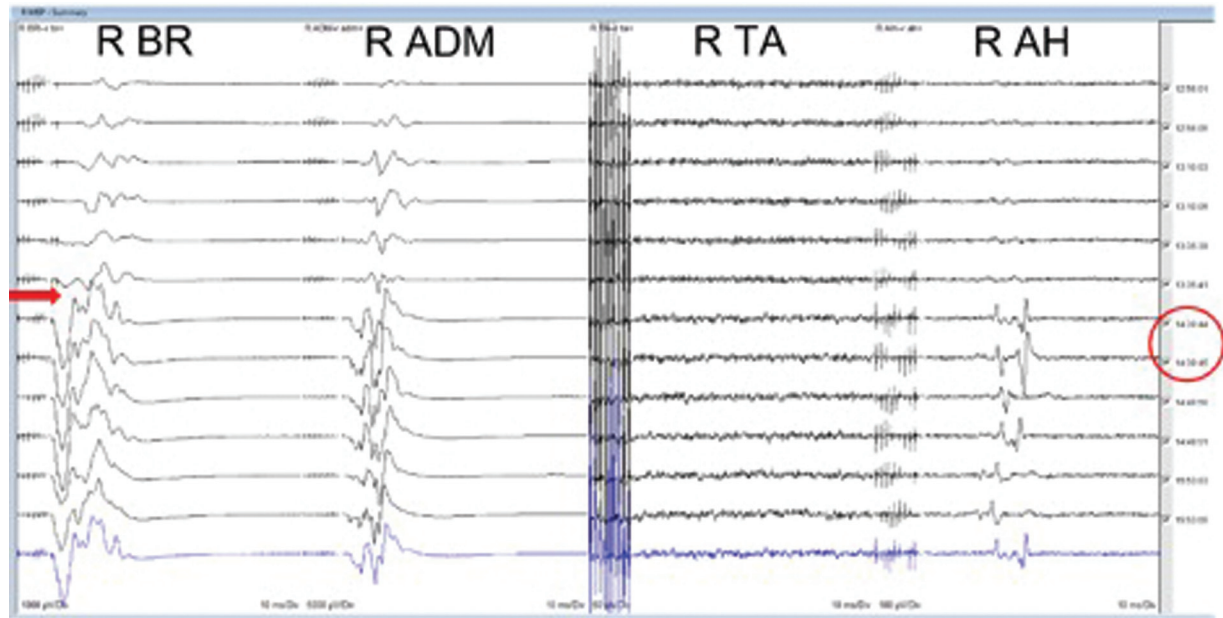
left abductor hallucis response (►Table 1). Right-sided MEPs showed an immediate and significant improvement in upper and lower extremity responses. The right abductor hallucis response became present and reliable with a small but complex multiphasic response (►Fig. 3). The improvement in MEPs continued to be stable after the dura was opened and



**Fig. 2** Preoperative magnetic resonance imaging (MRI) of the thoracic spine demonstrating cervical and upper thoracic spinal cord edema.

**Table 1** Motor evoked potentials (MEPs) pre- and post-decompression

	Left pre-incision	Left post-bony decompression	Right pre-incision	Right post-bony decompression
Brachioradialis	723.31 $\mu$ V	849.6 $\mu$ V	241.1 $\mu$ V	1,492.54 $\mu$ V
Adductor digiti minimi	1,584.39 $\mu$ V	1,699.2 $\mu$ V	1,079.22 $\mu$ V	5051.66 $\mu$ V
Tibialis anterior	24.68 $\mu$ V	31.57 $\mu$ V	0	0
Abductor hallucis	33.3 $\mu$ V	275.55 $\mu$ V	0	58.55 $\mu$ V

**Fig. 3** Right side motor evoked potentials (MEPs) pre- and post-decompression. The red arrow indicates time of bony decompression. Traces below the arrow show improved MEP response.

for the remainder of the surgery. SSEP responses were present and reliable from all extremities pre-incision, and showed no significant change after decompression.

Upon exposure, it was seen that her cerebellar tonsils were compressed against the brain stem down to the level of C2. The adhesions around the tonsils were dissected free. As the right tonsil was notably larger than the left, it was rounded slightly using gentle bipolar electrocautery, taking care not to violate the pia. This visibly improved the cerebrospinal fluid (CSF) flow around the tonsils, and the cerebellum became more appropriately pulsatile. Expansile duraplasty was performed using DuRepair (Medtronic; Minneapolis, MN). After dural closure, CSF leak was not observed with Valsalva maneuver.

### Postoperative Course

Upon awakening, the patient was able to move all four extremities spontaneously. Her right lower extremity strength was drastically improved postoperatively. She was able to spontaneously void that afternoon, and she was discharged 3 days after surgery with normal ambulation. At her 2-week follow-up appointment, she presented with a normal gait with full strength and mobility. Her parents

denied any residual bowel or bladder dysfunction. She reported mild headaches that were improving and she had no focal neurological deficits on her examination.

### Discussion

This is a unique case of closely correlated neuromonitoring, clinical findings, and imaging in an acutely presenting child with CM-I. The use of IONM is debated and studies have begun exploring the association of presentation, IONM, and outcomes in patients with CM-I.<sup>15,17</sup> Some show that IONM may be useful to determine the efficacy of decompression, assess the risk of neurological injury, and prevent complications from manipulation of the craniocervical junction.<sup>15,18,19</sup>

The association between radiologic imaging of CM-I patients and IONM findings is inconsistent. One study found no relationship between the extent of CM-I tonsillar ectopia and intraoperative brain stem auditory evoked potentials.<sup>17</sup> Another study of patients undergoing suboccipital decompression for symptomatic CM-I showed significant improvement in the conduction of median nerve SSEPs and brainstem auditory evoked potentials (BAEPs) following craniectomy, regardless of the level of herniation.<sup>20</sup> This is challenged by Zamel et al's

study that found a significant correlation between the degree of tonsillar herniation and IONM findings and suggested that syringomyelia was the most significant predictor of intraoperative improvement in BAEPs.<sup>21</sup> It is unclear, however, how these changes in IONM correlate with postoperative clinical findings.

The correlation of severity of preoperative and postoperative neurological symptoms with IONM also varies. Studies in adult CM-I patients with chronic symptoms have shown limited correlation with IONM. In one study, the majority of patients had syringomyelia at the time of surgery, and only patients with syringomyelia had distorted electrophysiology parameters. Despite intraoperative changes in neuromonitoring, there were no significant correlations between IONM and postoperative clinical findings.<sup>15</sup> Another prospective study found increases in BAEPs upon bony decompression, but questions whether the improvement seen intraoperatively is a good indicator of postoperative clinical improvement.<sup>18</sup>

However, cases with acute preoperative symptoms have described IONM findings that correlate with the postoperative clinical course. For example, there was immediate improvement in MEPs after suboccipital decompression and improvement in postoperative strength in an 11-month-old with CM-I who presented with acute hemiparesis from a ground level.<sup>10</sup> Similar to our case, this patient had crowding at the craniocervical junction with tonsillar herniation, cervical cord spinal edema, and a presyrinx.<sup>10</sup> Studies show that the majority of improvement in BAEPs occurs after bony decompression rather than duraplasty, suggesting that IONM improvement will correlate with clinical outcomes in the cases where crowding of the posterior fossa is the main cause of symptomatology.<sup>18,22,23</sup>

Acute paresis is associated with cord edema, and neurological deficits usually improve drastically upon decompression.<sup>9,10</sup> Acute neurological deterioration has been associated with increased length, size, and rostral extension of the syringomyelia, requiring urgent decompression.<sup>24</sup> The edema associated with trauma to the cervical cord likely magnifies crowding of the posterior fossa in the setting of CM-I. While it is rare to need to surgically decompress a CM urgently, IONM may be beneficial to assess adequate decompression to the edematous spinal cord in these acute cases.

## Conclusion

Acute weakness after mild trauma in the setting of previously asymptomatic CM-I showed close correlation with IONM, clinical findings, and imaging. This close correlation may not be consistent across different populations of patients with CM. IONM during decompressive surgery for CM-I may be most useful in patients who present acutely with cervical cord edema.

### Conflict of Interest

None declared.

## References

- Jussila MP, Nissilä J, Vakkuri M, et al. Preoperative measurements on MRI in Chiari 1 patients fail to predict outcome after decompressive surgery. *Acta Neurochir (Wien)* 2021;163(07):2005–2014
- Langridge B, Phillips E, Choi D. Chiari malformation type 1: a systematic review of natural history and conservative management. *World Neurosurg* 2017;104:213–219
- Atchley TJ, Alford EN, Rocque BG. Systematic review and meta-analysis of imaging characteristics in Chiari I malformation: does anything really matter? *Childs Nerv Syst* 2020;36(03):525–534
- Talamonti G, Marcati E, Gribaudo G, Picano M, D'Aliberti G. Acute presentation of Chiari 1 malformation in children. *Childs Nerv Syst* 2020;36(05):899–909
- Tubbs RS, Lyster MJ, Loukas M, Shoja MM, Oakes WJ. The pediatric Chiari I malformation: a review. *Childs Nerv Syst* 2007;23(11):1239–1250
- Khatib MY, Elshafei MS, Shabana AM, et al. Arnold-Chiari malformation type 1 as an unusual cause of acute respiratory failure: a case report. *Clin Case Rep* 2020;8(10):1943–1946
- Florou C, Andreanos K, Georgakoulas N, et al. Acute visual loss secondary to Arnold Chiari type I malformation completely resolving after decompressive posterior fossa surgery. *Int Med Case Rep J* 2020;13:657–661
- Carew CL, Prasad A, Tay KY, de Ribaupierre S. Unusual presentation of Chiari I in toddlers: case reports and review of the literature. *Childs Nerv Syst* 2012;28(11):1965–1970
- Miranda SP, Kimmell KT, Silberstein HJ. Acute presentation of Chiari I malformation with hemiparesis in a pediatric patient. *World Neurosurg* 2016;85(366):366.e1–366.e4
- Young CC, Ellenbogen RG, Hauptman JS. Acute traumatic presentation of Chiari I malformation with central cord syndrome and presyrinx in an infant. *Surg Neurol Int* 2019;10(253):253
- Strike SA, Hassanzadeh H, Jain A, et al. Intraoperative neuromonitoring in pediatric and adult spine deformity surgery. *Clin Spine Surg* 2017;30(09):E1174–E1181
- Fehlings MG, Brodke DS, Norvell DC, Dettori JR. The evidence for intraoperative neurophysiological monitoring in spine surgery: does it make a difference? *Spine* 2010;35(9, Suppl):S37–S46
- Ferguson J, Hwang SW, Tataryn Z, Samdani AF. Neuromonitoring changes in pediatric spinal deformity surgery: a single-institution experience. *J Neurosurg Pediatr* 2014;13(03):247–254
- Barzilai O, Roth J, Korn A, Constantini S. The value of multimodality intraoperative neurophysiological monitoring in treating pediatric Chiari malformation type I. *Acta Neurochir (Wien)* 2016;158(02):335–340
- Roser F, Ebner FH, Liebsch M, Tatagiba MS, Naros G. The role of intraoperative neuromonitoring in adults with Chiari I malformation. *Clin Neurol Neurosurg* 2016;150:27–32
- Rasul FT, Matloob SA, Haliasos N, Jankovic I, Boyd S, Thompson DNP. Intraoperative neurophysiological monitoring in paediatric Chiari surgery—help or hindrance? *Childs Nerv Syst* 2019;35(10):1769–1776
- Heffez DS, Golchini R, Ghorai J, Cohen B. Operative findings and surgical outcomes in patients undergoing Chiari 1 malformation decompression: relationship to the extent of tonsillar ectopia. *Acta Neurochir (Wien)* 2020;162(07):1539–1547
- Anderson RCE, Dowling KC, Feldstein NA, Emerson RG. Chiari I malformation: potential role for intraoperative electrophysiological monitoring. *J Clin Neurophysiol* 2003;20(01):65–72
- Kawasaki Y, Uchida S, Onishi K, Toyokuni M, Okanari K, Fujiki M. Intraoperative neurophysiological monitoring for prediction of postoperative neurological improvement in a child with Chiari type I malformation. *J Craniofac Surg* 2017;28(07):1837–1841
- Chen JA, Coutin-Churchman PE, Nuwer MR, Lazareff JA. Suboccipital craniotomy for Chiari I results in evoked potential conduction changes. *Surg Neurol Int* 2012;3(165):165

- 21 Zamel K, Galloway G, Kosnik EJ, Raslan M, Adeli A. Intraoperative neurophysiologic monitoring in 80 patients with Chiari I malformation: role of duraplasty. *J Clin Neurophysiol* 2009;26(02):70–75
- 22 Anderson RCE, Emerson RG, Dowling KC, Feldstein NA. Improvement in brainstem auditory evoked potentials after suboccipital decompression in patients with Chiari I malformations. *J Neurosurg* 2003;98(03):459–464
- 23 Kennedy BC, Kelly KM, Phan MQ, et al. Outcomes after suboccipital decompression without dural opening in children with Chiari malformation Type I. *J Neurosurg Pediatr* 2015;16(02):150–158
- 24 Almotairi FS, Tisell M. Acute deterioration of adults with Chiari I malformation associated with extensive syrinx. *Br J Neurosurg* 2020;34(01):13–17