

Intestinal MRI in Inflammatory Bowel Disease – Literature and Survey-Based Recommendations regarding Reporting by the German Radiological Society (DRG) and the German Competence Network for Inflammatory Bowel Diseases

Intestinale MRT bei chronisch-entzündlichen Darmerkrankungen – Literatur- und umfragebasierte Empfehlungen zur Befundung durch die AG Gastrointestinal-/Abdominaldiagnostik der DRG und der AG Bildgebung des Kompetenznetz Darmerkrankungen

Authors

Johannes Wessling¹, Torsten Kucharzik², Dominik Bettenworth³, Andreas Luegering⁴, Christian Maaser², Lars Grenacher⁵, Markus S. Juchems⁶, Kristina I. Ringe⁷ , Thomas Lauenstein⁸, Andreas G. Schreyer⁹

Affiliations

- 1 Department of Radiology, Clemenshospital GmbH Munster, Germany
- 2 Department of Gastroenterology, Lüneburg Municipal Hospital Clinic for General Internal Medicine and Gastroenterology, Lüneburg, Germany
- 3 Department for CED, praxis for internal medicine and CED, Himmelreichallee 37-41, Muenster, Germany
- 4 center for gastrointestinal diseases, mvz portal 10 Muenster, Germany
- 5 Imaging and Prevention Center, Conradia Radiology Munich, Germany
- 6 Department of interventional and diagnostic radiology, Schmieder Hospitals – Hospital Konstanz, Germany
- 7 Department of Radiology, MHH, Hannover, Germany
- 8 Department of Radiology, Evangelical Hospital Düsseldorf Medical Clinic, Düsseldorf, Germany
- 9 Institute of diagnostic and interventional radiology, Brandenburg Medical School Theodor Fontane, University Hospital Brandenburg a. d. Havel, Germany

Key words

abdomen, ileum, MR-imaging, inflammation, small bowel

received 19.08.2022

accepted 07.01.2023

published online 03.05.2023

Bibliography

Fortschr Röntgenstr 2023; 195: 675–690

DOI 10.1055/a-2036-7190

ISSN 1438-9029

© 2023, Thieme. All rights reserved.

Georg Thieme Verlag KG, Rüdigerstraße 14, 70469 Stuttgart, Germany

Correspondence

Prof. Johannes Wessling
Department of Radiology, Clemenshospital GmbH Munster,
Düesbergweg 124, 48153 Munster, Germany
Tel.: +497/02 51/9 76 26 21
J.Wessling@alexianer.de

ABSTRACT

Background MR-enterography/enteroclysis (MRE) is increasingly used for primary diagnosis, detection of complications, and monitoring of patients with inflammatory bowel disease (IBD). Standardization of reporting is relevant to ensure quality of the methodology and to improve communication between different faculties. The current manuscript describes the features that are required for optimized reporting of MRE in IBD.

Methods An expert consensus panel of radiologists and gastroenterologists conducted a systematic search of the literature. In a Delphi process, members of the German Radiological Society (DRG) and members of the Competence Network for Inflammatory Bowel Diseases voted on relevant criteria for the reporting of findings in MRE. Based on the voting results, statements were developed by the expert consensus panel.

Results Clinically relevant aspects of MRE findings have been defined to optimize reporting and to standardize terminology. Minimal requirements for standardized reporting are suggested. The statements focus on the description of disease activity as well as on complications of IBD. Attributes of intestinal inflammation are described and illustrated by exemplary images.

Conclusion The current manuscript provides standardized parameters and gives practical recommendations on how to report and how to characterize MRE findings in patients with IBD.

Key points:

1. Systematic overview provides practice-oriented recommendations and names and evaluates the decisive criteria for reporting and interpretation of MRI in inflammatory bowel disease.
2. Standardized terminology and reporting criteria for MRI in IBD improves interdisciplinary communication.
3. Standardized collection and documentation of MRI findings in IBD helps to further establish the method and to improve care for IBD patients.

Citation Format

- Wessling J, Kucharzik T, Bettenworth D et al. Intestinal MRI in Inflammatory Bowel Disease – Literature and Survey-Based Recommendations regarding Reporting by the German Radiological Society (DRG) and the German Competence Network for Inflammatory Bowel Diseases. *Fortschr Röntgenstr* 2023; 195: 675–690

ZUSAMMENFASSUNG

Hintergrund Bei Patienten mit chronisch-entzündlichen Darmerkrankungen (CED) wird zur Diagnosestellung, Erkennung von Erkrankungskomplikationen sowie zur Verlaufskontrolle die MRT eingesetzt. Eine systemische Befunderhebung und Dokumentation helfen, die Qualität der Befunderstellung und die Kommunikation zwischen den Fachgruppen zu verbessern. Die vorliegende Übersicht beschreibt die Voraussetzungen für Befunderhebung und Interpretation der MRE bei Patienten mit CED.

Methoden Eine Experten-Konsensusgruppe bestehend aus Radiologen und Gastroenterologen führte eine systematische

Literaturrecherche durch. In einem Delphi-Verfahren wurde unter Mitgliedern der Deutschen Röntgengesellschaft und des Kompetenznetzes Darmerkrankungen über relevante Kriterien bei der Befunderhebung von MRE-Befunden abgestimmt. Die daraus resultierenden Statements wurden in einer Experten-Konsensusgruppe verabschiedet.

Ergebnisse Praxisorientierte Empfehlungen für eine optimale Befunderhebung mit einer standardisierten Terminologie wurden entwickelt. Der Fokus der Erhebung lag auf der Beschreibung der Entzündungsaktivität sowie der extramuralen Komplikationen chronisch-entzündlicher Darmerkrankungen. Minimale Anforderungen für eine standardisierte Befunderhebung wurden definiert.

Schlussfolgerung Die vorliegende Übersicht gibt praktische Empfehlungen zur Optimierung und Vereinheitlichung der Befunderhebung und Beurteilung von MRE-Untersuchungen bei CED.

Kernaussagen:

1. Die systematische Übersicht gibt praxisrelevante Empfehlungen, benennt und bewertet die entscheidenden Kriterien für Befundung und Interpretation der MRT bei CED.
2. Standardisierte Terminologie und Befundkriterien für die MRT bei CED verbessern die interdisziplinäre Kommunikation.
3. Die standardisierte Erhebung und Dokumentation von MRT-Befunden bei CED hilft, die Methode weiter zu etablieren und die Versorgung von CED-Patienten zu verbessern.

Introduction

Chronic inflammatory bowel diseases (IBDs) require medication typically for the patient's entire life, and surgical treatment is also often required. In Germany, more than 300 000 people have been diagnosed with an IBD [1]. In Germany in the year 2019 alone, approximately 25 500 patients with Crohn's disease were treated on an inpatient basis [2].

Imaging has become increasingly important for the treatment of patients with chronic inflammatory bowel diseases for both initial diagnosis and follow-up. In addition to bowel ultrasound, MRI in particular is used for diagnosis and staging and for determining disease activity and severity and complications in IBD [3]. Numerous studies and meta-analyses show the high sensitivity of MR and CT enterography (MRE and CTE) and bowel ultrasound for the detection or exclusion of lesions of the small intestine [4] as well as for the detection of extramural complications [5]. Furthermore, more recent data highlight the significance of cross-sectional imaging for treatment monitoring. Patients with endoscopic mucosal healing and additional transmural healing on MRE have a better clinical outcome [6–9]. Thus, in patients with Crohn's disease, in addition to endoscopic evaluation, imaging of the transmural disease activity (transmural response) is becoming

increasingly important a target criterion for anti-inflammatory treatments [10].

The interdisciplinary cooperation of gastroenterologists, radiologists, and surgeons is thus an important requirement for optimal management of IBD patients. This requires common consensus-based understanding with respect to image criteria, interpretation of findings, and evaluation. Previously, reporting standards have been published by individual professional societies [11–14]. The ECCO (European Crohn's and Colitis Organization) and ESGAR (European Society of Gastrointestinal and Abdominal Radiology) recently proposed the first joint reporting standards for MRI, CT, and bowel ultrasound [15]. The goal of comprehensive implementation of standardized reporting has still not been reached in spite of the broad use of imaging in IBD.

The goal of the Work Group for Gastrointestinal/Abdominal Imaging of the Germany Radiological Society and the Imaging Work Group of the Competence Network for Inflammatory Bowel Diseases as national representation of the IBUS initiative (International Bowel Ultrasound Group; <https://ibus-group.org>) is to address this lack of standardization.

The present study provides recommendations for optimizing and standardizing MRI reports in IBD based on the current literature. The consensus was created by the members of the Work

Group for Gastrointestinal/Abdominal Imaging of the German Radiological Society in collaboration with the Imaging Work Group of the Competence Network for Inflammatory Bowel Diseases.

Methods

Representatives of the Imaging Work Group of the Competence Network for Inflammatory Bowel Diseases (T.K., C.M.) as national representation of the IBUS initiative (International Bowel Ultrasound Group; <https://ibus-group.org>) and the Work Group for Gastrointestinal/Abdominal Imaging (A.S., J.W.) of the German Radiological Society conducted a systematic search of the literature using the key words ((Crohn's disease) OR (inflammatory bowel disease) OR (ulcerative colitis)) AND ((imaging) OR (ultrasound) OR (ultrasonography)) OR (mri) AND ((systematic review) OR (score) OR (consensus) OR (guideline) OR (recommendation)) AND ((bowel) OR (intestinal)) AND ((activity) OR (monitor)) AND (constriction, pathologic [Mesh]) OR (stricture) OR (stenosis) AND (fistula) AND (abscess)) in the NLM PubMed, Cochrane Database. Based on this, relevant criteria were defined and provided to the members of the Competence Network and the members of the German Radiological Society for evaluation and voting. Criteria in the categories medical history, examination equipment, patient preparation, quality of the examination, description of the findings, and total evaluation (see appendix 1) were addressed. The resulting criteria were approved in an expert consensus group. 55 gastroenterologists (for ultrasound [16]) and 31 radiologists (for MRE) responded to the questionnaire online. Recommendations and guidelines for MRE were created based on the responses. Only statements with consensus of at least 75% of the participants were included in the recommendations. As a rule, these statement can only be considered in context with the accompanying texts and an overview of the literature.

Recommendations regarding reporting in MRE

General recommendations

Standardized reporting for creating MRE reports should be used in order to improve communication with medical practitioners. Reports should include all relevant disease manifestations and be able to be compared to reports by different examiners. The examination quality should also be included (expert consensus of the Work Group for Gastrointestinal/Abdominal Imaging; A.S., J.W. and the Imaging Work Group of the Competence Network for Inflammatory Bowel Diseases: T.K., C.M.).

The report is based on a standardized MRE examination (fasting for at least 4 hours, oral administration of 1.5 L mannitol 2.5% or methyl cellulose 0.5%, T2w with and without fat saturation axial and coronal, DWI axial, T1 3D GRE sequences after gadolinium axial and coronal, optionally TrueFisp cine sequences as well as image acquisition in a prone position to reduce intestinal peristalsis and FOV). In addition to the dedicated indication/med-

ical history, the type and quantity of oral and/or rectal contrast enhancement and the administration of butylscopolamine bromide should be noted in the report. Qualitative limitations on reporting, like insufficient bowel distension or artifacts, as well as a lack of visualization of the anal canal should be mentioned. Distant intestinal segment(s), anastomoses, or pouches should be mentioned at the beginning.

The report should use standard terminology for the description of pathological structures. Disease activity criteria relevant for MRI should be categorized separately in the report as mural, extramural, or extraintestinal. The inflammation status (degree of activity), stenosis status, penetration status (fistulas, abscesses), and complication status (extraintestinal manifestations) should be evaluated on the basis of the reporting criteria and in the clinical context (summarized in ► **Table 1, 2**).

There are various scores for evaluating inflammatory activity in Crohn's disease. For MRE these are partially validated scores like the (global) MaRIA score, simplified MaRIA score, London score, Clermont score, and MEGS score [17–22]. These semiquantitative scores are based on visual assessment (ulcers, high intramural T2 signal) and quantitative measurements (wall thickness, contrast enhancement, etc.) and differ with respect to the consideration of individual variables (e. g., in the Clermont score it is not necessary to evaluate Gd enhancement) and the weighting of the influencing variables. Most activity scores are currently used in scientific studies due to their reproducibility. It should be noted that these scores do not sufficiently reflect the intraindividual and intersegmental variation in inflammatory activity and thus the dynamic spectrum of IBDs. Therefore, scores are not always helpful with respect to clinical treatment decisions and are not an obligatory part of reporting.

Description of findings

Location

RECOMMENDATION 1

The number and location of intestinal segments with pathological changes should be described (agreement 96.8%).

The spectrum of inflammatory activity can vary on an intraindividual basis from location to location. MR enterography is suitable for adequately visualizing the dynamic spectrum and morphological continuum of disease manifestations in IBDs [12]. Affected segments of the small and large intestine should be documented with a description of the location (see ► **Table 1**) and should be individually interpreted and evaluated. The same is true for special anatomical situations like anastomotic recurrence, neoterminal ileum, and pouch. The disease activity at a certain location is important for the description of the disease classification, for example, according to the Montreal and Paris classifications in pediatrics and is also used to evaluate treatment response.

► **Table 1** Structured reporting for MR enterography in IBD. Categories of findings and imaging findings/criteria in IBD.

Categories of findings	Imaging findings	Comments
Medical history	HIS search, referring physician data, patient consultation	Known IBD? Perianal fistulas or extraintestinal manifestations known? List relevant bowel surgeries, ascertain anastomosis situation, determine presence of neoterminal ileum Medical question to be examined with MRE: Bowel disease, course/monitoring, which treatment?
Patient preparation	Fasting < 4 h	Document fasting status < or > 4 h Specify type and quantity of oral contrast enhancement (e. g. 1 L 2.5% Mannitol®) Make a note of Buscopan® administration 1x or 2x (start of examination/prior to Gd)
Image quality	Likert scale (1–5, very good to insufficient)	Specify patient-side and sequence-side image artifacts affecting the evaluation of findings
	Anal canal fully visualized	Complete visualization of sphincter complex including perianal region
Description of findings		
Affected bowel segment	Location	Provide correct anatomical information, particularly position in relation to ligament of Treitz and ileocecal valve. Pay attention to special situations like anastomoses, neoterminal ileum, and pouch. Pay attention to involvement of the appendix
	Length	Short (≤ 5 cm) Segmental (6–40 cm) Long (> 40 cm)
	Wall thickness	Look for sufficient distension, no measurement in collapsed bowel loops Asymmetrical: typical for Crohn's disease, mesenteric side, concentric but frequent Symmetrical: nonspecific, consider other differential diagnoses Normal (< 3 mm) Low (3–5 mm) Moderate (> 5 –9 mm) Severe (≥ 10 mm) In the case of > 15 mm and/or extension into the mesentery consider carcinoma.
	Stenosis	Criteria: Wall thickening, constriction of the lumen $> 50\%$, and prestenotic dilation ≥ 3 cm. If prestenotic dilation is absent: qualify as "probable stenosis" Describe location and length of stenosis. Determine inflammatory activity based on criteria described under "intramural manifestations". Look for penetrating complications in the proximal and middle portions of the stenosis
Intramural manifestations	Hyperenhancement	Compared with enhancement of an immediately adjacent segment without wall thickening. Pay attention to the possibility of false-positive findings in the jejunum and collapsed bowel segments due to increased fold density
	Two/three layers	Can be evaluated in T2w and post-Gd. Two but particularly three layers with submucosal edema (always in connection with T2w images and fat saturation) indicate active IBD
	Transmural homogeneous	No stratification, transmural enhancement, homogeneous to patchy, edema determines activity: absence of edema – mild activity
	Wall edema in T2	Evaluate in T2w with fat saturation, rule out submucosal fat
	Submucosal fat	SI decrease in T2w with fat saturation, high signal intensity in DIXON
	Diffusion restriction	Pay attention to shine-through effects caused by edema, always consult ADC
	Ulcers	Wall defects on the luminal side in T2w and/or post-Gd
	Intramural abscess	Differentiate from ulcers, DWI with diffusion restriction
	Sacculations	Antimesenteric due to shortening along the mesenteric border This can be caused by chronic scarring or more rarely by inflammation
	Loss of haustration	Observed in ulcerative colitis both in the acute inflammation stage and in the regenerative stage.
Pseudopolyps	Can be large and confused with tumors, e. g., MALT lymphoma.	

► **Table 1** (Continuation)

Categories of findings	Imaging findings	Comments
Extramural manifestations	Comb sign	Dilated vasa recta are seen near the intestinal wall on the mesenteric side. Compare with diameter of an adjacent bowel loop without wall thickening
	Creeping fat	Fibrofatty proliferation typically on the mesenteric side, sometimes also concentric. Pay attention to indirect signs like distancing of small bowel loops, can be better delimited on ultrasound in the case of slightly higher echogenicity and is an expression of inflammatory activity here
	Mesenteric edema	Can be effectively evaluated in T2w with fat saturation and post-Gd, indicates activity
	Free fluid	Interenteric, usually between the serous leaflets of two mesenteric roots = intra-peritoneal, not subperitoneal
	Mesenteric lymphadenopathy	> 15 mm SAD Crohn's involvement probable, no established activity criterion
Extramural complications	Sinus tracts	Specify origin with clock position, sinus tracts and fistulas occur particularly in the proximal and middle segments of stenoses and in inflammatory bowel segments.
	Internal fistulas	
	External perineal fistulas/abscesses	Present, not present
	Abscess	Determine location and size, in addition to T2w pay attention to DWI with diffusion restriction
	Inflammatory mass	Location, T2w without areas with fluid, DWI without abscess-related diffusion restriction
(Extra)intestinal complications	Diverse	Systematically consider typical extraintestinal manifestations/locations of IBD (sacroiliitis, PSC, pancreatitis, cholelithiasis, nephrolithiasis) In particular, pay attention to mesenteric vein thrombosis, can cause venous bowel congestion with hemorrhagic infarction, not to be confused with IBD manifestation Megacolon in ulcerative colitis

Length

RECOMMENDATION 2

The length and extent of pathological changes in the small and large intestine should be documented (agreement 100%).

The extent of the inflammation should be specified in centimeters and classified as short (≤ 5 cm), medium/segmental (6–40 cm), or long (>40 cm). The affected length of the intestinal wall is not a good individual marker for describing disease activity [23, 24] but can be useful when using scores since some of these are based on the summation of segmental activity scores (“anatomic burden of inflammation”). The Montreal and Paris classifications allow a phenotypical subclassification in various locations of the entire GI tract (non-stricturing/non-penetrating vs. stricturing vs. internally penetrating vs. external perianally penetrating). The length of the affected intestinal wall as well as the inflammatory activity in the affected GI tract segment are not taken into consideration here. Clinically relevant phenotypical overlapping phenomena (e.g. penetrating changes in stenoses) are also only insufficiently addressed.

Wall thickness

RECOMMENDATION 3

The maximum intestinal wall thickness in the most affected intestinal segment should be measured and documented. With the requirement of good bowel distension, the recommended cutoff value in the small and large intestine is 3 mm (agreement 100%).

Intestinal wall thickness is an important parameter for detecting bowel wall inflammation in IBD [23, 25–29]. The wall thickness of a sufficiently distended bowel segment should be measured with T1w or T2w MRE. Measurements in collapsed bowel segments can result in false-positive findings or an overestimation of the degree of inflammation of the intestinal wall.

Normal intestinal wall thickness is 2 mm [30]. However, a significant range between 2 mm and 7 mm is stated in the literature [27, 31–35]. An expert consensus specifies 3 mm as a compromise between sensitivity and specificity to detect active disease [12, 23, 31, 36]. In the sigmoid colon, intestinal wall thicknesses of up to 4 mm can be considered normal in the case of concomitant diverticulosis with hypertrophy of the muscularis propria/mucosae so that 4 mm is preferred by several authors as a cut-off value [35]. When the intestinal wall thickness is measured under standardized conditions, there is good reproducibility for MRE

► **Table 2** Structured evaluation of MR enterography in IBD. Evaluation of findings on the basis of recommended reporting criteria.

Evaluation categories	Content	Evaluation	MRE criteria
Detection status	Manifestations of Crohn's disease?	Nonspecific inflammation	Symmetrical wall thickening, hyperenhancement, other DD possible
		Specific Crohn's disease criteria present	Asymmetrical wall thickening on the mesenteric side, anti-mesenteric sacculation Extramural complications, indicative of skip lesions (also in NSAR)
Inflammatory status	Activity	Crohn's disease not active	No signs of activity, minimal wall thickening, and transmural enhancement correspond to mild, non-active changes
		Crohn's disease active	Signs of activity present: 1. Ulcerations 2. Increased T2 SI Highly active: Three layers with submucosal edema Active: transmural patchy edema 3. Moderate to severe wall thickening (only use in connection with 1 and/or 2)
		Crohn's disease with extramural manifestations	Sinus tracts and/or fistula and/or abscess should be evaluated as signs of activity (active Crohn's disease)
	Accuracy of the evaluation Likert scale (1–5, strongly agree to disagree)	1–5	Optional
Stenosis status	Stenosis	No stenosis	<50 % constriction of the lumen, no prestenotic dilation
		Stenosis probable	>50 % constriction of the lumen, no prestenotic dilation
		Stenosis not active	No signs of activity
		Stenosis active	Signs of activity (increased intramural T2 SI, particularly in the case of three layers, diffusion restriction, ulcers)
	Obstruction	No obstruction	No or only minor prestenotic dilation
		With obstruction	Moderate to severe prestenotic dilation
Accuracy of the evaluation Likert scale (1–5, strongly agree to disagree)	1–5	Optional	
Penetration status	Extramural complications	None	
		Sinus tracts	Location, clock position, association with stenosis or inflammatory bowel segment
		Simple fistulas	
		Complex fistulas	
		Inflammatory mass	Location, bowel loop involvement
	Abscesses	Location, size, able to be drained with image guidance?	
Accuracy of the evaluation Likert scale (1–5, strongly agree to disagree)	1–5	Optional	
Perianal status	External fistulas/abscesses	Not present	
		Present	Simple fistulas or complex fistulas, abscess size, mpMRI of the anal canal with St. James classification recommended

► **Table 2** (Continuation)

Evaluation categories	Content	Evaluation	MRE criteria
Extraintestinal complication status	Extraintestinal manifestations	None	Obtain medical history data, lab results, etc.
		Necrosis of the femoral head	
		Sacroiliitis	
		PSC	
		Pancreatitis	
		Mesenteric vein thrombosis	
		Cholelithiasis	
		Nephrolithiasis	
	Accuracy of the evaluation Likert scale (1–5, strongly agree to disagree)	1–5	Optional

with an ICC = 0.87 (95 % confidence interval 0.82–0.90) and also good agreement with histology [37]. Intestinal wall thickening, contrast enhancement, and diffusion restriction (DWI) (► **Fig. 1**) help to detect affected bowel segments. However, they are ambiguous in the case of multisegmental involvement with skip lesions and are nonspecific for IBD [38]. In contrast, asymmetrical wall thickening particularly on the mesenteric side is considered a specific sign of Crohn’s disease. Inflammatory or fibrotic shortening on the mesenteric side with antimesenteric pseudosacculations significantly increases the specificity [40]. Attention should be paid to concomitant extramural penetrating changes to corroborate the diagnosis of Crohn’s disease.

A descriptive categorization of intestinal wall thickness as normal (< 3 mm), mild (3–5 mm), moderate (5–9 mm), and severe (≥ 10 mm) is useful and has become established. There is no consensus-based correlation between intestinal wall thickness and inflammatory activity. Therefore, acute inflammation and chronic changes in thickened segments of the intestinal wall coexist in IBD. Thus, the measurement of intestinal wall thickness is neither the only nor the best parameter for evaluating inflammatory activity. Other activity parameters (e. g., edema in T2w, stratification phenomena, etc.) should therefore be used in MRE [37] (see below and ► **Table 1**).

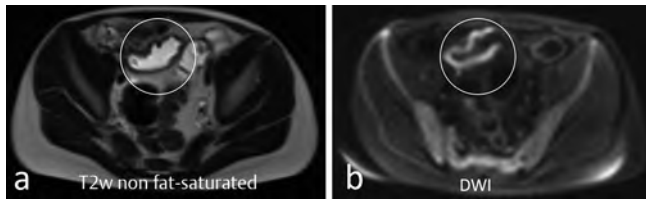
Stenosis

RECOMMENDATION 4

Number, location, and length of stenoses and any association with a surgical anastomosis should be documented. The extent of prestenotic dilation, the intestinal wall thickness, and the presence and severity of concomitant active inflammation within the stricture as well as concomitant fistulas should be documented. Areas suspicious for neoplasia should be noted (agreement 96.7 %).

Approximately half of all Crohn’s disease patients are affected by the stenotic type of the disease [41]. There is currently no consensus regarding the proper definition of stenosis. From an endoscopic perspective, a stenosis that is endoscopically impassable is indicative of stenotic disease. However, the evaluation of “luminal compliance” is limited on MRE. Thus, fixed stenoses can only be conditionally differentiated from strictures caused by spasms (string sign). The established definition of a stenosis (► **Fig. 2**) is the combination of 1. wall thickening, 2. constriction of the lumen > 50 %, and 3. prestenotic dilation ≥ 3 cm of the upstream bowel segment [12, 42, 43]. The degree of prestenotic dilation depends on many factors. In addition to the chronicity of the stenosis, this include the individual degree of filling of the bowel loops and the functional or obstructive properties of the stenosis for the mostly liquid content of the intestine. Concomitant fistulas, usually in the proximal part of the stenosis, can also contribute to a prestenotic buildup of pressure. In the case of a proximal (upstream) stenosis with obstructive properties and a distal collapsed bowel (downstream), further aboral stenosis (tandem stenoses) can be masked. The diagnostic requirement of a prestenotic dilation may thus reduce the sensitivity for the detection of stenosis [44–48]. Stenoses suspected on MRE without verified prestenotic dilation should therefore be described as “probable stenosis”. MRI studies with an adequate reference standard (endoscopy, surgery, or both) showed a sensitivity of 89 % and a specificity of 94 % for the diagnosis of a stenosis [49]. In the same meta-analysis, the sensitivity of bowel ultrasound is 79 % and the specificity is 92 % [49].

The detection of stenoses should be supplemented by the characterization of the inflammatory activity. While inflammatory stenoses can initially be treated with medication-based therapy, stenoses that cannot be treated with medication and include scar tissue are treated endoscopically (balloon dilation) or surgically (≤ 5 cm strictureplasty, > 5 cm resection) [50]. Stenoses usually contain both inflammatory and fibrotic components and thus do not correspond histopathologically to an “either-or” situa-



► **Fig. 1** **a** Moderate wall thickening (5–9 mm) in the ileum without wall edema. **b** Significant diffusion restriction on DWI that helps with the detection of intestinal wall segments with pathological thickening.

tion [51, 52]. In the case of predominant inflammation, areas of fibrosis are also present but are typically centered close around the muscularis propria, while in the case of predominant fibrosis, the fibrotic areas cover the width of the submucosa into the deep subserosa. Hypertrophy of the muscularis propria which is often also present completes the histological picture and contributes to further wall thickening [53].

The selection of optimal treatment depends on which component is dominant [54]. Reliable differentiation cannot be achieved with bowel ultrasound or MRE. Newer technologies like elastography [55] and contrast-enhanced bowel ultrasound may be helpful for determining the degree of fibrosis of a stenosis [56]. However, there are currently no standardized parameters for this. Newer developments in MRE like magnetization transfer or relative Gd enhancement in late acquisitions have also not yet been sufficiently validated for the detection of fibrosis [57].

Penetrating complications in terms of sinus tracts and fistulas often arise from the proximal part of the stenosis, are indicative of inflammatory activity, and should also be documented [43, 58].

In the follow-up, bowel wall thickness, lumen reduction, and prestenotic dilation over the course of the disease can be described and the response to treatment can be characterized [59, 60].

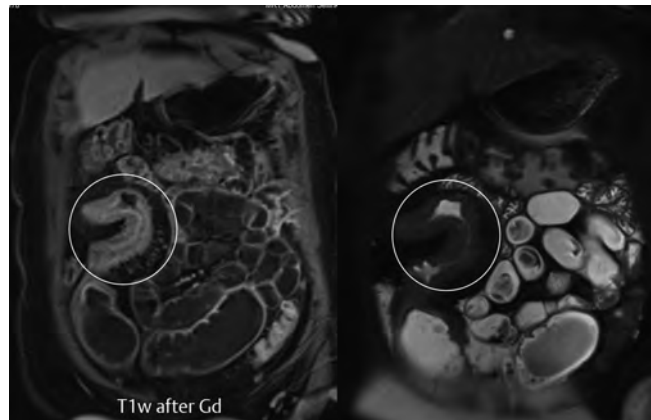
Indications of potential neoplasia, particularly in the case of new stenoses, should be described [61, 62]. Parameters for this are, for example, asymmetry of the stenosis, wall thickening greater than 15 mm, nodular changes, and soft tissue extending into the surrounding tissue [61, 63]. Inflammatory pseudopolyps can sometimes be difficult to differentiate from a carcinoma.

Intramural manifestations

RECOMMENDATION 5

Bowel wall edema (T2w signal), ulcerations, and stratification phenomena should be included in the MRE examination for the evaluation of transmural inflammatory activity. A diffusion restriction is supportive of but not specific for active inflammation. The evaluation of contrast enhancement should be qualitative (agreement 93.5%).

In addition to wall thickness, other parameters like bowel wall edema and intramural ulcerations, determine the disease activity and should be described.



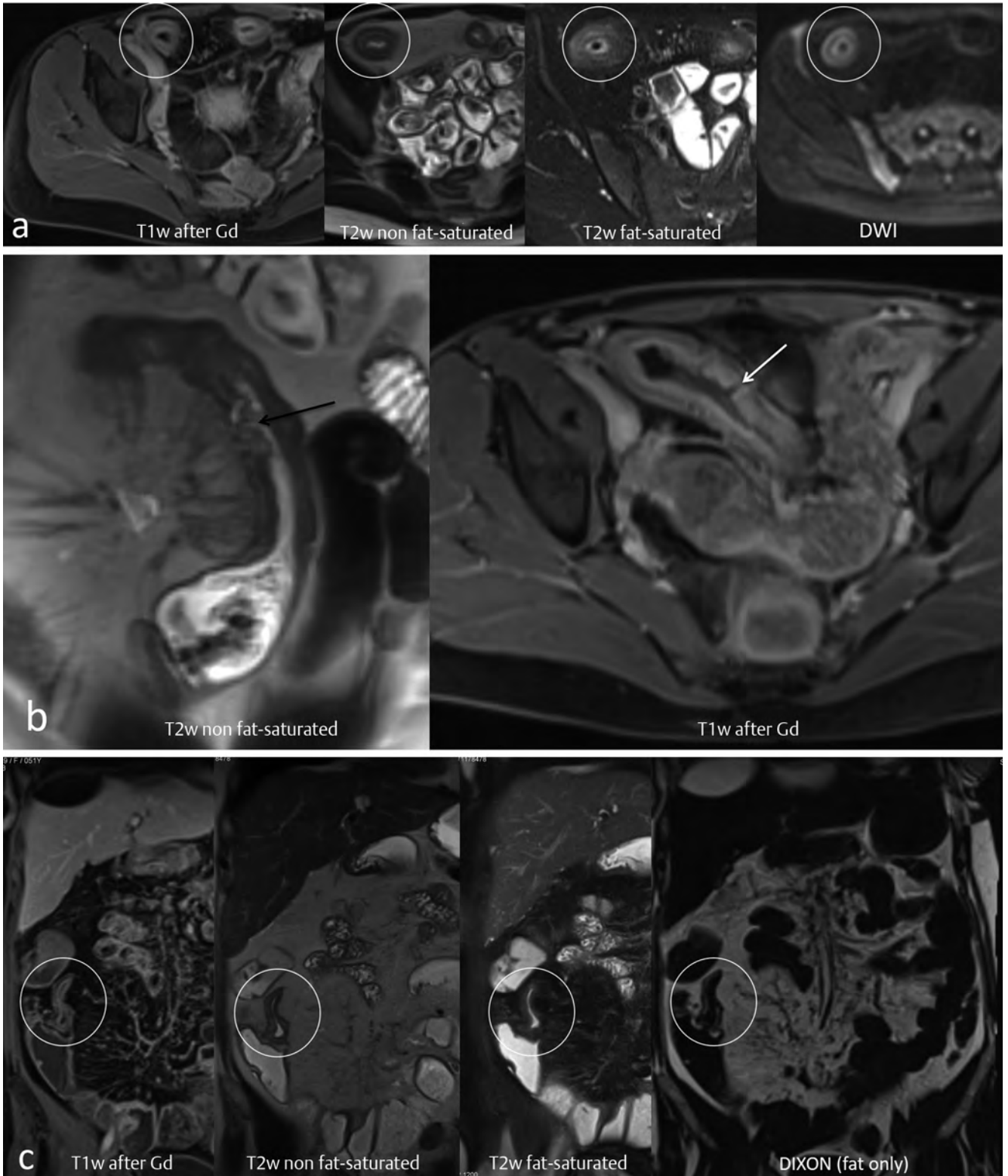
► **Fig. 2** Crohn's disease with stenosis (circle) in terms of wall thickening with constriction of the lumen > 50% and prestenotic dilation. Two layers without significant wall edema. Comb sign-positive, no extramural manifestations.

Wall edema: A high T2 wall signal in terms of intramural wall edema is predictive for high inflammatory activity [17, 64–67]. In the case of homogeneous wall thickening, edema can have a patchy appearance in the affected bowel segments. In the case of stratification phenomena, particularly with three layers, the edema is distributed concentrically in the submucosa (► **Fig. 3a**). Edema is detected in T2w sequences with fat saturation. Otherwise, it can be confused with submucosal fat. The latter is evidence of chronic inflammation without activity (► **Fig. 3a**).

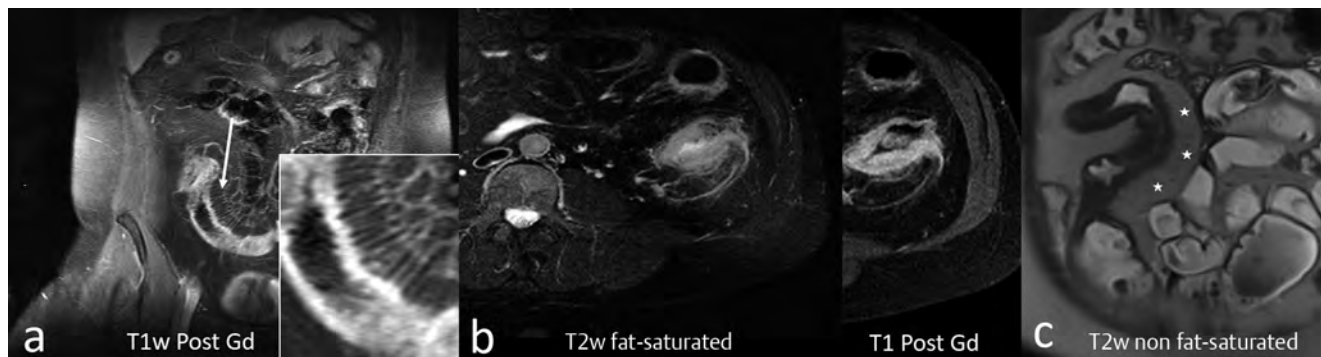
Ulcers: Ulcerations are typically linear (the term penetrating ulcer should be avoided) and are seen on MRE as small focal interruptions in the surface of the mucosa with defect-like extension (containing air or fluid) into the intestinal wall (► **Fig. 3b**). Ulcerations correlate endoscopically with high inflammatory activity [21].

Diffusion restriction: Diffusion restriction with a high B-factor should be documented as present or not present. Due to edema-based T2 shine-through effects, comparison with ADC maps is needed. DWI has moderate sensitivity and specificity for the detection of skip lesions in Crohn's disease (► **Fig. 1, 3a**) [68–70]. The possibility of false-positive findings due to insufficient bowel distension or an increased physiological fold density in the jejunum must be taken into consideration [71]. DWI as a single criterion for inflammatory activity is of no significance. In contrast, a hyperintense T2 signal and simultaneous diffusion restriction correlate with moderate to high inflammatory activity [71–74]. If further criteria are met, diffusion restriction supports the assumption of high inflammatory activity [67, 75].

Contrast enhancement: Neoangiogenesis and thus bowel wall vascularization is an important pathophysiological mechanism in chronic intestinal inflammation and contributes significantly to disease activity [31, 76, 77]. Various semiquantitative color Doppler scores (particularly Limberg score IBUS-CDS) correlate with the histological and endoscopic disease activity [78–80]. In contrast to IBD-induced neovascularization that can be detected on ultrasound, mural gadolinium enhancement in the late arterial (= enteric) to the portal venous phase [11] on MRE is subject to



▶ **Fig. 3** a Segmental wall thickening (circle) in Crohn's disease with three layers and signs of active inflammation. a In T1w+contrast enhancement of mucosa and muscularis propria/serosa with submucosa with relatively low signal intensity. The submucosa has high signal intensity in T2w without FS. In T2w with FS, confirmation of submucosal edema. Diffusion restriction on DWI that follows the stratification pattern. b Segmental wall thickening in Crohn's disease. The arrows mark linear ulcers to be considered signs of inflammatory activity in addition to the submucosal edema. c Segmental wall thickening (circle) in Crohn's disease with three layers and signs of a mild course and submucosal fat in terms of chronicity. In T1w+contrast enhancement of mucosa and muscularis propria/serosa with submucosa with relatively low signal intensity. The submucosa has high signal intensity in T2w without FS. In T2w with FS, submucosa with low signal intensity in terms of submucosal fat. In DIXON confirmation of submucosal fat with bands of high signal intensity in the submucosa.



► **Fig. 4** Crohn's disease with extramural manifestations. **a** Dilated vasa recta (arrow) in terms of “comb sign”. **b** In T2w with fat saturation, mesenteric, perienteric edema with contrast enhancement after gadolinium administration (T1 post-Gd). **c** Pronounced fibrofatty proliferation on the mesenteric side (stars) with distancing of the small bowel loops in terms of a “creeping fat sign”.

additional physiological and technical influencing factors. Mural enhancement on MRE is fundamentally also associated with disease activity. However, if no quantitative parameters (perfusion parameters like k_{trans} etc.) are used, a gradual evaluation of disease activity does not make sense [81]. The detection of mural enhancement on MRE is not specific for IBD in the absence of wall thickening. However, if wall thickening (particularly asymmetrical) is present, the sensitivity and specificity for the detection of IBD increase [27–29, 40].

Bowel wall pattern: In bowel wall segments with thickening, there are three basic contrast enhancement patterns. However, these are not specific for Crohn's disease. More or less homogeneous transmural enhancement indicates mild inflammatory activity depending on the wall thickness and given a lack of edema [72]. Stratification of the intestinal wall (► Fig. 3a) occurs in fat-saturated contrast-enhanced T1 sequences in two or three layers. In the case of two layers, there is pronounced concentric hyperenhancement on the lumen side or on the inner wall while hyperenhancement of the outer wall is additionally seen in the case of three layers. The term “mucosal hyperenhancement” of the inner wall should be avoided in the case of a mucosa that is mostly destroyed on endoscopy. The submucosa appears in both cases with intermediate to hypoechoic signal behavior after Gd administration (► Fig. 3a). It is currently not clinically relevant to differentiate between the two stratification phenomena. The signal behavior of the submucosa varies in the two stratification phenomena depending on the quality of the infiltrate. Edema has high signal intensity in T2w with fat saturation and indicates high inflammatory activity. A fatty submucosa has low signal intensity in T2w with fat saturation (or has high signal intensity in the DIXON technique) and indicates chronification of the IBD regardless of other inflammatory activity (► Fig. 3c). A predominantly inflammatory infiltrate tends to have an intermediate signal behavior in T2w.

Extramural manifestations

RECOMMENDATION 6

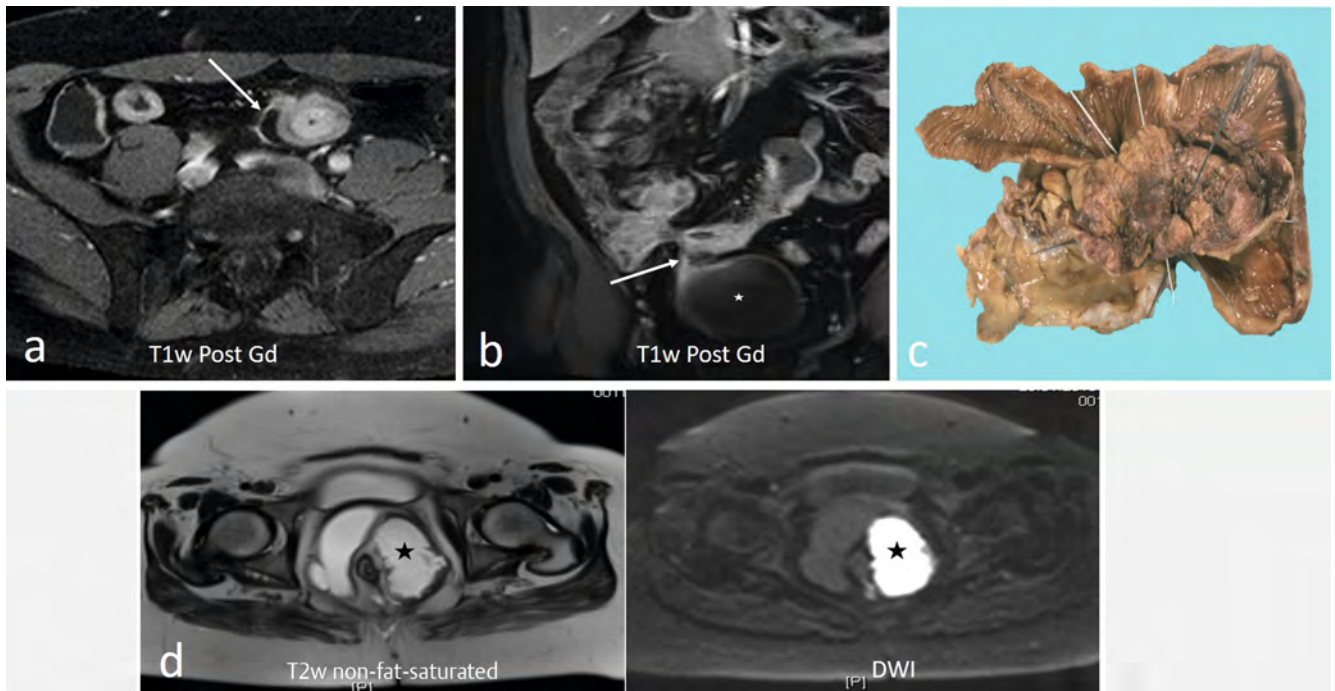
Manifestations of inflammation in the mesentery like edema, mesenteric fibrofatty proliferation (creeping fat), lymphadenopathy, and “comb sign” should be documented (agreement 93.5%).

Creeping fat: Perienteric inflammation usually presents as fibrofatty proliferation, partially also with edema or free mesenteric fluid [21] (► Fig. 4). The adipose tissue reaction described as “creeping fat” is associated with increased inflammatory activity and is usually seen on the mesenteric side of the bowel and is sometimes circumferential [21]. Mesenteric adipose tissue reactions are significantly more common in the small intestine than in the large intestine and are more common in Crohn's disease than in ulcerative colitis [21]. The quantitative representation of a mesenteric adipose tissue reaction is difficult so that it should only be described as “present” or “absent”.

Mesenteric edema: Perienteric mesenteric inflammatory reactions should be described in the report (► Fig. 4). This is usually seen perirectally with circumferential extension in the mesorectal fat tissue.

Comb sign: Inflammation with enlarged and engorged vasa recta (comb sign) are directly adjacent to the affected bowel loop (► Fig. 4). Since this sign can be seen both in acute inflammation and chronic mild inflammation, it should only be evaluated in conjunction with other activity markers [83].

Lymphadenopathy: There is currently no consensus regarding the number and size of regional lymph nodes associated with chronic bowel inflammation. Enlarged mesenteric lymph nodes with a short-axis diameter > 15 mm should be documented. A short-axis diameter of 10–15 mm can be viewed as normal in Crohn's disease.



► **Fig. 5** Crohn's disease with extramural manifestations. **a** Sinus tract at 11 o'clock (arrow). **b** Enterovesical fistula (arrow). **c** Complex fistula system with inflammatory tumor in the specimen. **d** Retained pararectal fluids, left side (star) with diffusion restriction in terms of an abscess.

Motility: The reduction of motility due to inflammation is a very subjective criterion that currently cannot be evaluated in a standardized manner and, at present, is not part of official activity indices [31, 84]. In “balanced steady state free precession” cine MRE sequences, a correlation with inflammatory activity could be shown [85, 86].

Extramural complications

RECOMMENDATION 7

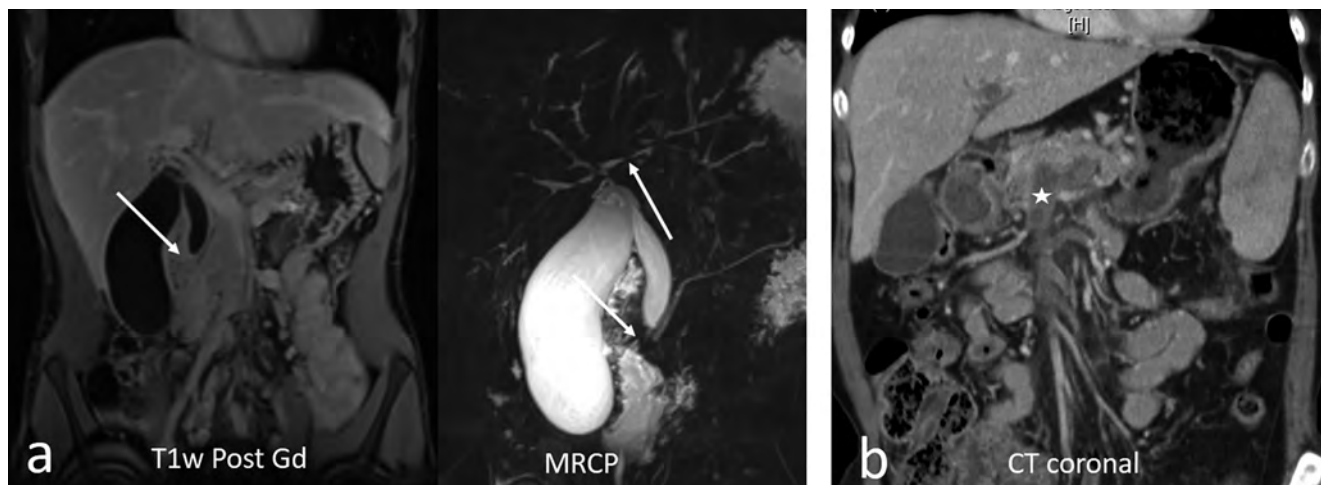
Penetrating complications like sinus tracts, fistulas, abscesses, and inflammatory masses should be detected and the location should be determined. Sinus tracts should be documented as blind-ending tubular structures and as early signs of a penetrating form of the disease. Fistulas should be categorized as simple and complex fistulas. The location of fistulas should be described by their origin and the structure to which they are connected. The extent and location of abscesses as well as the technical feasibility of ultrasound or CT-guided drainage should be described (agreement 93.5%).

Penetrating complications of Crohn's disease are the result of transmural inflammation and include fistulas, sinus tracts, abscesses, and inflammatory masses [87, 88]. In approximately one third of Crohn's patients, transmural inflammation with deep fissural ulcerations exceed the muscularis propria or serosa. Extramural extension of inflammation is the precursor to the formation of sinus tracts and fistulas.

Sinus tracts: Sinus tracts are blind-ending ducts, e.g. in the mesenteric adipose tissue (► Fig. 5) or in the abdominal wall, without a connection to other organ structures [88]. Sinus tracts often result in angulation or kinking or outpouching of the affected bowel loop at the origin of the sinus tract. Origin with clock position and length should be described.

Fistulas: In contrast to blind-ending sinus tracts, internal fistulas are connected to other epithelialized surfaces. A simple fistula is a simple extra-enteric connection to another bowel segment, the skin, or another hollow organ (► Fig. 5). A complex fistula is comprised of various extra-enteric ducts involving multiple structures [89, 90]. Complex fistulas result in multiple angulations and adhesions of the adjacent bowel loops with a star-shaped appearance [90]. In addition to the possible formation of abscesses between the bowel loops, inflammatory masses without a well-defined fluid component can form (see below). The type of fistula should be described including origin (clock position) and end (e.g. enterocutaneous, enteroenteric, enterovesical). Nonsterile fistulas connected to a sterile hollow organ (e.g. enterovesical, enterobiliary fistulas, etc.) are associated with an increased risk of septic complications and typically require surgical intervention [91]. Penetrating manifestations are typically seen in the middle or proximal portion of stenoses with transmural inflammatory activity [51, 58]. Therefore, stenoses should be carefully evaluated with respect to penetrating complications. Conversely, the origin of a fistula should be followed back to a segment with wall thickening and stenosis [92, 93]. In contrast, in the case of anastomoses, postoperative insufficiencies should be primarily considered.

Perianal fistulas: External perianal fistulas should not be subsumed under the term “penetrating complications” since there



► **Fig. 6** IBD with extraintestinal complications. **a** Stenosis on MRE in the distal common bile duct. In the subsequent MRCP confirmation of stenosis and multiple intrahepatic bile duct strictures (arrow) consistent with PSC. **b** Mesenteric vein thrombosis (star) in the vascular territory of the superior mesenteric vein.

are relevant differences with respect to their etiology and biology [94]. Approximately 25% of Crohn's patients have anal fistulas before or at the time of diagnosis. The anal canal including the sphincter complex should therefore be used for orientation in the MRE examination and the perianal status (fistula/abscesses present or absent) should be noted in the report. A detailed examination of the course of the fistula is not necessary or is not expedient with MRE. Therefore, in the case of suspicion of fistulas, inconclusive findings, and prior to therapy, dedicated multiparametric MRI of the anal canal should be additionally performed [95]. Classification should preferably be performed according to the AGA criteria (simple vs. complex fistulas) or according to the St. James classification [96].

Abscesses: Rim enhancement after Gd application is typical in MRE. DWI often shows diffusion restriction and also helps to differentiate smaller intramural abscesses or interloop abscesses from intestinal fluid with high T2 signal intensity [43] (► Fig. 5). The size, location, and feasibility of interventional drainage (ultrasound or CT-guided) should be documented [97–99].

Inflammatory mass: An inflammatory mass is seen on MRE as a mesenteric, ill-defined soft-tissue mass in the case of penetrating Crohn's manifestations (► Fig. 5). However, MRE shows soft-tissue segments and fatty inclusions but not any significant T2w equivalents [99]. The term mesenteric phlegmon should be avoided.

Extraintestinal involvement

RECOMMENDATION 8

In MRE, extraintestinal manifestations and complications should be described and documented (agreement 93.5%).

Sacroiliitis: In addition to possible erosion or fusion, bands of subchondral signal changes near the iliosacral joint or enhancement that is often asymmetrical and affects only one side is seen in the T2w sequence with FS, on DWI, and on post-Gd images.

PSC: Discontinuities of the intrahepatic bile ducts usually with intrahepatic and extrahepatic bile ducts with a normal width are typically seen. Advanced stages are characterized by wall thickening and segmental dilation of the bile ducts (► Fig. 6). In the case of suspicion of a PSC on MRE, MRCP should be additionally performed.

Avascular bone necrosis: Hip pain and/or steroid therapy can be seen in some cases as corresponding signal changes of the anterior femoral head circumference on MRE.

Pancreatitis: In addition to medication-induced and stone-induced pancreatitis, type II autoimmune pancreatitis must be considered. DWI MRE shows corresponding signal changes with a diffuse or focal character.

Mesenteric vein thrombosis: In particular, active chronic inflammatory bowel disease is associated with an increased risk of thromboembolic complications (► Fig. 6), including mesenteric and portalvenous thromboses [100]. Thromboembolic complications should be documented with MRE. Pronounced three-layer phenomena of the intestinal wall can indicate venous bowel congestion with hemorrhagic infarction and should not be misinterpreted on MRE as a manifestation of active inflammatory Crohn's disease.

Cholelithiasis and nephrolithiasis are sometimes seen as corresponding signal losses on the T2w MRE images.

Evaluation of findings

RECOMMENDATION 10

Findings should be evaluated based on the above image criteria and in the clinical context of the inflammation status (agreement 80.8%), stenosis status (agreement 93.3%), penetration status (agreement 96.7%), perianal status (agreement 83.3%), and the extraintestinal complication status (agreement 90.3%).

The phenotypical subclassifications according to the Paris and Montreal classifications do not take the intraindividual dynamics of the disease course of IBD into consideration. According to Cosnes and Lemann [101–103], strictures and extramural complications can develop over the course of the disease from intestinal segments with active inflammation. The reversibility of visible morphological surrogate parameters of inflammatory activity can be observed during treatment. On the basis of defined image and reporting criteria, systematic manifestations and the extent of an IBD should be determined based on inflammatory status, stenosis status, penetration status, perianal status, and extra-intestinal complication status (summary in ► **Table 2**).

Conclusion

The present study on MRE in IBD provides practice-oriented recommendations as to which criteria should be taken into consideration in reporting and the interpretation of findings. An improvement of the collection as well as documentation of MRE findings in IBD can help to further improve care for IBD patients. The standardization of image and evaluation criteria for MRE in IBD patients requires ongoing scientific evaluation. This manuscript does not claim to be a guideline but rather can be used as the foundation for the further development of interdisciplinary consensus in this area.

Conflict of Interest

The authors declare that they have no conflict of interest.

References

- [1] Ng SC, Shi HY, Hamidi N et al. Worldwide incidence and prevalence of inflammatory bowel disease in the 21st century: a systematic review of populationbased studies. *Lancet* 2018; 390: 2769–2778. doi:10.1016/S0140-6736(17)32448-0
- [2] Krankenhausstatistik – Diagnosedaten der Patienten und Patientinnen in Krankenhäusern ab 2000. Statistisches Bundesamt [Destatis] – Zentraler Auskunftsdiens (Eckdaten der vollstationären Patienten und Patientinnen). Gliederungsmerkmale: Jahre, Behandlungs-/Wohnort, ICD10. 2021. Available from: https://www.gbe-bund.de/gbe/pkg_isgbe5.prc_menu_olap?p_uid=gast&p_aid=83782102&p_sprache=D&p_help=0&p_indnr=550&p_indsp=&p_ityp=H&p_fid=
- [3] Sturm A, Atreya R, Bettebworth D et al. Aktualisierte S3-Leitlinie „Diagnostik und Therapie des Morbus Crohn“ der Deutschen Gesellschaft für Gastroenterologie, Verdauungs- und Stoffwechselkrankheiten (DGVS). *Z Gastroenterol* 2022; 60: 332–418
- [4] Dong J et al. Ultrasound as a diagnostic tool in detecting active Crohn's disease: a meta-analysis of prospective studies. *Eur Radiol* 2014; 24: 26–33
- [5] Panes J et al. Systematic review: the use of ultrasonography, computed tomography and magnetic resonance imaging for the diagnosis, assessment of activity and abdominal complications of Crohn's disease. *Aliment Pharmacol Ther* 2011; 34: 125–145
- [6] Kyunghwan Oh, Eun HyeOh, Soo MinNoh et al. Combined Endoscopic and Radiologic Healing Is Associated With a Better Prognosis Than Endoscopic Healing Only in Patients With Crohn's Disease Receiving Anti-TNF Therapy. *Clinical and Translational Gastroenterology* 2022; 13: e00442. doi:10.14309/ctg.0000000000000442
- [7] Rimola J, Alfaro I, Fernández-Clotet A et al. Persistent damage on magnetic resonance enterography in patients with Crohn's disease in endoscopic remission. *Aliment Pharmacol Ther* 2018; 48 (11): 1232–1241. doi:10.1111/apt.15013
- [8] Ordas I, Rimola J, Rodriguez S et al. Accuracy of magnetic resonance enterography in assessing response to therapy and mucosal healing in patients with Crohn's disease. *Gastroenterology* 2014; 146: 374–382. e371.21
- [9] Sauer CG, Middleton JP, McCracken C et al. Magnetic resonance enterography healing and magnetic resonance enterography remission predicts improved outcome in pediatric Crohn disease. *J Pediatr Gastroenterol Nutr* 2016; 62: 378–383
- [10] Deepak P, Fletcher JG, Fidler JL et al. Radiological response is associated with better long-term outcomes and is a potential treatment target in patients with small bowel Crohn's disease. *Am J Gastroenterol* 2016; 111: 997–1006
- [11] Grand DJ, Guglielmo FF, Al-Hawary MM. MR enterography in Crohn's disease: current consensus on optimal imaging technique and future advances from the SAR Crohn's disease-focused panel. *Abdom Imaging* 2015; 40: 953–964
- [12] Bruining DH, Zimmermann EM, Loftus EV Jr et al. Consensus Recommendations for Evaluation, Interpretation, and Utilization of Computed Tomography and Magnetic Resonance Enterography in Patients With Small Bowel Crohn's Disease. *Gastroenterology* 2018; 154: 1172–1194
- [13] Thipphavong S, Costa AF, Ali HA et al. Structured reporting of MRI for perianal fistula. *Abdominal Radiology* 2018; 44: 1295–1305
- [14] Halligan S, Tolan D, Amitai MM et al. ESGAR consensus statement on the imaging of fistula-in-ano and other causes of anal sepsis. *European radiology* 2020; 30: 4734–4740
- [15] Kucharzik T, Tielbeek J, Carter D et al. ECCO-ESGAR Topical Review on Optimizing Reporting for Cross-Sectional Imaging in IBD. *J Crohns Colitis* 2022; 16 (4): 523–543. doi:10.1093/ecco-jcc/jjab180
- [16] Kucharzik T, Atreyab R, Bachmann O et al. Positionspapier zur Befunderhebung von Darmultraschallbefunden bei chronisch entzündlichen Darmerkrankungen. *Z Gastroenterol* 2022; 60: 978–990
- [17] Rimola J, Rodriguez S, Garcia-Bosch O et al. Magnetic resonance for assessment of disease activity and severity in ileocolonic Crohn's disease. *Gut* 2009; 58: 1113–1120
- [18] Steward MJ, Punwani S, Proctor I et al. Non-perforating small bowel Crohn's disease assessed by MRI enterography: derivation and histopathological validation of an MRbased activity index. *Eur J Radiol* 2012; 81: 2080–2088
- [19] Hordonneau C, Buisson A, Scanzi J et al. Diffusion-weighted magnetic resonance imaging in ileocolonic Crohn's disease: validation of quantitative index of activity. *Am J Gastroenterol* 2014; 109: 89–98
- [20] Makanyanga JC, Pendse D, Dikaos N et al. Evaluation of Crohn's disease activity: initial validation of a magnetic resonance enterography global score (MEGS) against faecal calprotectin. *Eur Radiol* 2014; 24: 277–287
- [21] Ordás I, Rimola J, Alfaro I et al. Development and Validation of a Simplified Magnetic Resonance Index of Activity for Crohn's Disease. *Gastroenterology* 2019; 157: 432–439.e1
- [22] Deepak P, Fletcher JG, Fidler JL et al. Computed tomography and magnetic resonance enterography in Crohn's disease: assessment of radiologic criteria and endpoints for clinical practice and trials. *Inflamm Bowel Dis* 2016; 22: 2280–2288
- [23] Goodsall TM, Jairath V, Feagan BG et al. Standardisation of intestinal ultrasound scoring in clinical trials for luminal Crohn's disease. *Aliment Pharmacol Ther* 2021; 53: 873–886
- [24] Messadeg L, Hordonneau C, Bouguen G et al. Early Transmural Response Assessed Using Magnetic Resonance Imaging Could Predict Sustained Clinical Remission and Prevent Bowel Damage in Patients with Crohn's Disease Treated with Anti-Tumour Necrosis Factor Therapy. *Journal of Crohn's and Colitis* 2020; 14: 1524–1534

- [25] Bodily KD, Fletcher JG, Solem CA et al. Crohn Disease: mural attenuation and thickness at contrast-enhanced CT enterography—correlation with endoscopic and histologic findings of inflammation. *Radiology* 2006; 238: 505–516
- [26] Church PC, Turner D, Feldman BM et al. Systematic review with meta-analysis: magnetic resonance enterography signs for the detection of inflammation and intestinal damage in Crohn's disease. *Aliment Pharmacol Ther* 2015; 41: 153–166
- [27] Horsthuis K, Bipat S, Bennink RJ et al. Inflammatory bowel disease diagnosed with US, MR, scintigraphy, and CT: metaanalysis of prospective studies. *Radiology* 2008; 247: 64–79
- [28] Qiu Y, Mao R, Chen BL et al. Systematic review with meta-analysis: magnetic resonance enterography vs. computed tomography enterography for evaluating disease activity in small bowel Crohn's disease. *Aliment Pharmacol Ther* 2014; 40: 134–146
- [29] Siddiki H, Fletcher JG, Hara AK et al. Validation of a lower radiation computed tomography enterography imaging protocol to detect Crohn's disease in the small bowel. *Inflamm Bowel Dis* 2011; 17: 778–786
- [30] Nylund K, Hausken T, Ødegaard S et al. Gastrointestinal Wall Thickness Measured with Transabdominal Ultrasonography and Its Relationship to Demographic Factors in Healthy Subjects. *Ultraschall in der Medizin – European Journal of Ultrasound* 2012; 33: E225–E232
- [31] Goodsall TM, Nguyen TM, Parker CE et al. Systematic Review: Gastrointestinal Ultrasonography Scoring Indices for Inflammatory Bowel Disease. *J Crohns Colitis* 2021; 15: 125–142
- [32] Taylor SA, Mallett S, Bhatnagar G et al. Diagnostic accuracy of magnetic resonance enterography and small bowel ultrasound for the extent and activity of newly diagnosed and relapsed Crohn's disease (METRIC): a multicentre trial. *The Lancet Gastroenterology & Hepatology* 2018; 3: 548–558
- [33] Hallé E, Azahaf M, Duveau N et al. Radiological Response Is Associated with Better Outcomes and Should Be Considered a Therapeutic Target in Crohn's Disease. *Digestive Diseases and Sciences* 2019; 65: 2664–2674
- [34] Kucharzik T, Wittig BM, Helwig U et al. Use of Intestinal Ultrasound to Monitor Crohn's Disease Activity. *Clinical Gastroenterology and Hepatology* 2017; 15: 535–542
- [35] Maaser C, Petersen F, Helwig U et al. Intestinal ultrasound for monitoring therapeutic response in patients with ulcerative colitis: results from the TRUST&UC study. *Gut* 2020; 69: 1629–1636
- [36] Maconi G, Nylund K, Ripolles T et al. EFSUMB Recommendations and Clinical Guidelines for Intestinal Ultrasound (GIUS) in Inflammatory Bowel Diseases. *Ultraschall in der Medizin – European Journal of Ultrasound* 2018; 39: 304–317
- [37] Wilkens R, Hagemann-Madsen RH, Peters DA et al. Validity of Contrast-enhanced Ultrasonography and Dynamic Contrast-enhanced MR Enterography in the Assessment of Transmural Activity and Fibrosis in Crohn's Disease. *Journal of Crohn's and Colitis* 2017; 12: 48–56
- [38] Macari M, Balthazar EJ. CT of bowel wall thickening: significance and pitfalls of interpretation. *Am J Roentgenol* 2001; 176: 1105–1116
- [39] Plumb AA, Pendse DA, McCartney S et al. Lymphoid nodular hyperplasia of the terminal ileum can mimic active crohn disease on MR enterography. *Am J Roentgenol* 2014; 203: W400–W40
- [40] Baker ME, Walter J, Obuchowski NA et al. Mural attenuation in normal small bowel and active inflammatory Crohn's disease on CT enterography: location, absolute attenuation, relative attenuation, and the effect of wall thickness. *Am J Roentgenol* 2009; 192: 417–423
- [41] Louis E, Collard A, Oger AF et al. Behaviour of Crohn's disease according to the Vienna classification: changing pattern over the course of the disease. *Gut* 2001; 49: 777–782
- [42] Rieder F, Bettenworth D, Ma C et al. An expert consensus to standardise definitions, diagnosis and treatment targets for anti-fibrotic stricture therapies in Crohn's disease. *Aliment Pharmacol Ther* 2018; 48: 347–357
- [43] Guglielmo FF, Anupindi SA, Fletcher JG et al. Small Bowel Crohn Disease at CT and MR Enterography: Imaging Atlas and Glossary of Terms. *Radiographics* 2020; 40: 354–375
- [44] Bossuyt P, Debeuckelaere C, Ferrante M et al. Risk Stratification for Surgery in Stricturing Ileal Crohn's Disease: The BACARDI Risk Model. *J Crohns Colitis* 2018; 12: 32–38
- [45] Bouhnik Y, Carbonnel F, Laharie D et al. Efficacy of adalimumab in patients with Crohn's disease and symptomatic small bowel stricture: a multicentre, prospective, observational cohort (CREOLE) study. *Gut* 2018; 67: 53–60
- [46] Chaudhry NA, Rivero M, Grajo JR et al. A Fixed Stricture on Routine Cross-sectional Imaging Predicts Disease-Related Complications and Adverse Outcomes in Patients with Crohn's Disease. *Inflamm Bowel Dis* 2017; 23: 641–649
- [47] Schulberg JD, Wright EK, Holt BA et al. Magnetic resonance enterography for predicting the clinical course of Crohn's disease strictures. *J Gastroenterol Hepatol* 2020; 35: 980–987
- [48] Stocker D, King MJ, El Homsy M et al. Luminal narrowing alone allows an accurate diagnosis of Crohn's disease small bowel strictures at cross-sectional imaging. *J Crohns Colitis* 2021; 22 (6): 1009–1018. doi:10.1093/ecco-jcc/jjaa256
- [49] Panes J et al. Systematic review: the use of ultrasonography, computed tomography and magnetic resonance imaging for the diagnosis, assessment of activity and abdominal complications of Crohn's disease. *Aliment Pharmacol Ther* 2011; 34: 125–145
- [50] Bettenworth D, Gustavsson A, Atreja A et al. A Pooled Analysis of Efficacy, Safety, and Long-term Outcome of Endoscopic Balloon Dilation Therapy for Patients with Stricturing Crohn's Disease. *Inflamm Bowel Dis* 2017; 23 (1): 133–142. doi:10.1097/MIB.0000000000000988
- [51] Rieder F, Zimmermann EM, Remzi FH et al. Crohn's disease complicated by strictures: a systematic review. *Gut* 2013; 62: 1072–1084
- [52] Li C, Kuemmerle JF. Mechanisms that mediate the development of fibrosis in patients with Crohn's disease. *Inflamm Bowel Dis* 2014; 20: 1250–1258
- [53] Zidar N, Langner C, Jerala M et al. Pathology of fibrosis in Crohn's disease – contribution to understanding its pathogenesis. *Front Med (Lausanne)* 2020; 7: 167. doi:10.3389/fmed.2020.00167.eCollection 2020
- [54] Rimola J, Capozzi N. Differentiation of fibrotic and inflammatory component of Crohn's disease-associated strictures. *Intest Res* 2020; 18: 144–150
- [55] Baumgart DC, Muller HP, Grittner U et al. US-based Real-time Elastography for the Detection of Fibrotic Gut Tissue in Patients with Stricturing Crohn Disease. *Radiology* 2015; 275: 889–899
- [56] Allocca M, Fiorino G, Bonifacio C et al. Noninvasive Multimodal Methods to Differentiate Inflamed vs Fibrotic Strictures in Patients With Crohn's Disease. *Clin Gastroenterol Hepatol* 2019; 17: 2397–2415
- [57] Allocca M, Fiorino G, Bonifacio C et al. Noninvasive Multimodal Methods to Differentiate Inflamed vs Fibrotic Strictures in Patients With Crohn's Disease. *Clin Gastroenterol Hepatol* 2019; 17: 2397–2415
- [58] Orscheln ES, Dillman JR, Towbin AJ et al. Penetrating Crohn disease: does it occur in the absence of stricturing disease? *Abdom Radiol (NY)* 2018; 43: 1583–1589
- [59] Bouhnik Y, Carbonnel F, Laharie D et al. Efficacy of adalimumab in patients with Crohn's disease and symptomatic small bowel stricture: a multicentre, prospective, observational cohort (CREOLE) study. *Gut* 2018; 67: 53–60
- [60] Schulberg JD, Wright EK, Holt BA et al. Magnetic resonance enterography for predicting the clinical course of Crohn's disease strictures. *J Gastroenterol Hepatol* 2020; 35: 980–987
- [61] Weber NK, Fletcher JG, Fidler JL et al. Clinical characteristics and imaging features of small bowel adenocarcinomas in Crohn's disease. *Abdom Imaging* 2015; 40: 1060–1067

- [62] Radmard AR, Amouei M, Kooraki S et al. Potenzial MR Enterography Features to Differentiate Primary Small Intestinal Lymphoma from Crohn Disease. *American Journal of Roentgenology* 2020; 215: 864–873
- [63] Palascak-Juif V, Bouvier AM, Cosnes J et al. Small bowel adenocarcinoma in patients with Crohn's disease compared with small bowel adenocarcinoma de novo. *Inflamm Bowel Dis* 2005; 11: 828–832
- [64] Schreyer AG, Menzel C, Friedrich C et al. Comparison of high-resolution ultrasound and MR-enterography in patients with inflammatory bowel disease. *World J Gastroenterol* 2011; 17 (8): 1018–1025. doi:10.3748/wjg.v17.i8.1018
- [65] Rimola J, Ordas I, Rodriguez S et al. Magnetic resonance imaging for evaluation of Crohn's disease: validation of parameters of severity and quantitative index of activity. *Inflamm Bowel Dis* 2011; 17: 1759–1768
- [66] Tielbeek JA, Makanyanga JC, Bipat S et al. Grading Crohn disease activity with MRI: interobserver variability of MRI features, MRI scoring of severity, and correlation with Crohn disease endoscopic index of severity. *Am J Roentgenol* 2013; 201: 1220–1228
- [67] Park SH. DWI at MR enterography for evaluating bowel inflammation in Crohn disease. *Am J Roentgenol* 2016: 1–9
- [68] Hordonneau C, Buisson A, Scanzj J et al. Diffusion-weighted magnetic resonance imaging in ileocolonic Crohn's disease: validation of quantitative index of activity. *Am J Gastroenterol* 2014; 109: 89–98
- [69] Buisson A, Joubert A, Montoriel PF et al. Diffusion-weighted magnetic resonance imaging for detecting and assessing ileal inflammation in Crohn's disease. [Erratum appears in *Aliment Pharmacol Ther* 2013; 37: 1031 Note: Ines, D D [corrected to Da Ines, D]]. *Aliment Pharmacol Ther* 2013; 37: 537–545
- [70] Seo N, Park SH, Kim KJ et al. MR enterography for the evaluation of small-bowel inflammation in Crohn disease by using diffusion-weighted imaging without intravenous contrast material: a prospective noninferiority study. *Radiology* 2016; 278: 762–772
- [71] Kim K-J, Lee Y, Park SH et al. Diffusion-weighted MR Enterography for Evaluating Crohn's Disease. *Inflammatory Bowel Diseases* 2015; 21: 101–109
- [72] Punwani S, Rodriguez-Justo M, Bainbridge A et al. Mural inflammation in Crohn disease: location-matched histologic validation of MR imaging features. *Radiology* 2009; 252: 712–720
- [73] Maccioni F, Staltari I, Pino AR et al. Value of T2-weighted magnetic resonance imaging in the assessment of wall inflammation and fibrosis in Crohn's disease. *Abdom Imaging* 2012; 37: 944–957
- [74] Choi SH, Kim KW, Lee JY et al. Diffusion-weighted magnetic resonance enterography for evaluating bowel inflammation in Crohn's disease: a systematic review and meta-analysis. *Inflamm Bowel Dis* 2016; 22: 669–679
- [75] Morani AC, Smith EA, Ganeshan D et al. Diffusion-weighted MRI in pediatric inflammatory bowel disease. *Am J Roentgenol* 2015; 204: 1269–127746
- [76] Bots S, Nylund K, Löwenberg M et al. Ultrasound for Assessing Disease Activity in IBD Patients: A Systematic Review of Activity Scores. *Journal of Crohn's and Colitis* 2018; 12: 920–929
- [77] Ripollés T, Martínez MJ, Paredes JM et al. Crohn Disease: Correlation of Findings at Contrast-enhanced US with Severity at Endoscopy. *Radiology* 2009; 253: 241–248
- [78] Esteban J, Maldonado L, Sanchiz V et al. Activity of Crohn's disease assessed by colour Doppler ultrasound analysis of the affected loops. *European Radiology* 2001; 11: 1423–1428
- [79] Ripollés T, Paredes JM, Martínez-Pérez MJ et al. Ultrasonographic Changes at 12 Weeks of Anti-TNF Drugs Predict 1-year Sonographic Response and Clinical Outcome in Crohn's Disease. *Inflammatory Bowel Diseases* 2016; 22: 2465–2473
- [80] Novak KL, Nylund K, Maaser C et al. Expert Consensus on Optimal Acquisition and Development of the International Bowel Ultrasound Segmental Activity Score [IBUS-SAS]: A Reliability and Inter-rater Variability Study on Intestinal Ultrasonography in Crohn's Disease. *J Crohns Colitis* 2021; 15: 609–616
- [81] Makanyanga J, Punwani S, Taylor SA. Assessment of wall inflammation and fibrosis in Crohn's disease: value of T1-weighted gadolinium-enhanced MR imaging. *Abdom Imaging* 2012; 37: 933–943
- [82] Church PC, Turner D, Feldman BM et al. Systematic review with meta-analysis: magnetic resonance enterography signs for the detection of inflammation and intestinal damage in Crohn's disease. *Aliment Pharmacol Ther* 2015; 41: 153–166
- [83] Meyers MA, McGuire PV. Spiral CT demonstration of hypervascularity in Crohn disease: „vascular jejunization of the ileum“ or the „comb sign“. *Abdom Imaging* 1995; 20: 327–332
- [84] Bots S, Nylund K, Löwenberg M et al. Ultrasound for Assessing Disease Activity in IBD Patients: A Systematic Review of Activity Scores. *Journal of Crohn's and Colitis* 2018; 12: 920–929
- [85] Menys A, Puylaert C, Tutein Nolthenius CE et al. Quantified Terminal Ileal Motility during MR Enterography as a Biomarker of Crohn Disease Activity: Prospective Multinstitution Study. *Radiology* 2018; 289: 428–435
- [86] Girometti R, Zuiani C, Toso F et al. MRI Scoring System Including Dynamic Motility Evaluation in Assessing the Activity of Crohn's Disease of the Terminal Ileum. *Academic Radiology* 2008; 15: 153–164
- [87] Magro F, Langner C, Driessen A et al. European consensus on the histopathology of inflammatory bowel disease. *J Crohns Colitis* 2013; 7: 827–851
- [88] Rees MA, Dillman JR, Anton CG et al. Inter-radiologist agreement using Society of Abdominal Radiology-American Gastroenterological Association (SAR-AGA) consensus nomenclature for reporting CT and MR enterography in children and young adults with small bowel Crohn disease. *Abdom Radiol (NY)* 2019; 44: 391–397
- [89] Herrmann KA, Michaely HJ, Zech CJ et al. Internal fistulas in Crohn disease: magnetic resonance enteroclysis. *Abdom Imaging* 2006; 31: 675–687
- [90] Braithwaite KA, Alazraki AL. Use of the star sign to diagnose internal fistulas in pediatric patients with penetrating Crohn disease by MR enterography. *Pediatr Radiol* 2014; 44: 926–931
- [91] Sampietro GM, Casiraghi S, Foschi D. Perforating Crohn's disease: conservative and surgical treatment. *Dig Dis* 2013; 31: 218–221
- [92] Oberhuber G, Stangl PC, Vogelsang H et al. Significant association of strictures and internal fistula formation in Crohn's disease. *Virchows Arch* 2000; 437: 293–297
- [93] Baker ME, Fletcher JG, Al-Hawary M et al. Interdisciplinary Updates in Crohn's Disease Reporting Nomenclature, and Cross-Sectional Disease Monitoring. *Radiol Clin North Am* 2018; 56: 691–707
- [94] Tozer PJ, Whelan K, Phillips RK et al. Etiology of perianal Crohn's disease: role of genetic, microbiological, and immunological factors. *Inflamm Bowel Dis* 2009; 15: 1591–1598
- [95] Gecke KB, Bemelman W, Kamm MA et al. A global consensus on the classification, diagnosis and multidisciplinary treatment of perianal fistulising Crohn's disease. *Gut* 2014; 63: 1381–1392
- [96] Feuerstein JD, Ho EY, Shmidt E et al. AGA Clinical Practice Guidelines on the Medical Management of Moderate to Severe Luminal and Perianal Fistulizing Crohn's Disease. *Gastroenterology* 2021; 160 (7): 2496–2508. doi:10.1053/j.gastro.2021.04.022
- [97] Patil SA, Cross RK. Medical versus surgical management of penetrating Crohn's disease: the current situation and future perspectives. *Expert Rev Gastroenterol Hepatol* 2017; 11: 843–848
- [98] Dietrich CF, Lorentzen T, Appelbaum L et al. EFSUMB Guidelines on Interventional Ultrasound (INVUS), Part III – Abdominal Treatment Procedures (Short Version). *Ultraschall in Med* 2016; 37: 27–45
- [99] Ripollés T, Martínez-Pérez MJ, Paredes JM et al. Contrast-enhanced ultrasound in the differentiation between phlegmon and abscess in Crohn's disease and other abdominal conditions. *Eur J Radiol* 2013; 82: e525–e531

- [100] Violi NV, Schoepfer AM, Fournier N et al. Prevalence and clinical importance of mesenteric venous thrombosis in the Swiss Inflammatory Bowel Disease Cohort. *Am J Roentgenol* 2014; 203: 62–69
- [101] Levine A, Griffiths A, Markowitz J et al. Pediatric modification of the Montreal classification for inflammatory bowel disease: the Paris classification. *Inflamm Bowel Dis* 2011; 17: 1314–1321
- [102] Pariente B, Cosnes J, Danese S et al. Development of the Crohn's disease digestive damage score, the Lemann score. *Inflamm Bowel Dis* 2011; 17: 1415–1422
- [103] Cosnes J, Cattan S, Blain A et al. Long term evolution of disease behaviour of Crohn's disease. *Inflamm Bowel Dis* 2002; 8: 244–250