

Severe Complications after Corneal Collagen Cross-Linking (CXL)

Schwerwiegende Komplikationen nach kornealem Kollagen-Crosslinking (CXL)



Authors

Frank Blaser, Sandrine Zweifel, Maximilian Robert Justus Wiest, Anahita Bajka, Sadiq Said, Daniel Barthelmes, Daniel Rudolf Muth

Affiliation

Ophthalmology and Eye Clinic, University Hospital Zurich, University of Zurich, Zurich, Switzerland

Key words

corneal collagen cross-linking (CXL), keratoconus, complications, keratitis, epithelium on off

Schlüsselwörter

Hornhaut, korneales Kollagen-Crosslinking (CXL), Keratoconus, Komplikationen, Keratitis, Epithel-on-off-Kornea

received 5. 11. 2022

accepted 22. 1. 2023

Bibliography

Klin Monatsbl Augenheilkd 2023; 240: 369–378

DOI 10.1055/a-2040-4290

ISSN 0023-2165

© 2023. The Author(s).

This is an open access article published by Thieme under the terms of the Creative Commons Attribution-NonDerivative-NonCommercial-license, permitting copying and reproduction so long as the original work is given appropriate credit. Contents may not be used for commercial purposes, or adapted, remixed, transformed or built upon. (<https://creativecommons.org/licenses/by-nc-nd/4.0/>)

Georg Thieme Verlag KG, Rüdigerstraße 14, 70469 Stuttgart, Germany

Correspondence

Dr. Daniel Rudolf Muth, M.D.

Ophthalmology and Eye Clinic, University Hospital Zurich, University of Zurich

Frauenklinikstrasse 24, 8091 Zurich, Switzerland

Phone: + 41 (0) 442 55 49 13

dr-muth@t-online.de

ABSTRACT

Purpose To present a case series of rare and severe complications after corneal collagen cross-linking (CXL) of keratoconus patients.

Methods Single-center descriptive case series covering the period of 2012 to 2022 at the Department of Ophthalmology at the University Hospital, Zurich, Switzerland.

Results We present four eyes of four patients that showed severe unusual complications within the first month after CXL. Three patients had been treated with the classical epithelium-off “Dresden” protocol. One patient had been treated with the accelerated epithelium-off protocol. One patient presented with extensive corneal edema due to rubbing the eye after treatment. Two patients showed a bacterial infectious keratitis: one due to *Streptococcus pneumoniae* and the other due to *Staphylococcus hominis*, *Micrococcus luteus*, and *Streptococcus epidermidis*. The latter of the two patients exhibited extensive infectious crystalline keratopathy. The fourth patient showed a severe ulcerative lesion where no infectious cause could be found. Therefore, an autoimmune keratolytic process had to be suspected. Apart from the corneal edema, which resolved *ad integrum*, the other complications resulted in permanent corneal scarring and thinning. One patient needed an emergency amniotic transplant.

Conclusion Severe complications after CXL remain rare. Most common causes are complications that are not directly associated with the treatment as such. Those indirect complications occur after the treatment during the healing course of the epithelium. Associations with bandage contact lenses, topical steroids, atopic disease, and inappropriate patient behavior are often suspected. Correctly performed corneal scrapings with repeated microbiological analysis and a de-

Introduction

Corneal collagen cross-linking (CXL) in human studies was introduced in 2003 by Wollensak et al. [1,2]. The principle is based on the acceleration of cross-linking of corneal collagen fibers. CXL

mimics a premature ageing (oxidative deamination) of the cornea [3]. This results in a reduction of elasticity of the cornea and fixates the cornea in its current shape. Thus, the procedure can be used to halt the progression of corneal ectatic disorders such as keratoconus, pellucid marginal degeneration (PMD), or post-

tailed patient history are essential for establishing the correct diagnosis, especially in complicated cases that do not respond to a standard therapeutic regimen. This case series supports the efforts that are currently taken to improve the CXL technique in a way that postoperative complications are further reduced. A more efficient epithelium-on technique might be a step in that direction.

ZUSAMMENFASSUNG

Ziel Darstellung einer Fallserie von seltenen, schwerwiegenden Komplikationen nach kornealem Kollagen-Crosslinking (CXL) von Patienten mit Keratokonus.

Methoden Monozentrische, beschreibende Fallserie über einen Zeitraum von 2012 bis 2022 an der Augenklinik des Universitätsspitals Zürich, Schweiz.

Ergebnisse Wir zeigen 4 Augen von 4 Patienten, die mit ungewöhnlichen, schwerwiegenden Komplikationen innerhalb des 1. Monats nach CXL an unserer Klinik vorstellten. Drei der Patienten waren mit dem klassischen Epithelium-off-„Dresden“-Protokoll behandelt worden, ein Patient mit einem beschleunigten Epithelium-off-Protokoll. Ein Patient stellte sich mit einem ausgeprägten Hornhautstromaödem aufgrund von Reiben des Auges vor. Zwei Patienten zeigten eine infektiöse, bakterielle Keratitis mit *Streptococcus pneumoniae*

bzw. *Staphylococcus hominis*, *Micrococcus luteus*, *Streptococcus epidermidis*. Der 4. Patient zeigte eine schwere ulzerative Läsion ohne nachweisbare infektiöse Genese, weshalb ein autoimmuner, keratolytischer Prozess vermutet wurde. Außer dem Hornhautödem, das sich vollständig zurückbildete, resultierten die anderen Komplikationen in einer bleibenden Vernarbung und Ausdünnung der Hornhaut. Ein Patient benötigte eine notfallmäßige Amnionmembrantransplantation.

Schlussfolgerung Schwerwiegende Komplikationen nach CXL bleiben selten. Die häufigsten Ursachen hierfür sind Komplikationen, die nicht direkt mit der eigentlichen Prozedur zusammenhängen, sondern erst im postoperativen Heilungsverlauf des Hornhautepithels auftreten. Ein Zusammenhang mit therapeutischen Kontaktlinsen und unangemessenem Patientenverhalten wird in vielen Fällen angenommen. Korrekt durchgeführte Hornhaut-Scrapings mit wiederholter mikrobiologischer Aufarbeitung und eine detaillierte Patientenanamnese sind unerlässlich für eine korrekte Diagnosestellung, insbesondere in komplizierten Fällen, die nicht auf die üblichen Therapieregime ansprechen. Diese Fallserie unterstützt die aktuellen Bemühungen, die CXL-Technik dahingehend zu verbessern, sodass postoperative Komplikationen weiter reduziert werden. Eine effizientere Epithelium-on-Technik wäre ein Schritt in diese Richtung.

laser-assisted *in situ* keratomileusis (LASIK) ectasia [4]. Two techniques can be distinguished:

1. Epithelium-on (epi-on) where the corneal epithelium is left in place and the CXL is done transepithelially (TE CXL).
2. Epithelium-off (epi-off) where the corneal epithelium is removed mechanically with a scalpel or rotating brush, chemically using ethyl alcohol or via excimer laser [5–8].

The central 7–9 mm diameter of the epithelium is removed [9]. The peripheral epithelium is left in place to keep a protective distance to the limbal stem cells [3]. The CXL is then performed directly on the stroma. Post-CXL, a therapeutic contact lens is necessary to support and protect the corneal re-epithelialization process. Refractive contact lenses can be worn after 4 weeks (1 week after TE CXL) [9].

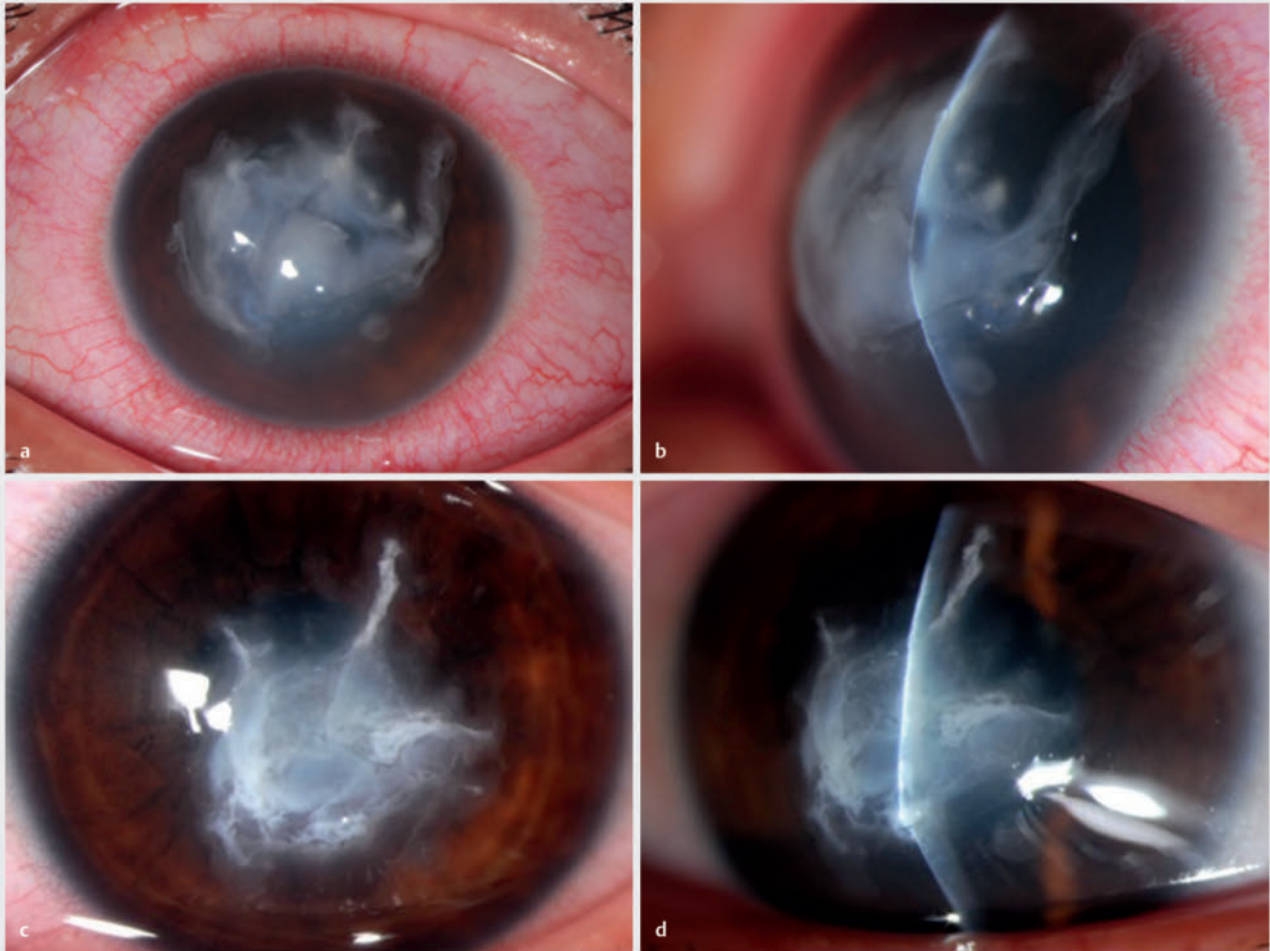
Currently, different CXL protocols vary in treatment duration and UV-A power density (irradiance) [5]. Most applied is the standard “Dresden” protocol, an epi-off procedure consisting of 30 minutes of riboflavin instillation at a fixed time interval (every 0.5 to 5 minutes) followed by a UV-A irradiance (power/surface area) of 3 mW/cm² for 30 minutes under continued riboflavin application [2, 6, 8]. This results in a total fluence (energy/surface area) of 5.4 J/cm² [9]. The accelerated epi-off protocol applies the same instillation time as the Dresden protocol but is followed by a different irradiance of 10 mW/cm² for 9 minutes [10]. Modifications of the standard protocols, such as pulsed UV-A irradiation or oxygen-enriched CXL to facilitate oxygen diffusion and increase stromal oxygen saturation, are under evaluation [11, 12].

CXL is generally considered a safe procedure with a low complication rate [9, 13]. It is more critical to raise awareness of severe

► **Table 1** Demographic analysis.

| | |
|--|---|
| Time period of chart review | 2012–2022 |
| Eyes (patients) included (n) | 4 (4) |
| Localization OD/OS | 1 (25%)/3 (75%) |
| Gender female/male | 0 (0%)/4 (100%) |
| Age mean [years] ± SD (min; max) | 20.3 ± 10.0 (11; 34) |
| CXL method | 4× epithelium-off |
| CXL protocol | 3× standard Dresden (75%) 1× accelerated (25%) |
| Postoperative period until complication [days] median [Q1; Q3]/mean ± SD (min; max) [95% CI] | 10.0 [2.5; 20.0]/12.5 ± 3.1 (1; 29) [– 8.3; 33.3] |
| Period until resolution of complication [days] median [Q1; Q3]/mean ± SD (min; max) [95% CI] | 45.5 [15.5; 85.3]/55.3 ± 52.9 (8; 122) [– 28.9; 139.4] |
| Type of complication | 2× infectious (50%) 1× autoimmune (25%) 1× patient behavior (25%) |

OD: right eye; OS: left eye; SD: standard deviation of arithmetic mean; min: minimum; max: maximum; CXL: corneal collagen cross-linking; Q1: first quartile, 25th percentile; Q3: third quartile, 75th percentile; 95% CI: 95% confidence interval



► **Fig. 1** Case 1. **a** Slit lamp photo left eye, en face view, taken on the next workday (3 days) after initial presentation. The anterior chamber reaction and hypopyon had already decreased under the initial therapy. **b** Slit lamp photo left eye, side view, taken on the next workday (3 days) after initial presentation. **c** Follow-up (2 weeks) slit lamp photo left eye, en face view. **d** Follow-up (2 weeks) slit lamp photo left eye, side view.

complications after CXL. Therefore, this series presents four cases with severe post-CXL complications, their therapy, and their respective outcomes.

Case Series

Results

The chart review covering the past 10 years (2012–2022) of all accessible patient files, identified 4 eyes of 4 patients with a severe complication associated with CXL. All of them were male and presented with an CXL-related severe complication no later than 1 month after the procedure (see ► **Table 1**).

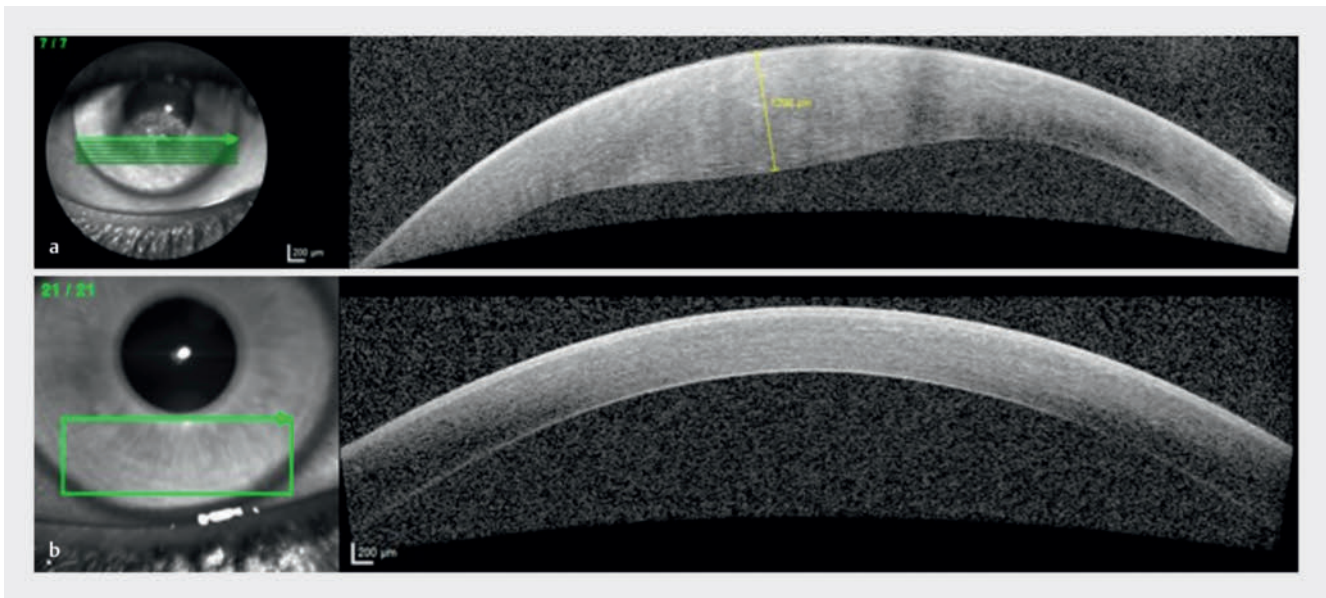
All patients had undergone an epi-off CXL to treat keratoconus, three using the standard Dresden protocol, and one with an accelerated protocol. Causes of the complication included infection, a corneal autoimmune reaction, and inappropriate patient behavior (see ► **Table 1**).

Case 1

The patient (15 years old, male) was referred 3 days after ex domo CXL on the left eye (oculus sinister, OS) to treat keratoconus using an accelerated epi-off protocol with an irradiance of 10 mW/cm² for 9 minutes. He complained of ocular pain and a reduced visual acuity (VA) of hand movements (HM) in the OS since the CXL procedure. He presented with marked conjunctival injection, a large stromal corneal infiltrate, and a small hypopyon at the base of the anterior chamber (AC) of the OS despite postoperative topical antibiotic treatment (see ► **Fig. 1 a** and **b**). Corneal swabs identified *Streptococcus pneumoniae*. Treatment was initiated with ceftazidime gtt. 5% hourly, ofloxacin gtt. 0.3% hourly, cyclopentolate 1% gtt. twice a day (BID), and oral doxycycline 100 mg BID. The situation stabilized over the course of 2 weeks, with resulting stromal scarring and a VA of counting fingers (CF; see ► **Fig. 1 c** and **d**).

Case 2

The patient (11 years old, male) presented 3 days after in domo CXL on the right eye (oculus dexter, OD) to treat keratoconus using the standard Dresden protocol. He complained of increasing ocular pain and a reduced VA of 0.05 decimal in the OD. He presented with a missing bandage contact lens, and a corneal de-



► **Fig. 2** Case 2. **a** Initial corneal OCT right eye showing stromal edema. Corneal thickness measured 1298 μm . **b** Follow-up (18 days) corneal OCT right eye.

compensation with a massive grotesque stromal edema with a centrally whitish cornea. The central pachymetry measured a massive stromal edema of 1298 micrometers (see ► **Fig. 2a**).

The clinical findings and the time course were not suspicious for an infectious cause. Preventative ofloxacin gtt. 4 \times /d and dexamethasone 0.1% gtt. 4 \times /d were started, and a new bandage lens was installed. Corneal swabs at baseline were not positive for any pathogen. At the following short-term checkup visits, the patient presented with a missing bandage contact lens and received a replacement each time. Repeated targeted patient history finally revealed that the patient had been intensively rubbing the treated eye at home. According to the parents, this assumably had led to repeated loss of the bandage contact lens. The mechanical stress and the lack of a therapeutic contact lens were a plausible explanation for the noninfectious corneal edema. The findings completely resolved under stopping of the eye rubbing, which was monitored by the parents, and strict therapeutic contact lens wear and continued topical antibiotic and steroid treatment over a course of 18 days (see ► **Fig. 2b**). The VA on that eye recovered to 0.6 decimal.

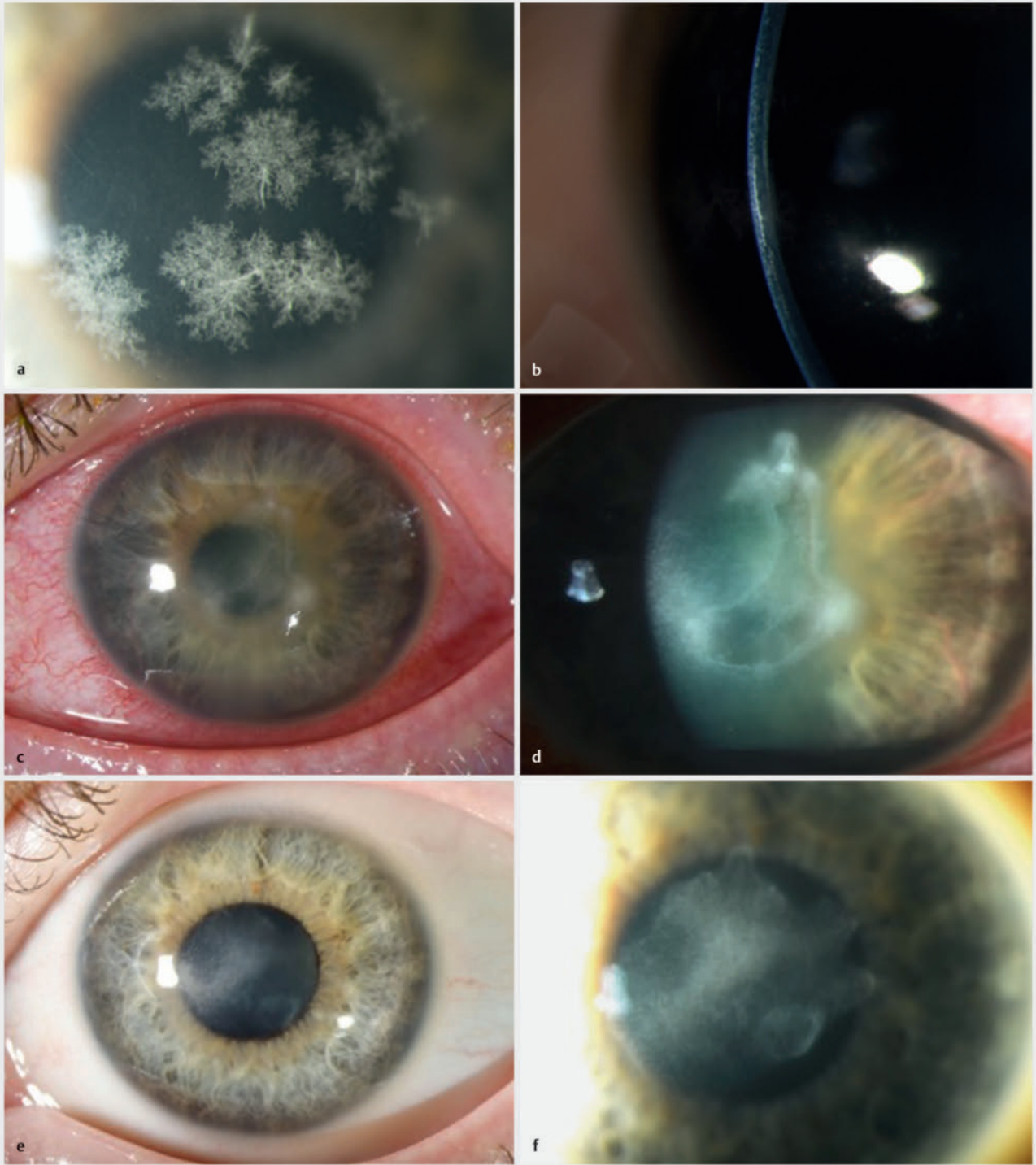
Case 3

The patient (35 years old, male) was referred 29 days after ex domo CXL on the OS to treat keratoconus using the standard Dresden protocol. He complained of a blurry reduced VA of 0.25 decimal in the OS. He presented with subepithelial and anterior stromal crystalline infiltrates despite topical postoperative antibiotic and steroid treatment (see ► **Fig. 3a** and **b**). The corneal epithelium was closed. Initially, no further signs of inflammation were present. However, a corneal swab with bacterial cultures and polymerase chain reaction (PCR) tests identified *Staphylococcus hominis*, *Micrococcus luteus*, and *Streptococcus epidermidis*. We established treatment using ceftazidime 5% gtt. hourly, ofloxacin

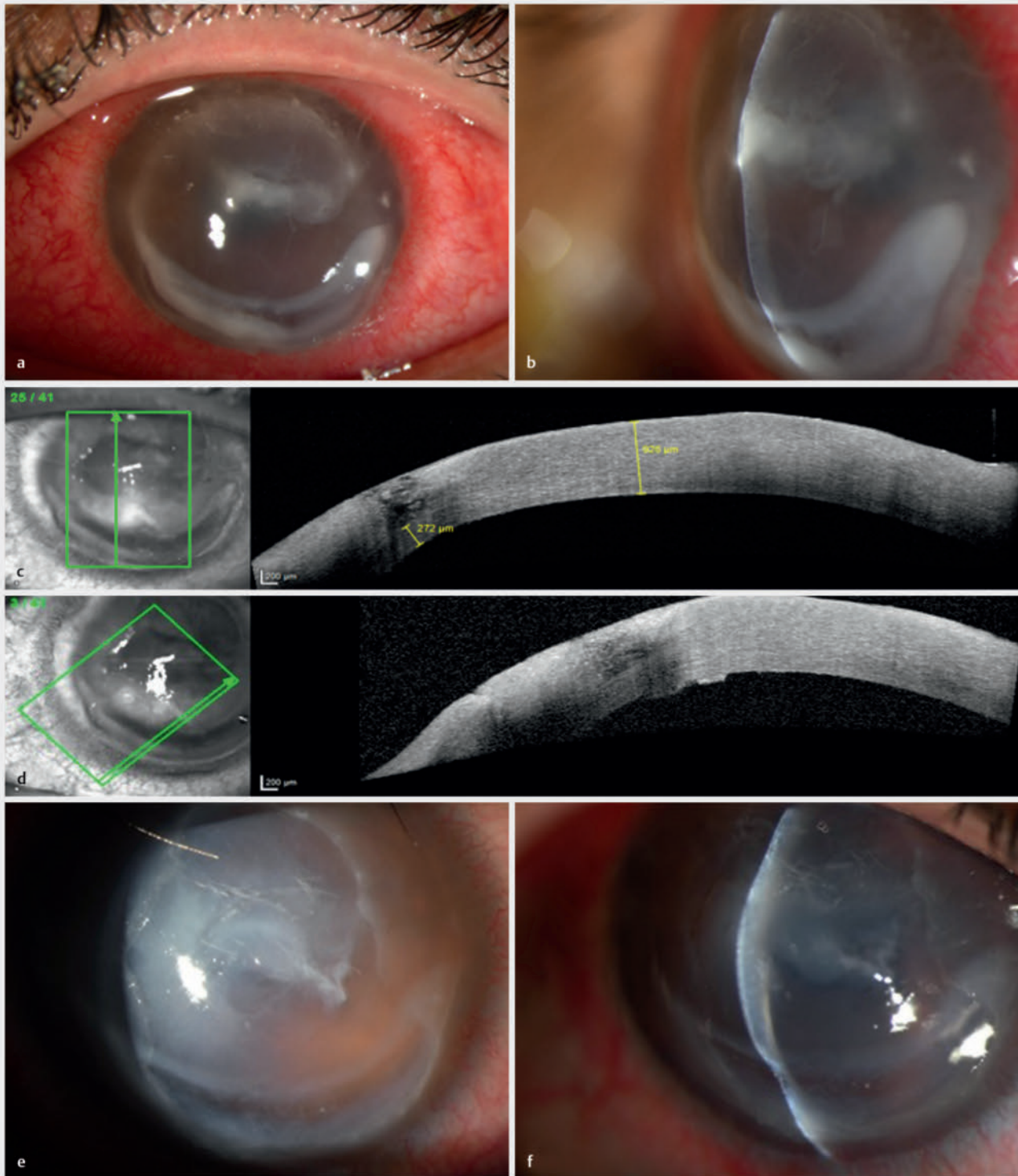
0.3% gtt. hourly, vancomycin 5% gtt. Hourly, and valaciclovir 500 mg oral three times per day (TID). The PCR test on herpes virus (HSV) species was negative. After initial stabilization, the findings aggravated 14 days after the first presentation. The patient now showed new stromal infiltrates, endothelial precipitates, and an AC reaction (see ► **Fig. 3c** and **d**). VA had dropped to 0.2 decimal. With a suspected mycotic superinfection, we initiated antimycotic treatment using natamycin 5% gtt. hourly and voriconazole oral 600 mg per day. Repeated corneal scrapings with a pan-fungal culture and PCR test, however, did not reveal a mycotic infection. The findings of this infectious crystalline keratitis slowly stabilized over the course of 3 months (see ► **Fig. 3e** and **f**). The initial postoperative treatment with topical steroids might have promoted the infection. Eventually, VA recovered to 0.4 decimal.

Case 4

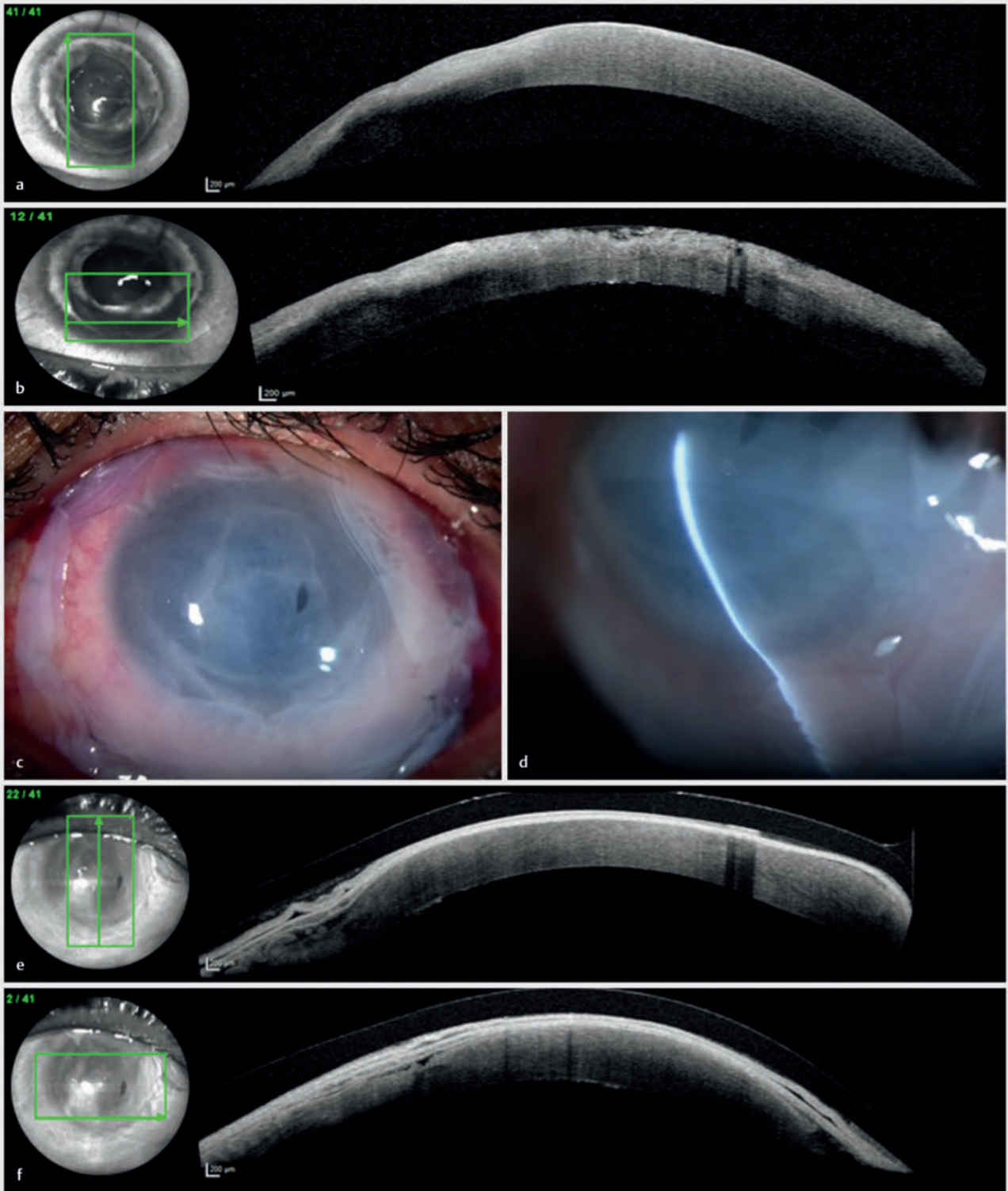
The patient (21 years old, male) was referred 12 days after ex domo CXL on the OS to treat keratoconus using the standard Dresden protocol. He complained of ocular pain and foreign body sensation and a decreased VA of HM in the OS. He presented with an ulcerative lesion with extensive affection of the conjunctiva and AC in the OS (see ► **Fig. 4a–d**). We suspected a contact lens-associated infectious keratitis. We started treatment using ceftazidime 5% gtt. hourly, ofloxacin 0.3% gtt. hourly, and tobramycin 0.3% gtt. hourly. Corneal swabs taken before the treatment regimen was initiated was not positive for any pathogen. The lesion progressed over the course of 2 weeks, with marked lysis of the surrounding corneal tissue and the formation of a descemetocoele (see ► **Fig. 4e** and **f** and ► **Fig. 5a** and **b**). We assumed an autoimmune keratolytic process and added dexamethasone 0.1% gtt eight times per day, and methylprednisolone intravenously 500 mg per day (together with an oral proton pump inhibitor, calcium, and vitamin D3) to the treatment regimen.



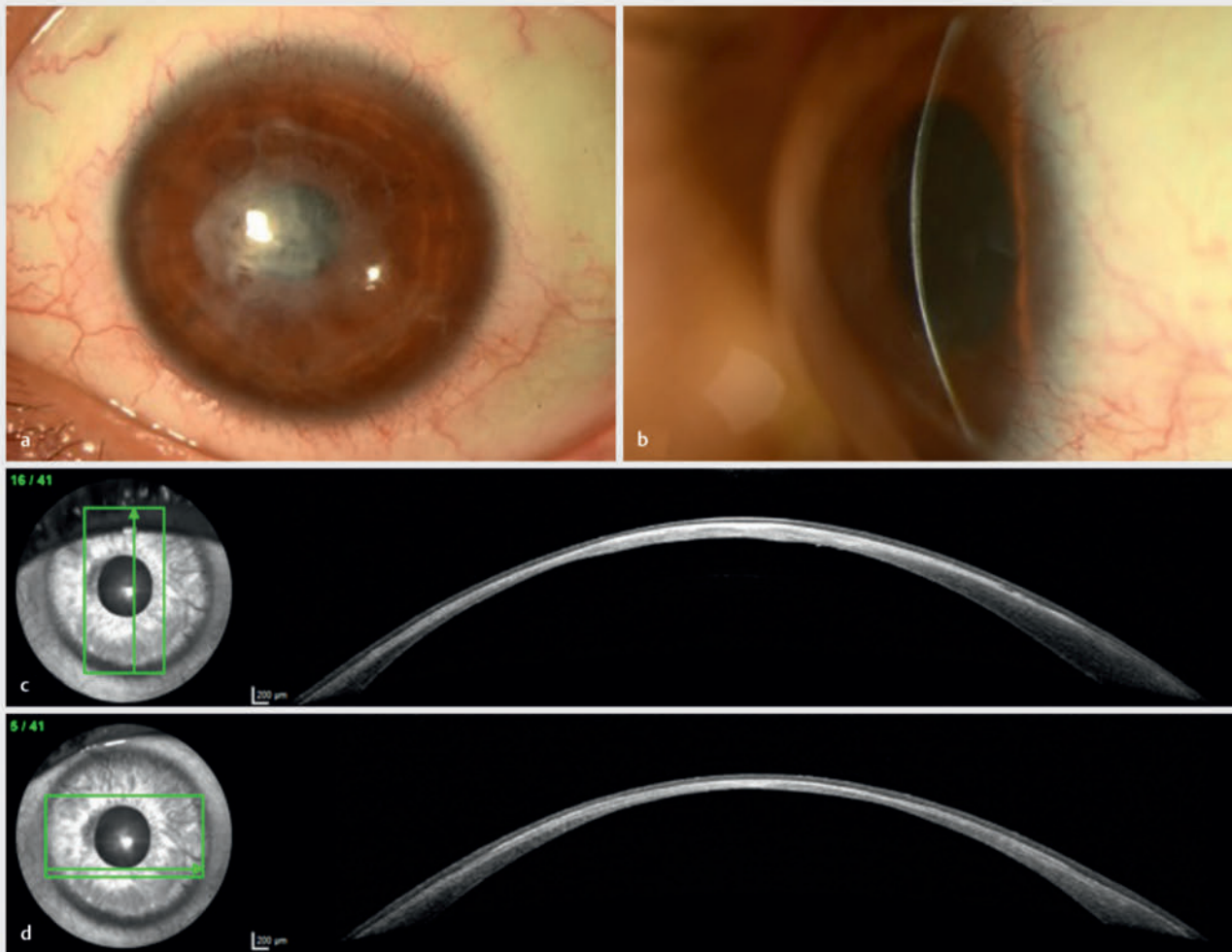
► **Fig. 3** Case 3. **a** Initial slit lamp photo, left eye, en face view. **b** Initial slit lamp photo, left eye, side view. **c** Follow-up (14 days) slit lamp photo, left eye, en face view. **d** Follow-up (14 days) slit lamp photo, left eye, close-up. **e** Follow-up (3 months) slit lamp photo, left eye, en face view. **f** Follow-up (3 months) slit lamp photo, left eye, close-up.



► **Fig. 4** Case 4. **a** Initial slit lamp photo, left eye, en face view. **b** Initial slit lamp photo, left eye, side view. **c** Initial corneal OCT, vertical, left eye showing central stromal edema (926 μm) and peripheral corneal thinning (272 μm). **d** Initial corneal OCT, horizontal, left eye. **e** Follow-up (2 weeks) slit lamp photo, left eye, en face view. **f** Follow-up (2 weeks) slit lamp photo, left eye, side view.



► **Fig. 5** Case 4. **a** Follow-up (2 weeks) corneal OCT, vertical, left eye. **b** Follow-up (2 weeks) corneal OCT, horizontal, left eye. **c** Follow-up (3 weeks) slit lamp photo, left eye, en face view. **d** Follow-up (3 weeks) slit lamp photo, left eye, side view. **e** Follow-up (3 weeks) corneal OCT, vertical, left eye with amniotic membrane cover. **f** Follow-up (3 weeks) corneal OCT, horizontal, left eye with amniotic membrane cover.



► **Fig. 6** Case 4. a Follow-up (2.5 years) slit lamp photo, left eye, en face view. b Follow-up (2.5 years) slit lamp photo, left eye, side view. c Follow-up (2.5 years) corneal OCT, vertical, left eye. d Follow-up (2.5 years) corneal OCT, horizontal, left eye.

To cover the descemetocoele, we decided to apply an amniotic patch (epithelial side down, facing patient's cornea and stromal side towards patient's lids) for further stabilization (see ► **Fig. 5 c–f**). Moreover, we induced an upper eye lid ptosis using botulinum toxin A to provide additional corneal protection.

Repeated swabs and corneal biopsies showed negative results regarding the most common bacteria, viruses, fungi, and acanthamoeba. Hence, we suspected an autoimmune keratolytic process. Continuing the above therapy with additional autologous serum eye drops (ASEDs), the stromal defect slowly stabilized over the course of 4 months. At the final follow-up visit, VA increased to 0.05 decimal and the patient presented with a stable but very thin cornea (see ► **Fig. 6 a–d**).

Discussion

In our series of severe post-CXL complications, we found an infectious keratitis in two cases, an autoimmune keratolysis in one case, and a markedly decompensated cornea due to postoperative misbehavior in the form of eye rubbing.

The literature reports infectious keratitis after CXL, with the most common cause being gram-positive bacteria, most notably *Staphylococcus aureus* [14]. Other gram-positive bacteria associated are *Staphylococcus epidermidis* and *Streptococcus viridans* subtypes such as *Streptococcus oralis*, *Streptococcus salivarius*, and *Streptococcus sanguinis*. Reported gram-negative pathogens include *Pseudomonas aeruginosa* and *Escherichia coli* [9, 15–17]. Infectious keratitis may also be caused by viruses, mainly from herpes virus species. It is hypothesized that UV-A irradiation causes a reactivation of latent herpes viruses [18, 19]. Further infectious causes are fungi, commonly *Fusarium* and *Microsporidia* species and by protozoa such as *Acanthamoeba* [9]. Amongst the patho-

gens, *Acanthamoeba* and *Pseudomonas* species, both ubiquitous germs, are reported to cause the most severe courses of keratitis after CXL, potentially aggravated by atopic disease [14, 15]. Non-infectious keratitis after epi-off CXL is known and reported to respond well to topical steroids [20–23]. Cases of sterile corneal melting are described without being able to clearly identify predictive risk factors [24–26]. CXL complications may occur directly during the procedure or indirectly during the subsequent healing phase. A higher incidence of infectious post-CXL complications was found when an epi-off protocol was used [27]. This seems conclusive as the epi-off technique is highly vulnerable to infections as long as the epithelium is not completely closed. Moreover, it has to be borne in mind that the epi-off treatment is done more often compared to epi-on procedures, as the standard epi-off Dresden protocol is the only FDA-approved technique [9]. Bandage contact lenses and topical steroids seem to support post-CXL infections [28]. It has been reported that patients with complications present well within 1 week after the intervention, which is congruent with the time needed for reepithelialization in epi-off procedures [14]. The mean time until presentation in our dataset was longer. This was due to one patient presenting after 29 days, which affected the mean and the median values as the group size was small.

In general, CXL is an effective and safe procedure with a very low rate for severe complications [13, 14]. The rare severe complications that occur usually happen after the CXL procedure, during the healing phase, which is prolonged with epi-off techniques. Inappropriate patient compliance can increase the complication profile. Considering the number of performed CXL procedures, complications due to noncompliant patients can also be considered very rare. For effective complication management, a good patient history and correctly performed and repeated corneal scrapings, if necessary, are essential. More effective and approved epi-on techniques could replace the epi-off procedure and further lower the CXL complication rate in the future.

CONCLUSION BOX

Already known:

- Corneal collagen cross-linking (CXL) is a safe procedure with low complication rates.

Newly described:

- Severe complications associated with CXL usually occur during the healing phase after the CXL procedure. CXL techniques with longer healing phases might be prone to a higher risk of severe complications.

Acknowledgement

The authors owe gratitude to the members of photography department as well as to all colleagues who contributed to taking high-quality clinical images at the Department of Ophthalmology at the University Hospital Zurich.

Conflict of Interest

The authors declare that they have no conflict of interest.

References

- [1] Wollensak G, Spoerl E, Seiler T. Riboflavin/ultraviolet-a-induced collagen crosslinking for the treatment of keratoconus. *Am J Ophthalmol* 2003; 135: 620–627. doi:10.1016/s0002-9394(02)02220-1
- [2] Belin MW, Lim L, Rajpal RK et al. Corneal Cross-Linking: Current USA Status: Report From the Cornea Society. *Cornea* 2018; 37: 1218–1225. doi:10.1097/ICO.0000000000001707
- [3] Feldmann BH, Bernfeld E, Reddy V et al. Corneal Collagen Cross-Linking. 2021. In: Shafer B, ed. https://eyewiki.aao.org/Corneal_Collagen_Cross-Linking. Accessed March 15, 2023 at: https://eyewiki.aao.org/Techniques_for_Corneal_Collagen_Crosslinking:_Epi-off_vs_Epi-on.
- [4] Sorokin N, Varssano D. Corneal collagen crosslinking: a systematic review. *Ophthalmologica* 2014; 232: 10–27. doi:10.1159/000357979
- [5] Randleman JB, Khandelwal SS, Hafezi F. Corneal cross-linking. *Surv Ophthalmol* 2015; 60: 509–523. doi:10.1016/j.survophthal.2015.04.002
- [6] Feldmann BH, Bunya VY, Santos M et al. Techniques for Corneal Collagen Crosslinking: Epi-off vs. Epi-on. Accessed March 15, 2022 at: https://eyewiki.aao.org/Techniques_for_Corneal_Collagen_Crosslinking:_Epi-off_vs_Epi-on.
- [7] Kapasi M, Baath J, Mintsoulis G et al. Phototherapeutic keratectomy versus mechanical epithelial removal followed by corneal collagen crosslinking for keratoconus. *Can J Ophthalmol* 2012; 47: 344–347. doi:10.1016/j.jcjo.2012.03.046
- [8] Kanellopoulos AJ. Long term results of a prospective randomized bilateral eye comparison trial of higher fluence, shorter duration ultraviolet A radiation, and riboflavin collagen cross linking for progressive keratoconus. *Clin Ophthalmol* 2012; 6: 97–101. doi:10.2147/OPTH.S27170
- [9] Evangelista CB, Hatch KM. Corneal Collagen Cross-Linking Complications. *Semin Ophthalmol* 2018; 33: 29–35. doi:10.1080/08820538.2017.1353809
- [10] Subasinghe SK, Ogbuehi KC, Dias GJ. Current perspectives on corneal collagen crosslinking (CXL). *Graefes Arch Clin Exp Ophthalmol* 2018; 256: 1363–1384. doi:10.1007/s00417-018-3966-0
- [11] Sachdev GS, Sachdev M. Recent advances in corneal collagen cross-linking. *Indian J Ophthalmol* 2017; 65: 787–796. doi:10.4103/ijo.IJO_648_17
- [12] Seiler TG, Komninou MA, Nambiar MH et al. Oxygen Kinetics During Corneal Cross-linking With and Without Supplementary Oxygen. *Am J Ophthalmol* 2021; 223: 368–376. doi:10.1016/j.ajo.2020.11.001
- [13] Meiri Z, Keren S, Rosenblatt A et al. Efficacy of Corneal Collagen Cross-Linking for the Treatment of Keratoconus: A Systematic Review and Meta-Analysis. *Cornea* 2016; 35: 417–428. doi:10.1097/ICO.0000000000000723
- [14] Murchison CE, Petroll WM, Robertson DM. Infectious keratitis after corneal crosslinking: systematic review. *J Cataract Refract Surg* 2021; 47: 1075–1080. doi:10.1097/j.jcrs.0000000000000620
- [15] Abbouda A, Abicca I, Alio JL. Infectious Keratitis Following Corneal Cross-Linking: A Systematic Review of Reported Cases: Management, Visual Outcome, and Treatment Proposed. *Semin Ophthalmol* 2016; 31: 485–491. doi:10.3109/08820538.2014.962176
- [16] Pollhammer M, Cursiefen C. Bacterial keratitis early after corneal crosslinking with riboflavin and ultraviolet-A. *J Cataract Refract Surg* 2009; 35: 588–589. doi:10.1016/j.jcrs.2008.09.029
- [17] Sharma N, Maharana P, Singh G et al. *Pseudomonas* keratitis after collagen crosslinking for keratoconus: case report and review of literature. *J Cataract Refract Surg* 2010; 36: 517–520. doi:10.1016/j.jcrs.2009.08.041

- [18] Kymionis GD, Portaliou DM, Bouzoukis DI et al. Herpetic keratitis with iritis after corneal crosslinking with riboflavin and ultraviolet A for keratoconus. *J Cataract Refract Surg* 2007; 33: 1982–1984. doi:10.1016/j.jcrs.2007.06.036
- [19] Yuksel N, Bilgihan K, Hondur AM. Herpetic keratitis after corneal collagen cross-linking with riboflavin and ultraviolet-A for progressive keratoconus. *Int Ophthalmol* 2011; 31: 513–515. doi:10.1007/s10792-011-9489-x
- [20] Koller T, Mrochen M, Seiler T. Complication and failure rates after corneal crosslinking. *J Cataract Refract Surg* 2009; 35: 1358–1362. doi:10.1016/j.jcrs.2009.03.035
- [21] Ghanem RC, Netto MV, Ghanem VC et al. Peripheral sterile corneal ring infiltrate after riboflavin-UVA collagen cross-linking in keratoconus. *Cornea* 2012; 31: 702–705. doi:10.1097/ICO.0b013e318226da53
- [22] Krok M, Wroblewska-Czajka E, Kokot J et al. Retrospective Analysis of Sterile Corneal Infiltrates in Patients with Keratoconus after Cross-Linking Procedure. *J Clin Med* 2022; 11: 585. doi:10.3390/jcm11030585
- [23] Arora R, Jain P, Gupta D et al. Sterile keratitis after corneal collagen cross-linking in a child. *Cont Lens Anterior Eye* 2012; 35: 233–235. doi:10.1016/j.clae.2012.06.002
- [24] Mohamed-Noriega K, Butron-Valdez K, Vazquez-Galvan J et al. Corneal Melting after Collagen Cross-Linking for Keratoconus in a Thin Cornea of a Diabetic Patient Treated with Topical Nepafenac: A Case Report with a Literature Review. *Case Rep Ophthalmol* 2016; 7: 119–124. doi:10.1159/000444437
- [25] Faschinger C, Kleinert R, Wedrich A. [Corneal melting in both eyes after simultaneous corneal cross-linking in a patient with keratoconus and Down syndrome]. *Ophthalmologe* 2010; 107: 951–952, 954–955. doi:10.1007/s00347-009-2127-6
- [26] Labiris G, Kaloghianni E, Koukoula S et al. Corneal melting after collagen cross-linking for keratoconus: a case report. *J Med Case Rep* 2011; 5: 152. doi:10.1186/1752-1947-5-152
- [27] Dhawan S, Rao K, Natrajan S. Complications of corneal collagen cross-linking. *J Ophthalmol* 2011; 2011: 869015. doi:10.1155/2011/869015
- [28] Tzamalīs A, Romano V, Cheeseman R et al. Bandage contact lens and topical steroids are risk factors for the development of microbial keratitis after epithelium-off CXL. *BMJ Open Ophthalmol* 2019; 4: e000231. doi:10.1136/bmjophth-2018-000231