

# Surgical Treatment of Another Sequelae of COVID-19: Post-COVID CTEPH

Nezih Onur Ermerak<sup>1</sup> Sehnaz Olgun Yildizeli<sup>2</sup> Derya Kocakaya<sup>2</sup> Bulent Mutlu<sup>3</sup> Koray Ak<sup>4</sup>  
Serpil Tas<sup>5</sup> Bedrettin Yildizeli<sup>1</sup>

<sup>1</sup> Department of Thoracic Surgery, Marmara University School of Medicine, Istanbul, Turkey

<sup>2</sup> Department of Pulmonology, Marmara University School of Medicine, Istanbul, Turkey

<sup>3</sup> Department of Cardiology, Marmara University School of Medicine, Istanbul, Turkey

<sup>4</sup> Department of Cardiovascular Surgery, Marmara University School of Medicine, Istanbul, Turkey

<sup>5</sup> Department of Cardiovascular Surgery, Kartal Kosuyolu Training and Research Hospital, Istanbul, Turkey,

Address for correspondence Nezih Onur Ermerak, MD, Department of Thoracic Surgery, Marmara University School of Medicine, Marmara Universitesi Pendik Egitim ve Arastrima Hastanesi Fevzi Cakmak Mah, Muhsin Yazicioglu Cad, no:10 7, Kat Gogus Cerrahisi, Klinigi, Istanbul 34668, Turkey (e-mail: onur.ermerak@marmara.edu.tr).

Thorac Cardiovasc Surg 2023;71:413–417.

## Abstract

**Background** Coronavirus disease 2019 (COVID-19) is still an ongoing entity and every day we face new sequelae of the disease. We hereby present surgical results of patients who are treated for post-COVID chronic thromboembolic pulmonary hypertension.

**Methods** Data were collected among patients who underwent pulmonary endarterectomy and had a diagnosis of post-COVID chronic thromboembolic pulmonary hypertension. All data were retrospectively reviewed from a prospectively conducted database. Operative mortality was described as death in hospital or within 30 days of surgery.

**Results** Eleven patients (seven males, four females; median age, 52 [22–63] years) were identified. Pulmonary vascular resistance improved significantly from 572 dyn/s/cm<sup>-5</sup> (240–1,192) to 240 (195–377) dyn/s/cm<sup>-5</sup> ( $p < 0.005$ ). Significant difference was also detected in median mPAP, as it decreased from 40 mm Hg (24–54) to 24 mm Hg (15–36) following surgery ( $p < 0.005$ ). Mortality was observed in one patient due to sepsis on the fifth postoperative day. Median time from COVID-19 disease to surgery was 12 months (6–24). Median length of hospital stay of the survivors was 10 days (8–14).

**Conclusion** In the new era of chronic thromboembolic pulmonary hypertension, hybrid approach including surgery, balloon pulmonary angioplasty, and medical treatment has been recommended. pulmonary endarterectomy is still the only curative treatment when the disease is surgically accessible. We hereby report the first publication of post-COVID chronic thromboembolic pulmonary hypertension patients who were surgically treated. As we see a lot of long-term symptoms and clinical manifestations in patients who had COVID-19, we should always remember chronic thromboembolic pulmonary hypertension in the differential diagnosis.

## Keywords

- ▶ COVID-19
- ▶ chronic thromboembolic pulmonary hypertension
- ▶ post-COVID
- ▶ long COVID
- ▶ pulmonary endarterectomy

received

January 3, 2023

accepted after revision

March 14, 2023

accepted manuscript online

March 21, 2023

article published online

May 3, 2023

© 2023. Thieme. All rights reserved.  
Georg Thieme Verlag KG,  
Rüdigerstraße 14,  
70469 Stuttgart, Germany

DOI <https://doi.org/10.1055/a-2059-4513>.  
ISSN 0171-6425.

## Introduction

The world has been dealing with coronavirus disease 2019 (COVID-19) and its complications since December 2019. Although it has been more than 2 years with the pandemic, numbers of patients have still been rising to date. More than 400 million cases and 6 million deaths have been reported all over the world so far.<sup>1</sup> Due to the accumulating data and the vaccinations, we, the physicians, have built a general opinion about the course of the disease. Unfortunately, long-term complications are still not totally clear and we face with new clinical entities every day.<sup>2–6</sup> There are different studies about various biomarkers discussing the pathophysiology behind this spectrum of diseases and symptoms.<sup>7,8</sup> Thrombosis and venous thrombosis associated with COVID-19 are one of the most feared and well-documented complications of the disease.<sup>9,10</sup> Thus, guidelines and recommendations have been published regarding the use of prophylaxis for thromboembolism.<sup>11,12</sup> Moreover, patients with pulmonary hypertension started emerging in the long-term follow-ups during the assessment of resisting pulmonary symptoms. Even though there are established treatment guidelines for pulmonary embolism (PE), 2 to 4% of the patients develop chronic thromboembolic pulmonary hypertension (CTEPH). Although specific programs exist all over the world, diagnosis of CTEPH is easily missed due to the lack of awareness among physicians. To date, it has been well accepted that pulmonary endarterectomy (PEA) is the only curative treatment of CTEPH.<sup>13–15</sup>

Here, we report our experience with 11 patients with post-COVID CTEPH who underwent PEA and review our data regarding clinical features, management, and outcomes.

## Methods

Between March 2011 and July 2022, 896 consecutive patients underwent PEA at our institution. A total of 11 patients (seven males, four females) were surgically treated with post-COVID CTEPH. Medical records of the 11 patients were retrospectively reviewed from a prospectively conducted database in terms of demographics, clinical features, peri- and postoperative complications, length of hospital stay, morbidity, mortality, and short- and long-term results. Operative mortality was described as death in hospital or within 30 days of surgery. The research board of our center approved the ethical application for this study.

Patients who had PE during or after COVID-19 infection were followed up by our PE team and the diagnosis of CTEPH was made by the presence of mismatched perfusion defects on ventilation perfusion (V/Q) scan in conjunction with evidence of pulmonary hypertension despite adequate anticoagulation for at least 3 months. Patients who had a past medical history of PE, any kind of coagulopathy, or major risk factors were excluded from the study. Pulmonary function tests including computed tomography pulmonary angiography (CTPA), 6-minute walk test (6MWT), and right heart catheterization were performed as a routine preoperative work-up for all patients. Our indications for PEA surgery can

be listed as: patients with mean pulmonary artery pressure (mPAP) of at least 20 mm Hg; pulmonary vascular resistance (PVR) of at least 300 dyn/s/cm<sup>-5</sup>; surgically accessible disease demonstrated on CTPA; and World Health Organization (WHO) functional class greater than II. Institutional standard protocols were followed for each patient in the management of perioperative anesthesia and postoperative care.<sup>16</sup>

They were followed up at every 3- to 6-month intervals by the multidisciplinary team. Patients were functionally evaluated according to WHO functional class and examined at each follow-up with CTPA, 6MWT, and echocardiogram.

## Statistical Analysis

Statistical analyses were performed using statistical software (SPSS, version 25.0 for Windows; SPSS, Chicago, Illinois, United States). Discrete random variables were presented as percentage and continuous random variables were presented as median and range (minimum–maximum values). A *p*-value < 0.05 was considered statistically significant.

## Results

Eleven patients (seven males, four females) with a median age of 52 (22–63) years were diagnosed with post-COVID CTEPH and underwent PEA. The demographic and preoperative characteristics of the patients are shown in ►Table 1. All patients described shortness of breath and fatigue as the chief complaint. Functional capacity of the patients was WHO class III or IV.

## Intraoperative Course and Complications

All PEAs were performed under deep hypothermia and intermittent circulatory arrest (20°C). The rewarming phase began after completion of PEA on both sides. Patients were kept intubated and transferred to the intensive care unit (ICU), where both postoperative hemodynamic parameters and mPAP were closely monitored from the first postoperative day until transfer from the ICU to the floor. The intraoperative and postoperative data are summarized in ►Table 2. All postoperative hemodynamic measurements were monitored and recorded for all the patients. Thirty-day mortality was observed in one patient (9.09%) due to sepsis on the fifth postoperative day. One patient needed two-vessel coronary artery bypass graft in addition to PEA. Images of the chronic thromboembolism and surgical specimen are shown in ►Fig. 1.

## Follow-up

Median PVR improved significantly from 572 dyn/s/cm<sup>-5</sup> (240–1,192) to 240 (195–377) dyn/s/cm<sup>-5</sup> (*p* < 0.005). Significant difference was also detected in median mPAP, as it decreased from 40 mm Hg (24–54) to 24 mm Hg (15–36) following surgery (*p* < 0.005). Images of the surgical materials can be seen in the ►Fig. 2. Median time from COVID-19 disease to surgery was 12 months (6–24). Median length of hospital stay of the survivors were 10 days (8–14). Median follow-up after PEA was 8 (2–14) months for all the survivors and they all improved to WHO functional class I and II.

**Table 1** Patient demographics and preoperative characteristics

Characteristics	Value or <i>n</i>
Age (y)	52 (22–63)
Sex ( <i>n</i> )	
Female	4 (36.4%)
Male	7 (63.6%)
Duration from COVID-19 to surgery (mo)	12 (6–24)
Symptoms ( <i>n</i> )	
Shortness of breath	11 (100%)
Fatigue	11 (100%)
Cough	5 (45.4%)
Headache	4 (36.4%)
Syncope	1 (91%)
WHO class ( <i>n</i> )	
I	0
II	0
III	8 (72.7%)
IV	3 (27.3%)
6MWT (m)	255 (0–462)
FEV1 (L)	2.24 (1.18–3.05)
FEV1 (%)	75 (70–84)
FEV1/FVC	86 (77–128)
sPAP (mm Hg)	66.5 (28–92)
mPAP (mm Hg)	40 (24–54)
Cardiac index (L/min/m <sup>2</sup> )	2.49 (1.4–3.26)
Cardiac output (L/min/m <sup>2</sup> )	4.3 (3.02–6.91)
PVR (dyn/s/cm <sup>-5</sup> )	572 (240–1,192)
Comorbidities ( <i>n</i> )	
CAD	1 (9.1%)

Abbreviations: 6MWT, 6-minute walk test; CAD, coronary artery disease; COVID-19, coronavirus disease 2019; FEV<sub>1</sub>, forced expiratory volume in 1 second; FVC, forced vital capacity; mPAP, mean pulmonary arterial pressure; PVR, pulmonary vascular resistance; sPAP, systolic pulmonary arterial pressure; WHO, World Health Organization. Note: The values are presented as number (%) or median (range).

## Discussion

After the first COVID-19 case in China in 2019, the whole world turned into a new era in many different capacities, and we still have been feeling its effect, especially in the medical field. Even though we have come far with the management of the disease, we are not out of the woods yet. We see different complications and presentations of the post-COVID patients and try to identify them to build diagnostic and therapeutic protocols.<sup>5,17</sup> Everyday, physicians encounter patients having various kinds of symptoms that they did not have before COVID-19, and the management of these patients can be challenging due to lack of data. There are different symptoms

**Table 2** Intraoperative and postoperative data

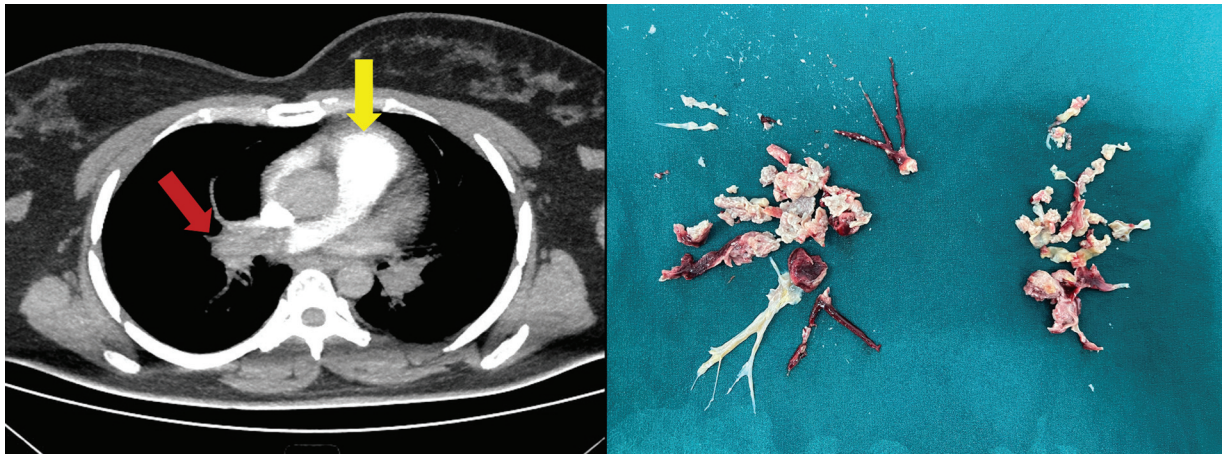
	Value
CPB (min)	180 (215–149)
Aortic cross-clamp (min)	29 (4–67)
TCA (min)	19 (4–44)
ECMO ( <i>n</i> )	0
MV time (d)	1 (1–2)
ICU (d)	2 (2–3)
LOS (d)	10 (8–14)
Postoperative mPAP (mm Hg)	24 (15–36)
Postoperative PVR (dyn/s/cm <sup>-5</sup> )	240 (195–377)
Postoperative WHO class I ( <i>n</i> )	10 (90.1%)

Abbreviations: CBP, cardiopulmonary bypass; ECMO, extracorporeal membrane oxygenation; ICU, intensive care unit; LOS, length of hospital stay; mPAP, mean pulmonary arterial pressure; MV, mechanical ventilation; PVR, pulmonary vascular resistance; TCA, total circulatory arrest; WHO, World Health Organization. Note: The values are presented as number (%) or median (range).

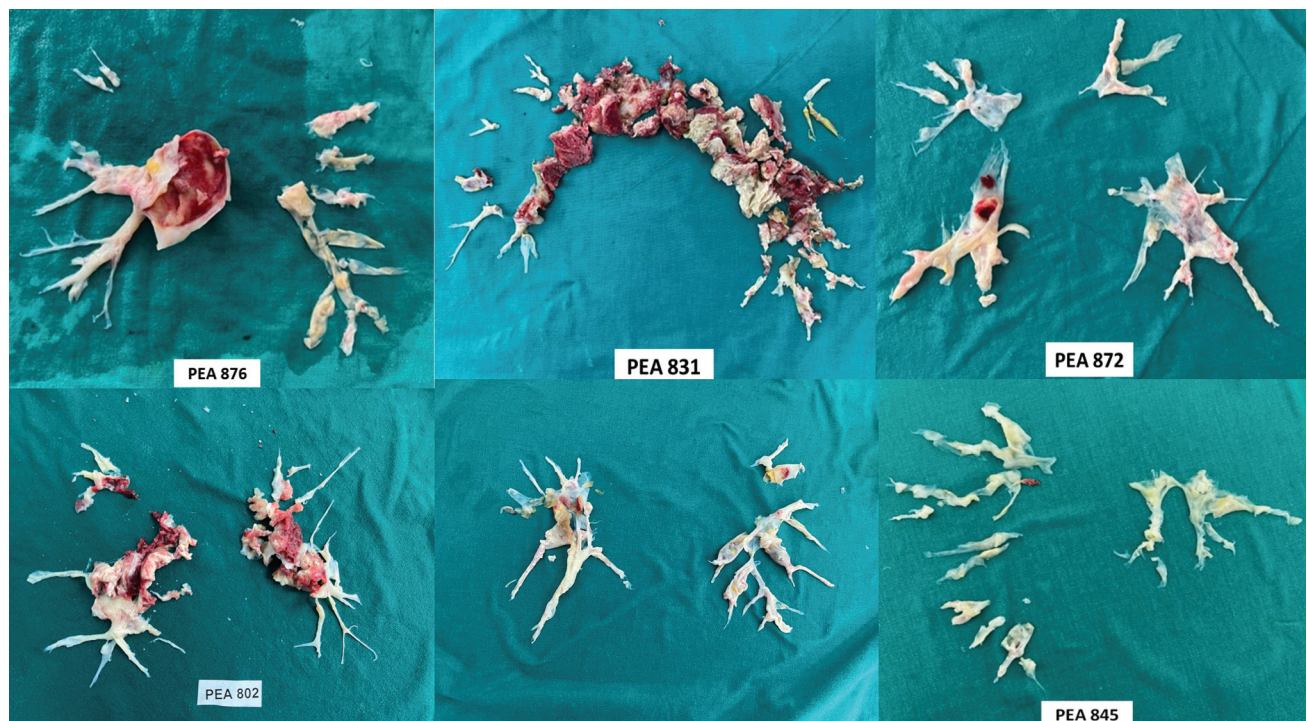
and diseases in various fields of the medicine, and they have been assessed under the topic of long-COVID or post-COVID syndrome.<sup>18,19</sup>

Venous thromboembolism (VTE) and PE were one of the first discovered complications of COVID-19 since the beginning of the pandemic.<sup>20</sup> PE is one of the major clinical problems and has clinical presentation mimicking many other diseases and the potential of unfavorable outcomes.<sup>21</sup> Even though there are well-established diagnostic and treatment algorithms, it is easily underdiagnosed, resulting in inadequate treatment. It is estimated that the annual mortality related to PE is around 300,000 in both United States and Europe.<sup>22,23</sup> Jimenez et al<sup>24</sup> reported the incidence of the VTE and PE in COVID-19 patients as 17 and 7.1%, respectively. Additionally, Poissy et al reported a 20.6% incidence of PE among COVID-19 patients.<sup>25</sup> Thus, studies started to emerge presenting recommendations and protocols for the prophylaxis of PE and VTE. Additionally, prophylactic low-dose heparin is one of the few medications that are widely accepted by the medical authorities in the battle with COVID-19. There are multiple theories explaining the pathophysiology of increased risk of PE with COVID-19 infection. Poor pointed to the effect of microvascular in situ immunothrombosis because of activated innate immune system.<sup>26</sup> On the other hand, Jayarangaiah et al blamed mainly the potentiating effect of immune system and coagulation pathways on each other for the occurrence of VTE and PE.<sup>27</sup>

As we know, even with the established protocols and medications, 2 to 4% of all PE patients develop CTEPH.<sup>28,29</sup> CTEPH can be defined as chronic stenosis and occlusion of the pulmonary arteries due to obstructive intraluminal organized thromboembolic materials. It is categorized as Group 4 pulmonary hypertension according to the 6th World Symposium on Pulmonary Hypertension classification and diagnosed with having mPAP  $\geq$  20 mm Hg with a pulmonary



**Fig. 1** Images of preoperative CTPA and postsurgical specimen. CTPA shows enlarged main pulmonary artery (yellow arrow) and chronic thromboembolism in the left main pulmonary artery (red arrow). CTPA, computed tomography pulmonary angiography; PE, pulmonary embolism.



**Fig. 2** Pulmonary endarterectomy specimens resected from some of the post-COVID CTEPH patients.

arterial wedge pressure of  $\leq 15$  mm Hg. These hemodynamic parameters must be supported by the radiological verification after 3 months of anticoagulation. PEA is still the only curative treatment when the disease is surgically accessible. Cueto-Robledo and colleagues recently published the first case series of post-COVID CTEPH patients. They followed up 77 COVID-19 patients with PE for 11 months and 3 (3.8%) of them developed CTEPH.<sup>30</sup> All patients received medical treatment and none of these patients underwent PEA. Their data showed a similar incidence of CTEPH with the regular population, but it is very early to conclude. We need to review our data worldwide to identify the real incidence of the disease. Moreover, we must be sure whether we can use the same protocols as with the regular PE for the manage-

ment of these patients. Although this is an important study in the post-COVID era, no data exist about the outcomes of surgical treatment. Our study presents the largest patient population of post-COVID CTEPH who underwent PEA.

A limitation of our study is the low volume of the patient population, but this can be explained by the lack of data due to the recent occurrence of the disease after COVID-19. Another limitation is the absence of the comparison of the results with the non-COVID CTEPH patients, but this study is designed to describe the characteristics and surgical outcomes of a new group of patients for the first time in the literature and to pave the way for the future studies with more patients. We expect to see more post-COVID CTEPH patients in the following years. Therefore, we plan to design a

future study comparing both groups with higher volume of patients for better understanding of this new entity.

CTEPH is a severe disease necessitating experienced teams for its management. Although there are multiple CTEPH and PH centers all over the world, only 16% of the patients find the chance to get diagnosed. Things are more complicated for the post-COVID CTEPH patients. We should design more studies for the better understanding of the disease. It is important to know whether we can treat these patients as we treat the other CTEPH patients or we should find totally different options. There are multiple medications for keeping pulmonary hypertension under certain levels to preserve right heart and quality of life, but we do not know if these medications will be helpful in the management. On the other hand, it is important to create awareness of the post-COVID CTEPH among physicians dealing with post-COVID and long-COVID patients. It is in the best interest of the patients to get referrals to experienced centers as early as possible for better outcomes. Post-COVID CTEPH is another new entity that COVID-19 brought into medical field and, given the circumstances, it looks like the number of patients will be increased day by day. As we see a lot of long-term symptoms and clinical manifestations in patients who had COVID-19, we should always remember CTEPH in the differential diagnosis.

#### Funding

None.

#### Conflict of Interest

None declared.

#### References

- Myoung J. Two years of COVID-19 pandemic: where are we now? *J Microbiol* 2022;60(03):235–237
- Martelletti P, Bentivegna E, Spuntarelli V, Luciani M. Long-COVID headache. *SN Compr Clin Med* 2021;3(08):1704–1706
- Baig AM. Chronic long-COVID syndrome: a protracted COVID-19 illness with neurological dysfunctions. *CNS Neurosci Ther* 2021;27(12):1433–1436
- Cortés-Telles A, López-Romero S, Figueroa-Hurtado E, et al. Pulmonary function and functional capacity in COVID-19 survivors with persistent dyspnoea. *Respir Physiol Neurobiol* 2021;288:103644
- Raman B, Bluemke DA, Lüscher TF, Neubauer S. Long COVID: post-acute sequelae of COVID-19 with a cardiovascular focus. *Eur Heart J* 2022;43(11):1157–1172
- Raj SR, Arnold AC, Barboi A, et al; American Autonomic Society. Long-COVID postural tachycardia syndrome: an American Autonomic Society statement. *Clin Auton Res* 2021;31(03):365–368
- Proal AD, VanElzakker MB. Long COVID or post-acute sequelae of COVID-19 (PASC): an overview of biological factors that may contribute to persistent symptoms. *Front Microbiol* 2021;12:698169
- Yong SJ. Long COVID or post-COVID-19 syndrome: putative pathophysiology, risk factors, and treatments. *Infect Dis (Lond)* 2021;53(10):737–754
- Al-Ani F, Chehade S, Lazo-Langner A. Thrombosis risk associated with COVID-19 infection. A scoping review. *Thromb Res* 2020;192:152–160
- Spiezia L, Boscolo A, Poletto F, et al. COVID-19-related severe hypercoagulability in patients admitted to intensive care unit for acute respiratory failure. *Thromb Haemost* 2020;120(06):998–1000
- Engelen MM, Vandenbrielle C, Balthazar T, et al. Venous thromboembolism in patients discharged after COVID-19 hospitalization. *Semi Thromb Hemost* 2021;47(04):362–371
- Moores LK, Tritschler T, Brosnahan S, et al. Thromboprophylaxis in patients with COVID-19: a brief update to the CHEST guideline and expert panel report. *Chest* 2022;162(01):213–225
- Galiè N, McLaughlin VV, Rubin LJ, Simonneau G. An overview of the 6th World Symposium on Pulmonary Hypertension. *Eur Respir J* 2019;53(01):1
- Guth S, D'Armini AM, Delcroix M, et al. Current strategies for managing chronic thromboembolic pulmonary hypertension: results of the worldwide prospective CTEPH Registry. *ERJ Open Res* 2021;7(03):3
- Lankeit M, Krieg V, Hobohm L, et al. Pulmonary endarterectomy in chronic thromboembolic pulmonary hypertension. *J Heart Lung Transplant* 2017;37(02):250–258
- Yıldızeli B, Taş S, Yanartaş M, et al. Pulmonary endarterectomy for chronic thrombo-embolic pulmonary hypertension: an institutional experience. *Eur J Cardiothorac Surg* 2013;44(03):e219–e227, discussion e227
- Adeloye D, Elneima O, Daines L, et al; International COVID-19 Airways Diseases Group. The long-term sequelae of COVID-19: an international consensus on research priorities for patients with pre-existing and new-onset airways disease. *Lancet Respir Med* 2021;9(12):1467–1478
- Yong SJ, Liu S. Proposed subtypes of post-COVID-19 syndrome (or long-COVID) and their respective potential therapies. *Rev Med Virol* 2022;32(04):e2315
- Garg M, Maralakunte M, Garg S, et al. The conundrum of 'long-COVID-19': a narrative review. *Int J Gen Med* 2021;14:2491–2506
- Miró Ò, Jiménez S, Mebazaa A, et al; Spanish Investigators on Emergency Situations TeAm (SIESTA) network. Pulmonary embolism in patients with COVID-19: incidence, risk factors, clinical characteristics, and outcome. *Eur Heart J* 2021;42(33):3127–3142
- Martinez Licha CR, McCurdy CM, Maldonado SM, Lee LS. Current management of acute pulmonary embolism. *Ann Thorac Cardiovasc Surg* 2020;26(02):65–71
- Heit JA, Cohen AT, Anderson JR FA. Estimated annual number of incident and recurrent, non-fatal and fatal venous thromboembolism (VTE) events in the US. *Blood* 2005;106(11):910
- Cohen AT, Agnelli G, Anderson FA, et al; VTE Impact Assessment Group in Europe (VITAE) Venous thromboembolism (VTE) in Europe. The number of VTE events and associated morbidity and mortality. *Thromb Haemost* 2007;98(04):756–764
- Jiménez D, García-Sánchez A, Rali P, et al. Incidence of VTE and Bleeding Among Hospitalized Patients With Coronavirus Disease 2019: A Systematic Review and Meta-analysis. *Chest* 2021;159(03):1182–1196
- Poissy J, Goutay J, Caplan M, et al; Lille ICU Haemostasis COVID-19 Group. Pulmonary embolism in patients with COVID-19: awareness of an increased prevalence. *Circulation* 2020;142(02):184–186
- Poor HD. Pulmonary thrombosis and thromboembolism in COVID-19. *Chest* 2021;160(04):1471–1480
- Jayarangaiah A, Kariyanna PT, Chen X, Jayarangaiah A, Kumar A. COVID-19-associated coagulopathy: an exacerbated immunothrombosis response. *Clin Appl Thromb Hemost* 2020;26:1076029620943293
- Kim NH, Delcroix M, Jenkins DP, et al. Chronic thromboembolic pulmonary hypertension. *J Am Coll Cardiol* 2013;62(25, Suppl):D92–D99
- Sharma S, Lang IM. Current understanding of the pathophysiology of chronic thromboembolic pulmonary hypertension. *Thromb Res* 2018;164:136–144
- Cueto-Robledo G, Roldan-Valadez E, Graniel-Palafox LE, et al. Chronic thromboembolic pulmonary hypertension (CTEPH): a review of another sequel of severe post-Covid-19 pneumonia. *Curr Probl Cardiol* 2023;48(08):101187