

Ultrasound Assisted Endoscopic Gastric Bypass (USA-EGB): a potential endoscopic alternative to surgical bypass, a pre-clinical proof of concept study ▶




Authors

Kambiz Kadkhodayan¹  Artur Viana¹, Sanmeet Singh¹, Natalie Cosgrove¹, Deepanshu Jain¹, Dennis Yang¹, Mustafa A Arain¹, Shayam Irani², Muhammad Khalid Hasan¹

Institutions

- 1 Center For Interventional Endoscopy , AdventHealth Orlando, Orlando, United States
- 2 Gastroenterology and Hepatology, Virginia Mason Medical Center, Seattle, United States

submitted 12.2.2023

accepted after revision 27.4.2023

accepted manuscript online 3.5.2023

Key words

Endoscopic ultrasonography, Intervention EUS, NOTES, Endoscopy Small Bowel, Small bowel endoscopy, Other focus (of reviewers), GI surgery

Bibliography

Endosc Int Open 2023; 11: E581–E587

DOI 10.1055/a-2085-3866

ISSN 2364-3722

© 2023. The Author(s).

This is an open access article published by Thieme under the terms of the Creative Commons Attribution-NonDerivative-NonCommercial License, permitting copying and reproduction so long as the original work is given appropriate credit. Contents may not be used for commercial purposes, or adapted, remixed, transformed or built upon. (<https://creativecommons.org/licenses/by-nc-nd/4.0/>)

Georg Thieme Verlag KG, Rüdigerstraße 14,
70469 Stuttgart, Germany

Corresponding author

Dr. Kambiz Kadkhodayan, AdventHealth Orlando, Center For Interventional Endoscopy , Orlando, United States
kamd@gmail.com

ABSTRACT

Background and study aims Endoscopic weight loss procedures have gained traction as minimally invasive options for the primary treatment of obesity. Thus far, we have developed endoscopic procedures that reliably address gastric restriction but result in significantly less weight loss than surgical gastrointestinal bypass. The goal of this nonsurvival study was to assess the technical feasibility of an endoscopic procedure, that incorporates both gastric restriction and potentially reversible gastrointestinal bypass.

Methods Ultrasound-assisted endoscopic gastric bypass (USA-EGB) was performed in three consecutive live swine, followed by euthanasia and necropsy. Procedure steps were: 1) balloon-assisted enteroscopy that determines the length of the bypassed limb; 2) endoscopic ultrasound-guided gastroenterostomy that creates a gastrointestinal anastomosis using a lumen apposing metal stent; 3) endoscopic pyloric exclusion that disrupts transpyloric continuity resulting in complete gastrointestinal bypass; and 4) gastric restriction that reduces gastric volume.

Results Complete gastrointestinal bypass and gastric restriction was achieved in all three swine. The mean total procedure time was 131 minutes (range 113–143), mean length of the bypassed limb was 92.5 cm and 180 cm, using short and long overtubes, respectively. There were no significant complications.

Conclusions We successfully described USA-EGB in three consecutive live swine. Further studies are needed to assess the procedures safety, efficacy, and clinical use.

Introduction

Global obesity rates have tripled since 1975 and it is estimated that by the year 2030, nearly half of the adult population in the United States will be either overweight or obese [1]. There is an urgent need to develop weight loss solutions that are clinically efficacious, cost efficient and scalable [2, 3].

Current treatment options for patients with obesity include diet-lifestyle modification, pharmacotherapy, surgery and in

recent years, endoscopic procedures. Diet-lifestyle modification is generally difficult to adhere to and has a high rate of recurrence [4]. Despite recent advances in pharmacotherapy, patient compliance, side effects and high cost are potential drawbacks [5]. Surgery, while highly efficacious, is unlikely to meet the growing global demand for obesity treatment [6, 7]. Unfortunately, fewer than 2% of eligible patients will choose to have surgery, and this is largely due to the fear of undergoing an operation [8, 9]. In recent years, novel endoscopic platforms have

facilitated transoral incisionless procedures that alter gastric anatomy and induce weight loss. When compared to surgery, endoscopic procedures are perceived to be less invasive, have shorter recovery periods, lower morbidity, are cost-effective and have gained traction as primary treatment options for obesity [10, 11].

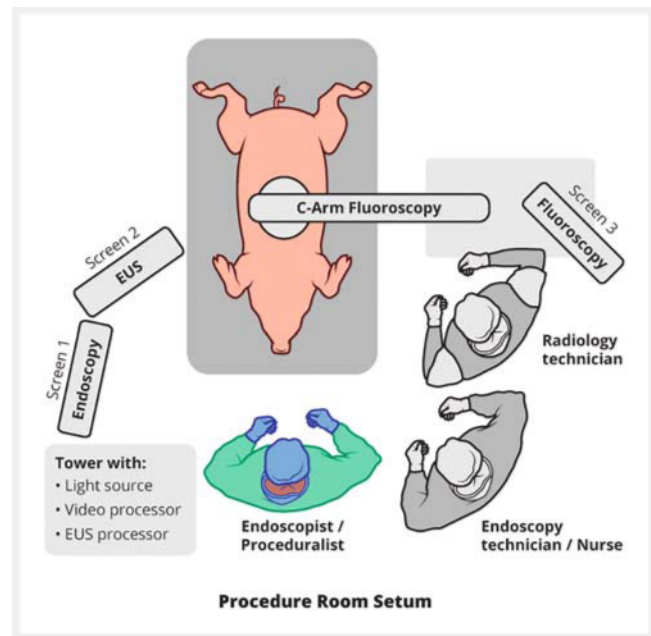
Endoscopic procedures that restrict gastric volume have been developed for clinical use in humans. Examples of such procedures are endoscopic balloon therapy and endoscopic sleeve gastroplasty. Procedures that simultaneously bypass proximal small bowel and restrict gastric volume are more effective at inducing weight loss and have superior metabolic effects than procedures that restrict gastric volume alone [12, 13]. Several promising animal studies have evaluated the utility of alternatives such as natural orifice transluminal endoscopic surgery and self-assembling magnets to create a gastroenteric or entero-enteric bypass. An endoscopic procedure that simultaneously bypasses the proximal small bowel and restricts gastric volume has not yet been developed for clinical use in humans [14, 15, 16].

The goal of this nonsurvival animal study was to assess the technical feasibility of an endoscopic ultrasound (EUS)-assisted bypass procedure, that incorporates both gastric restriction and small intestinal bypass.

Materials and methods

The study was conducted at a United States Department of Agriculture-licensed facility, under an active protocol that was approved by our Institutional Review Board. Animal Care and Use Committee (IACUC) guidelines were strictly adhered to. Three large Yorkshire pigs that weighed 170 to 175 lb were used (► **Table 1**). On the day of the procedure, the animals were sedated and placed on a ventilator. Vitals including noninvasive blood pressure (NIBP), pulse, peripheral oxygen saturation, end tidal carbon dioxide levels and respiratory rate were measured throughout. After completion of the procedure, all three animals were euthanized using weight-based doses of sodium pentobarbital and necropsy was performed.

Procedure success was defined as the ability to accomplish all required steps of the procedure in a live swine without significant hemodynamic change or respiratory distress. At the conclusion of the procedure, water-soluble contrast was injected at the esophagogastric junction and the following was ensured on fluoroscopy: 1) absence of transpyloric contrast passage; 2) reduction in gastric volume by at least 50%; 3) presence of a common conduit that connects the gastric inlet to both the pylorus and the lumen apposing metal stent (LAMS); and 4) complete diversion of contrast through the gastroenteric anastomosis with no fluoroscopic evidence of a leak. Procedure-related complications were defined as perforation, significant bleeding that required intervention or any gross deviation from the expected procedure outcome.

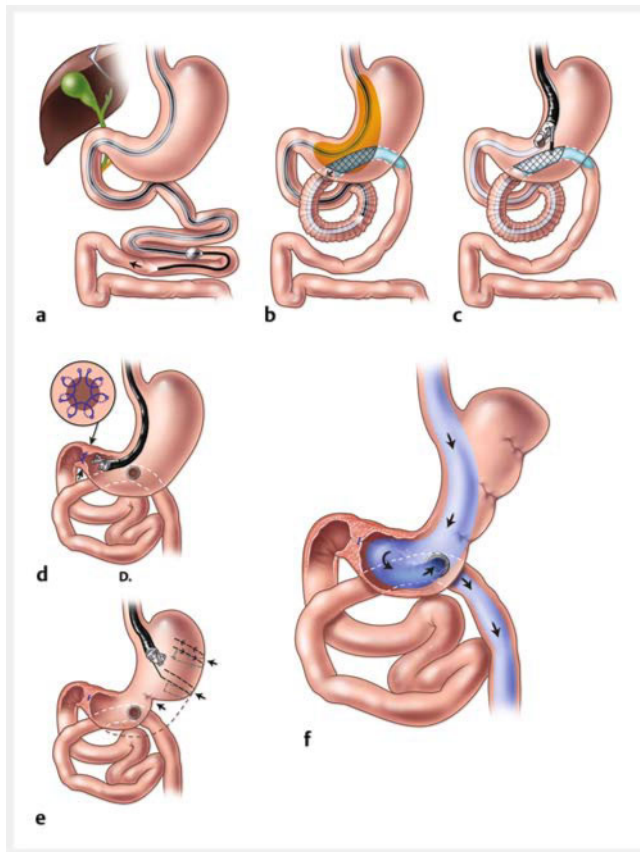


► **Fig. 1** Procedure room setup. The swine were kept supine on a horizontal surface and the c-arm was positioned in a neutral anterior-posterior (AP) direction throughout. Source: Image courtesy of Elena S. Kakoshina.

► **Table 1** Characteristics of live swine models.

| | Swine 1 | Swine 2 | Swine 3 |
|------------------------------|--|--|--|
| Sex | F | F | F |
| Weight (lb) | 170 | 175 | 170 |
| Pre-procedure preparation | Half-ration solid food for 48 hours, and only water 24 hours prior to the procedure* | Only water for 48 hours | Only water for 48 hours |
| Induction anesthesia | Acepromazine 0.4 mL Atropine 9.9 mL Buprenorphine 1.3 mL | Acepromazine 0.4 mL Atropine 9.9 mL Buprenorphine 1.3 mL | Acepromazine 0.4 mL Atropine 9.9 mL Buprenorphine 1.3 mL |
| Ventilator tidal volume (mL) | 630 | 650 | 630 |
| Necropsy performed | Yes | Yes | Yes |

* Despite pre-procedure fasting and copious pre-procedure gastric lavage, we encountered large amounts of solid debris in the stomach of Swine 1. The issue was resolved by a prolonged 48-hour liquid fast in the subsequent two animal models.



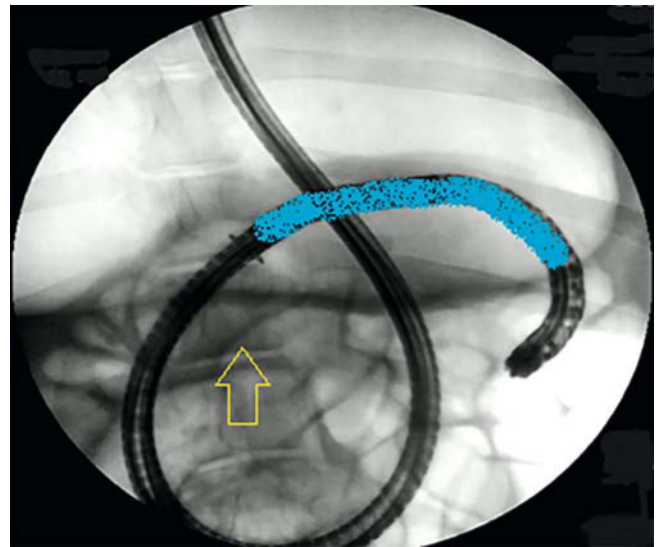
► **Fig. 2** Descriptive illustrations USA-EGB procedure. **a** A balloon-assisted enteroscope is advanced into the small bowel. **b** The enteroscope and overtube are manipulated until the loop of small bowel located immediately downstream from the overtube balloon, overlaps the gastric silhouette on fluoroscopy. The “target segment” (meshed lines) within this loop of small bowel that is ideally suited for LAMS placement, is the segment of bowel that also overlaps a hypothetical 3- to 5-cm tubular zone that starts at the gastric inlet, runs along the lesser curvature, and ends at the pylorus (orange). The small bowel is then infused with a solution of water, radio contrast and a blue dye. The enteroscope is then withdrawn, leaving the overtube with an inflated balloon in situ. **c** A curvilinear echoendoscope is inserted alongside the overtube and the LAMS is deployed within the “target segment” (meshed lines) of small bowel. **d** Closure of the pylorus using a single continuous polypropylene suture. **e** Reduction of gastric volume by application of transmural sutures. **f** Completed USA-EGB procedure depicting complete gastrointestinal bypass and gastric restriction. Source: Image courtesy of Elena S. Kakoshina.

Procedure description

The ultrasound-assisted endoscopic gastric bypass (USA-EGB) procedure was performed using the following steps, in three consecutive live swine, by a team of one physician with training in advanced endoscopy, one endoscopy technician, and one fluoroscopy technician (► **Fig. 1**).

Step 1: Balloon-assisted enteroscopy

This step determines the length of small bowel that is bypassed. Balloon-assisted enteroscopy (BAE) is utilized to explore the small bowel to a pre-determined depth from the pylorus. The



► **Fig. 3** X-ray image (neutral AP) of an optimal fluoroscopic position for EUS-GEA i. e., the overtube balloon (yellow arrow) is located at the outer margin of the gastric silhouette and the leading portion of the enteroscope (represents the loop of bowel that is located immediately downstream from the overtube balloon) overlaps the gastric silhouette (highlighted in blue).

enteroscope is also used to manipulate the small bowel and create a window for EUS-guided gastroenteric anastomosis (EUS-GEA).

A balloon-assisted enteroscope was advanced into the small bowel and, using standard technique, either 15 anterograde push-and-pull cycles were completed or 60 minutes elapsed (► **Fig. 2a**). Following this, the enteroscope and overtube were manipulated until the loop of bowel that is located immediately downstream from the overtube balloon, overlaps the gastric silhouette on fluoroscopy (► **Fig. 3**). Within this loop, the segment of bowel that simultaneously overlaps a hypothetical 3- to 5-cm tubular zone that starts at the gastric inlet, runs along the lesser curvature, and ends at the pylorus, is ideally suited for LAMS placement (► **Fig. 2b**). This segment of small bowel will be referred to as the “target segment” for simplicity. After this position was achieved, the small bowel was infused with a solution of water, radio contrast, and methylene blue. The enteroscope was then withdrawn leaving the overtube with an inflated balloon in situ.

Step 2: EUS-guided gastroenterostomy.

Using a commercially available LAMS, this step creates an EUS-guided anastomosis between the stomach and small bowel.

A curvilinear echoendoscope was advanced alongside the flexible overtube, and using fluoroscopy and EUS, the “target segment” of small bowel was identified. After obtaining an avascular window on Doppler, a 15 × 10 mm electrocautery-enhanced LAMS (Hot Axios stent, Boston Scientific, Marlborough, Massachusetts, United States) was deployed freehand using standard technique and a gastroenteric anastomosis was created (► **Fig. 2c**). The overtube balloon was then deflated and the echoendoscope and overtube were withdrawn.

Step 3: Endoscopic pyloric exclusion

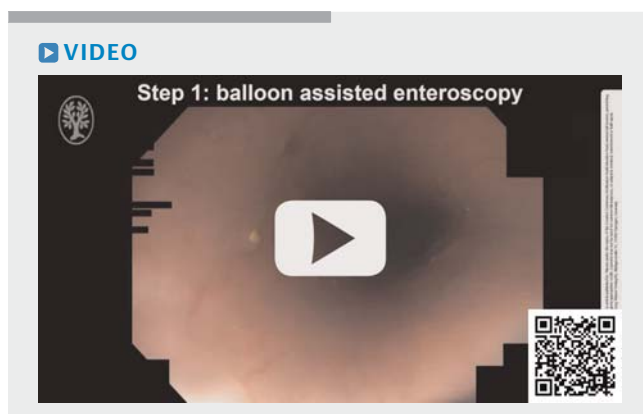
This step closes the pylorus and completely excludes the proximal small bowel from the nutrient stream. After this step is completed, the gastroenteric anastomosis serves as the sole conduit for the nutrient stream, therefore completing the gastrointestinal bypass.

An endoscope mounted with a suturing devise (OverStitch Endoscopic Suturing System, Apollo Endosurgery, Austin, Texas, United States) was used to close the pylorus with a single continuous 2.0 polypropylene suture (► **Fig. 2d**). The endoscope was kept in a short position to prevent excess linear force on the greater curvature of the stomach or the recently placed LAMS. To allow for reversibility, the pylorus is not de-epithelialized prior to suturing, and a single continuous suture is used that can be easily cut if necessary.

Step 4: Gastric restriction

This step reduces gastric volume by using a plication or suturing devise.

The stomach was reduced in volume, by the application of transmural sutures (OverStitch Endoscopic Suturing System, Apollo Endosurgery, Austin, Texas, United States). We adhered to the following principals while suturing the stomach: 1) preservation of a hypothetical 3- to 5-cm tubular zone that starts at the gastric inlet, runs along the lesser curvature and connects the gastric inlet to both the gastroenteric anastomosis and the pylorus; 2) no suturing of the gastric fundus or antrum; and 3) no suturing within 2 to 3 cm of the LAMS, as that may have compromised the gastric outlet or result in undue pressure on the LAMS (► **Fig. 2e**). After completion of the suturing portion of the procedure, the LAMS was dilated to 10 mm using a wire-guided dilating balloon. At the conclusion of the procedure, contrast was injected at the esophagogastric junction to fill the stomach. Under fluoroscopy, reduction of gastric volume combined with complete diversion of the enteric stream into the small bowel via the LAMS was ensured (► **Fig. 2f**). Following this, the endoscope and all accessories were withdrawn (► **Video 1**).



► **Video 1** Description of the ultrasound-assisted endoscopic gastric bypass (USA-EGB) procedure in a live swine model.

Results

We were able to successfully reduce gastric volume and achieve complete gastrointestinal bypass in all three consecutive live swine (► **Fig. 4**).

All three swine had stable vital signs throughout the procedure and there were no significant complications. The mean total intervention time was 131 minutes (range 113–143). The mean time for BAE was 44.3 minutes (range 40–52). The mean time for EUS-guided gastroenterostomy was 27 minutes (range 23–34), mean time for pyloric exclusion was 15.6 minutes (range 14–17), mean time for gastric restriction was 44.3 minutes (range 32–52).

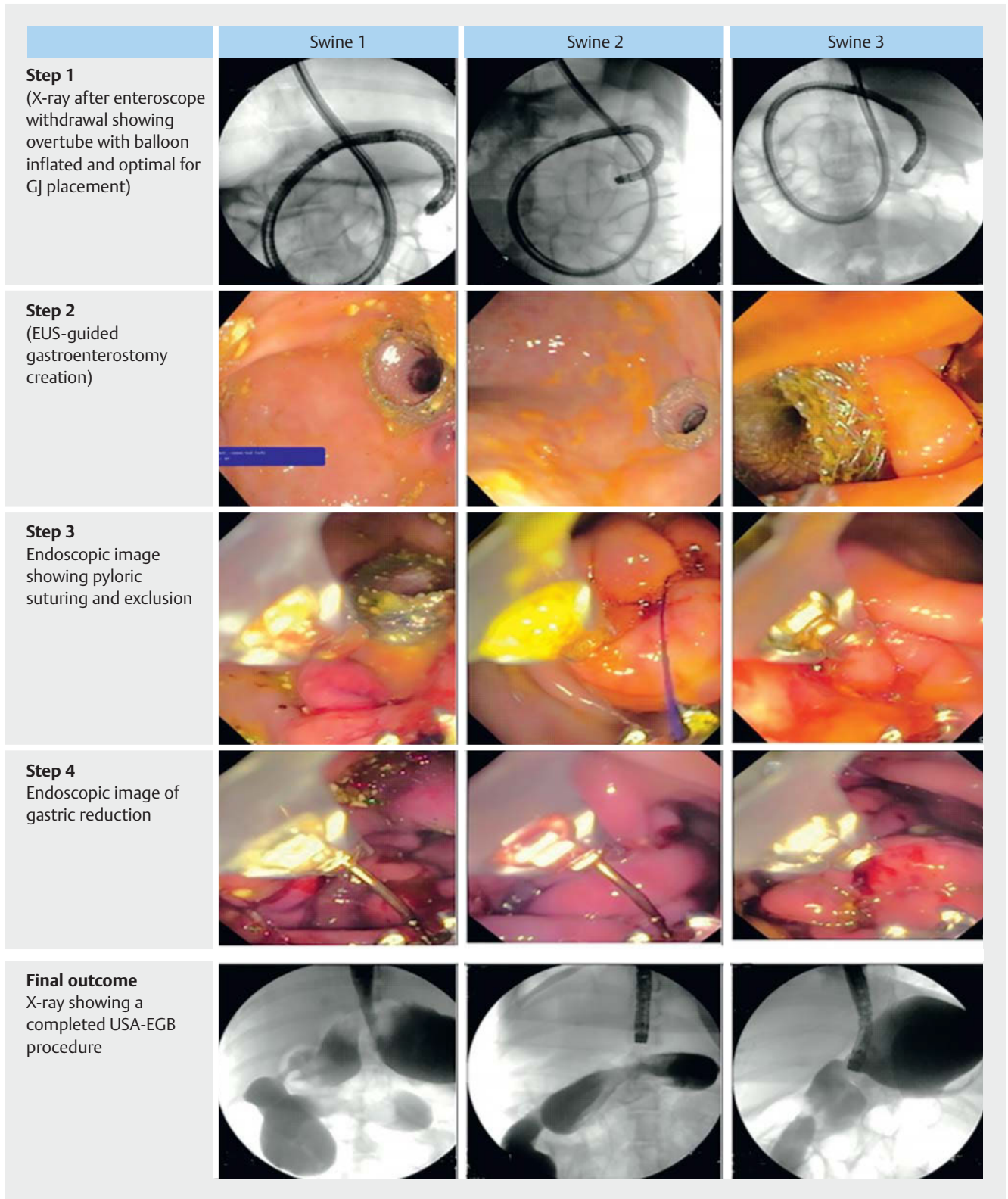
On necropsy, there was no significant intraperitoneal bleeding or enteric contamination in any of the swine. The stomachs were thoroughly examined and revealed topographic changes consistent with transmural suturing. There were no gross defects, misplaced sutures, or tethering to adjacent abdominal structures. The gastroenterostomy was inspected and found to be intact to palpation and visual inspection, with no gross leakage of air or gastric content. All three LAMS were located on the mid to distal posterior gastric wall. Using a flexible measuring tape, the bowel was measured three times from the duodenal-jejunal junction to the site of the enterotomy. The average length of the bypassed limb was 92.5 cm using the short overtube and 180 cm using the long overtube (► **Table 2**).

Discussion

In this preclinical proof-of-concept study, we have successfully demonstrated the use of a novel endoscopic technique that results in both gastroenteric bypass and gastric restriction. The procedure is arguably similar to a surgical single-anastomosis gastric bypass, one of the most commonly performed bypass operations in some countries [17].

Drawbacks of the study are as follows. First, this was a non-survival animal study. Swine have larger stomachs than humans and variant small bowel anatomy. Considering this, procedural dynamics and success on a swine model may not fully apply to humans. Weight loss trajectories and metabolic benefits remain unknown given the nonsurvival design of the study. Second, there is a relative paucity of literature supporting the safety of long-term LAMS use for gastroenteric anastomosis. This may not be clinically relevant, if the LAMS is removed and the bypass reversed within 6 months. Third, EUS-guided gastroenteric anastomosis is usually fashioned through the posterior wall of the stomach. The LAMS must transverse the transverse mesocolon, before reaching the small bowel. The mesocolon is likely to be thicker in an overweight human than it is in swine. Based on our experience with EUS-guided gastrojejunostomy, we feel that this may add some technical difficulty, but do not consider it to be prohibitive.

The bypass in USA-EGB may be potentially reversed while leaving gastric restriction intact (► **Fig. 5**). This is accomplished via endoscopic removal of the LAMS and cutting the polypropylene suture at the pylorus. Once the LAMS is removed, the gastroenteric anastomosis is likely to spontaneously close within a



► **Fig. 4** Pictographic depiction of various steps of the procedure in all three swine.

► **Table 2** Procedure results.

| | Swine model 1 | Swine model 2 | Swine model 3 |
|---|---------------|-----------------|-------------------------------|
| Balloon-assisted enteroscopy | 40 min | 41 min | 52 min |
| EUS-guided gastroenterostomy | 34 min | 24 min | 23 min |
| Pyloric exclusion | 17 min | 16 min | 14 min |
| Gastric restriction | 52 min | 32 min | 49 min |
| Total procedure time* | 143 min | 113 | 138 |
| No. sutures used for gastric volume reduction | 4 | 2 | 3 |
| No. full balloon cycles (fluoroscopy) | 15 | 15 | 15 |
| Procedure successful | Yes | Yes | Yes |
| Intraprocedure complications | No | No | Yes [†] |
| Evidence of complications on necropsy | No | No | No |
| Measured length of bypassed limb | 95 cm | 90 cm | 180 cm |
| Length of overtube used for the procedure | m (TS-13101) | 95 m (TS-13101) | 145 m (TS-13140) [‡] |

*Total procedure time, including a sum of scope-in to scope-out timings for each component of the procedure. Non-procedure time, including time spent to clear the stomach, arrange equipment etc. was not included.

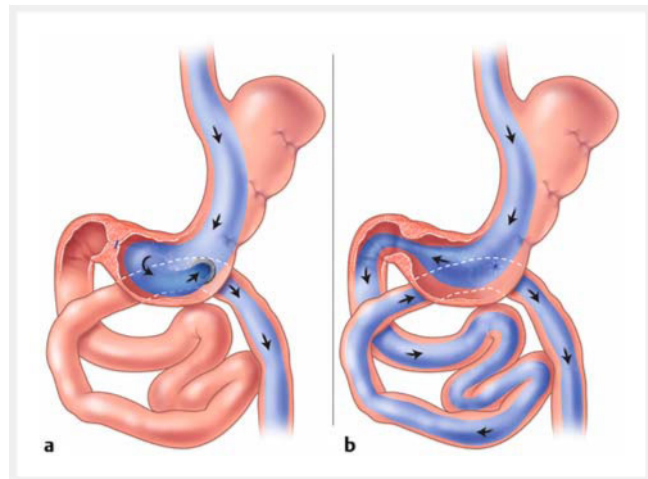
[†]Intragastic mis-deployment of a LAMS occurred during the gastroenterostomy portion of the procedure. After application of electrocautery, for unclear reasons, the LAMS did not make it through the gastric wall and was deployed into the stomach. The LAMS was retrieved using a rat toothed forceps. There was no evidence of pneumoperitoneum on x-ray and no transmural defect noted on endoscopy. Following this, a different electrocautery-enhanced LAMS was deployed into the small bowel without difficulty.

[‡]A longer overtube was used for the third model. This resulted in more efficient anterograde movement and enteroscopy. We believe this is because the overtube passed deeper into the small bowel and was able to engage it better beyond the duodenal-jejunal junction where most of the small bowel pleating occurs.

few days [18, 19]. If persistent, the fistula can be closed endoscopically via suturing. In addition, the pylorus was not de-epithelialized, and a single continuous suture was used during pyloric closure. Cutting the pyloric suture at a single location would open the pylorus and restore transpyloric continuity, hence reversing the gastroenteric bypass [20].

Conclusions

To our knowledge, this is the first successful description of a partially reversible ultrasound-guided endoscopic bypass procedure. The gastrointestinal bypass may be reversed, leaving gastric restriction intact. The procedure can be performed by a



► **Fig. 5** **a** Illustration of the USA-EGB procedure. **b** USA-EGB procedure after reversal of gastrointestinal bypass. This is accomplished via endoscopic removal of the LAMS and cutting the polypropylene suture at the pylorus. Source: Image courtesy of Elena S. Kalkoshina.

single endoscopist using equipment and accessories that are widely available. Further studies are needed to evaluate safety, efficacy, and clinical use.

Conflict of Interest

Dennis Yang: Consultant for Microtech, Medtronic, Olympus, Fuji-Flim, Apollo Endosurgery Mustafa Arain: Consultant for Cook, Merit, Boston Scientific and Olympus Muhammad Hasan: Consultant for Boston Scientific and Olympus Natalie Cosgrove: Consultant for Boston Scientific Shayan Irani: is a consultant for Boston Scientific, Conmed and Gore. The remaining authors have no conflict of interest to declare

References

- [1] Ward ZJ, Bleich SN, Cardock AL et al. Projected U.S. state-level prevalence of adult obesity and severe obesity. *N Engl J Med* 2019; 381: 2440–2450
- [2] Dobbs R et al. Overcoming obesity: an initial economic analysis. McKinsey global institute; 2014
- [3] Ward ZJ, Bleich SN, Long MW et al. Association of body mass index with health care expenditures in the United States by age and sex. *Plos One* 2021; 16: e0247307 doi:10.1371/journal.pone.0247307
- [4] Wadden TA, Webb VL, Moran CL et al. Lifestyle modification for obesity: new developments in diet, physical activity, and behavior therapy. *Circulation* 2012; 125: 1157–1170 doi:10.1161/CIRCULATIONAHA.111.039453
- [5] Shi Q, Wang Y, Hao QH et al. Pharmacotherapy for adults with overweight and obesity: a systematic review and network meta-analysis of randomised controlled trials. *Lancet* 2022; 399: 259–269
- [6] Kohn GP, Galanko JA, Overby DW et al. Recent trends in bariatric surgery case volume in the United States. *Surgery* 2009; 146: 375–380 doi:10.1016/j.surg.2009.06.005

- [7] Pickett-Blakely OE, Huizinga MM, Clark JM et al. Sociodemographic trends in bariatric surgery utilization in the USA. *Obesity Surgery* 2012; 22: 838–842 doi:10.1007/s11695-012-0629-9
- [8] Fung M, Wharton S, Macpherson A et al. Receptivity to bariatric surgery in qualified patients. *J Obesity* 2016; 2016: 5372190 doi:10.1155/2016/5372190
- [9] Wharto S, Serodio KJ, Sivapalan N et al. Interest, views and perceived barriers to bariatric surgery in patients with morbid obesity. *Clin Obes* 2016; 6: 154–160
- [10] Uhe I, Douissard J, Podetta M et al. Roux-en-Y gastric bypass, sleeve gastrectomy, or one-anastomosis gastric bypass? A systematic review and meta-analysis of randomized-controlled trials *Obesity (Silver Spring)* 2022; 30: 614–627 doi:10.1002/oby.23338
- [11] Khaitan L, Shea B et al. Current and future endoscopic weight loss solutions. *techniques in vascular and interventional radiology* 2020; 23: 100655 doi:10.1016/j.tvir.2020.100655
- [12] Gloy VL, Matthias B, Bhatt DL et al. Bariatric surgery versus non-surgical treatment for obesity: a systematic review and meta-analysis of randomised controlled trials. *BMJ* 2013; 347: 5934 doi:10.1136/bmj.f5934
- [13] Heymsfield SB, Wadden TA. Mechanisms, pathophysiology, and management of obesity. *N Engl J Med* 2017; 376: 254–266 doi:10.1056/NEJMr1514009
- [14] Gonzalez JM, Ouazzani S, Berdah S et al. Feasibility of a new bariatric fully endoscopic duodeenal-jejunal bypass: a pilot study in adult obese pigs. *Sci Rep* 2022; 12: 202–275
- [15] Barthet M, Binmoeller KF, Vanbiervlietm G et al. Natural orifice transluminal endoscopic surgery gastroenterostomy with a biflanged lumen-apposing stent: first clinical experience (with videos). *Gastrointest Endosc* 2015; 81: 215–218
- [16] Lee CL, Lium HM, Khan S et al. Vaginal natural orifice transvaginal endoscopic surgery (vNOTES) surgical staging for endometrial carcinoma: The feasibility of an innovative approach. *Taiwan J Obstet Gynecol* 2022; 61: 345–352
- [17] Haddad A, Bashir A, Fobi M et al. The IFSO Worldwide One Anastomosis Gastric Bypass Survey: Techniques and Outcomes? *Obes Surg* 2021; 31: 1411–1421 doi:10.1007/s11695-021-05249-5
- [18] Betés M, Perez-Longo P, Peralta S et al. Feasibility and patency of echoendoscopic anastomoses with lumen apposing metal stents depending on the gastrointestinal segment involved. *Sci Rep* 2021; 11: 3992 doi:10.1038/s41598-021-83618-x
- [19] Kerdsirichairat T, Irani S, Yang J et al. Durability and long-term outcomes of direct EUS-guided gastroenterostomy using lumen-apposing metal stents for gastric outlet obstruction. *Endosc Int Open* 2019; 7: E144–E150 doi:10.1055/a-0799-9939
- [20] Kadkhodayan K, Hussain A, Khan H et al. Endoscopic pyloric exclusion-EUS-guided gastrojejunostomy combined with endoscopic suturing and closure of the pylorus: a novel approach to failed surgical repair of a perforated duodenal ulcer. *VideoGIE* 2023; 8: 121–123