

# Toxoplasma gondii Infection in Pregnancy – Recommendations of the Working Group on Obstetrics and Prenatal Medicine (AGG – Section on Maternal Disorders)

## Toxoplasma-gondii-Infektion in der Schwangerschaft – Empfehlungen der Arbeitsgemeinschaft Geburtshilfe und Pränatalmedizin (AGG – Sektion Maternale Erkrankungen)



### Authors

Michael Oliver Schneider<sup>1</sup>, Florian Faschingbauer<sup>1</sup>, Karl Oliver Kagan<sup>2</sup>, Uwe Groß<sup>3</sup>, Martin Enders<sup>4</sup>, Sven Kehl<sup>1</sup>, for the AGG Section Maternal Diseases

### Affiliations

- 1 Department of Gynaecology and Obstetrics, Erlangen University Hospital, Friedrich-Alexander University Erlangen-Nürnberg, Erlangen, Germany
- 2 Department for Women's Health, University Hospital of Tübingen, Tübingen, Germany
- 3 Institute of Medical Microbiology and Virology, University Medical Centre Göttingen, Göttingen, Germany
- 4 Laboratory Prof. Gisela Enders and Colleagues, Stuttgart, Germany

### Key words

pregnancy, transmission, therapy, *Toxoplasma gondii*, congenital toxoplasmosis

### Schlüsselwörter

Schwangerschaft, Toxoplasmose, Diagnostik, Transmissionsprophylaxe, Therapie

received 14.6.2023  
accepted after revision 18.7.2023  
published online 18.9.2023

### Bibliography

Geburtsh Frauenheilk 2023; 83: 1431–1445

DOI 10.1055/a-2111-7394

ISSN 0016-5751


© 2023. The Author(s).

This is an open access article published by Thieme under the terms of the Creative Commons Attribution-NonDerivative-NonCommercial-License, permitting copying and reproduction so long as the original work is given appropriate credit. Contents may not be used for commercial purposes, or adapted, remixed, transformed or built upon. (<https://creativecommons.org/licenses/by-nc-nd/4.0/>)

Georg Thieme Verlag KG, Rüdigerstraße 14,  
70469 Stuttgart, Germany

### Correspondence

Priv.-Doz. Dr. med. Michael Oliver Schneider  
Department of Gynaecology and Obstetrics, Erlangen University Hospital, Friedrich-Alexander University Erlangen-Nürnberg  
Universitätsstraße 21–23, 91054 Erlangen, Germany  
[michael.schneider@uk-erlangen.de](mailto:michael.schneider@uk-erlangen.de)

 Deutsche Version unter:  
<https://doi.org/10.1055/a-2111-7394>

### ABSTRACT

**Aim** The AGG (Working Group for Obstetrics and Prenatal Diagnostics, Section Maternal Diseases) has issued these recommendations to improve the detection and management of *Toxoplasma gondii* infection in pregnancy.

**Methods** Members of the Task Force developed the recommendations and statements presented here using recently published literature. The recommendations were adopted after a consensus process by members of the working group.

**Recommendations** This article focuses on the epidemiology and pathophysiology of *Toxoplasma gondii* infection in pregnancy and includes recommendations for maternal and fetal diagnosis, transmission prophylaxis, therapy, prevention, screening, and peripartum management.

### ZUSAMMENFASSUNG

**Ziel** Diese Empfehlungen der AGG (Arbeitsgemeinschaft für Geburtshilfe und Pränatalmedizin, Sektion maternale Erkrankungen) haben das Ziel der Verbesserung der Diagnostik und des Managements von *Toxoplasma-gondii*-Infektionen in der Schwangerschaft.

**Methoden** Basierend auf der aktuellen Literatur entwickelten die Mitglieder der Task Force die vorliegenden Empfehlungen und Stellungnahmen. Diese Empfehlungen wurden nach einem Konsens der Mitglieder der Arbeitsgruppe verabschiedet.

**Empfehlungen** Das folgende Manuskript beschäftigt sich mit der Epidemiologie und Pathophysiologie von Toxoplasma-gondii-Infektionen in der Schwangerschaft und enthält Empfehlungen zu maternaler und fetaler Diagnostik, Transmissionsprophylaxe, Therapie, Prävention, Screening und peripartalem Management.

## 1 Introduction

Toxoplasma gondii infection in pregnancy can be dangerous for the fetus. As screening is currently not legally required in Germany and there is no clear evidence regarding the best strategy in pregnancy, there is currently no consistent approach used for the diagnosis and therapy of this infection. This paper therefore includes a review of the current data together with a list of recommendations for the appropriate approach in pregnancy based on the available literature.

## 2 Methodology

The RKI guideline on toxoplasmosis published in 2018 [1] was used as the basis for compiling these recommendations. In addition, we carried out a MEDLINE literature search using the search terms “pregnancy AND toxoplasmosis” and the filters “meta-analysis,” “systematic review” and “10 years”. Identified abstracts were reviewed for relevance and relevant studies were consulted for this publication. Topic-related literature searches were additionally carried out to cover specific individual questions.

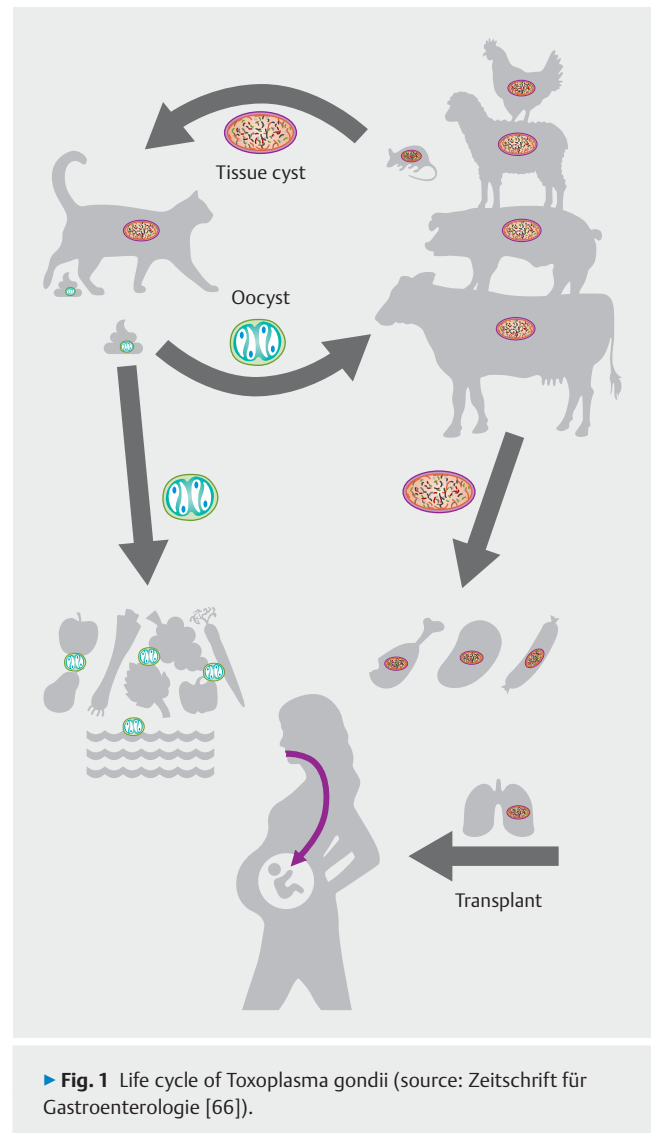
## 3 Pathogen, Transmission and Epidemiology

Toxoplasmosis is a zoonotic disease caused by the intracellular protozoan parasite Toxoplasma (*T.*) gondii.

Sexual development and reproduction of *T. gondii* occur in the epithelial cells of the feline bowel following initial oral ingestion of the parasite by cats or other Felidae (definitive hosts) (► Fig. 1). Oocysts are subsequently shed in the feces and develop into infectious sporozoites after 24 hours' maturation in the open air; in suitable climatic conditions they can survive several months to years.

Ingestion of water or food contaminated by oocysts [2] leads to initial infection of the intestinal epithelium in the intermediate host (all warm-blooded creatures, including cattle, pigs, birds, and humans) and, following hematogenic spread, to lifelong persistence in the form of tissue cysts containing slowly replicating bradyzoites in different types of tissue (primarily the brain, but also the retina and in skeletal and cardiac musculature) [1]. After primary infection, most people become immune but reactivation can occur in immunocompromised persons (e.g., patients with AIDS or transplant recipients).

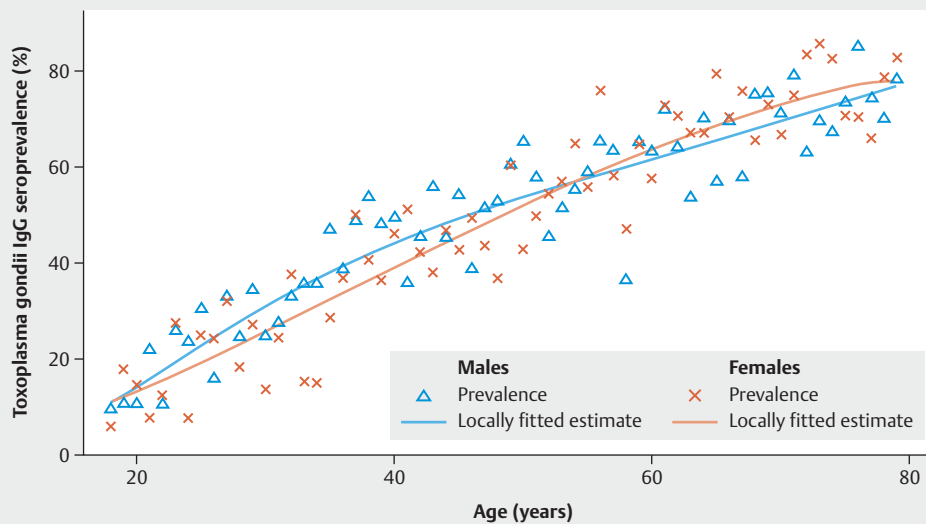
Infection of humans occurs through the oral ingestion of sporulated oocysts (e.g., after forgetting to wash hands after working in the garden or eating unwashed vegetables) or of tissue



► Fig. 1 Life cycle of *Toxoplasma gondii* (source: Zeitschrift für Gastroenterologie [66]).

cysts containing vital bradyzoites (in raw or undercooked meat). Very rarely, transmission can occur through a patient receiving an infected transplant [3].

In Germany, the main cause of infection is assumed to be the consumption of raw meat products such as sausages and ground pork (mince). Additional risk factors are a high body mass index (BMI) and domestic cats [2].



► **Fig. 2** Estimated seroprevalence of *Toxoplasma gondii*-specific antibodies according to age (18–79 years) and gender in Germany, 2008–2011 [2].

#### AGG STATEMENT (1)

In Germany, more than half of all women of child-bearing age are seronegative and their first infection with *Toxoplasma gondii* can occur in pregnancy.

In addition to the transmission routes described above, primary infection during pregnancy can lead to congenital toxoplasmosis in the infant.

It is assumed that one third of the global population has been infected with *Toxoplasma gondii* [4]. According to an evaluation of the RKI (Robert Koch Institute) for the years 2008–2011, seroprevalence in women of child-bearing age in Germany increases with age from around 20% (age range: 18–29 years) to almost 50% (age range: 40–49 years) (► **Fig. 2**) [2]. The seroprevalence measured in 1992 in a cohort of pregnant women in Germany was 39% (n = 5670, age range: 15–47 years) [5].

The incidence of seroconversion in pregnancy is estimated to be 1325/100 000 pregnancies (i.e., 1% of pregnancies) [2] although, according to an analysis of data from health insurance companies in Germany, acute infection with *T. gondii* was only diagnosed in 40/100 000 pregnancies [6].

## 4 Maternal Symptoms

#### AGG STATEMENT (2)

Infection with *Toxoplasma gondii* is generally asymptomatic in immunocompetent pregnant women.

In immunocompetent adults, mononucleosis-related symptoms such as fever, headache and cervical/occipital lymphadenopathy occur in less than 10% of infections following an incubation period of between one and three weeks. Symptoms can persist for several weeks. In exceptional cases, infected immunocompetent patients may present with maculopapular rash, reactive arthritis, hepatosplenomegaly, or other organic abnormalities [4, 7].

Infection with *T. gondii* in immunocompromised pregnant women can cause severe encephalitis, myocarditis, pneumonitis, or hepatitis [8].

## 5 Congenital Toxoplasmosis

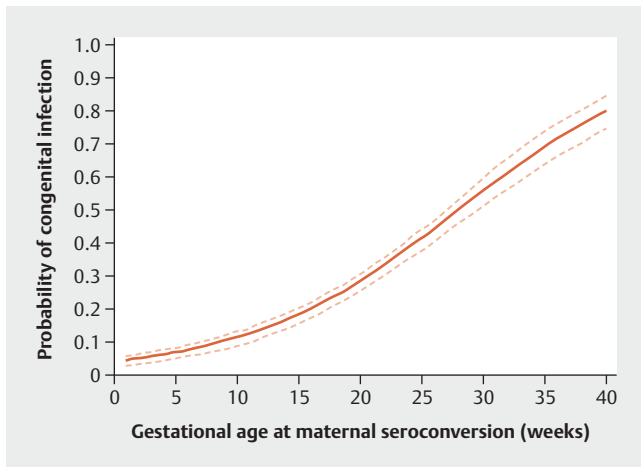
Transplacental infection of the fetus can develop following primary infection of a previously seronegative mother or rare reactivation of *Toxoplasma gondii* in a pregnant seropositive woman who is severely immunocompromised. Maternal-fetal transmission occurs between one and four months after placental colonization by *Toxoplasma gondii* [8]. The placenta acts as both a barrier and a reservoir for *Toxoplasma gondii* [9].

### 5.1 Epidemiology of congenital toxoplasmosis

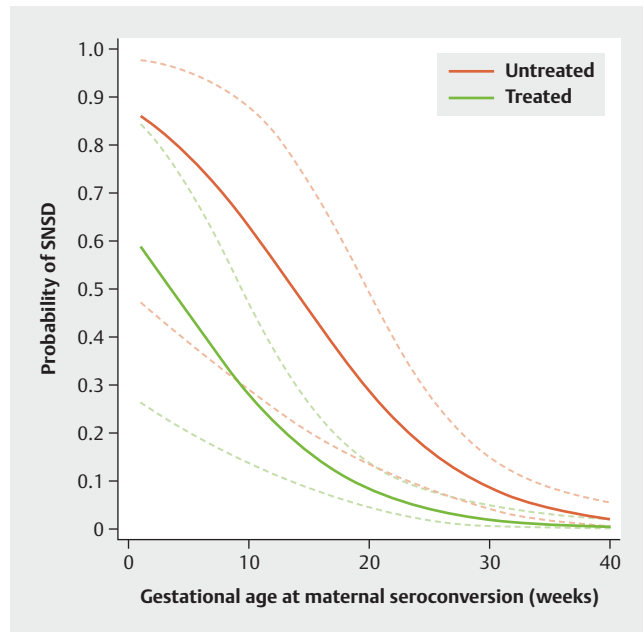
#### AGG STATEMENT (3)

The rate of maternal-fetal transmission of *T. gondii* increases with gestational age, although the risk of severe fetal disease decreases with increasing duration of the pregnancy.

Overall, between 6 and 23 cases of congenital toxoplasmosis are reported to the RKI every year in Germany [1], although a review of health insurance data covering the same time period found 43–



► **Fig. 3** Risk of *T. gondii* transmission between mother and fetus according to gestational age when maternal seroconversion has occurred (during maternal treatment with medication) [15].



► **Fig. 4** Probability of serious neurological sequelae or death of infected fetuses (including abortion) depending on the time of maternal seroconversion and treatment [51].

116 diagnosed cases. It is generally thought that the number of unrecorded cases of fetal infection is much higher (e.g., due to miscarriage or asymptomatic course of disease) and the real number of cases with congenital toxoplasmosis is assumed to be around 1300 asymptomatic and 350 symptomatic cases annually [2].

As with other infectious diseases, the rate of maternal-fetal transmission of toxoplasmosis increases with gestational age (► **Fig. 3**), although the risk of severe fetal disease decreases with increasing duration of pregnancy (► **Fig. 4**). The data on maternal-fetal transmission rates were obtained from studies in which the majority of infected mothers received medication after being diagnosed.

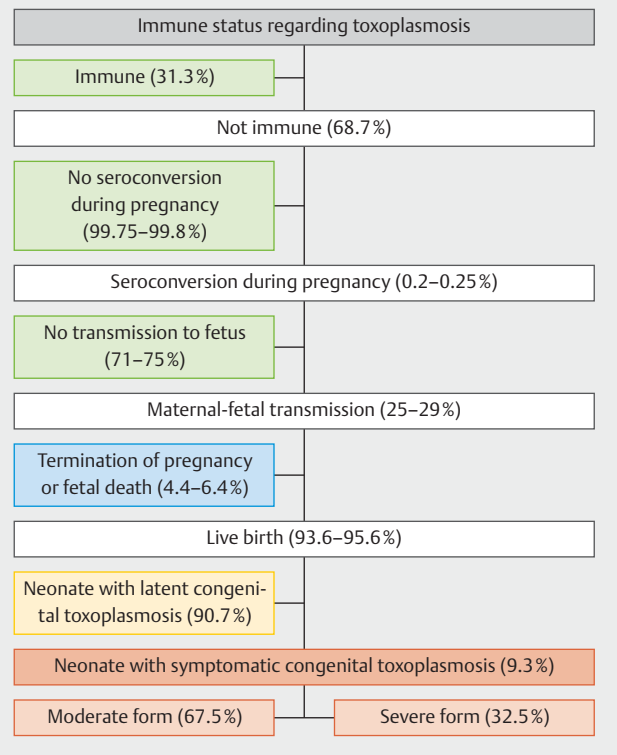
Based on the drug regimen commonly used in Germany, the reported rates of transmission were 1.3% if maternal infection occurred in the 1st trimester of pregnancy, 10.6% if infection occurred in the 2nd trimester and 21.7% if infection occurred in the 3rd trimester [10].

## 5.2 Fetal and neonatal symptoms

The typical triad associated with symptomatic congenital infection with toxoplasmosis was first described in the 1950s by Dr. Albert Sabin [11] and consists of retinochoroiditis, cerebral calcifications and hydrocephalus.

Data from France (2006–2017, ► **Fig. 5**) obtained from prenatal screening and the treatment of liveborn children with congenital toxoplasmosis at birth showed that 90.7% of cases were asymptomatic and 9.3% were symptomatic. Two thirds of symptomatic children had moderate symptoms (intracranial calcifications, peripheral retinochoroiditis) and 1/3 presented with severe symptoms (disseminated toxoplasmosis, hydrocephalus or retinochoroiditis affecting the macula) [12].

It appears that severe forms of congenital toxoplasmosis with hydrocephalus only occur if maternal infection occurs in the 1st and 2nd trimester of pregnancy [13], whereas retinochoroiditis may also occur following infection in the 3rd trimester [10, 14].



► **Fig. 5** Flowchart showing the risk of the fetus or neonate developing disease based on maternal seroconversion of toxoplasmosis (source: Picone et al. [12]).

Depending on the start and type of therapy, the percentage of symptomatic neonates reported in the literature varies significantly.

### 5.2.1 Retinochoroiditis

#### AGG STATEMENT (4)

Ocular lesions (toxoplasma retinochoroiditis) may first appear several years after birth in cases with congenital toxoplasmosis.

15.5–26% of children with congenital toxoplasmosis go on to develop retinochoroiditis [15–18]. These data were obtained from studies in which the majority of children received prenatal and/or postnatal treatment with antiparasitic medication.

Visual impairment of the more strongly affected eye occurs in 29% of children with toxoplasma retinochoroiditis [19]. Severe bilateral visual impairment is rare (9%) [20,21]. Ocular lesions may first appear several years after birth (39% at birth, 85% before 5 years of age, 96% before 10 years of age) [16].

In one study of 102 patients (12.7% of whom had impaired vision) the impact of congenital toxoplasmosis on quality of life was described as low [22], whereas a study of 16 children with impaired vision by Roizen et al. also reported lower cognitive abilities in these children compared to 48 children with no visual impairments [23].

### 5.2.2 Neurological outcome

#### AGG STATEMENT (5)

Symptomatic congenital toxoplasmosis can have severe neurological consequences such as hydrocephalus and/or psychomotor retardation. These consequences have become relatively rare due to the administration of medical therapy pre- and postnatally.

In 1960, Heinz Eichenwald described an untreated cohort of children infected with *T. gondii* during pregnancy who had generalized or neurological symptoms at birth. At follow-up after 4 years, more than 85% presented with mental retardation, 81% had seizures, 70% presented with motor impairments, 60% had severe visual impairments and 33% had hydrocephalus or microcephalus. Only 11% of children had no symptoms [24].

More recent publications largely describe the outcomes of children who received intrauterine treatment and/or postnatally. Hydrocephalus is now reported to occur in only 4% of symptomatic neonates [25]. In the study by Hotop et al., only 2 of 11 fetuses presented with hydrocephalus in utero (in both cases, therapy had been delayed by > 8 weeks), although discreet residual traces were only found in one of the children at birth.

In 2004, Wallon et al. described a cohort of 327 children with confirmed congenital toxoplasmosis [21]. Intrauterine therapy with pyrimethamine and sulfadiazine was administered in 38% of

cases and postnatal therapy with pyrimethamine and sulfadiazine was given to 72% of cases. After a median follow-up of 6 years, 24% had retinal lesions, 9% had cerebral calcifications, 2% had hydrocephalus and < 1% had microcephalus. Three of the six children with hydrocephalus had moderate psychomotor retardation; development was normal in the other three. Two of the 31 children with cerebral calcifications had had a single seizure episode. McLone et al. reported on 65 children with hydrocephalus due to congenital toxoplasmosis. Presentation ranged from normal cognitive function to severe developmental disorders. Early placement of a ventriculoperitoneal shunt (< 25 days after diagnosis) improved the outcome. Nevertheless, almost 30% of the children in this group were too cognitively impaired to participate in formal intelligence tests [26].

It has been reported that certain subtypes of *Toxoplasma gondii* found outside Europe and the USA are associated with severe clinical manifestations in children [19,27,28].

## 6 Diagnosis

### 6.1 Maternal serological diagnosis

#### AGG RECOMMENDATION (1)

All serological toxoplasmosis findings must be recorded in the mother's maternity health passport.

#### AGG STATEMENT (6)

Primary infection with *Toxoplasma gondii* during pregnancy can either be confirmed by serology test showing seroconversion in a previously seronegative mother or assumed based on estimating the time of infection using avidity analysis and follow-up serum tests.

#### AGG RECOMMENDATION (2)

Every positive IgM antibody (Ab) test in a pregnant woman must be investigated further in a specialized laboratory.

The diagnosis of maternal primary infection with *T. gondii* in pregnancy is confirmed by the detection of *Toxoplasma gondii*-specific antibodies in a previously seronegative patient (seroconversion) [29].

If negative results were not previously found during the pregnancy, evidence of *Toxoplasma*-specific IgG antibodies before 18 weeks of gestation (GW) combined with seronegativity for *Toxoplasma*-specific IgM antibodies are an indication that the pregnant woman is probably immune (in terms of protection of the unborn child) due to a previous infection prior to her current pregnancy [29]. Rare exceptions include *Toxoplasma gondii* infection with merely transient or completely absent formation of IgM

antibodies or reactivation of *Toxoplasma gondii* in an immunocompromised woman or reinfection with a virulent strain [30].

Reinfection or reactivation in pregnant women has been reported in individual cases but it is very rare. It appears that more virulent (atypical) toxoplasma strains and maternal immune status play an important role [31, 32].

If IgG antibodies are first detected after 18 weeks of gestation (GW) or IgM antibodies are detected, further investigations, consisting of additional serology tests (e.g., IgG avidity, immunoblot, IgA tests, analysis of older retention samples) must be carried out by a laboratory with the relevant expertise to differentiate acute infection in pregnancy with an associated fetal risk from infection prior to pregnancy which does not put the fetus at risk (see also the guide to toxoplasmosis issued by the RKI [1]).

This is particularly important because IgM can persist for several years in individual cases and a positive IgM result (especially a low IgM titer) does not always equate to acute *Toxoplasma gondii* infection. An American study showed that a positive IgM result provided by a non-reference laboratory was only confirmed as acute infection by a reference laboratory in 40% of cases [33].

## 6.2 Amniocentesis

### AGG RECOMMENDATION (3)

Amniocentesis may be carried out after weighing up the risks and benefits if the result will affect the decision for or against initiating therapy.

Fetal infection can be diagnosed using amniocentesis and polymerase chain reaction (PCR) of *Toxoplasma* DNA obtained from amniotic fluid.

Most data on sensitivity and specificity and negative predictive value are available for amniocentesis carried out **at least 4 weeks after primary infection of the mother (i.e., two weeks after maternal seroconversion) and from week 18 + 0 of gestation**. These are the time periods given in French, Canadian and US recommendations as well as by the RKI as a precondition for amniocentesis [1, 8, 34, 35]. This is because from that period on, fetal urine production is sufficient to allow detection of fetal toxoplasma infection in amniotic fluid [36].

Depending on the study, the overall sensitivity of toxoplasma PCR obtained by amniocentesis in pregnancy ranges from 69–92%. This means that a negative PCR test does not completely exclude fetal infection. Even though the lowest sensitivity is reported for the first trimester of pregnancy (56.7% [37]), some studies have reported that the negative predictive value showing increasing probability of fetal infection decreases with gestational age (1st trimester: 98–99%; 2nd trimester: 92–99%; 3rd trimester: 56–100%) [38–41].

The specificity of toxoplasma PCR in amniotic fluid is 98–100% [38–41]. A positive PCR result is therefore generally an indication of fetal infection.

According to an evaluation carried out by the Austrian prenatal screening program, starting anti-toxoplasmosis treatment prior

to amniocentesis had no impact on the sensitivity and specificity of amniocentesis [42].

Most international recommendations generally advise carrying out amniocentesis in cases with maternal *Toxoplasma gondii* infection in pregnancy to allow the drug treatment regimen to be adjusted in cases with fetal infection (► **Table 1**) and avert or reduce fetal injury. Prospective randomized studies on this are lacking. A more restrictive approach has been proposed in cases with infection after 24 GW or in the 3rd trimester, as the risk of complications of amniocentesis must also be taken into account [8, 34]. The RKI has generally stated that the risk associated with amniocentesis must also be considered (the risk of miscarriage according to recent meta-analyses is 0.1–0.3% [43]). The RKI therefore recommends that irrespective of gestational age, great caution must be exercised when taking the decision to carry out amniocentesis, stating that amniocentesis “may be considered if the result would be relevant for the decision to initiate therapy.” In accordance with these cautious recommendations for amniocentesis in Germany, in the cohort of Hotop et al. [10] amniocentesis was only carried out in 12.1% of cases with maternal toxoplasmosis in pregnancy.

## 6.3 Fetal ultrasound

### AGG RECOMMENDATION (4)

If maternal infection with *Toxoplasma gondii* has been confirmed, ultrasound examinations should be carried out at 4-weekly intervals (the examiner must have the appropriate qualifications, e.g., DEGUM level II) to exclude signs of fetal infection.

### AGG RECOMMENDATION (5)

The interval between control examinations should be changed to once every 2 weeks if maternal-fetal transmission is confirmed.

### AGG RECOMMENDATION (6)

Magnetic resonance imaging may be additionally carried out if the ultrasound findings are unremarkable or unclear.

In the largest cohort of fetuses with congenital toxoplasmosis and ultrasound abnormalities to date, isolated cerebral anomalies were found in 45 of 88 cases and a combination of cerebral and extracerebral anomalies in 35 of 88 cases. Isolated extracerebral anomalies were found in 8 of 88 cases [13].

The most common intracranial lesions are hyperechoic foci, progressive ventriculomegaly and periventricular abscesses. This type of ultrasound findings occurred almost exclusively following infection in the 1st and 2nd trimester of pregnancy. Postnatally, hyperechoic foci presented as calcifications which became smaller or were no longer detectable on imaging in 75% of cases following

► **Table 1** Review of recommendations on toxoplasmosis during pregnancy issued by different national and international working groups, professional societies and institutes.

Country	Author	Year	Type of publication	Recommendations			
				Screening	Treatment	Amniocentesis (AC)	Follow-up
France	Mandelbrot et al. [47]	2021	Expert opinion	<ul style="list-style-type: none"> <li>Since 1992</li> <li>Serology test at first presentation in the 1st trimester; if seronegative: monthly serology tests until the birth</li> </ul>	<p><b>Maternal infection between 2 and 6 GW:</b></p> <ul style="list-style-type: none"> <li>Ultrasound examination 1× per trimester</li> <li>Neonatal examination after birth</li> <li>Spiramycin/AC not recommended</li> </ul> <p><b>Maternal infection between 6 and 14 GW:</b></p> <ul style="list-style-type: none"> <li>Spiramycin* until the birth if AC is negative</li> <li>If AC is positive: pyrimethamine/sulfadiazine/folinic acid** until the birth</li> </ul> <p><b>Maternal infection between 14 and 32 GW:</b></p> <ul style="list-style-type: none"> <li>Start with pyrimethamine/sulfadiazine/folinic acid** as soon as possible (inform patient about the alternative option of spiramycin*)</li> <li>If AC is negative: pyrimethamine/sulfadiazine for a total of four weeks, then switch to spiramycin* until the birth</li> <li>If AC is positive: pyrimethamine/sulfadiazine/folinic acid** until the birth</li> </ul> <p><b>Maternal infection after 32 GW:</b></p> <ul style="list-style-type: none"> <li>Start with pyrimethamine/sulfadiazine/folinic acid** as soon as possible and continue until the birth</li> <li>Recommend AC to plan postnatal diagnostic examinations/therapy</li> </ul> <p>* 3 × 1 g spiramycin/day</p> <p>** 50 mg pyrimethamine/day + 2 × 1.5 g sulfadiazine/day + 2 × 25 mg folinic acid/week</p> <p>Alternatively, if medications are not available: cotrimoxazole and folinic acid or pyrimethamine, azithromycin and folinic acid</p>	<ul style="list-style-type: none"> <li>Not before 18 GW</li> <li>No earlier than 4 weeks after the presumed time of maternal infection</li> <li>Generally recommended after infection in every trimester of pregnancy</li> </ul>	<ul style="list-style-type: none"> <li>Monthly ultrasound examinations</li> <li>If AC is positive, examinations every two to four weeks</li> </ul>
Canada	SOGC [8]	2018	Clinical Practice Guideline	<ul style="list-style-type: none"> <li>No routine screening</li> <li>Only in high-risk cohorts (immunosuppression, ultrasound anomalies: e. g. intracranial calcifications, microcephalus, hydrocephalus, ascites, hepatosplenomegaly, FGR)</li> </ul>	<p><b>Maternal infection in pregnancy without fetal infection:</b></p> <ul style="list-style-type: none"> <li>Spiramycin*</li> </ul> <p><b>Confirmed or highly suspicious for fetal infection:</b></p> <ul style="list-style-type: none"> <li>Pyrimethamine/sulfadiazine/folinic acid**</li> </ul> <p>* 3 × 1 g spiramycin/day, no information about duration</p> <p>** No information about dosages or duration</p>	<ul style="list-style-type: none"> <li>Not before 18 GW</li> <li>No earlier than 4 weeks after the presumed time of maternal infection</li> <li>Generally recommended after infection in every trimester, late in the 3rd trimester (individual decision)</li> </ul>	No data provided

Continued next page

► **Table 1** Review of recommendations on toxoplasmosis during pregnancy issued by different national and international working groups, professional societies and institutes. (Continued)

Country	Author	Year	Type of publication	Recommendations			
				Screening	Treatment	Amniocentesis (AC)	Follow-up
Austria	Infectiology Working Group of the Austrian Society for Pediatrics [65]	2013	Guideline	<ul style="list-style-type: none"> <li>Since 1975</li> <li>Serology test in the first trimester before 9 + 0 GW; if test is seronegative, serology test every 8 weeks until the birth (IgG; if this is positive, also IgM)</li> <li>If findings are positive: start therapy and test again after 14 days</li> <li>At birth: final testing of maternal or umbilical cord blood</li> </ul>	<p><b>Therapy of acute toxoplasmosis during pregnancy:</b></p> <ul style="list-style-type: none"> <li>Spiramycin* until 15 + 6 GW</li> <li>From 16 + 0 GW: pyrimethamine/sulfadiazine/folinic acid** for 4 weeks</li> </ul> <p>Additional treatment depending on results of AC:</p> <p><b>PCR from amniotic fluid is positive or AC not carried out:</b></p> <ul style="list-style-type: none"> <li>alternate 4 weeks of combination therapy (pyrimethamine/sulfadiazine/folinic acid**) and 4 weeks spiramycin* until the birth</li> </ul> <p><b>Negative PCR from amniotic fluid:</b></p> <ul style="list-style-type: none"> <li>Spiramycin* until the birth</li> </ul> <p>* 3 × 750 mg spiramycin/day</p> <p>** 25 mg pyrimethamine/day (on day 1: 50 mg) + 1 × 750 mg sulfadiazine/day (day 1: 3 × 500 mg) + 3 × 15 mg folinic acid/week</p>	<ul style="list-style-type: none"> <li>All pregnant women with confirmed acute infection</li> <li>From 15 + 0 GW</li> <li>Optimally before starting therapy (no contraindication if therapy has already been initiated)</li> </ul>	<ul style="list-style-type: none"> <li>If AC is positive: ultrasound examinations every 4 weeks</li> </ul>
USA	Committee on Infectious Diseases (American Academy of Pediatrics) Maldonado et al. [34]	2017	Review with treatment recommendations by the PAMF-TSL (Palo Alto Medical Foundation Toxoplasma Serology Laboratory)	<ul style="list-style-type: none"> <li>Data is still insufficient</li> </ul>	<p><b>Treatment of acute toxoplasmosis if maternal infection occurred between 3 months prior to conception and 18 + 0 GW:</b></p> <ul style="list-style-type: none"> <li>Spiramycin*</li> </ul> <p><b>If AC is negative:</b></p> <ul style="list-style-type: none"> <li>Spiramycin* until the birth</li> </ul> <p><b>If AC is positive or ultrasound suspicious for fetal infection:</b></p> <ul style="list-style-type: none"> <li>Pyrimethamine/sulfadiazine/folinic acid** until the birth</li> </ul> <p><b>Therapy of acute toxoplasmosis during pregnancy if maternal infection occurred after 18 + 0 SSW:</b></p> <ul style="list-style-type: none"> <li>Pyrimethamine/sulfadiazine/folinic acid** until the birth</li> </ul> <p>* 3 × 1 g spiramycin/day</p> <p>** 50 mg pyrimethamine/day (on days 1 and 2: 2 × 50 mg/d) + 2 × 50 mg/kg/bw Sulfadiazine/day (max. 4 g/d; day 1: 2 × 37.5 mg/kg/bw) + 10–12 mg folinic acid/day (continue until 1 week after pyrimethamine therapy)</p>	<ul style="list-style-type: none"> <li>As soon as possible from 18 + 0 GW</li> <li>The risk of complications from week 24 of gestation should be considered</li> </ul>	<p>Monthly ultrasound examinations</p>
International	ISUOG (The International Society of Ultrasound in Obstetrics and Gynecology) [36]	2020	Practice Guideline	<ul style="list-style-type: none"> <li>No data provided</li> </ul>	<p><b>Therapy of acute toxoplasmosis during pregnancy:</b></p> <ul style="list-style-type: none"> <li>Spiramycin* until the birth</li> </ul> <p><b>If AC is positive:</b></p> <ul style="list-style-type: none"> <li>Spiramycin* for one week.</li> <li>Then pyrimethamine/sulfadiazine/folinic acid** until the birth</li> </ul> <p>* 3 × 1 g spiramycin/day</p> <p>** 50 mg pyrimethamine/day + 3 × 1 g sulfadiazine/day + 50 mg folinic acid/week</p>	<ul style="list-style-type: none"> <li>Not before 18 GW</li> <li>No earlier than 4 weeks after the presumed time of maternal infection</li> </ul>	<ul style="list-style-type: none"> <li>Ultrasound examinations every 4 weeks (brain, eyes, fetal growth should be monitored)</li> <li>Possibly MRI if ultrasound results are unremarkable</li> </ul>

Continued next page



► **Table 1** Review of recommendations on toxoplasmosis during pregnancy issued by different national and international working groups, professional societies and institutes. (Continued)

Country	Author	Year	Type of publication	Recommendations			
				Screening	Treatment	Amniocentesis (AC)	Follow-up
Germany	RKI (Robert Koch Institute) [1]	2018	Guide	<ul style="list-style-type: none"> <li>No data provided</li> </ul>	<p><b>Therapy of acute toxoplasmosis during pregnancy:</b></p> <ul style="list-style-type: none"> <li>Up until 14 + 6 GW: spiramycin*</li> <li>From 15 + 0 GW: pyrimethamine/sulfadiazine/folinic acid** for at least 4 weeks</li> </ul> <p><b>if anomalies are detected on ultrasound:</b></p> <ul style="list-style-type: none"> <li>Pyrimethamine/sulfadiazine/folinic acid** until the birth</li> </ul> <p>* 3 g (9 MIU) spiramycin/day</p> <p>** 25 mg pyrimethamine/day (on day 1: 50 mg) + 50 mg/kg/bw sulfadiazine/day (3 g/day for &lt; 80 kg/bw, 4 g/day for &gt; 80 kg/bw) + 10–15 mg folinic acid/day</p>	<ul style="list-style-type: none"> <li>Caution is advised before opting for AC. AC may be considered if the results would be relevant when deciding to initiate therapy</li> <li>Not before 18 GW</li> <li>No earlier than 4 weeks after the presumed time of maternal infection</li> </ul>	<ul style="list-style-type: none"> <li>No data provided</li> </ul>

therapy [44]. Ventriculomegaly is considered an important prognostic factor for a poor neurological outcome [45].

Extracerebral changes consist mainly of fluid accumulations such as ascites as well as hepatomegaly and splenomegaly.

If infection occurred in the 3rd trimester, the only anomaly diagnosed on ultrasound in some cases in the above-described cohort was fetal growth restriction [13].

Fetal retinochoroiditis cannot be detected on ultrasound.

If an infected fetus shows no anomalies on ultrasound, the outcome in most cases will be favorable. In a study by Berrebi et al., only 1 of the 36 children with no anomalies on ultrasound imaging following primary infection in the 1st trimester presented with a severe form of congenital toxoplasmosis at one year of age. Seven children developed retinochoroiditis without relevant loss of vision and their neurological development was unremarkable [46].

When ultrasound findings are unremarkable or unclear, some international recommendations have suggested carrying out additional fetal magnetic resonance imaging [36, 47]. In the context of fetal infection with cytomegalovirus, an additional benefit of MRI in addition to diagnostic ultrasound was the detection of fetal CNS anomalies [48]. There is currently no specific evidence for infection with *Toxoplasma gondii*.

## 7 Transmission Prophylaxis and Therapy

Two medication options are currently used to treat toxoplasmosis in pregnancy.

Spiramycin is used as prophylaxis against transmission in cases with no signs of fetal infection and a combination of pyrimethamine, sulfadiazine and folinic acid is used in the period from 14 + 0 to 15 + 6 GW. Pyrimethamine and sulfadiazine should not be used in the 1st trimester of pregnancy because of their teratogenicity.

The only prospective randomized study on the prophylactic use of medication to prevent transmission from week 14 + 0 of gestation compared spiramycin with pyrimethamine/sulfadiazine and found a tendency to lower rates of transmission with pyrimethamine/sulfadiazine (did not reach statistical significance, ► **Fig. 6**). Cerebral anomalies only occurred in the spiramycin group [49], which could be explained by the fact that spiramycin does not cross the blood-brain barrier [50]. The study did not have a placebo arm.

A retrospective evaluation of the Austrian toxoplasmosis register found a 6-times lower rate of maternal-fetal transmission if the start of treatment followed the Austrian treatment regimen (► **Table 1**) within 4 weeks after maternal infection (► **Fig. 7**) [7].

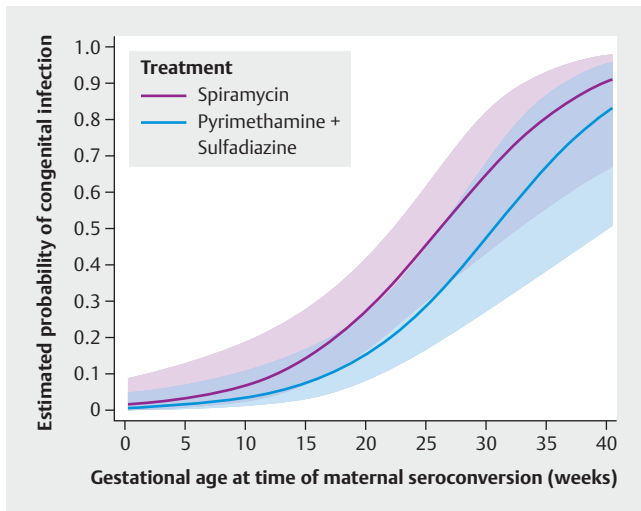
If signs of fetal infection are already detectable, a combination of pyrimethamine and sulfadiazine is used for transplacental therapy of the fetus in the 2nd and 3rd trimester of pregnancy. Pyrimethamine and sulfadiazine cross the placenta more easily and can also cross the blood-brain barrier.

If medication is used for transmission prophylaxis and therapy, its effect is limited to the folic acid/protein metabolism of fast-replicating tachyzoites; medication has very little effect against bradyzoite-containing cysts [1].

Clindamycin and cotrimoxazole have also been used in combination as an alternative to treat toxoplasmosis.

Several retrospective studies were able to show that different therapy regimens reduced the clinical manifestations of fetal toxoplasmosis, especially if treatment was initiated early (see also ► **Fig. 4**) [10, 14, 51, 52]. For ethical reasons, there are no prospective randomized, placebo-controlled studies.

After reviewing the above-mentioned studies and numerous other low evidence studies, some of which had methodological weaknesses, the German internet portal IGeL-Monitor which reviews individual health care services paid for by patients them-



► **Fig. 6** Probability of congenital infection depending on gestational age at maternal seroconversion and medication used for treatment (spiramycin vs. pyrimethamine and sulfadiazine) [49].

selves found only **weak indirect indications** that medication to treat toxoplasmosis in pregnancy offered an overall benefit in terms of reducing the transmission rate and number of clinical manifestations in infected children [53].

## 7.1 Spiramycin

### AGG STATEMENT (7)

Spiramycin is not teratogenic and can be used in the first trimester of pregnancy.

Spiramycin is a parasitostatic macrolide antibiotic which acts through inhibiting protein synthesis. It accumulates in the placenta although transplacental transfer is low. Rare contraindications include erythrocyte glucose-6-phosphate dehydrogenase deficiency (risk of acute hemolysis) and long QT syndrome.

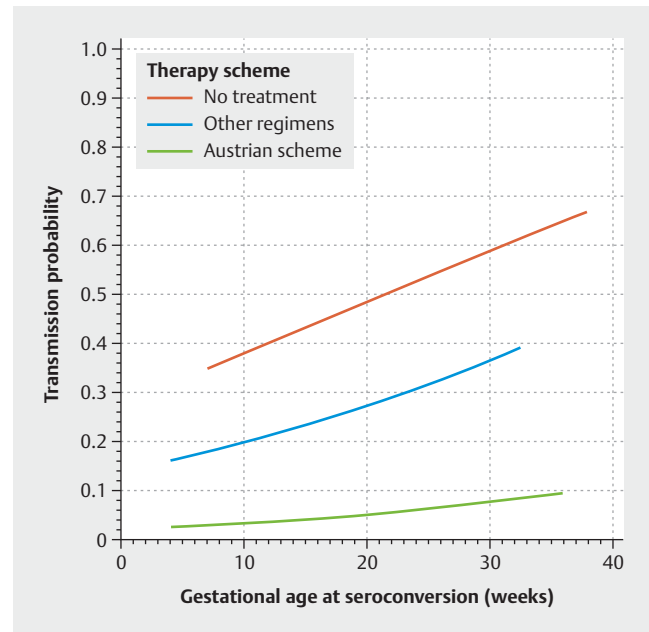
## 7.2 Pyrimethamine, sulfadiazine and folic acid

### AGG RECOMMENDATION (7)

Pyrimethamine and sulfadiazine are teratogenic and must not be used prior to the second trimester of pregnancy.

### AGG RECOMMENDATION (8)

Weekly blood counts (differential blood count) should be carried out during therapy and up to two weeks after therapy with pyrimethamine to exclude bone marrow depression (see the summary of product characteristics).



► **Fig. 7** Probability of congenital infection depending on maternal treatment with medication and age of gestation at the time of maternal infection (start of therapy within 4 weeks after maternal infection) [7].

### AGG RECOMMENDATION (9)

It is important to ensure that fluid intake is sufficient during therapy with pyrimethamine and sulfadiazine (> 2 liters/day or at least 1.2 liters urine/day) as this reduces the risk of crystalluria.

### AGG RECOMMENDATION (10)

Folic acid supplementation must be discontinued during therapy with pyrimethamine and sulfadiazine and replaced by folinic acid (calcium folinate) to prevent hematological toxicity.

Pyrimethamine and sulfadiazine act in synergy and interfere with the pathogen's folic acid synthesis by inhibiting dihydropteroate acid synthase. This therapy should not be administered in the first trimester of pregnancy because it is teratogenic.

Folinic acid (calcium folinate) must be taken during treatment with pyrimethamine to reduce the risk of bone marrow depression (anemia, leukopenia, thrombopenia). Supplementation with folic acid which usually taken during pregnancy should be discontinued to maintain the selectivity of pyrimethamine and sulfadiazine against the parasite.

Sulfadiazine should not be used alone. Potential side effects of sulfadiazine include hypersensitivity reactions of varying severity (usually late reaction); Stevens-Johnson syndrome and toxic epi-

dermal necrolysis have been reported in very rare cases. Sulfadiazine must not be used in cases with congenital erythrocyte glucose-6-phosphate dehydrogenase deficiency. The administration of sulfonamides in pregnancy can increase the risk of hyperbilirubinemia, especially in premature infants.

### 7.3 Clindamycin

Prospective randomized studies on the treatment of toxoplasmosis encephalitis in non-pregnant patients with HIV evaluated the use of clindamycin as an alternative to sulfadiazine in combination with pyrimethamine and folinic acid. The data indicate that the combination of clindamycin/pyrimethamine/folinic acid is tolerated better than the sulfadiazine/pyrimethamine/folinic acid combination and is just as effective in terms of the acute treatment of toxoplasmosis encephalitis, but recurrence is more common during maintenance therapy [54]. The only data available on treatment and transmission prophylaxis in pregnancy is from a mouse model in which monotherapy with clindamycin prevented transplacental transmission [55].

### 7.4 Cotrimoxazole

A recent retrospective study compared the efficacy of the combination therapy spiramycin/cotrimoxazole ( $n = 97$ ) with that of pyrimethamine/sulfadiazine ( $n = 8$ ) or monotherapy with spiramycin ( $n = 64$ ) [56]. No significant differences were found between the two combination regimens, but monotherapy with spiramycin resulted in significantly higher rates of maternal-fetal transmission. The small number of cases and the retrospective design of the study were insufficient to permit a general recommendation to be made about the use of cotrimoxazole in pregnancy.

## 7.5 Therapy regimen

### 7.5.1 Transmission prophylaxis

#### AGG RECOMMENDATION (11)

The following treatment regimen should be started as quickly as possible as a prophylaxis against transmission in cases with acute maternal *Toxoplasma gondii* infection in pregnancy without signs of fetal infection:

Up to week 14 + 6 of gestation:

- spiramycin (3.0 g = 9 MIU/day)

From week 15 + 0 of gestation (for at least 4 weeks):

a combination of

- pyrimethamine (50 mg on 1st day, 25 mg from 2nd day) +
- sulfadiazine (50 mg/kg/bw/day; 3 g/day up to < 80 kg/bw; 4 g/day for  $\geq 80$  kg/bw) +
- folinic acid (10–15 mg/day, folic acid supplementation must be discontinued)

Spiramycin 9 MIU/day is used as transmission prophylaxis in the first trimester. The recommendations in the international literature on whether and when prophylactic medication should be switched to pyrimethamine and sulfadiazine vary (► Table 1). The above-mentioned prospective randomized study by Mandelbrot et al. [49] indicates that pyrimethamine and sulfadiazine could be a more effective prophylaxis against transmission than spiramycin. The RKI recommends switching to pyrimethamine and sulfadiazine in week 15 + 0 of gestation [1].

Because of the lack of evidence from prospective randomized studies, the recommendations in the international literature regarding the duration of transmission prophylaxis with pyrimethamine and sulfadiazine when there are no indications of fetal infection (ultrasound anomalies or positive amniocentesis if AC is carried out) also vary considerably. In Austria, pyrimethamine and sulfadiazine are administered (if no amniocentesis was carried out) in alternation with spiramycin until the end of the pregnancy. In a French study by Mandelbrot et al., pyrimethamine and sulfadiazine were discontinued after 4 weeks if amniocentesis was negative; if no amniocentesis was carried out, pyrimethamine and sulfadiazine were discontinued at the earliest after 8 weeks. In Germany, the RKI recommends prophylactic therapy with pyrimethamine and sulfadiazine for at least 4 weeks (irrespective of whether AC was carried out or not). In a large German retrospective examination by Hotop et al. [10], pyrimethamine-sulfadiazine prophylaxis for maternal infection occurring after week 15 + 0 of gestation was extended to 6 weeks. Amniocentesis in this cohort was only carried out in 83 of 685 (12%) pregnant women. The adjusted rate of transmission in this cohort was lower (11% vs. 18–30%) compared to French studies [17, 18, 49] and comparable with the rate of transmission in Austria (13%) [7].

The percentage of children who were symptomatic at birth was higher in the German cohort compared to the French and the Austrian cohorts (33% vs. 13–20% and 17%, respectively), although comparisons between studies are limited because of the differences in the incidence of infections per trimester in the respective studies.

### 7.5.2 Therapy for suspected or confirmed fetal infection

#### AGG RECOMMENDATION (12)

Treatment with pyrimethamine, sulfadiazine and folinic acid should be continued until the birth if fetal infection is strongly suspected or confirmed.

If anomalies are detected on ultrasound which appear to indicate fetal infection with *Toxoplasma gondii* or the pathogen is confirmed in amniotic fluid, treatment with pyrimethamine, sulfadiazine and folinic acid should be continued until the birth.

### 7.5.3 Alternative treatment regimens

#### AGG RECOMMENDATION (13)

If sulfadiazine is not available or not tolerated, the following alternative treatment regimens may be used for transmission prophylaxis and therapy:

From 15 + 0 GW: a combination of

- spiramycin (3.0 g = 9 MIU/day) +
- cotrimoxazole (2 × 960 mg/day) +
- folic acid (10–15 mg/day, folic acid supplementation must be discontinued)

or

- cotrimoxazole (2 × 960 mg/day) +
- folic acid (10–15 mg/day, folic acid supplementation must be discontinued)

or

- pyrimethamine (50 mg/day) +
- clindamycin (3 × 600 mg/day) +
- folic acid (10–15 mg/day, folic acid supplementation must be discontinued)

It may be difficult to obtain sulfadiazine or procuring sulfadiazine may be delayed. To avoid a delay in treatment, the following alternative treatment regimens may be used: a combination of **spiramycin, cotrimoxazole and folic acid** (adapted from Buonsenso et al. [56]; in the original publication treatment with spiramycin started before 13 + 0 GW and was continued together with cotrimoxazole/folic acid from 13 + 0 GW up until one week prior to delivery of the fetus) or **cotrimoxazole/folic acid** (adapted from a French expert opinion [47]; the publication reported that cotrimoxazole/folic acid was administered as transmission prophylaxis from 14 + 0 GW and was continued until the birth in cases with fetal infection or late maternal infection from 33 + 0 GW; if maternal infection occurred before 33 + 0 GW and amniocentesis was negative, this was replaced by spiramycin until the birth) or **pyrimethamine, clindamycin and folic acid** (expert opinion, analogous to the treatment of toxoplasmosis encephalitis in cases with HIV [57]; from 15 + 0 GW for at least 4 weeks).

The data on the efficacy of these three therapy regimens during pregnancy is very limited and insufficient. These combinations should therefore not be administered as first-choice regimens but only when sulfadiazine is not available and after the patient has been informed about the individual approaches.

### 7.6 Best time to initiate medical therapy

#### AGG RECOMMENDATION (14)

If medical therapy to treat toxoplasmosis in pregnancy is indicated, treatment must be started immediately.

Different studies have stated that the time when drug treatment is initiated has an impact on maternal-fetal rates of transmission

and/or the percentage of symptomatic fetuses. Some studies reported a significant benefit if treatment was started 3 [15] (or 4 [10, 52] or 8 [14]) weeks after maternal infection compared to 4 [52] or 8 [10, 14, 15] weeks after maternal infection.

### 7.7 Medication levels

#### AGG STATEMENT (8)

The levels of sulfadiazine and pyrimethamine in maternal serum vary considerably. A serology test two weeks after starting medical therapy may be useful.

In a retrospective case-control study of 89 women with primary toxoplasma infection in pregnancy and 17 non-pregnant women with acute ocular toxoplasmosis, 26% of the pregnant women had sulfadiazine levels of less than 20 mg/l and 17% of cases additionally had pyrimethamine levels of less than 700 µg/l [58]. As studies are lacking, it is still not clear which therapeutic levels should be aimed for in pregnant women. It is assumed that the pyrimethamine level in fetal blood could be 1/3 of the level in maternal blood [59]. In non-pregnant patients, therapeutic levels of 50–150 mg/l for sulfadiazine and 700–1300 µg/l for pyrimethamine have been reported for the combination therapy of sulfadiazine and pyrimethamine [58].

## 8 Prevention

#### AGG RECOMMENDATION (15)

Seronegative pregnant women must be advised about the hygiene measures they should follow as prophylaxis against exposure to *Toxoplasma gondii*.

Seronegative pregnant women can reduce their risk of *Toxoplasma gondii* infection by exposure prophylaxis [60]. Preventive measures include [1, 8]:

- do not eat raw, undercooked, or frozen meat products (e.g., ground meat or briefly matured raw sausages),
- wash raw vegetables and fruits thoroughly before consumption,
- wash hands before eating,
- wash hands thoroughly after preparing raw meat, working in the garden or in the fields or carrying out excavation works as well as after visiting sand play areas,
- if there is a cat at home in the vicinity of the pregnant woman, the cat should only be given canned food and/or dry cat food to eat. The cat's litter tray should be cleaned every day with hot water by a non-pregnant person, especially if the cat is free to go outside.

The pregnant woman must be advised about this as part of standard prenatal care in accordance with German maternity guidelines [61].

## 9 Screening

### AGG RECOMMENDATION (16)

Non-immune pregnant women must be informed about the risks of infection with *Toxoplasma gondii* and the option to be screened for toxoplasmosis.

### AGG RECOMMENDATION (17)

If a pregnant woman wishes to be screened for toxoplasmosis, her antibody status (toxoplasma IgG and IgM) should be evaluated as early as possible during pregnancy and seronegative pregnant women should be followed up regularly every 4–8 weeks until the end of the pregnancy to exclude seroconversion.

Screening for toxoplasmosis in pregnancy is already standard procedure in different European countries (since 1974 in Austria, since 1992 in France, since 1998 in Italy, and since 1995 in Slovenia). Numerous studies have shown that the introduction of systematic screening programs resulted in the simultaneous reduction of maternal-fetal transmissions and fetal injury and is cost effective [62]. The screening intervals proposed in various countries for seronegative pregnant women differ (e.g., once a month in France and every 8 weeks in Austria). In Switzerland, the decision was taken in 2008 not to screen for toxoplasmosis because of the unclear evidence, the low incidence of congenital toxoplasmosis and possible negative consequences (e.g., the upset caused to the pregnant woman if results are false-positive, complications during amniocentesis) [63].

In Germany, serology screening for *Toxoplasma gondii* is currently not funded by statutory health insurance companies and is therefore only offered to persons with statutory health insurance as an individual health service paid for by the patient. If there is a reasonable suspicion of infection (e.g., relevant exposure, symptoms, ultrasound anomalies), testing is considered a curative procedure and reimbursed accordingly.

Pregnant women should be informed about this option but also told that the information obtained during screening is unclear [53]. If a pregnant woman wishes to be screened for toxoplasmosis, her antibody status (toxoplasmosis IgG and IgM) should be evaluated as early as possible in pregnancy and seronegative pregnant women should be followed up every 4–8 weeks until the end of the pregnancy to exclude seroconversion. Regular follow-up tests can ensure that if therapy does become necessary, it can be initiated in good time (see 6.5).

## 10 Delivery and Breastfeeding

### AGG RECOMMENDATION (18)

Delivery of infants in cases with maternal-fetal *Toxoplasma gondii* infection should be based on general obstetric criteria.

### AGG STATEMENT (9)

Transmission of *Toxoplasma gondii* via breast milk has not been detected in humans.

In a study of 10 pregnant women with maternal *Toxoplasma gondii* infection, fetal infection occurred in 9 out of 10 cases despite prompt delivery of the infant by induction of labor or caesarean section (on average, 3 weeks after maternal infection). The authors concluded that even in cases with late maternal primary infection, premature delivery of infants should not be encouraged as early delivery does not definitively exclude maternal-fetal transmission [64].

Information about maternal-fetal diagnostic examinations and therapy should be passed to pediatric colleagues peripartum to allow them to plan the requisite diagnostic examinations and therapy of the neonate.

Breastfeeding is possible even in cases of maternal infection with *Toxoplasma gondii* as there are no documented cases of transmission of *Toxoplasma gondii* via breast milk in humans.

## 11 Treatment of Neonates After Delivery

A combination of pyrimethamine, sulfadiazine and folinic acid is the first-choice treatment regimen for infected neonates. Duration of treatment depends on the symptoms displayed by the neonate (usually 3–12 months) [1].

### Conflict of Interest

The authors declare that they have no conflict of interest.

### References

- [1] Robert Koch-Institut. RKI-Ratgeber Toxoplasmose. *Epidemiol Bull* 2018; 42: 451–460
- [2] Wilking H, Thamm M, Stark K et al. Prevalence, incidence estimations, and risk factors of *Toxoplasma gondii* infection in Germany: a representative, cross-sectional, serological study. *Sci Rep* 2016; 6: 22551. doi:10.1038/srep22551
- [3] Pleyer U, Groß U, Schlüter D et al. Toxoplasmosis in Germany: Epidemiology, Diagnosis, Risk Factors, and Treatment. *Dtsch Arztebl Int* 2019; 116: 435–444. doi:10.3238/arztebl.2019.0435
- [4] Montoya JG, Liesenfeld O. Toxoplasmosis. *Lancet* 2004; 363: 1965–1976. doi:10.1016/S0140-6736(04)16412-X

- [5] Beringer T. [Is diagnosis of toxoplasmosis within the scope of prenatal care meaningful?]. *Geburtshilfe Frauenheilkd* 1992; 52: 740–741. doi:10.1055/s-2007-1023804
- [6] Krings A, Jacob J, Seeber F et al. Estimates of Toxoplasmosis Incidence Based on Healthcare Claims Data, Germany, 2011–2016. *Emerg Infect Dis* 2021; 27: 2097–2106. doi:10.3201/eid2708.203740
- [7] Prusa A-R, Kasper DC, Pollak A et al. The Austrian Toxoplasmosis Register, 1992–2008. *Clin Infect Dis* 2015; 60: e4–e10. doi:10.1093/cid/ciu724
- [8] Paquet C, Yudin MH. No. 285-Toxoplasmosis in Pregnancy: Prevention, Screening, and Treatment. *J Obstet Gynaecol Can* 2018; 40: e687–e693. doi:10.1016/j.jogc.2018.05.036
- [9] Leruez-Ville M, Benoist G, Ville Y. Fetal Infections: Clinical Management. In: Kilby MD, Johnson A, Oepkes D, eds. *Fetal Therapy*. Cambridge University Press; 2019: 224–247. doi:10.1017/9781108564434.023
- [10] Hotop A, Hlobil H, Gross U. Efficacy of rapid treatment initiation following primary *Toxoplasma gondii* infection during pregnancy. *Clin Infect Dis* 2012; 54: 1545–1552. doi:10.1093/cid/cis234
- [11] Dubey JP, Murata FHA, Cerqueira-Cézar CK et al. Congenital toxoplasmosis in humans: an update of worldwide rate of congenital infections. *Parasitology* 2021; 148: 1406–1416. doi:10.1017/S0031182021001013
- [12] Picone O, Fuchs F, Benoist G et al. Toxoplasmosis screening during pregnancy in France: Opinion of an expert panel for the CNGOF. *J Gynecol Obstet Hum Reprod* 2020; 49: 101814. doi:10.1016/j.jogoh.2020.101814
- [13] Codaccioni C, Picone O, Lambert V et al. Ultrasound features of fetal toxoplasmosis: A contemporary multicenter survey in 88 fetuses. *Prenat Diagn* 2020; 40: 1741–1752. doi:10.1002/pd.5756
- [14] Kieffer F, Wallon M, Garcia P et al. Risk factors for retinochoroiditis during the first 2 years of life in infants with treated congenital toxoplasmosis. *Pediatr Infect Dis J* 2008; 27: 27–32. doi:10.1097/INF.0b013e318134286d
- [15] SYROCOT (Systematic Review on Congenital Toxoplasmosis) study group, Thiébaud R, Leproust S et al. Effectiveness of prenatal treatment for congenital toxoplasmosis: a meta-analysis of individual patients' data. *Lancet* 2007; 369: 115–122. doi:10.1016/S0140-6736(07)60072-5
- [16] Berrébi A, Assouline C, Bessières M-H et al. Long-term outcome of children with congenital toxoplasmosis. *Am J Obstet Gynecol* 2010; 203: 552.e1–552.e6. doi:10.1016/j.ajog.2010.06.002
- [17] Dunn D, Wallon M, Peyron F et al. Mother-to-child transmission of toxoplasmosis: risk estimates for clinical counselling. *Lancet* 1999; 353: 1829–1833. doi:10.1016/S0140-6736(98)08220-8
- [18] Wallon M, Peyron F, Cornu C et al. Congenital toxoplasma infection: monthly prenatal screening decreases transmission rate and improves clinical outcome at age 3 years. *Clin Infect Dis* 2013; 56: 1223–1231. doi:10.1093/cid/cit032
- [19] Gilbert RE, Freeman K, Lago EG et al. Ocular sequelae of congenital toxoplasmosis in Brazil compared with Europe. *PLoS Negl Trop Dis* 2008; 2: e277. doi:10.1371/journal.pntd.0000277
- [20] Tan HK, Schmidt D, Stanford M et al. Risk of visual impairment in children with congenital toxoplasmic retinochoroiditis. *Am J Ophthalmol* 2007; 144: 648–653. doi:10.1016/j.ajo.2007.07.013
- [21] Wallon M, Kodjikian L, Binquet C et al. Long-term ocular prognosis in 327 children with congenital toxoplasmosis. *Pediatrics* 2004; 113: 1567–1572. doi:10.1542/peds.113.6.1567
- [22] Peyron F, Garweg JG, Wallon M et al. Long-term impact of treated congenital toxoplasmosis on quality of life and visual performance. *Pediatr Infect Dis J* 2011; 30: 597–600. doi:10.1097/INF.0b013e31820bb5f3
- [23] Roizen N, Kasza K, Karrison T et al. Impact of visual impairment on measures of cognitive function for children with congenital toxoplasmosis: implications for compensatory intervention strategies. *Pediatrics* 2006; 118: e379–e390. doi:10.1542/peds.2005-1530
- [24] Eichenwald HF. A study of congenital toxoplasmosis, with particular emphasis on clinical manifestations, sequelae and therapy. In: Siim JC, ed. *Human toxoplasmosis*. Copenhagen: Munksgaard; 1960: 41–49
- [25] Hutson SL, Wheeler KM, McLone D et al. Patterns of Hydrocephalus Caused by Congenital *Toxoplasma gondii* Infection Associate With Parasite Genetics. *Clin Infect Dis* 2015; 61: 1831–1834. doi:10.1093/cid/civ720
- [26] McLone D, Frim D, Penn R et al. Outcomes of hydrocephalus secondary to congenital toxoplasmosis. *J Neurosurg Pediatr* 2019. doi:10.3171/2019.6.PEDS18684
- [27] Anand R, Jones CW, Ricks JH et al. Acute primary toxoplasmosis in travelers returning from endemic countries. *J Travel Med* 2012; 19: 57–60. doi:10.1111/j.1708-8305.2011.00564.x
- [28] Rudzinski M, Khoury M, Couto C et al. Reactivation of Ocular Toxoplasmosis in Non-Hispanic Persons, Misiones Province, Argentina. *Emerg Infect Dis* 2016; 22: 912–913. doi:10.3201/eid2205.150025
- [29] Montoya JG, Remington JS. Management of *Toxoplasma gondii* infection during pregnancy. *Clin Infect Dis* 2008; 47: 554–566. doi:10.1086/590149
- [30] Fricker-Hidalgo H, Cimon B, Chemla C et al. *Toxoplasma* seroconversion with negative or transient immunoglobulin M in pregnant women: myth or reality? A French multicenter retrospective study. *J Clin Microbiol* 2013; 51: 2103–2111. doi:10.1128/JCM.00169-13
- [31] Elbez-Rubinstein A, Ajzenberg D, Dardé M-L et al. Congenital toxoplasmosis and reinfection during pregnancy: case report, strain characterization, experimental model of reinfection, and review. *J Infect Dis* 2009; 199: 280–285. doi:10.1086/595793
- [32] Low incidence of congenital toxoplasmosis in children born to women infected with human immunodeficiency virus. European Collaborative Study and Research Network on Congenital Toxoplasmosis. *Eur J Obstet Gynecol Reprod Biol* 1996; 68: 93–96. doi:10.1016/0301-2115(96)02497-9
- [33] Liesenfeld O, Montoya JG, Tathineni NJ et al. Confirmatory serologic testing for acute toxoplasmosis and rate of induced abortions among women reported to have positive *Toxoplasma* immunoglobulin M antibody titers. *Am J Obstet Gynecol* 2001; 184: 140–145. doi:10.1067/mob.2001.108341
- [34] Maldonado YA, Read JS; COMMITTEE ON INFECTIOUS DISEASES. Diagnosis, Treatment, and Prevention of Congenital Toxoplasmosis in the United States. *Pediatrics* 2017; 139: e20163860. doi:10.1542/peds.2016-3860
- [35] Peyron F, L'ollivier C, Mandelbrot L et al. Maternal and Congenital Toxoplasmosis: Diagnosis and Treatment Recommendations of a French Multidisciplinary Working Group. *Pathogens* 2019; 8: 24. doi:10.3390/pathogens8010024
- [36] Khalil A, Sotiriadis A, Chaoui R et al. ISUOG Practice Guidelines: role of ultrasound in congenital infection. *Ultrasound Obstet Gynecol* 2020; 56: 128–151. doi:10.1002/uog.21991
- [37] de Oliveira Azevedo CT, do Brasil PEAA, Guida L et al. Performance of Polymerase Chain Reaction Analysis of the Amniotic Fluid of Pregnant Women for Diagnosis of Congenital Toxoplasmosis: A Systematic Review and Meta-Analysis. *PLoS One* 2016; 11: e0149938. doi:10.1371/journal.pone.0149938
- [38] Sterkers Y, Pratlong F, Albaba S et al. Novel Interpretation of Molecular Diagnosis of Congenital Toxoplasmosis According to Gestational Age at the Time of Maternal Infection. *J Clin Microbiol* 2012; 50: 3944–3951. doi:10.1128/JCM.00918-12
- [39] Wallon M, Franck J, Thulliez P et al. Accuracy of real-time polymerase chain reaction for *Toxoplasma gondii* in amniotic fluid. *Obstet Gynecol* 2010; 115: 727–733. doi:10.1097/AOG.0b013e3181d57b09
- [40] Rabilloud M, Wallon M, Peyron F. In utero and at birth diagnosis of congenital toxoplasmosis: use of likelihood ratios for clinical management. *Pediatr Infect Dis J* 2010; 29: 421–425. doi:10.1097/INF.0b013e3181c80493
- [41] Thalib L, Gras L, Romand S et al. Prediction of congenital toxoplasmosis by polymerase chain reaction analysis of amniotic fluid. *BJOG Int J Obstet Gynaecol* 2005; 112: 567–574. doi:10.1111/j.1471-0528.2005.00486.x

- [42] Prusa A-R, Kasper DC, Pollak A et al. Amniocentesis for the detection of congenital toxoplasmosis: results from the nationwide Austrian prenatal screening program. *Clin Microbiol Infect* 2015; 21: 191.e1–191.e8. doi:10.1016/j.cmi.2014.09.018
- [43] Salomon LJ, Sotiriadis A, Wulff CB et al. Risk of miscarriage following amniocentesis or chorionic villus sampling: systematic review of literature and updated meta-analysis. *Ultrasound Obstet Gynecol* 2019; 54: 442–451. doi:10.1002/uog.20353
- [44] Patel DV, Holfels EM, Vogel NP et al. Resolution of intracranial calcifications in infants with treated congenital toxoplasmosis. *Radiology* 1996; 199: 433–440. doi:10.1148/radiology.199.2.8668790
- [45] Blondiaux E, Garel C. Fetal cerebral imaging – ultrasound vs. MRI: an update. *Acta Radiol* 2013; 54: 1046–1054. doi:10.1258/ar.2012.120428
- [46] Berrebi A, Bardou M, Bessieres M-H et al. Outcome for children infected with congenital toxoplasmosis in the first trimester and with normal ultrasound findings: a study of 36 cases. *Eur J Obstet Gynecol Reprod Biol* 2007; 135: 53–57. doi:10.1016/j.ejogrb.2006.11.002
- [47] Mandelbrot L, Kieffer F, Wallon M et al. Toxoplasmose pendant la grossesse: proposition actuelle de prise en charge pratique. *Gynecol Obstet Fertil Senol* 2021; 49: 782–791. doi:10.1016/j.gofs.2021.03.003
- [48] Di Mascio D, Rizzo G, Khalil A et al. Role of fetal magnetic resonance imaging in fetuses with congenital cytomegalovirus infection: multicenter study. *Ultrasound Obstet Gynecol* 2023; 61: 67–73. doi:10.1002/uog.26054
- [49] Mandelbrot L, Kieffer F, Sitta R et al. Prenatal therapy with pyrimethamine + sulfadiazine vs. spiramycin to reduce placental transmission of toxoplasmosis: a multicenter, randomized trial. *Am J Obstet Gynecol* 2018; 219: 386.e1–386.e9. doi:10.1016/j.ajog.2018.05.031
- [50] Schoondermark-van de Ven EM, Melchers WJ, Galama JM et al. Prenatal diagnosis and treatment of congenital *Toxoplasma gondii* infections: an experimental study in rhesus monkeys. *Eur J Obstet Gynecol Reprod Biol* 1997; 74: 183–188. doi:10.1016/s0301-2115(97)00119-x
- [51] Cortina-Borja M, Tan HK, Wallon M et al. Prenatal Treatment for Serious Neurological Sequelae of Congenital Toxoplasmosis: An Observational Prospective Cohort Study. *PLoS Med* 2010; 7: 11
- [52] Gras L, Wallon M, Pollak A et al.; European Multicenter Study on Congenital Toxoplasmosis. Association between prenatal treatment and clinical manifestations of congenital toxoplasmosis in infancy: a cohort study in 13 European centres. *Acta Paediatr* 2005; 94: 1721–1731. doi:10.1111/j.1651-2227.2005.tb01844.x
- [53] Schuster S, Janatzek S, Chittka L. IGeLMonitor- Evidenz ausführlich – Toxoplasmose-Test in der Schwangerschaft. Accessed September 10, 2022 at: [https://www.igel-monitor.de/fileadmin/user\\_upload/Toxoplasmosestest\\_Schwangerschaft\\_Evidenz\\_ausfuehrlich.pdf](https://www.igel-monitor.de/fileadmin/user_upload/Toxoplasmosestest_Schwangerschaft_Evidenz_ausfuehrlich.pdf)
- [54] Katlama C, De Wit S, O'Doherty E et al. Pyrimethamine-clindamycin vs. pyrimethamine-sulfadiazine as acute and long-term therapy for toxoplasmic encephalitis in patients with AIDS. *Clin Infect Dis* 1996; 22: 268–275. doi:10.1093/clinids/22.2.268
- [55] Araujo FG, Remington JS. Effect of Clindamycin on Acute and Chronic Toxoplasmosis in Mice. *Antimicrob Agents Chemother* 1974; 5: 647–651. doi:10.1128/AAC.5.6.647
- [56] Buonsenso D, Pata D, Turriziani Colonna A et al. Spyramicine and Trimethoprim-Sulfamethoxazole Combination to Prevent Mother-To-Fetus Transmission of *Toxoplasma gondii* Infection in Pregnant Women: A 28-Years Single-center Experience. *Pediatr Infect Dis J* 2022; 41: e223–e227. doi:10.1097/INF.0000000000003469
- [57] EACSociety. EACS Guidelines. Accessed September 17, 2022 at: <https://www.eacsociety.org/guidelines/eacs-guidelines/>
- [58] Reiter-Owona I, Hlobil H, Enders M et al. Sulfadiazine plasma concentrations in women with pregnancy-acquired compared to ocular toxoplasmosis under pyrimethamine and sulfadiazine therapy: a case-control study. *Eur J Med Res* 2020; 25: 59. doi:10.1186/s40001-020-00458-7
- [59] Peytavin G, Leng JJ, Forestier F et al. Placental transfer of pyrimethamine studied in an ex vivo placental perfusion model. *Biol Neonate* 2000; 78: 83–85. doi:10.1159/000014254
- [60] Wehbe K, Pencole L, Lhuire M et al. Hygiene measures as primary prevention of toxoplasmosis during pregnancy: A systematic review. *J Gynecol Obstet Hum Reprod* 2022; 51: 102300. doi:10.1016/j.jogoh.2021.102300
- [61] Gemeinsamer Bundesausschuss. Mutterschafts-Richtlinien. 2021. Accessed April 18, 2023 at: [https://www.g-ba.de/downloads/62-492-2676/Mu-RL\\_2021-09-16\\_iK-2022-01-01.pdf](https://www.g-ba.de/downloads/62-492-2676/Mu-RL_2021-09-16_iK-2022-01-01.pdf)
- [62] Prusa A-R, Kasper DC, Sawers L et al. Congenital toxoplasmosis in Austria: Prenatal screening for prevention is cost-saving. *PLoS Negl Trop Dis* 2017; 11: e0005648. doi:10.1371/journal.pntd.0005648
- [63] SGGG. Expertenbrief 31 – Verzicht auf das Toxoplasmose-Screening in der Schwangerschaft – kurze zusammenfassende Begründung. 2010. Accessed September 17, 2022 at: [https://www.sggg.ch/fileadmin/user\\_upload/PDF/31\\_Toxoplasmose-Screening\\_2010.pdf](https://www.sggg.ch/fileadmin/user_upload/PDF/31_Toxoplasmose-Screening_2010.pdf)
- [64] Wallon M, Kieffer F, Huissoud C et al. Cesarean delivery or induction of labor does not prevent vertical transmission of toxoplasmosis in late pregnancy. *Int J Gynaecol Obstet* 2015; 129: 176–177. doi:10.1016/j.ijgo.2014.10.026
- [65] Arbeitsgruppe Infektiologie der Österreichischen Gesellschaft für Kinderheilkunde. Österreichische Richtlinie für das Toxoplasmose-Screening in der Schwangerschaft und frühen Kindheit. 2013. Accessed January 21, 2021 at: [https://www.oeghmp.at/media/richtlinie\\_toxoplasmose-screening.pdf](https://www.oeghmp.at/media/richtlinie_toxoplasmose-screening.pdf)
- [66] Wichtige humane Parasitosen: Toxoplasmose. *Z Gastroenterol* 2020; 58: 742–746. doi:10.1055/a-1120-1338