

A loop cutter is an ideal gripper for endoscopic removal of press-through-package sheets

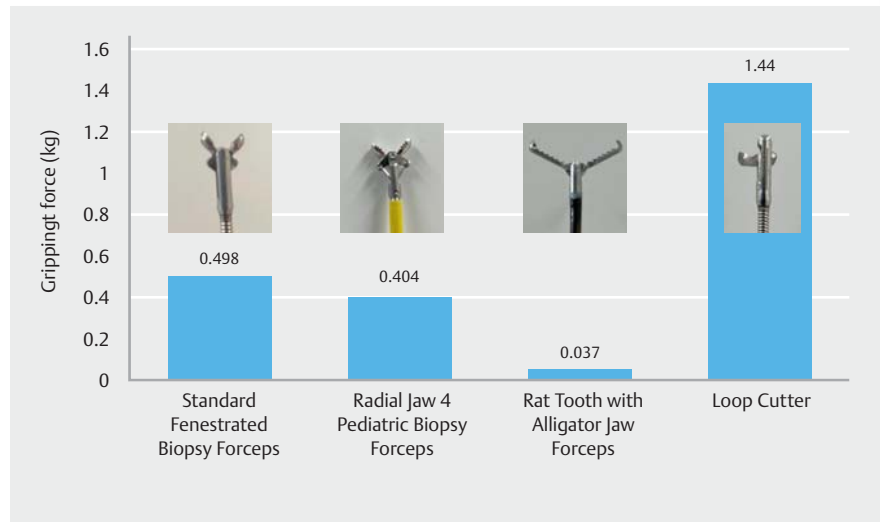


► **Fig. 1** Press-through-package (PTP) sheets have sharp edges.

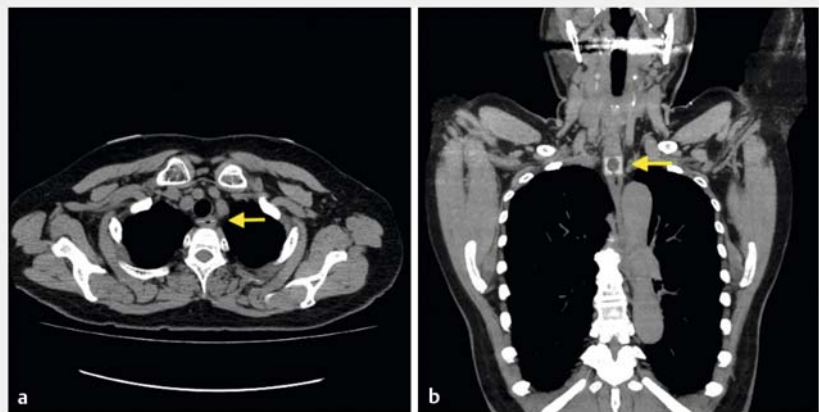


► **Fig. 2** A PTP sheet was attached to the tip of the spring scale to evaluate the gripping force of various devices.

A press-through package (PTP) sheet is sometimes accidentally swallowed [1]. PTP sheets have sharp edges (► **Fig. 1**) and may cause mucosal damage and/or perforation to the gastrointestinal tract [2, 3]. Thus, ingested PTP sheets should



► **Fig. 3** Comparison of the gripping force of various devices.

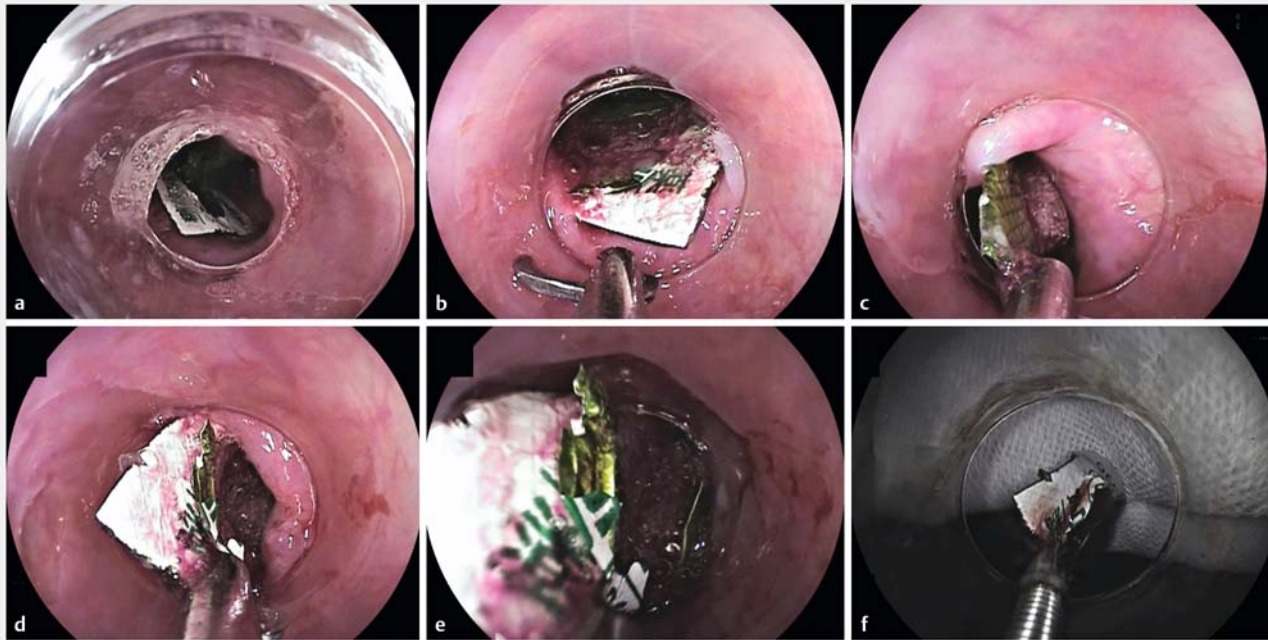


► **Fig. 4** A 70-year-old woman presented to our hospital complaining of a sore throat after accidentally ingesting PTP sheets. **a, b** A computed tomography scan showed the PTP sheets located in the esophagus.

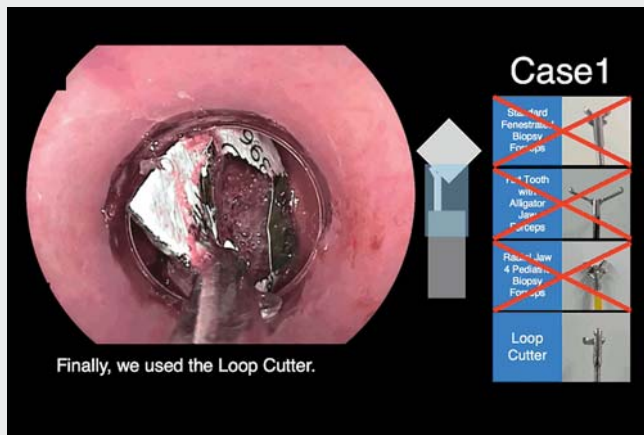
be removed endoscopically as soon as possible. Several methods have been reported using hoods and covers to prevent mucosal damage during removal [4, 5]. However, a firm grip on the PTP sheet is necessary for successful removal. Grasping forceps or a snare are commonly used as grasping devices but can often fail because the PTP is slippery with saliva

and the working space is insufficient for snaring. To address this, we used a Loop Cutter (FS-5L-1; Olympus, Tokyo, Japan), whose teeth can penetrate the PTP plastic sheet to secure a firm grip. The Loop Cutter's strong grip allows the PTP to be easily removed.

To evaluate the gripping force of various devices, we attached a PTP sheet to the



► Fig. 5 a The ingested PTP sheet was located in the upper esophagus. b–e We used the Loop Cutter. Its teeth can penetrate the PTP plastic sheet, securing a firm grip. Because the gripping force is strong, the PTP can be easily removed. f The PTP sheet was detached easily from the Loop Cutter.



► Video 1 A Loop Cutter is an ideal gripper for endoscopic removal of press-through packages.

large amount of food residue. The PTP sheets were successfully and safely removed endoscopically in both cases by grasping the PTP sheet using a Loop Cutter (► Fig. 5, ► Video 1).

Endoscopy_UCTN_Code_TTT_1AO_2AL

Acknowledgement

The authors thank Mizuki Kai for editing assistance.

Competing interests

The authors declare that they have no conflict of interest.

The authors

Yuji Ino , Masafumi Kitamura , Yoshie Nomoto , Chihiro Iwashita, Yoshimasa Miura, Tomonori Yano , Hironori Yamamoto
Department of Medicine, Division of Gastroenterology, Jichi Medical University, Shimotsuke, Japan

tip of a spring scale (► Fig. 2). The gripping force was measured until the PTP was detached from the grasping device. The mean gripping force of each thirty times was 498 g in Standard Fenestrated Biopsy Forceps (FB-25K-1, Olympus), 404 g in the Radial Jaw 4 Pediatric Biopsy Forceps (M00513440; Boston Scientific, Marlborough, Massachusetts, USA), 37 g in the Rat Tooth with Alligator Jaw Grasp-

ing Forceps (FG-47L-1; Olympus), and 1440 g in the Loop Cutter (► Fig. 3). A 70-year-old woman presented to our hospital complaining of a sore throat after accidentally ingesting PTP sheets. A computed tomography (CT) scan showed the PTP location in the esophagus (► Fig. 4). The second case was a 63-year-old man with dementia. PTP was found in the stomach along with a

Corresponding author

Tomonori Yano, MD

Jichi Medical University, 3311-1 Yakushiji,
Shimotsuke, Tochigi, 329-0498, Japan
tomonori@jichi.ac.jp

References

- [1] Limpas Kamiya KJ, Hosoe N, Takabayashi K et al. Endoscopic removal of foreign bodies: A retrospective study in Japan. *World J Gastrointest Endosc* 2020; 12: 33–41
- [2] Tamura T, Okamoto H, Suzuki T et al. Evaluation of the extent of damage to the esophageal wall caused by press-through package ingestion. *PeerJ* 2019; 7: e6763
- [3] Sudo T, Sueyoshi S, Fujita H et al. Esophageal perforation caused by a press through pack. *Dis Esophagus* 2003; 16: 169–172
- [4] Seo YS, Park JJ, Kim JH et al. Removal of press-through-packs impacted in the upper esophagus using an overtube. *World J Gastroenterol* 2006; 12: 5909–5912

- [5] Tateno Y, Suzuki R. Cut endotracheal tube for endoscopic removal of an ingested push-through pack. *World J Gastrointest Endosc* 2016; 8: 472–476

Bibliography

Endoscopy 2023; 55: E889–E891

DOI 10.1055/a-2113-9265

ISSN 0013-726X

© 2023. The Author(s).

This is an open access article published by Thieme under the terms of the Creative Commons Attribution License, permitting unrestricted use, distribution, and reproduction so long as the original work is properly cited.

(<https://creativecommons.org/licenses/by/4.0/>)

Georg Thieme Verlag KG, Rüdigerstraße 14,
70469 Stuttgart, Germany



ENDOSCOPY E-VIDEOS

<https://eref.thieme.de/e-videos>



E-Videos is an open access online section of the journal *Endoscopy*, reporting on interesting cases and new techniques in gastroenterological endoscopy. All papers include a high-quality video and are published with a Creative Commons CC-BY license. *Endoscopy E-Videos* qualify for HINARI discounts and waivers and eligibility is automatically checked during the submission process. We grant 100% waivers to articles whose corresponding authors are based in Group A countries and 50% waivers to those who are based in Group B countries as classified by Research4Life (see: <https://www.research4life.org/access/eligibility/>).

This section has its own submission website at <https://mc.manuscriptcentral.com/e-videos>