

The Management of Posttraumatic Nasal Deformities

W. Katherine Kao, MD¹ Tang Ho, MD, MSc¹

¹Department of Otolaryngology, University of Texas Health Science Center at Houston, Houston, Texas

Address for correspondence Tang Ho, MD, MSc, University of Texas Health Science Center at Houston, 6400 Fannin Street, MSB 5.036, Houston, TX 77030 (e-mail: Tang.ho@uth.tmc.edu).

Facial Plast Surg 2023;39:630–637.

Abstract

Nasal bone fractures are the most common fractures of the facial skeleton and are often accompanied by bony, cartilaginous, and soft tissue injuries. These injuries are often complex, and when untreated or inadequately treated, can lead to posttraumatic nasal deformity. The most common deformities are the crooked nose and the saddle nose. Both deformities may result in significant cosmetic and functional concerns. The treatment of these deformities can be complex, requiring careful evaluation of the nose and thoughtful planning to correct the cosmetic deformity and restore functional integrity. The rhinoplasty surgeon will benefit from having a large repertoire of techniques to achieve these repairs. In this article, we discuss the options and concepts for the management of nasal bone fractures as well as complicated posttraumatic nasal deformity. Level of evidence is not available.

Keywords

- ▶ posttraumatic nasal deformity
- ▶ rhinoplasty
- ▶ nasal bone fracture

Nasal bone fractures are the most common facial fractures and account for 40 to 50% of bony injuries to the facial skeleton.^{1–3} As the most prominent anterior feature of the face, the nose is easily subject to trauma. Nasal bone injuries are often accompanied by cartilaginous and soft tissue injuries as well. While often thought of as minor injuries, nasal bone fractures can have lingering long-term effects. In fact, the incidence of posttraumatic nasal deformity varies from 14 to 50%,⁴ and posttraumatic nasal deformities can often be very challenging to address and resolve. In this article, we discuss the tools and techniques available for acute and delayed management of nasal bone fractures and posttraumatic nasal deformities.

Anatomy

The nose is the most prominent anterior feature of the face. The nose contains a bony vault, upper cartilaginous vault, and lower cartilaginous vault. The bony vault is composed of paired nasal bones, the ascending process of the maxilla and the nasal process of the frontal bone.⁵ The nasal bones articulate with the upper lateral cartilages which form the upper cartilaginous vault. This vault contains the internal

nasal valve which is bordered by the nasal septum, the upper lateral cartilage, the head of the inferior turbinate, and the nasal floor. The upper lateral cartilages overlap the nasal bone by 6 to 8 mm providing a strong support between the bony and cartilaginous portions of the nose. Caudally, the upper lateral cartilages articulate with the cephalic edge of the lower lateral cartilage in the scroll region⁵ (see ▶ **Fig. 1**). The septum acts as a “tent pole” to support the nasal tip and nasal dorsum and becomes thicker posteriorly, basally and caudally where it attaches to the bony framework of the nose.⁶

Overlying the cartilaginous and bony support of the nose is the skin soft tissue envelope of the nose which has distinct tissue layers. These are the epidermis, dermis, subcutaneous fat, muscle and fascia, areolar tissue, and periosteum or perichondrium. The skin overlying the nose can have variable type, texture, and sebaceous content. This is important for the rhinoplasty surgeon to consider as thick skin requires more aggressive modification of the bony/cartilaginous framework of the nose to achieve desired contours of the nose, while thin skin will show off the slightest imperfections of contour, asymmetry, and underlying graft material.^{7–15}

accepted manuscript online
August 11, 2023
article published online
September 14, 2023

Issue Theme Functional
Rhinoplasty; Guest Editors:
Krista L. Olson, MD, and Sunthosh
Kumar Sivam, MD

© 2023, Thieme. All rights reserved.
Thieme Medical Publishers, Inc.,
333 Seventh Avenue, 18th Floor,
New York, NY 10001, USA

DOI <https://doi.org/10.1055/a-2152-8670>.
ISSN 0736-6825.

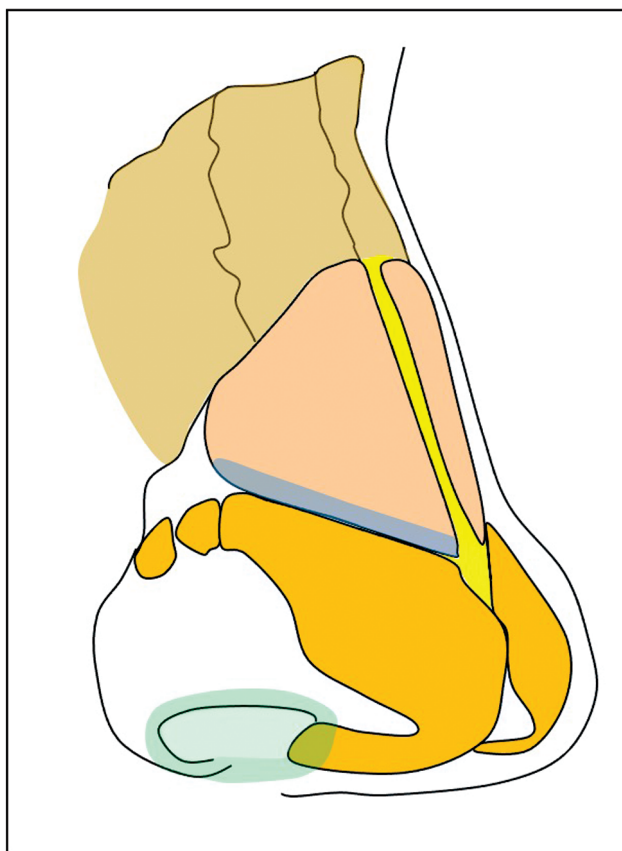


Fig. 1 The bony vault of the nose is composed of paired nasal bones, the ascending process of the maxilla and the nasal process of the frontal bone. The nasal bones articulate with the upper lateral cartilages which in turn articulate with the lower lateral cartilage. The internal nasal valve is depicted in blue and the external nasal valve is depicted in green.

Evaluation

The preoperative assessment of the nose begins with a good history and physical examination. A detailed nasal history should include the history of injury, the timing of injury, mechanism of injury, object responsible for injury, direction of injury, and force of injury. For acute nasal bone injury, a history of epistaxis indicates concurrent laceration of the nasal mucosa. Epistaxis without obvious nasal deformity may be the only clinical finding in some nasal bone fractures. The history should also include previous nasal surgery, functional status of the nose, nasal airway obstruction, and change in the appearance of the nose. Preinjury photos may be useful in ascertaining postinjury changes to the appearance of the nose.

A detailed physical examination should follow. The physical examination should start with an external examination of the nose. The external examination includes notation of any deviation to the nose, C-shape or S-shape deformity, bony width, alar rim morphology, dorsal profile, saddle nose deformity, and tip definition/projection. Any palpable step-offs or mobility of the nasal bone, swelling, fresh or well-healed lacerations, and changes in the shape of the nose should be noted. An internal examination should follow with a good headlight, decongestant, topical anesthesia if indicated, suction, and endoscope.

Topical decongestant may assist in the examination as there may be significant post-injury swelling. The internal examination should make note of the septum, septal fractures, septal deviations, septal dislocations, inferior turbinate size, internal nasal valve patency, and nasal airflow. A modified Cottle examination should also be done to assess nasal valve competency. In the event of an acute injury, a complete evaluation of the septum should be done, and septal hematoma should be ruled out. If a septal hematoma is present, it should be addressed promptly to avoid subsequent septal distortion, infection, necrosis, and saddle nose deformity. The septal mucosa is examined to assess for tears and fracture. A rigid endoscope may be used to better assess the septum, especially posteriorly. Rigid endoscopy can also assist in detecting other defects and previous septal injuries including septal fractures, posterior spurs, and septal perforations.

For acute nasal bone fracture evaluation, imaging may supplement a good history and physical examination. Plain radiographs are not necessary or cost-effective in the diagnosis of nasal bone fractures.¹⁵ Plain radiographs have poor sensitivity and poor specificity and can cloud the clinical picture. Computed tomography imaging can be obtained for patients who have significant swelling that prevents a good clinical examination of the nose, a history of high impact injury, cerebrospinal fluid rhinorrhea, or suspicion for other facial fractures based on physical examination.

Acute Treatment of Nasal Bone Fractures

There are three considerations to make when deciding on appropriate treatment for nasal bone fractures. The first is the timing of repair, the second is the choice of anesthetic, and the third is closed versus open reduction. In the first few days following nasal bone fracture, soft tissue swelling usually masks the underlying bony injury. For this reason, the timing of repair is generally completed within the first 10 to 14 days after injury.^{16–18} In the pediatric population, some authors have recommended performing the reduction within 7 days as bone healing can occur more quickly in the pediatric population.⁶ The indications for closed reduction are (1) unilateral or bilateral nasal bone fracture and (2) fracture of the nasal-septal complex with nasal deviation less than one-half width of the nasal bridge. The indications for open repair are (1) extensive fracture or dislocation of the nasal bones and septum, (2) nasal deviation that is greater than one-half width of the nasal bridge, (3) fracture and dislocation of the caudal septum, (4) open septal fracture, and (5) persistent nasal deformity after closed reduction.⁶

Closed nasal bone reductions can be done under local or general anesthesia. Numerous studies have demonstrated that local anesthesia is just as effective as general anesthesia and less expensive than general anesthesia.^{19–21} Following adequate analgesia, digital pressure can then be applied to reduce the nasal bone. For more complicated fractures, instrumentation may aid reduction—the Boies elevator is often less traumatic and less likely to cause mucosal damage and epistaxis. In this technique, the Boies elevator is inserted into the nose and the surgeon's thumb is placed over the

nasal bones to detect bony mobilization and assist reduction. A Walsham forceps may be used to correct and reduce impacted nasal bones, while an Asch forceps may be used to reduce the nasal septum.

For more complicated fractures and septal injuries, open reduction of the nasal bones should be performed. Open reductions can be accomplished by a variety of approaches.²² Complete exposure of the septum is obtained, and the septum is relocated onto the anterior nasal spine. In cases where the septum cannot be reduced and adequately secured, submucous resection of the septum is performed. This includes resection of the fractured portions of the cartilage and bone (vomere, perpendicular plate of the ethmoid).¹⁴ Following reduction, intranasal splints and external splints are applied to stabilize the reduction and allow for healing.

Delayed Treatment of Posttraumatic Nasal Deformity

Nasal deformity following nasal trauma is one of the most common reasons that patients seek open septorhinoplasty. In cases where acute and primary treatment of the nasal bone fracture or nasal deformity are not possible, delayed reconstruction may be done to address functional deficiencies, asymmetries, and deformities of the nose. In general, reconstruction and open septorhinoplasty are performed 6 to 12 months after injury to allow time for the scar tissue to mature and the deformity to stabilize. The incidence of posttraumatic nasal deformity ranges from 14 to 50% and the two most commonly seen posttraumatic nasal deformities are the crooked nose and the saddle nose deformity.⁷⁻⁹ Bony deviation from traumatic injury to the septum and to the nasal bones can result in a crooked nose. Inadequately treated septal fractures or unrecognized septal injury can also lead to a crooked nose. The septum is the key structure to correct to minimize secondary deformity and a crooked nose.⁵ Unrepaired septal injuries can cause progressive distortion of the septum and cause the nasal bones to heal in a deviated position, pulled to one side or another by the nasal septum. The age-old adage "as the septum goes, so goes the nose"²³ applies in these scenarios. For simple injuries involving the distal portion of the quadrangular cartilage, closed reduction with intranasal splints results in satisfactory outcomes.¹² Complex septal fractures are better addressed through an open approach.^{11,13,14} The saddle nose deformity is another common posttraumatic nasal deformity and is the result of loss of septal support. This may occur secondary to untreated septal hematoma. The saddle nose deformity is characterized by a scooped out profile, step-off between the bony and cartilaginous vaults and widened nasal width on frontal view.

The Crooked Nose

To fully address the crooked nose, the surgeon must address the bony vault, septum, and the lower two-thirds of the nose. When closed reduction is ineffective, and posttraumatic deformity persists, an open septorhinoplasty can be per-

formed 6 to 12 months following injury. This allows time for scar tissue to mature and the deformity to stabilize so an accurate operative plan can be executed.

The Bony Vault

Open reduction of the bony vault may be performed via an endonasal or external rhinoplasty approach. There are various osteotomy types that can be performed to achieve this (►Fig. 2). They include the lateral osteotomy, intermediate osteotomy, medial osteotomy, and transverse osteotomy. The purpose of an osteotomy is to mobilize the bony pyramid so that it can be reset in a more anatomically favorable position. A medial osteotomy is often necessary to create a controlled back fracture for the lateral nasal bone. To perform a medial osteotomy, a narrow straight osteotome is engaged in the nasal bone at the junction of the septum and nasal bone. The osteotome is then directed in a cephalic direction and faded laterally in a paramedian, medial oblique, or superior oblique direction. There are various approaches and methods for performing lateral osteotomies. Various points of access have been described, but^{5,24,25} the two most common approaches are the internal continuous lateral osteotomy and the perforated percutaneous lateral osteotomy.⁵ In the internal continuous lateral osteotomy technique, a 3-mm stab incision is made in the nasal vestibule just anterior to the insertion of the head of the inferior turbinate. A curved osteotome with a guard on the lateral edge is inserted into the incision and

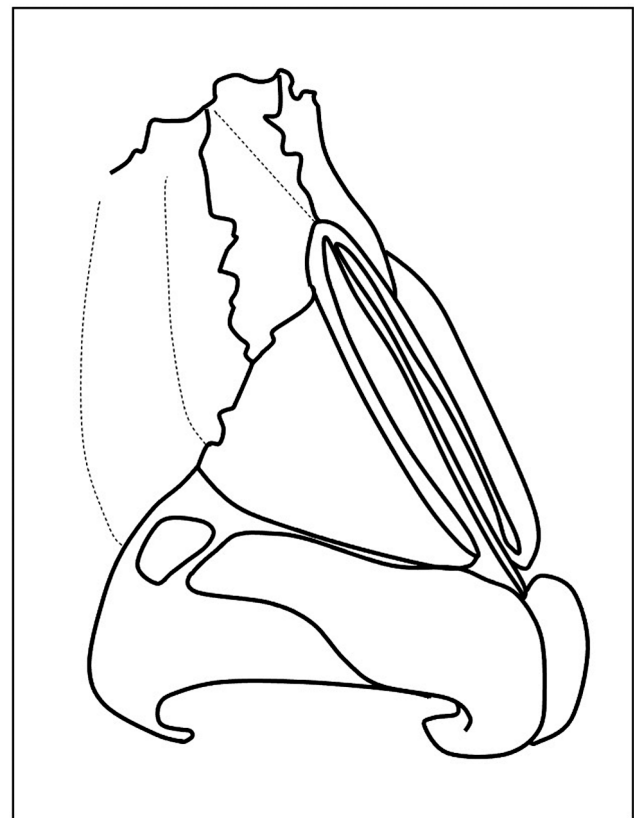


Fig. 2 Osteotomies: Medial, intermediate, and lateral osteotomies may be necessary to correct a severely deviated bony vault. In patients who have had a bony hump takedown with open roof, a medial osteotomy may be unnecessary to mobilize the nasal bone.

using tactile feedback, the curved osteotome is engaged with the edge of the piriform aperture. The guard on the lateral edge of the osteotome is then used as a guide to move the blade in the desired direction to perform a high-low-high, low-to-high, or low-to-low lateral osteotomy.^{5,26} The lateral osteotomy should not extend past the medial canthus cephalically. At the end of the osteotomy, the osteotome is directed back to create a fracture and mobilize the lateral nasal bone.

In the perforated percutaneous technique, a small stab incision is made externally over the nasal bone and a 2-mm osteotome is inserted at the mid-portion of the bony pyramid along the planned fracture line. A series of small discontinuous osteotomies are made in a postage-stamp fashion along the planned osteotomy line. In cases where there is significant deviation, concavity or convexity to the nasal bones, an intermediate osteotomy may also need to be performed (►Fig. 2). In these cases, the intermediate osteotomy should be done first to preserve stable bone on which to perform the lateral osteotomy. An external nasal splint is placed at the end of the procedure to help hold the reduced nasal bones in place during healing.

Middle Vault and Tip

In some patients with a crooked nose, osteotomies and repositioning of the bony vault will also straighten the nose. If the upper lateral cartilage, septum, and lower vault are intact and stable, bony repositioning can pull the entire cartilaginous vault into midline position. In cases where osteotomy does not reposition or straighten the nose, it is likely that there are more complex underlying septal deviations that need to be corrected and addressed. In general, asymmetries of the middle vault will parallel the asymmetries in the dorsal septum and upper lateral cartilages. Asymmetries of the nasal tip will follow deviation of the anterior septal angle and asymmetries in the medial crura and columellar deviation will parallel the caudal septal margin. To address these asymmetries in the cartilaginous vault of the nose, these respective portions of the septum need to be carefully assessed and corrected.²⁷

Middle Vault Asymmetry

Middle vault asymmetry often results from asymmetry in the upper lateral cartilages and dorsal septum. Addressing these asymmetries is best accomplished through an open/external rhinoplasty approach. After the nose is opened, the dorsal septum is carefully examined. Deviations in the dorsal septum can be addressed with spreader grafts. Spreader graft dimensions can vary from 10 to 20 mm × 2 to 3 mm × 2 to 4 mm.²⁸ Spreader grafts can open the nasal valve and camouflage asymmetries in the middle vault. Asymmetric spreader grafts can be fashioned and placed on either side of the deviated dorsal septum to address cosmetic asymmetries. Typically, a thicker spreader graft may be placed on the concave side of the deviation and the thinner graft on the convex side. Unilateral spreader graft placement is not recommended because the unilateral graft will tend to be pulled by the septum in the direction of deviation. It is the

inward force exerted by bilateral graft placement that will help correct the deviated septum.²⁷ An ethmoid bone graft harvested from the perpendicular plate of the ethmoid during septoplasty can also be fashioned into a spreader graft to splint the deviated dorsal septum into midline position.^{27,29} While the ethmoid bone graft provides a strong and stable splint for the deviated septum without widening the nose, one limitation of the ethmoid bone graft is a tendency for the bone to resorb over time leading to recurrence of functional and cosmetic issues.

The Nasal Tip and Lower Third

Deviation of the nasal tip and lower third can often be traced to caudal septal deviation. Correcting deviations in the caudal septum is challenging but crucial to reset the nasal tip in the midline. In cases where the caudal septum is straight but dislocated off the anterior nasal spine, nasal tip deviation may be addressed by repositioning the posterior septal angle over the nasal spine. If there is buckling of the caudal septum after repositioning due to excessive septal height, the excess can be trimmed along the posterior angle inferiorly and the septum repositioned over the nasal spine.

Deflections of the caudal septum that are mild can be addressed with various techniques. A mild deflection can be treated with scoring of the cartilage to combat the memory in the cartilage. Once the cartilage is scored, it can then be straightened and a cartilage graft can be sutured to the convex side to act as a splint to hold the caudal septum straight. If the cartilage graft has a curvature to it, the graft can be strategically placed so that the natural curvature opposes the deflection in the caudal septum to act as a splint to keep it straight. Ethmoid bone can also be harvested and used to splint the caudal septum to remove the curvature and straighten the deflection. While the ethmoid bone can act as an excellent splint to hold the cartilage straight, the bone may resorb over time with recurrence of the septal deviation and deflection.²⁷

For those patients who have a shortened nose, uprotated tip or retracted columella, a septal extension graft can be used to lengthen the nose, rotate the tip, and set the nasal tip in the midline. The caudal septal extension graft is overlapped with the caudal septum and sutured in place using two horizontal mattress sutures. Care should be taken to ensure the nasal airway is not obstructed by the overlapping septal extension graft. If there is a slight curve to the septal extension graft, this curve can be used to counteract the deflection in the existing caudal septum. Once the septal extension graft is placed, the medial crura are sutured to the graft, and the columellar base and nasal tip are set in the midline. The septal extension graft can be used to alter the length of the nose, tip projection, tip rotation, nasolabial angle, and columellar show.³⁰

Extracorporeal Septoplasty

For the severely deviated septum that involves the caudal septum and dorsal septal strut, the techniques described earlier may not be sufficient. In these cases, an extracorporeal septoplasty should be done to correct deviations in the

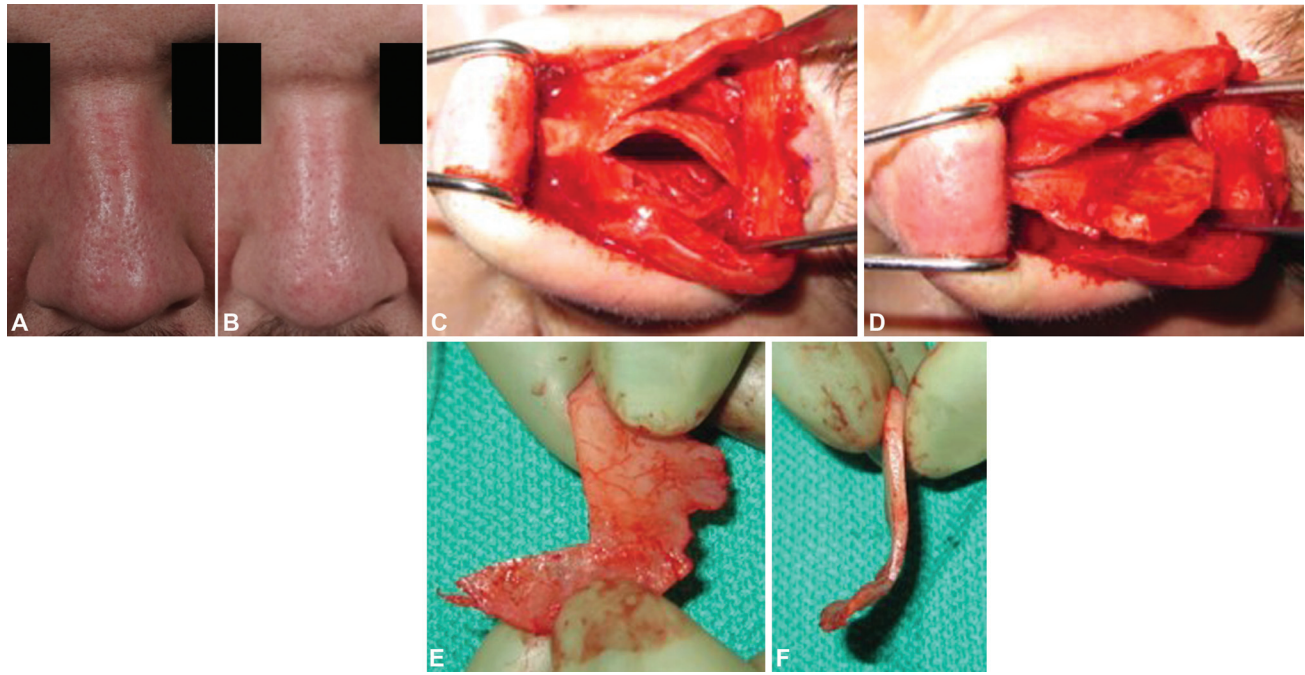


Fig. 3 Extracorporeal septoplasty. (A) Preoperative view of posttraumatic nasal deformity showing deviation and C-shape deformity to the nose. (B) Postoperative view demonstrating correction of the nasal deviation and deformity. (C) Intraoperative dissection demonstrating severe deviation of the cartilaginous septum. (D) Reconstructed septum with caudal septal replacement graft fashioned from septal cartilage. A portion of the dorsal cartilaginous strut has been maintained and preserved for securing the caudal septal replacement graft. (E) Deviated portion of septum including portions of the L strut completely excised. (F) Note the severe deviation and curve in the dorsal septal strut.

middle vault and nasal tip. Exposure of the septum is completed via an external rhinoplasty approach. The entire septum including the caudal septum is then removed en bloc and the entire L strut is reconstructed. When removing the septum, a remnant of the dorsal septum is left attached at the osseocartilaginous junction/keystone area to leave a cartilaginous remnant for reattachment of the replacement graft. The longer the dorsal remnant, the easier the repair will be. If possible, leaving at least 1.5 cm of dorsal remnant will be ideal and ensuring the dorsal attachment of the cartilaginous septum to the bony septum remains intact is ideal.²⁷ The attachment of the cartilaginous septum to the bony septum is what will provide dorsal stability for the septal reconstruction. If the native septum does not offer enough cartilage for reconstruction, additional cartilage may be harvested from the ear or the rib. Once the replacement septal graft is fashioned, it is overlapped with the remaining dorsal strut and secured to the dorsal strut with horizontal mattress sutures. The caudal portion of the graft is then secured to the periosteum of the nasal spine or the posterior septal angle remnant if one is left (►Fig. 3). Once the L-strut and septal replacement graft are inset, spreader grafts can be placed to stabilize the septal replacement graft to the mid-vault, fine tune cosmetic asymmetry in the mid-vault, and restore function of the internal nasal valve.

Saddle Nose Deformity

Saddle nose deformity after nasal trauma results from a loss of septal support and structure. This may result from untreated septal hematoma which may lead to an abscess

that results in cartilage resorption and loss of septal support. Saddle nose deformity is characterized by a distinct scooped out profile, step-off between the bony and cartilaginous vaults, widened nasal width on frontal view, and functional nasal obstruction due to collapse of the internal nasal valve from collapsing upper lateral cartilages (►Fig. 4).

There are various methods available to augment the nasal dorsum. For more mild cases of deformity where only a few millimeters of augmentation are needed, dorsal onlay grafts can be used for augmentation. Dorsal onlay grafts can be fashioned from septal, auricular, or costal cartilage. The cartilage is carved into a canoe shape and the edges are beveled to better camouflage any sharp edges under the skin. Depending on the amount of augmentation needed, multiple segments may need to be carved, stacked, and sutured together to achieve the desired height. A subperiosteal pocket is then created and the graft is inserted into this pocket and the graft is secured to the remaining dorsal septum. A transcutaneous suture can be placed to stabilize the graft cephalically.³¹

For severe saddle nose deformities and cases that require significant augmentation, costal cartilage should be harvested as grafting material. The rib cartilage is carved en bloc into a canoe-shaped structure and placed along the dorsum to augment and correct the saddle nose deformity (►Fig. 4). The canoe-shaped graft is typically concave on the undersurface and has an 8:2:1 length to width to height ratio.³² Contouring the rib to avoid sharp edges is important to improve the cosmetic outcome and prevent palpable edges or visible edges in the graft. This is particularly important in thin-skinned individuals. When inseting the monobloc rib graft, the underlying septum must be strong enough to support the graft. In patients with

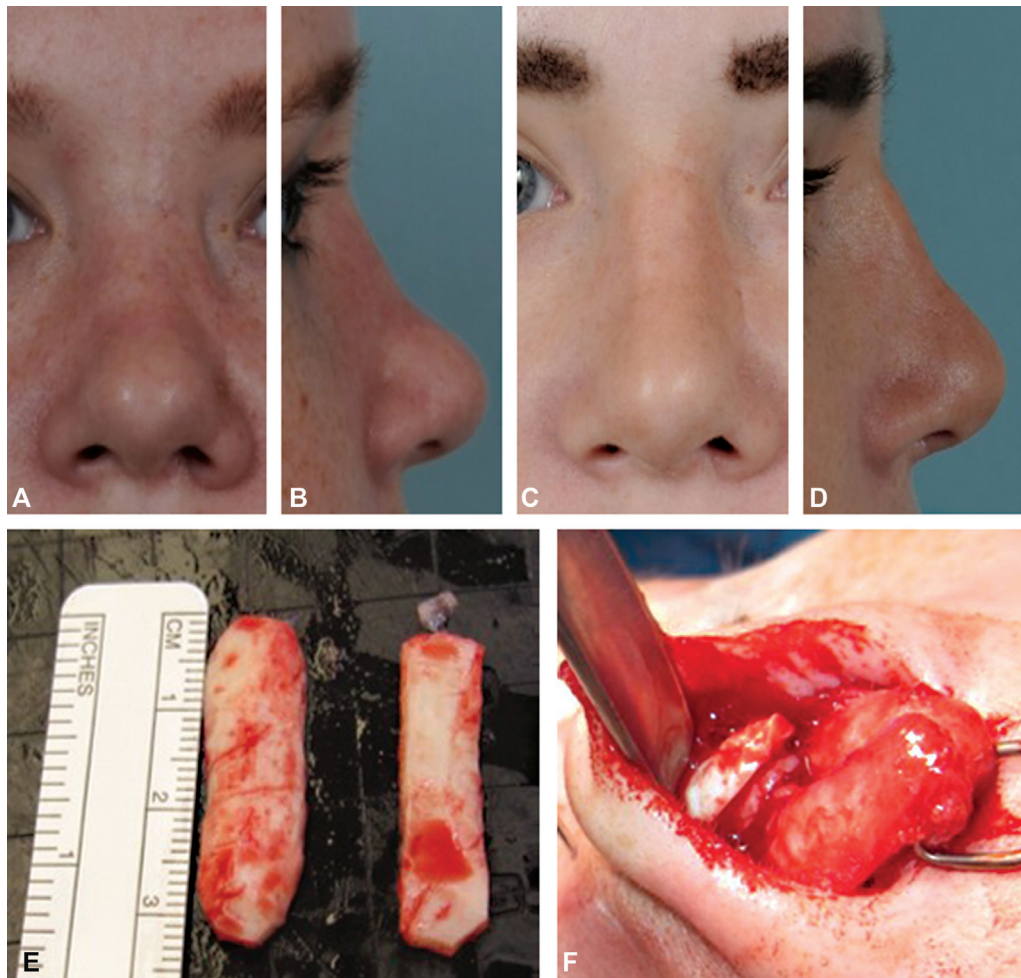


Fig. 4 Posttraumatic saddle nose deformity. (A) Frontal view of a patient with posttraumatic saddle nose deformity showing step-off between the bony and cartilaginous vaults and widened nasal width. (B) Preoperative profile view showing scooped out appearance of the nose on profile view. (C, D) Postoperative photos showing narrowed bony vault on frontal view and correction of scooped out profile and step-off between the bony and cartilaginous vaults. (E) Autologous rib cartilage carved for dorsal augmentation. (F) The graft is placed in a tight subperiosteal pocket to provide dorsal augmentation.

severe septal compromise, caudal support of the tip will also need to be reconstructed to support the graft and the nasal tip. In these patients, a caudal septal replacement graft or caudal septal extension graft can be fashioned and fixed to the anterior nasal spine to provide tip support. This caudal septal graft is then incorporated into the dorsal monobloc graft. The dorsal graft is then stabilized cephalically by the nasal bone and caudally by the caudal septal extension graft. A subperiosteal pocket is then created over the nasal bones and the dorsal graft is inserted snugly into this pocket and can be fixed with a Kirschner wire cephalically. Caudally, the dorsal graft is secured to the caudal septal extension or replacement graft.

Another option for dorsal augmentation is diced cartilage. Diced cartilage for nasal augmentation was revived by Erol's publication on the use of the "Turkish delight" graft.³³ Daniel and Calvert recommended the use of autologous temporalis fascia as the wrap for the diced cartilage.^{34,35} In this technique, cartilage is diced into 0.5 to 1 mm cubes. The grafts are then wrapped in temporalis fascia or placed in a 1-mL syringe for easy insertion of the diced cartilage into the fascial wrap. The grafts remain palpable postoperatively and are malleable for

10 to 14 days postoperatively. Due to lack of absorption, the graft can be used to achieve the ideal shape of the nose at the time of surgery, and no overcorrection is necessary.³⁴

Due to the drawbacks of temporalis fascia harvest, various methods have been developed to simplify the use of the diced cartilage graft in dorsal augmentation. Modifications of this procedure and experimentation with other materials to wrap and prepare the diced cartilage graft have been described. Other materials used to wrap the diced cartilage include acellular cadaveric dermis and oxidized regenerated cellulose.³⁶ Tasman et al described the use of two-component fibrin glue to hold the diced cartilage together in a malleable graft that may be used to augment the nasal dorsum. In this technique, the cartilage is diced into 0.5 to 1 mm sized cubes and placed in a 3-mL syringe that has been fashioned into a boat. Fibrin glue is applied over the cartilage (—Fig. 5), and the graft is unmolded and inserted into a tight subperiosteal pocket. The graft is malleable and can be molded to the desired shape on the table. This technique has reduced operative time and the grafts have demonstrated good longevity³⁷ and good results in dorsal augmentation.

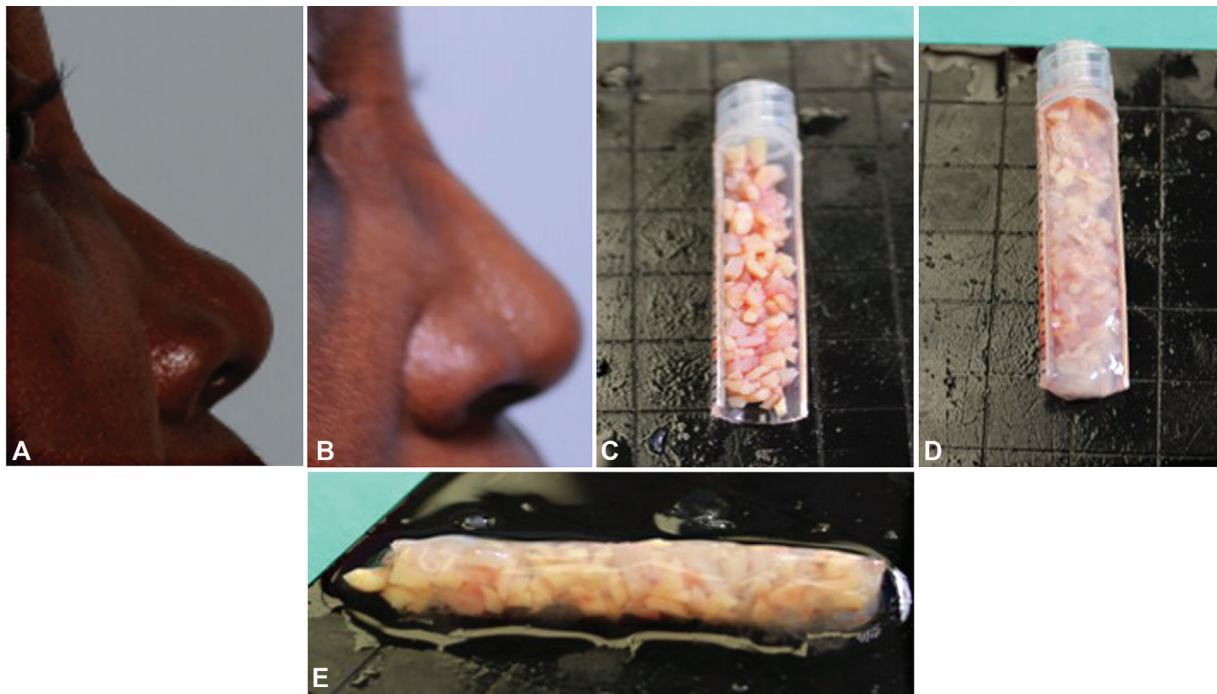


Fig. 5 Diced cartilage glue graft for correction of saddle nose deformity. (A) Preoperative profile view of saddle nose deformity with decreased dorsal height and step-off between bony and cartilaginous vaults. (B) Postoperative view demonstrating improved dorsal height and correction of step-off between the bony and cartilaginous vaults. (C) Diced cartilage placed in a 1-mL syringe. (D) Fibrin glue applied to diced cartilage. (E) Diced cartilage glue graft unmolded from the syringe for insertion into the nasal dorsum. The graft holds its shape but continues to be malleable following placement in the nose.

Summary/Conclusion

While considered a mild injury, nasal bone fractures can have long-lasting consequences on the cosmetic and functional form of the nose. Even with prompt treatment and early closed reduction, posttraumatic nasal deformity can result. The two most common posttraumatic deformities are the crooked nose and the saddle nose. Both require attention to the bony and cartilaginous vaults of the nose and careful attention to the septum. Good reduction and adequate treatment often involve carefully planned osteotomies and reconstruction of the L-strut of the nose to reconstitute the middle vault and reset the nasal tip in the midline. There are many techniques available to the rhinoplasty surgeon to accomplish this. By understanding the anatomy of the nose, the relation between the bony and cartilaginous vaults, and the anatomy of the L-strut, the rhinoplasty surgeon can address these difficult deformities while maintaining the cosmetic and functional integrity of the nose.

Conflict of Interest

T.H. is a consultant for Hansbiomed.

References

- 1 Basheeth N, Donnelly M, David S, Munish S. Acute nasal fracture management: a prospective study and literature review. *Laryngoscope* 2015;125(12):2677–2684
- 2 Kucik CJ, Clenney T, Phelan J. Management of acute nasal fractures. *Am Fam Physician* 2004;70(07):1315–1320
- 3 Dong SX, Shah N, Gupta A. Epidemiology of nasal bone fractures. *Facial Plast Surg Aesthet Med* 2022;24(01):27–33
- 4 Maliniac J. *Rhinoplasty and Restoration of Facial Contour: With Specific Reference to Trauma*. Boca Raton, FL: FA Davis; 1947
- 5 Rohrich RJ, Adams WPJ, Ahmad J, Gunter JP. *Dallas Rhinoplasty: Nasal Surgery by the Masters*. Whitefish, MT: CRC Press; 2014
- 6 Mondin V, Rinaldo A, Ferlito A. Management of nasal bone fractures. *Am J Otolaryngol* 2005;26(03):181–185
- 7 Kurihara K, Kim K. Open reduction and interfragment wire fixation of comminuted nasal fractures. *Ann Plast Surg* 1990;24(02):179–185
- 8 Yilmaz MS, Guven M, Varli AF. Nasal fractures: is closed reduction satisfying? *J Craniofac Surg* 2013;24(01):e36–e38
- 9 Crowther JA, O'Donoghue GM. The broken nose: does familiarity breed neglect? *Ann R Coll Surg Engl* 1987;69(06):259–260
- 10 Murray JA, Maran AG. The treatment of nasal injuries by manipulation. *J Laryngol Otol* 1980;94(12):1405–1410
- 11 Murray JA, Maran AG, Mackenzie IJ, Raab G. Open v closed reduction of the fractured nose. *Arch Otolaryngol* 1984;110(12):797–802
- 12 Renner GJ. Management of nasal fractures. *Otolaryngol Clin North Am* 1991;24(01):195–213
- 13 Pollock RA. Nasal trauma. Pathomechanics and surgical management of acute injuries. *Clin Plast Surg* 1992;19(01):133–147
- 14 Harrison DH. Nasal injuries: their pathogenesis and treatment. *Br J Plast Surg* 1979;32(01):57–64
- 15 Hester TO, Campbell JP. Diagnosis and management of nasal trauma for primary care physicians. *J Ky Med Assoc* 1997;95(09):386–392
- 16 Rubinstein B, Strong EB. Management of nasal fractures. *Arch Fam Med* 2000;9(08):738–742
- 17 Rohrich RJ, Adams WP Jr. Nasal fracture management: minimizing secondary nasal deformities. *Plast Reconstr Surg* 2000;106(02):266–273

- 18 Ridder GJ, Boedeker CC, Fradis M, Schipper J. Technique and timing for closed reduction of isolated nasal fractures: a retrospective study. *Ear Nose Throat J* 2002;81(01):49–54
- 19 Cook JA, McRae RD, Irving RM, Dowie LN. A randomized comparison of manipulation of the fractured nose under local and general anaesthesia. *Clin Otolaryngol Allied Sci* 1990;15(04):343–346
- 20 Waldron J, Mitchell DB, Ford G. Reduction of fractured nasal bones; local versus general anaesthesia. *Clin Otolaryngol Allied Sci* 1989;14(04):357–359
- 21 Watson DJ, Parker AJ, Slack RW, Griffiths MV. Local versus general anaesthetic in the management of the fractured nose. *Clin Otolaryngol Allied Sci* 1988;13(06):491–494
- 22 Fernandes SV. Nasal fractures: the taming of the shrewd. *Laryngoscope* 2004;114(03):587–592
- 23 Rengaraja D, Jagade M, Kale V, et al. As the nasal spine goes, so goes the septum. *J Clin Diagn Res* 2016;10(11):MC04–MC06
- 24 Parsa FD. Intraoral versus intranasal approach to lateral osteotomy. *Plast Reconstr Surg* 1992;90(02):341
- 25 Gyskiewicz JM, Gyskiewicz KM. Nasal osteotomies: a clinical comparison of the perforating methods versus the continuous technique. *Plast Reconstr Surg* 2004;113(05):1445–1456, discussion 1457–1458
- 26 Rohrich RJ, Minoli JJ, Adams WP, Hollier LH. The lateral nasal osteotomy in rhinoplasty: an anatomic endoscopic comparison of the external versus the internal approach. *Plast Reconstr Surg* 1997;99(05):1309–1312, discussion 1313
- 27 Kim DW, Toriumi DM. Management of posttraumatic nasal deformities: the crooked nose and the saddle nose. *Facial Plast Surg Clin North Am* 2004;12(01):111–132
- 28 Paul MA, Kamali P, Chen AD, et al. Assessment of functional rhinoplasty with spreader grafting using acoustic rhinomanometry and validated outcome measurements. *Plast Reconstr Surg Glob Open* 2018;6(03):e1615
- 29 Sadooghi M, Ghazizadeh M. Extended osteocartilaginous spreader graft for reconstruction of deviated nose. *Otolaryngol Head Neck Surg* 2012;146(05):712–715
- 30 Kim MH, Choi JH, Kim MS, Kim SK, Lee KC. An introduction to the septal extension graft. *Arch Plast Surg* 2014;41(01):29–34
- 31 Swanepoel PF, Fysh R. Laminated dorsal beam graft to eliminate postoperative twisting complications. *Arch Facial Plast Surg* 2007;9(04):285–289
- 32 Kim DW, Shah AR, Toriumi DM. Concentric and eccentric carved costal cartilage: a comparison of warping. *Arch Facial Plast Surg* 2006;8(01):42–46
- 33 Erol OO. The Turkish delight: a pliable graft for rhinoplasty. *Plast Reconstr Surg* 2000;105(06):2229–2241, discussion 2242–2243
- 34 Daniel RK, Calvert JW. Diced cartilage grafts in rhinoplasty surgery. *Plast Reconstr Surg* 2004;113(07):2156–2171
- 35 Calvert JW, Brenner K, DaCosta-Iyer M, Evans GR, Daniel RK. Histological analysis of human diced cartilage grafts. *Plast Reconstr Surg* 2006;118(01):230–236
- 36 Heidari MB, Rasti M, Nadri S, Roozbehani A, Farhang Fallah A, Mahmoudvand H. Comparison between wrapping dice cartilage with temporal fascia and wrapping in alloderm for dorsal nasal augmentation. *World J Plast Surg* 2020;9(02):160–165
- 37 Tasman AJ, Diener PA, Litschel R. The diced cartilage glue graft for nasal augmentation. Morphometric evidence of longevity. *JAMA Facial Plast Surg* 2013;15(02):86–94