

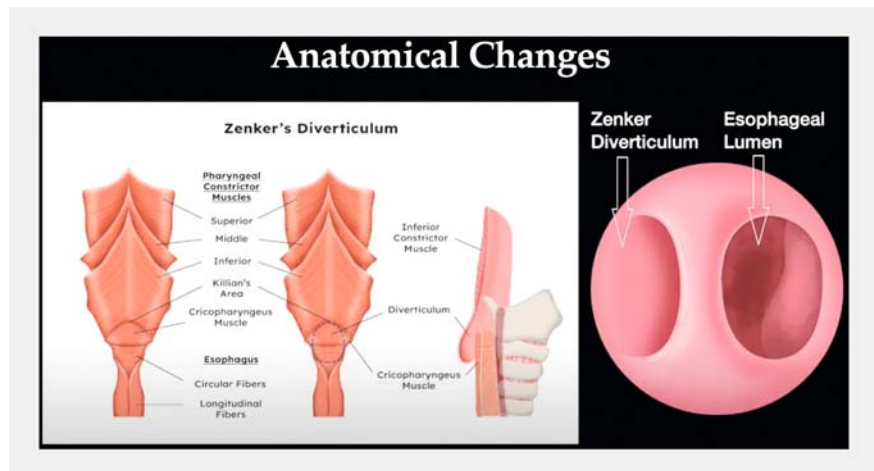
Simplified endoscopic septotomy for a large symptomatic Zenker's diverticulum



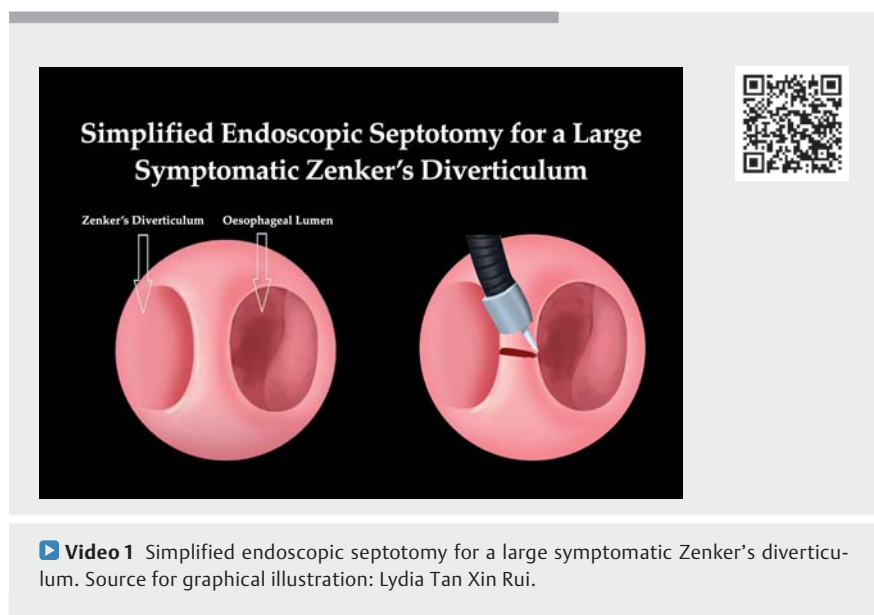
Zenker's diverticulum is a pulsion diverticulum occurring because of abnormal cricopharyngeal muscle (CPM) relaxation during swallowing (► **Fig. 1**) [1]. Traditionally, Zenker's diverticulum has been treated by surgery; however, open surgery has high complication rates and morbidity. Flexible endoscopic options are a safe and effective treatment alternative for Zenker's diverticulum, with comparable efficacy and low recurrence rates [2]. The Zenker's diverticulum peroral endoscopic myotomy (zPOEM) and modified Z-POEM have been described as effective treatment options [3]. These procedures are technically demanding and require high levels of expertise. We present a simplified technique that was used to treat a large symptomatic Zenker's diverticulum (► **Video 1**).

A 79-year-old man presented with a 2-year history of dysphagia, weight loss, and regurgitation. Esophagogastroduodenoscopy showed a large (5 cm) Zenker's diverticulum (► **Fig. 2**). A computed tomography scan and barium studies confirmed the large Zenker's diverticulum, which was compressing the esophagus and occluding the lumen (► **Fig. 3**). The patient was therefore planned to undergo a simplified endoscopic septotomy under general anesthesia.

We equipped the endoscope with a distal cap and used CO₂ insufflation. First, we marked the esophageal lumen by advancing a feeding tube into it. Second, we cleaned the diverticular sac until it was free of debris. Third, we used a rotatable short insulated scissor-type knife (SB knife; Sumitomo Bakelite, Japan) to cut the septum and the CPM, using blended current for dissection. We started at the center and cut the septal mucosa and CPM sequentially to prevent flap formation. We regularly inspected the Zenker's diverticulum and the esophageal lumen to ascertain the dissection depth, and ensured that the septum was dissected adequately to create a common space be-



► **Fig. 1** Illustration showing the anatomy of a Zenker's diverticulum. Source: Lydia Tan Xin Rui.



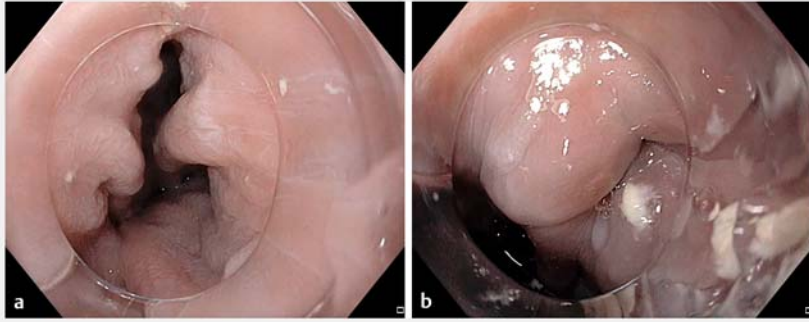
► **Video 1** Simplified endoscopic septotomy for a large symptomatic Zenker's diverticulum. Source for graphical illustration: Lydia Tan Xin Rui.

tween the sac and the esophagus. Lastly, we secured hemostasis and closed the defect with clips (► **Fig. 4**). The patient was kept on a liquid diet and was discharged after 24 hours with analgesics. In conclusion, our simplified stepwise approach is less technically challenging and could be quickly adopted to treat large Zenker's diverticula safely.

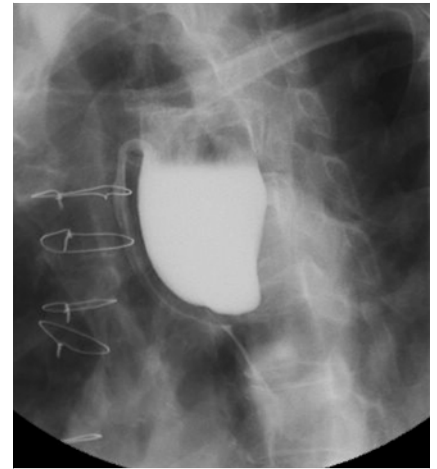
Endoscopy_UCTN_Code_TTT_1AO_2AG

Acknowledgments

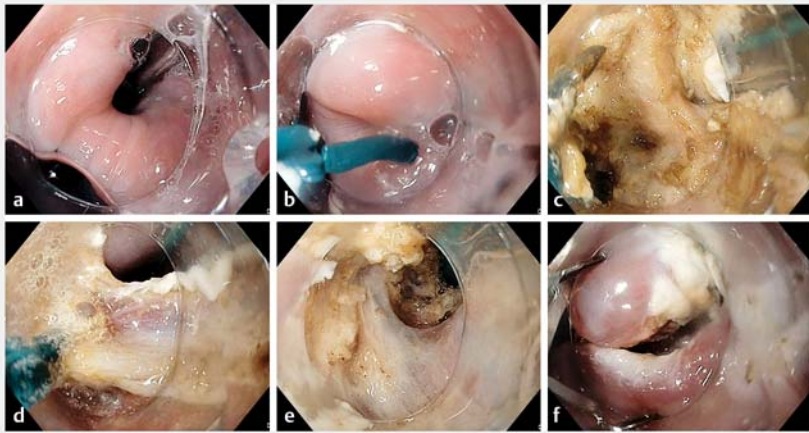
We thank Ms. Lydia Tan Xin Rui for the informative illustrations.



► **Fig. 2** Endoscopic images showing: **a** a large Zenker's diverticulum; **b** the septum and the compressed esophageal lumen.



► **Fig. 3** Barium swallow showing a large Zenker's diverticulum causing compression of the esophagus.



► **Fig. 4** Endoscopic images during the simplified Zenker's diverticulum peroral endoscopic myotomy (zPOEM) procedure showing: **a** the esophageal lumen marked with a feeding tube; **b** a scissor-type knife being used to cut the septum; **c** dissection of the mucosa to expose the cricopharyngeal muscle (CPM); **d** cutting of the CPM muscle; **e** dissection and cutting of the mucosa and the muscle until the base of the diverticulum is reached; **f** inspection of the base of the diverticulum, with hemostasis secured and the defect closed with clips.

Corresponding author

Ravishankar Asokkumar, MBBS

Department of Gastroenterology and Hepatology, Singapore General Hospital, 20, College Road, Outram Campus, 169856 Singapore
ravishnkr03@gmail.com

References

- [1] Cook IJ, Gabb M, Panagopoulos V et al. Pharyngeal (Zenker's) diverticulum is a disorder of upper esophageal sphincter opening. *Gastroenterology* 1992; 103: 1229–1235
- [2] Law R, Katzka DA, Baron TH. Zenker's diverticulum. *Clin Gastroenterol Hepatol* 2014; 12: 1773–1782
- [3] Zhang LY, Nieto J, Ngamruengphong S et al. Zenker's diverticulum: advancing beyond the tunnel. *VideoGIE* 2021; 6: 562–567

Bibliography

Endoscopy 2023; 55: E1122–E1123

DOI 10.1055/a-2174-8690

ISSN 0013-726X

© 2023. The Author(s).

This is an open access article published by Thieme under the terms of the Creative Commons Attribution License, permitting unrestricted use, distribution, and reproduction so long as the original work is properly cited.

(<https://creativecommons.org/licenses/by/4.0/>)

Georg Thieme Verlag KG, Rüdigerstraße 14, 70469 Stuttgart, Germany



Competing interests

R. Asokkumar is a consultant for Apollo Endosurgery, USA. J. Ng, C. Francisco, T. Yi Yuan, C. Khor, and M. Cheah declare that they have no conflict of interest.

The authors

Ravishankar Asokkumar^{1,2,‡}, Jeanette Pei Xuan Ng^{1,‡}, Francisco Carlos Paolo Dimatatac¹, Yi Yuan Tan¹, Christopher Khor^{1,2}, Mark Cheah Chang Chuen^{1,2}

1 Department of Gastroenterology and Hepatology, Singapore General Hospital, Singapore

2 Duke-NUS Graduate Medical School, Singapore

[‡] Joint first authors