Cold snare defect protrusion and incomplete polyp resection after forced cold snare polypectomy: a prospective observational study

GRAPHICAL ABSTRACT

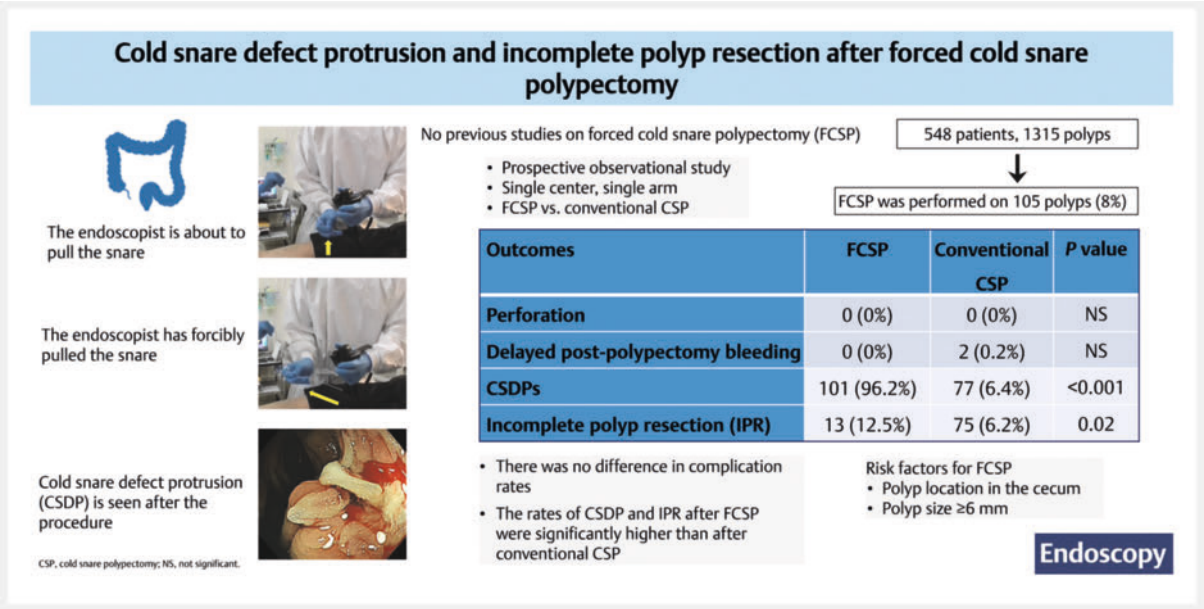

Authors

Jun Arimoto[1], Hideyuki Chiba[1], Keiji Yamada[1], Takanori Nishiguchi[1], Mikio Kobayashi[1], Naoya Okada[1], Takuma Suto[1], Toshihiro Niikura[1], Hiroki Kuwabara[1], Michiko Nakaoka[1], Tomonori Ida[1]

Institution

1 Gastroenterology, Omori Red Cross Hospital, Ota-ku, Japan

received 5.1.2023
accepted after revision 28.9.2023
accepted manuscript online 28.9.2023
published online 10.11.2023

Bibliography
Endoscopy 2024; 56: 14–21
DOI 10.1055/a-2183-5505
ISSN 0013-726X

Georg Thieme Verlag KG, Rüdigerstraße 14, 70469 Stuttgart, Germany

Supplementary material
Supplementary material is available under https://doi.org/10.1055/a-2183-5505

Corresponding author
Hideyuki Chiba, MD, Department of Gastroenterology, Omori Red Cross Hospital, 4-30-1, Chuo, Ota-Ku, 143-8527 Tokyo, Japan
h.chiba04@gmail.com

ABSTRACT

Background Cold snare defect protrusions (CSDPs) that occur after cold snare polypectomy (CSP) are considered indicators of incomplete polyp resection (IPR). We have sometimes experienced difficulty resecting polyps with snaring alone; in such cases, a forcible pull on the snare by the endoscopist is necessary. We call this procedure "forced CSP (FCSP)." However, no previous studies have evaluated this procedure.

Methods This was a prospective observational study. From November 2020 to June 2021, the frequency, safety, and validity of FCSP were evaluated at our hospital. We distinguished CSP with snaring alone performed by the assistant as conventional CSP, and CSP requiring a forcible pull on the snare by the endoscopist as FCSP.

Results Of 1315 polyps removed, 105 underwent FCSP (8%). The perforation rate was 0% in both groups. The rate of CSDP after the procedure was 96.2% (101/105) with FCSP and 6.4% (77/1210) with conventional CSP ($P<0.001$). The rate of IPR was 12.5% (13/104) with FCSP and 6.2% (75/1208) with conventional CSP ($P=0.02$). Multivariable analysis identified polyps located in the cecum (risk ratio [RR], 1.13; 95%CI 1.050–1.179; $P=0.003$) and polyps ≥6 mm in diameter (RR, 2.37; 95%CI 2.146–2.542; $P<0.001$) as independent risk factors for FCSP.

Conclusions FCSP was performed on 105 polyps (8%) in this study. FCSP may be associated with the occurrence of CSDP and IPR. Further studies are necessary to confirm our results.

Introduction

Resection of colorectal polyps can reduce the incidence and mortality of colorectal cancer by interrupting the adenoma–carcinoma sequence [1, 2, 3]. Therefore, the importance of early detection and early treatment is recognized, and endoscopic removal of all detected colorectal polyps is currently a standard practice during colonoscopic screening. Hot snare polypectomy (HSP) and endoscopic mucosal resection (EMR) are the most commonly performed endoscopic therapies for resection of colorectal polyps. However, delayed post-polypectomy bleeding is a major complication of HSP and EMR [4, 5, 6]. In contrast, several studies have shown that delayed post-polypectomy bleeding is less common after cold snare polypectomy (CSP) than after conventional polypectomy (i.e. HSP and/or EMR) [7, 8]. We have also reported that continued use of antithrombotic agents does not increase the risk of delayed post-polypectomy bleeding after CSP, even in those receiving multiple antithrombotic agents [9]. In addition, CSP has been reported to be superior to conventional HSP and EMR in terms of the procedure time [10, 11].

The use of CSP has spread rapidly in recent years because of its convenience and safety. CSP is certainly safe; however, a small number of difficult cases have been reported [12, 13]. In addition, cold snare defect protrusions (CSDPs) that occur after CSP are important issues in clinical practice [14]. A prevalence rate for CSDP of 14%–36% has been reported, with CSDPs involving the muscularis mucosa and submucosal tissues [14, 15, 16].CSDPs are considered indicators of incomplete mucosal layer resection.

Although the use of CSP has spread rapidly worldwide, there is no strict definition of the procedure. In some cases, snaring alone performed by the assistant is insufficient for polyp resection, and the endoscopist may need to forcibly pull the snare to remove the lesion. We have also performed this procedure and call it “forced CSP (FCSP).” However, no previous studies have assessed the outcomes after FCSP. Our clinical impression is that FCSP often causes CSDPs. If FCSP is truly associated with the development of CSDPs, FCSP should be avoided for accurate evaluation of pathological margins. We conducted this study to examine the validity of FCSP.

Methods

Patients

From November 2020 to June 2021, the frequency, safety, and validity of FCSP were evaluated at Omori Red Cross Hospital. During the study period, consecutive patients who were scheduled for colonoscopy were prospectively enrolled. CSP was indicated for colorectal polyps measuring up to 10 mm in diameter; lesions with submucosal invasion and lesions suspected of being cancerous during the preprocedural diagnostic evaluation were excluded. Narrow-band imaging, magnifying endoscopy, and chromoendoscopy were used for the diagnosis. We included all patients who underwent CSP, even those being treated with antithrombotic agents. We performed CSP during continuation of antithrombotic treatment, even in patients receiving multiple agents.

In this study, we counted each polyp that was resected, even if two or more polyps were resected during the same colonoscopy procedure. The study protocol complied with the Declaration of Helsinki and the Ethics Guidelines for Clinical Research published by the Ministry of Health, Labour and Welfare, Japan. Written informed consent for polypectomy and this study was obtained from all patients scheduled for colonoscopy. The study was approved by the Ethics Committee of Omori Red Cross Hospital on August 24, 2020.

CSP procedure

Bowel preparation for the procedure was initiated 1 day prior to colonoscopy. Each patient was instructed to consume a low-residue diet and take 5 mg of oral sodium picosulfate the evening before the colonoscopy. On the day of the colonoscopy, each patient was given 1500 mL of polyethylene glycol. If the stools were not sufficiently clear, an additional 500 mL of polyethylene glycol was given to ensure sufficient bowel cleansing. In almost all cases, midazolam (2–5 mg) for conscious sedation and pethidine (17.5–35 mg) were administered at the beginning of the procedure. During the procedure, blood pressure, heart rate, electrocardiography, and peripheral oxygen saturation were monitored. Intravenous glucagon or scopolamine was administered, as needed, to reduce colonic movements.

A standard or magnifying colonoscope with carbon dioxide insufflation was used in all cases (CF-HQ290ZI, PCF-Q260AZI, PCF-Q260AI, and PCF-H290ZI; Olympus Co., Tokyo, Japan). A transparent attachment was placed on the tip of the endoscope. Cecal intubation was verified by identification of the appendiceal orifice and ileocecal valve. The location, size, and

macroscopic type of all detected lesions were documented according to the Paris Classification [17, 18]. Polyp resection was performed with a Snaremaster-Plus (Olympus) or Captivator II snare (Boston Scientific, Tokyo, Japan) or Captivator COLD (Boston Scientific), which have sheath widths of 2.6 mm and 2.4 mm, respectively, and the snare was chosen by the individual endoscopist. Endoscopists measured the polyps using the size of the snare catheter or snare diameter.

All detected colorectal polyps up to 10 mm in diameter, except for tiny hyperplastic polyps in the rectum and distal sigmoid colon, were resected. We usually perform CSP during colonoscopy. Whether the polyps were resected with HSP (or EMR) or CSP was left to the judgment of the experts. Experts were defined as endoscopists with experience performing ≥500 colonoscopies, and trainees were defined as endoscopists with experience performing <500 colonoscopies. We used the cutoff value for endoscopy experience of 500 colonoscopies based on a previous report showing that experience of ≥500 colonoscopies was probably required to ensure reliable independent completion rates [19].

In our hospital, CSP is performed as follows. Every polyp was examined in detail to determine the appropriateness of resection with CSP. After it was judged that CSP would be suitable, the polyp was manipulated to the 6 o'clock position to secure a stable endoscopic view. The snare was opened by the assistant, and the endoscopist carefully enveloped the polyp with the snare to secure an adequate margin. The snare was closed by the assistant; then, the sheath was straightened to apply force to the tip of the snare to remove the polyp. When snaring alone performed by the assistant (conventional CSP) was inadequate for polyp resection, FCSP was performed. In rare situations, even FCSP was inadequate for polyp removal. We defined these cases as "conversion to HSP": CSP was attempted first, but the procedure was converted to HSP because of the need for additional electrocautery. When conventional CSP was inadequate for polyp removal, direct conversion to HSP was not performed without first attempting FCSP. Therefore, no subjective evaluation was performed. After polypectomy, the resultant wound was inspected carefully in all cases to confirm that there was no residual lesion. At our hospital, we usually perform these steps as part of daily clinical practice. At our institution, we do not discontinue antithrombotic agents in patients undergoing CSP, even in those receiving multiple drugs [11]. CSP was performed on either an outpatient or inpatient basis. All patients were given a regular diet starting from the evening of the day CSP was performed.

Diagnosis of the morphologic type was made in accordance with the Paris classification system [17, 18]. With regard to morphologic types, we previously conducted three studies on the use of CSP for Ip polyps with thin stalks [20, 21, 22], and we also included CSP for Ip polyps with thin stalks in the current study. However, we did not perform CSP for Ip polyps with thick stalks or for polyps >10 mm in diameter. In addition, we did not perform CSP for lesions showing evidence of carcinoma during the preprocedural diagnostic evaluation.

We divided CSP into two procedures due to differences in technique. We distinguished CSP with snaring alone performed by the assistant as conventional CSP and CSP with a forcible pull on the snare performed by the endoscopist as FCSP. ▶ **Fig. 1** shows the typical FCSP procedure performed at our hospital.

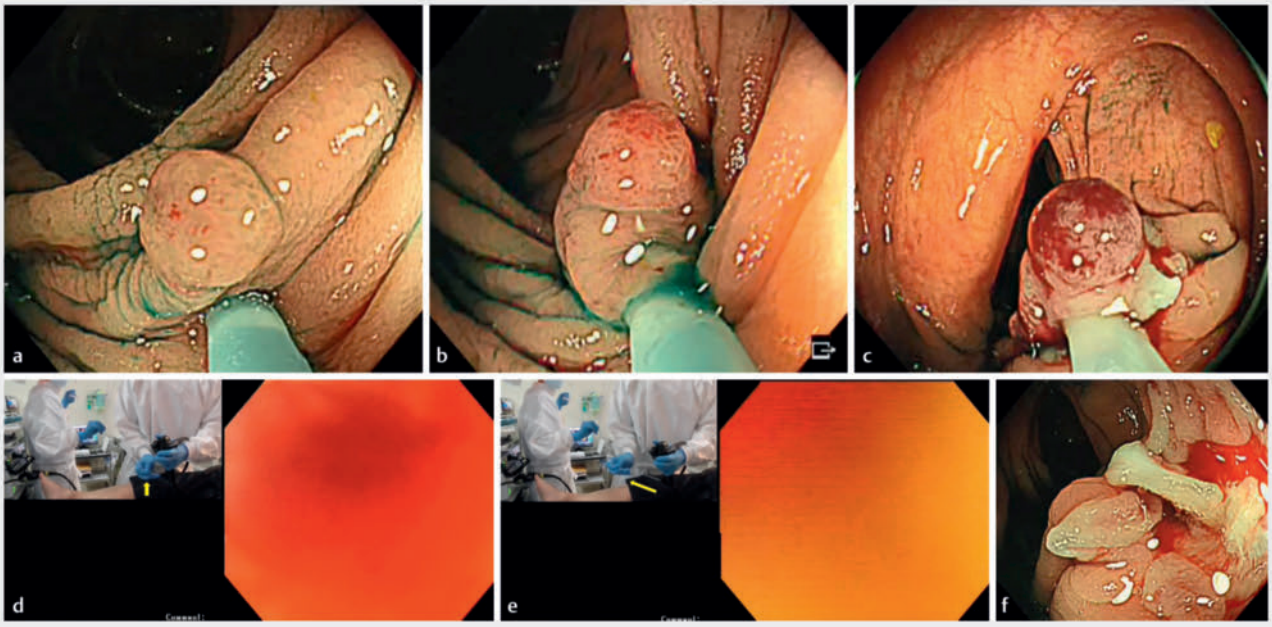

▶ **Fig. 1** Forced cold snare polypectomy (FCSP) procedure. **a** A 4-mm 0-Is polyp is visualized above the fold of the ascending colon. **b** Snaring is performed with an adequate margin. **c** The polyp cannot be removed by snaring alone. **d** Before FCSP, the endoscopist is about to pull the snare. **e** After FCSP, the endoscopist has forcibly pulled the snare. **f** Cold snare defect protrusion is seen after FCSP.

Data analysis and definition of outcomes

All patients were divided into two groups: the FCSP group and the conventional CSP group. The primary outcome measure was the frequency of FCSP. The secondary outcome measures were the outcomes of FCSP and conventional CSP, and the risk factors for FCSP. We examined the rate of delayed post-polypectomy bleeding within 2 weeks after polypectomy, immediate bleeding during the procedure, and the pathological margins of the resected specimen as outcomes of CSP. Delayed post-polypectomy bleeding was defined as a fall in the hemoglobin level by at least 2 g/dL below the most recent preoperative level or the need for endoscopic hemostasis and/or blood transfusion and/or massive melena [9, 23, 24, 25]. Immediate bleeding that necessitated hemostatic clipping was defined as spurting or oozing that continued for more than 30 seconds [9, 23]. This definition was used to avoid the potential for a biased assessment of immediate bleeding. Regarding the pathological margins, we evaluated the incomplete polyp resection (IPR) rate. The polyps were categorized according to the pathological margin status after FCSP or conventional CSP as having a negative margin, an unclear margin, or a positive margin. Polyps for which both the lateral and deep margins were free of the tumor cells were defined as having a negative margin. Polyps for which it was unclear whether the resection margins were involved were defined as having an unclear margin. Polyps for which either or both the lateral margin and the deep margin contained tumor cells were defined as having a positive margin. Finally, IPR was defined as the resection of a lesion with an unclear or a positive pathological margin, as in previous reports [26, 27, 28]. Complete resection was defined as the resection of the lesion with a negative pathological margin [26]. To investigate the potential risk factors for FCSP, we investigated the influence of polyp location, polyp location in the flexural area or not, polyp diameter (<6 mm/≥6 mm), morphology, experience with endoscopy, pathological diagnosis. We used a cutoff polyp diameter of 6 mm, based on a previous report that a polyp diameter ≥6 mm was a risk factor for CSDPs [14, 15, 16]. Clipping after the procedure was not routinely performed; however, hemostatic clipping was performed during the procedure to manage immediate bleeding [29].

Statistical analysis

The results are presented as the mean (SD) or median (range) for quantitative data, and as frequencies (percentages) for categorical data. For categorical data, Fisher's exact test was used to analyze small amounts of data, and the chi-squared test was used to analyze large amounts of data. The Kolmogorov–Smirnov test was used to assess whether the data fit a normal distribution. Normally distributed and non-normally distributed data were compared using a *t* test and the Mann–Whitney *U* test, respectively. Multivariable analysis was performed to determine the risk factors for FCSP. Adjusted odds ratios were converted to risk ratios (RRs) [30]. A *P* value of <0.05 was considered statistically significant. All the statistical analyses were performed using SPSS statistics, version 23 (IBM Corp, Armonk, New York, USA).

Results

Study flow

We performed 1052 colonoscopies in 953 patients from November 2020 to June 2021. We excluded patients in whom colonoscopies were performed but who underwent observation or biopsy only, and patients in whom only HSP and/or EMR was performed. The final analysis was performed on 1315 polyps treated with CSP in 548 patients (see **Fig. 1s** in the online-only Supplementary material). The polyps were divided into two groups according to the procedures performed for polyp resection: the FCSP group (105 polyps) and the conventional CSP group (1210 polyps).

Patient characteristics

The clinical characteristics of the patients are presented in ▶ **Table 1**. The total number of patients was 548 (70 patients in the FCSP group and 478 patients in the conventional CSP group), with a mean age 66.3 (SD 13.3) years in the FCSP group and 68.6 (SD 11.2) years in the conventional CSP group. In all, 89 patients received antithrombotic therapy: 17 patients in the FCSP group and 72 patients in the conventional CSP group.

▶ **Table 1** Clinical characteristics of the patients.

Characteristics of the patients	FCSP group	Conventional CSP group
Patients, n	70	478
Sex (M:F), n	44:26	305:173
Age, mean (SD), years	66.3 (13.3)	68.6 (11.2)
Patients receiving antithrombotic agents, n	17	72
▪ Aspirin	4	12
▪ Clopidogrel	2	10
▪ Cilostazol	1	7
▪ Limaprost alfadex	1	2
▪ Warfarin	1	5
▪ DOAC	5	23
▪ Multiple antithrombotic agents	3	13
Indication for the use of antithrombotic agents, n (%)		
▪ Ischemic heart disease	2 (11.8)	16 (22.2)
▪ Atrial fibrillation	5 (29.4)	25 (34.7)
▪ Cerebrovascular disease	9 (52.9)	27 (37.5)
▪ Preventive medication	1 (5.9)	4 (5.6)

FCSP, forced cold snare polypectomy; CSP, cold snare polypectomy; DOAC, direct oral anticoagulants.

Colorectal polyp characteristics

The colorectal polyp characteristics are presented in ▶ **Table 2**. The total number of polyps resected was 1315 (105 polyps were removed by FCSP, and 1210 polyps were removed by conventional CSP). In all, 7 (6.7%) and 79 (6.5%) of the polyps resected from the FCSP group and conventional CSP group, respectively, were located in the rectum. The mean polyp sizes were 6 (SD 2.1) mm and 4.1 (SD 1.6) mm in the FCSP and conventional CSP groups, respectively. The percentages of patients receiving treatment with antithrombotic agents were 18.1% (19/105) and 17.3% (209/1210) in the FCSP and conventional CSP groups, respectively.

Outcomes of CSPs

The outcomes of FCSP and conventional CSP are presented in ▶ **Table 3**. FCSP was performed on 105 polyps (8%, 105/1315). The total en bloc resection rate was 99.7% (1311/1315). "Conversion to HSP" was required for one polyp (0.08%). The rate of CSDP after the procedures was 96.2% (101/105) and 6.4% (77/1210) in the FCSP and conventional CSP groups, respectively (P<0.001). The rate of CSDP after FCSP was significantly higher than that after conventional CSP. The perforation rate was 0% in both groups. The total delayed post-polypectomy bleeding rate was 0.15% (2/1315). Low grade adenoma was the main histopathological result in both groups. Regarding the pathological

▶ **Table 2** Clinical characteristics of the colorectal polyps.

Characteristics of the polyps	FCSP group	Conventional CSP group
Polyps (N = 1315), n	105	1210
Tumor location, n (%)		
▪ Rectum	7 (6.7)	79 (6.5)
▪ Colon	98 (93.3)	1131 (93.5)
Polyp size, mean (SD), mm	6 (2.1)	4.1 (1.6)
Treatment with antithrombotic agents, n (%)		
▪ Present	19 (18.1)	209 (17.3)
▪ Absent	86 (81.9)	1001 (82.7)

FCSP, forced cold snare polypectomy; CSP, cold snare polypectomy.

▶ **Table 3** Outcomes of forced and conventional cold snare polypectomy.

Outcomes	FCSP group	Conventional CSP group	*P* value
Polyps (N = 1315), n	105 (8.0)	1210 (92.0)	
Resection, n (%)			>0.99
▪ En bloc	105 (100)	1206 (99.7)	
▪ Piecemeal	0 (0)	4 (0.3)	
Conversion to HSP, n (%)			0.08
▪ Yes	1 (1.0)	0 (0)	
▪ No	104 (99.0)	1210 (100)	
CSDP, n (%)			<0.001
▪ Present	101 (96.2)	77 (6.4)	
▪ Absent	4 (3.8)	1133 (93.6)	
Perforation, n (%)			>0.99
▪ Yes	0 (0)	0 (0)	
▪ No	105 (100)	1210 (100)	
Immediate bleeding, n (%)			0.46
▪ Yes	3 (2.9)	23 (1.9)	
▪ No	102 (97.1)	1187 (98.1)	
Clipping after the procedure, n (%)			0.46
▪ Yes	3 (2.9)	23 (1.9)	
▪ No	102 (97.1)	1187 (98.1)	
Delayed post-polypectomy bleeding, n (%)			>0.99
▪ Yes	0 (0)	2 (0.2)	
▪ No	105 (100)	1208 (99.8)	
Histopathology, n (%)			
▪ Low grade adenoma	73 (69.5)	1005 (83.1)	
▪ High grade adenoma	0 (0)	5 (0.4)	
▪ Hyperplastic polyp	6 (5.7)	105 (8.7)	
▪ SSA/P	26 (24.8)	88 (7.3)	
▪ Inflammatory polyp	0 (0)	5 (0.4)	
▪ Adenocarcinoma	0 (0)	0 (0)	
▪ Loss of specimen	0 (0)	2 (0.2)	
Pathological margin (1312 polyps)[1], n (%)			0.02
▪ IPR (unclear, positive)	13 (12.5)	75 (6.2)	
▪ Complete resection (negative)	91 (87.5)	1133 (93.8)	

FCSP, forced cold snare polypectomy; HSP, hot snare polypectomy; CSDP, cold snare defect protrusion; SSA/P, sessile serrated adenoma/polyp; IPR, incomplete polyp resection.
[1]FCSP n = 104 (conversion to HSP for one polyp); conventional CSP n = 1208 (two specimens lost).)

margins, two lesions were lost and one lesion was converted to HSP; therefore, 1312 lesions were included in the analysis. The IPR rate was 12.5% (13/104) and 6.2% (75/1208) in the FCSP and conventional CSP groups, respectively ($P = 0.02$). The risk factors for IPR are shown in **Table 1s**.

Factors associated with FCSP

Univariable analyses were performed to explore the risk factors for FCSP (▶ **Table 4**). Polyps located in the cecum (20.0% [21/105] vs. 10.1% [122/1210]; $P = 0.005$), polyps ≥6 mm in diameter (65.7% [69/105] vs. 15.5% [188/1210]; $P<0.001$), and sessile serrated lesions (hyperplastic polyp and sessile serrated adenoma/polyp, 30.5% [32/105] vs. 16.0% [193/1210]; $P<0.001$) were significantly more likely to be resected with FCSP. There were no significant differences in any of the other variables (location in the flexural area or not, morphology, and experience with endoscopy) between the FCSP group and conventional CSP group.

▶ **Table 4** Univariable analysis to identify risk factors for forced cold snare polypectomy.

Outcomes	FCSP	Conventional CSP	*P* value
Polyps (N = 1315), n (%)	105 (8.0)	1210 (92.0)	
Tumor location, n (%)			0.005
▪ Cecum	21 (20.0)	122 (10.1)	
▪ Others	84 (80.0)	1088 (89.9)	
Flexural area[1], n (%)			0.07
▪ Yes	4 (3.8)	111 (9.2)	
▪ No	101 (96.2)	1099 (90.8)	
Polyp size, n (%)			<0.001
▪ ≥6mm	69 (65.7)	188 (15.5)	
▪ <6mm	36 (34.3)	1022 (84.5)	
Morphology, n (%)			0.21
▪ 0-IIa	71 (67.6)	740 (61.2)	
▪ Others	34 (32.4)	470 (38.8)	
Endoscopist, n (%)			0.61
▪ Trainee	8 (7.6)	119 (9.8)	
▪ Expert	97 (92.4)	1091 (90.2)	
Histopathology, n/N (%)			<0.001
▪ SSL (hyperplastic polyp, SSA/P)	32/105 (30.5)	193/1208 (16)	
▪ Others	73/105 (69.5)	1015/1208 (84)	

FCSP, forced cold snare polypectomy; SSL, sessile serrated lesion; SSA/P, sessile serrated adenoma/polyp.
[1]Hepatic or splenic flexure.

We also performed a multivariable analysis using all the variables included in the univariable analysis (▶ **Table 5**). The multivariable analysis identified polyps located in the cecum (RR, 1.13; 95%CI 1.050–1.179; $P = 0.003$) and polyps ≥6 mm in diameter (RR, 2.37; 95%CI 2.146–2.542; $P<0.001$) as independent risk factors for FCSP. Adjusted odds ratios were converted to RRs to accurately represent the relative risk (**Table 2s**). Although a pathological diagnosis of sessile serrated lesions was identified as a significant factor in the univariable analysis and could therefore be considered a potential risk factor for FCSP, multivariable analysis failed to confirm this factor as a significant independent risk factor for FCSP.

Discussion

Although CSP use has spread rapidly, no studies have been performed on FCSP. Shichijo et al. reported that CSDP was a good indicator of incomplete mucosal resection [15]. In addition, Ishii et al. reported that CSDP was a good indicator of polyp fragmentation [16]. Therefore, the occurrence of CSDPs may result in a poor pathological diagnosis, and CSP without CSDPs is desirable. Our clinical impression is that FCSP often causes CSDPs. If FCSP is truly associated with the development of CSDPs, FCSP should be avoided in order to obtain accurate evaluation of pathological margins. In previous reports, CSDPs occurred in 11.3%–34% of cases [14, 15, 16]. In the current study, the rate of CSDPs after the procedure was 13.5% (178/1315), which is consistent with the findings of previous reports. There is the possibility that FCSP may have been included in previous studies. However, the frequency and safety of FCSP and the IPR rate due to FCSP remained unknown; therefore, we conducted this study, which is the first study to compare the outcomes of FCSP and conventional CSP.

In this study, FCSP was performed on 105 polyps (8% [105/1315]). There was no difference in complication rates such as

▶ **Table 5** Multivariable analysis to identify risk factors for forced cold snare polypectomy.

Factors[1]	RR[2] (95%CI)	*P* value
Polyp location in the cecum	1.13 (1.050–1.179)	0.003
Flexural area[3]	0.98 (0.895–1.016)	0.36
Polyp size ≥6mm	2.37 (2.146–2.542)	<0.001
Morphology (0-IIa)	1.09 (0.781–1.446)	0.59
Endoscopist (trainee)	0.98 (0.901–1.027)	0.49
SSL (hyperplastic polyp, SSA/P)	1.04 (0.881–1.175)	0.57

RR, risk ratio; SSL, sessile serrated lesion; SSA/P, sessile serrated adenoma/polyp; FCSP, forced cold snare polypectomy;.
[1]Multivariable analysis was performed to determine the risk factors for FCSP using the following factors: tumor location, flexural area, polyp size, morphology, endoscopist, histopathology, and FCSP.
[2]We converted adjusted odds ratios (aORs) to risk ratios (RRs) using the following formula: $RR = OR/(1-P_0) + (P_0 \times OR)$, where P_0 indicates the incidence of FCSP in the group without risk factors. The data of aORs are shown in the Supplementary material.
[3]Hepatic or splenic flexure.

perforation, immediate bleeding, and delayed post-polypectomy bleeding between the FCSP and conventional CSP groups. However, the IPR rate and CSDP rate after FCSP were significantly higher than those after conventional CSP. CSDPs occurred in almost all cases of FCSP. As the incidence of CSDPs was high with FCSP, the high IPR rate after FCSP is consistent with the findings of previous reports suggesting that CSDPs are good indicators of IPR [14, 15, 16]. FCSP is associated with a very high probability of CSDPs, and CSDPs are indicators of incomplete mucosal resection and fragmentation of polyps. Therefore, FCSP may be likely to result in IPR. Tutticci et al. reported that CSDPs were associated with polyp size (≥6 mm) [14]. In addition, Shichijo et al. reported that a large polyp size (≥6 mm) and serrated lesions were risk factors for CSDPs [15]; Ishii et al. also reported that CSDPs were significantly associated with large polyp size and large specimen size [16]. The results of these reports about risk factors for CSDPs are consistent with the risk factors for FCSP identified in our study. Therefore, these previous studies describing CSDPs may have also included a certain proportion of FCSP procedures. Avoidance of CSDPs is desirable for prevention of polyp fragmentation, and avoidance of FCSP is desirable for prevention of CSDPs. In other words, avoiding FCSP may reduce the incidence of CSDPs and IPR. Therefore, FCSP and conventional CSP should be considered separately rather than focusing only on the presence or absence of CSDPs.

Regarding the risk factors for FCSP, polyps located in the cecum, polyps ≥6 mm in diameter, and a pathological diagnosis of sessile serrated lesions were identified as risk factors for FCSP. Multivariable analysis identified polyps located in the cecum and polyps ≥6 mm in diameter as independent risk factors for FCSP. In addition, adjusted odds ratios were converted to RRs to accurately represent the relative risk, which is very close to the true RR. Although a pathological diagnosis of sessile serrated lesions was identified as a significant factor in the univariable analysis and therefore may be considered a potential risk factor for FCSP, the multivariable analysis failed to confirm this factor as a significant independent risk factor for FCSP. Shichijo et al. also reported that large polyp size (≥6 mm) and a serrated lesion type were risk factors for CSDPs [15]; this is consistent with the risk factors for FCSP identified in the current study. In addition, they considered that CSDPs occur when the grasped tissue is stiff and difficult to transect because the snare can transect less stiff tissue with mechanical pressure alone; thus, stiff tissue may remain in situ. We agree and have experienced that FCSP is needed when too much tissue is grasped. When we remove large polyps with CSP, a large amount of tissue tends to be grasped with the snare. The presence of a polyp ≥6 mm in diameter and a polyp location in the cecum are understandably risk factors for FCSP. As the cecum contains considerable amounts of fat, a large amount of tissue tends to be grasped with the snare. In addition, the cecum is a known area of involvement in infectious diseases, which can cause various inflammatory changes. Chiba et al. reported that cecal lesions are more likely to have fibrosis in endoscopic procedures [31]. CSP for cecal polyps may often require FCSP because the grasped tissue is stiff due to fibrosis. A pathological diagnosis of sessile serrated lesions was considered a potential risk factor for FCSP. Serrated lesions have pathological changes in the basal crypts, which may affect the difficulty in performing CSP with snaring alone.

Although polyps located in the cecum and polyps ≥6 mm in diameter were identified as independent risk factors for FCSP, these types of polyps may not be outside of the indications for CSP. It is important to be aware of the risk factors for FCSP and to make an effort to avoid FCSP. Although it is important to obtain a sufficient margin to ensure complete resection, it is also important not to take excessively wide margins so that FCSP can be avoided. In addition, for situations in which the colorectal tract is tense due to overinflation, the snare may slip; therefore, therefore, suctioning the air from the colorectal tract and snaring may be performed. However, excessive suctioning tends to result in the muscularis mucosa being grasped, and the grasped tissue may become stiff. It is important to maintain moderate air volume and colorectal wall tension to avoid FCSP. Furthermore, additional education for assistants and improved devices may also be important in avoiding FCSP.

This study had several limitations. First, it was a single-center study; nonetheless, this is the first study to evaluate the outcomes of FCSP. Second, the number of CSPs performed using a dedicated snare was limited. Therefore, although it has been reported that type of snare can affect the completeness of resection [26], we could not assess the impact of snare type in this study. Third, no previous reports on FCSP have been published; therefore, it was difficult to accurately calculate the sample size, and the frequency of FCSP was lower than expected. Fourth, it is uncertain whether IPR as defined in this study is associated with post-colonoscopy colorectal cancer. Bearing in mind these limitations, we would like to perform a prospective, multicenter trial to confirm our results.

In conclusion, FCSP was performed on 105 polyps (8%) in this study. There is the possibility that FCSP is associated with the occurrence of CSDPs and IPR. Avoiding FCSP in order to prevent the occurrence of CSDPs and obtaining an accurate pathological diagnosis are desirable. Prospective, multicenter studies are necessary in the future to confirm our results.

Acknowledgement

The authors would like to thank the staff of the participating institutions for their support in recruiting eligible patients, and also the patients who participated in this study.

Conflict of Interest

The authors declare that they have no conflict of interest.

Clinical trial

Trial Registration: UMIN Japan (http://www.umin.ac.jp/english/) | Registration number (trial ID): UMIN000041718 | Type of study: Prospective, observational study

References

[1] Shaukat A, Mongin SJ, Geisser MS et al. Long-term mortality after screening for colorectal cancer. N Engl J Med 2013; 369: 1106–1114 doi:10.1056/NEJMoa1300720

[2] Zauber AG, Winawer SJ, O'Brien MJ et al. Colonoscopic polypectomy and long-term prevention of colorectal-cancer deaths. N Engl J Med 2012; 366: 687–696 doi:10.1056/NEJMoa1100370

[3] Winawer SJ, Zauber AG, Ho MN et al. Prevention of colorectal cancer by colonoscopic polypectomy. The National Polyp Study Workgroup. N Engl J Med 1993; 329: 1977–1981 doi:10.1056/NEJM199312303292701

[4] Levin TR, Zhao W, Conell C et al. Complications of colonoscopy in an integrated health care delivery system. Ann Intern Med 2006; 145: 880–886 doi:10.7326/0003-4819-145-12-200612190-00004

[5] Watabe H, Yamaji Y, Okamoto M et al. Risk assessment for delayed hemorrhagic complication of colonic polypectomy: polyp-related factors and patient-related factors. Gastrointest Endosc 2006; 64: 73–78 doi:10.1016/j.gie.2006.02.054

[6] Sonnenberg A. Management of delayed postpolypectomy bleeding: a decision analysis. Am J Gastroenterol 2012; 107: 339–342 doi:10.1038/ajg.2011.426

[7] Takeuchi Y, Yamashina T, Matsuura N et al. Feasibility of cold snare polypectomy in Japan: a pilot study. World J Gastrointest Endosc 2015; 7: 1250–1256 doi:10.4253/wjge.v7.i17.1250

[8] Yamashina T, Fukuhara M, Maruo T et al. Cold snare polypectomy reduced delayed postpolypectomy bleeding compared with conventional hot polypectomy: a propensity score-matching analysis. Endosc Int Open 2017; 5: E587–594

[9] Arimoto J, Chiba H, Ashikari K et al. Safety of cold snare polypectomy in patients receiving treatment with antithrombotic agents. Dig Dis Sci 2019; 64: 3247–3255

[10] Ichise Y, Horiuchi A, Nakayama Y et al. Prospective randomized comparison of cold snare polypectomy and conventional polypectomy for small colorectal polyps. Digestion 2011; 84: 78–81 doi:10.1159/000323959

[11] Fujiya M, Sato H, Ueno N et al. Efficacy and adverse events of cold vs. hot polypectomy: a meta-analysis. World J Gastroenterol 2016; 22: 5436–5444 doi:10.3748/wjg.v22.i23.5436

[12] Ogasawara N, Takayama M, Ono S et al. A case of colonic stenosis caused by cold snare polypectomy for the removal of a colonic polyp. Clin J Gastroenterol 2017; 10: 415–419 doi:10.1007/s12328-017-0765-9

[13] Sanchez JR, Alonso MS, Urquiza MP. The "bubble sign": a novel way to detect a perforation after cold snare polypectomy. Endoscopy 2019; 51: 796–797

[14] Tutticci N, Burgess NG, Pellise M et al. Characterization and significance of protrusions in the mucosal defect after cold snare polypectomy. Gastrointest Endosc 2015; 82: 523–528 doi:10.1016/j.gie.2015.01.051

[15] Shichijo S, Takeuchi Y, Kitamura M et al. Does cold snare polypectomy completely resect the mucosal layer? A prospective single-center observational trial J Gastroenterol Hepatol 2020; 35: 241–248

[16] Ishii T, Harada T, Tanuma T et al. Histopathologic features and fragmentation of polyps with cold snare defect protrusions. Gastrointest Endosc 2021; 93: 952–959

[17] The Paris endoscopic classification of superficial neoplastic lesions: esophagus, stomach, and colon: November 30 to December 1, 2002. Gastrointest Endosc 2003; 58: (Suppl. 06): S3–43 doi:10.1016/s0016-5107(03)02159-x

[18] Endoscopic Classification Review Group. Update on the Paris classification of superficial neoplastic lesions in the digestive tract. Endoscopy 2005; 37: 570–578 doi:10.1055/s-2005-861352

[19] Bret J, Mark B, Patrick R et al. Colonoscopy training in gastroenterology fellowships: determining competence. Gastrointest Endosc 2010; 71: 319–324

[20] Arimoto J, Chiba H, Ashikari K et al. Safety and efficacy of cold snare polypectomy for pedunculated (Ip) polyps measuring less than 10 mm in diameter. Int J Colorectal Dis 2020; 35: 859–867

[21] Arimoto J, Chiba H, Ashikari K et al. Management of less than 10-mm-sized pedunculated polyps with thin stalk: hot snare polypectomy versus cold snare polypectomy. Dig Dis Sci 2021; 66: 2353–2361

[22] Arimoto J, Chiba H, Tachikawa J et al. Evaluation of cold snare polypectomy for small pedunculated (Ip) polyps with thin stalks: a prospective clinical feasibility study. Scand J Gastroenterol 2022; 57: 253–259

[23] Horiuchi A, Nakayama Y, Kajiyama M et al. Removal of small colorectal polyps in anticoagulated patients: a prospective randomized comparison of cold snare and conventional polypectomy. Gastrointest Endosc 2014; 79: 417–423 doi:10.1016/j.gie.2013.08.040

[24] Arimoto J, Higurashi T, Chiba H et al. Continued use of a single antiplatelet agent does not increase the risk of delayed bleeding after colorectal endoscopic submucosal dissection. Dig Dis Sci 2018; 63: 218–227

[25] Tajiri H, Kitano S. Complication associated with endoscopic mucosal resection: definition of bleeding that can be viewed as accidental. Dig Endosc 2004; 16: S134–136

[26] Horiuchi A, Hosoi K, Kajiyama M et al. Prospective, randomized comparison of 2 methods of cold snare polypectomy for small colorectal polyps. Gastrointest Endosc 2015; 4: 686–692 doi:10.1016/j.gie.2015.02.012

[27] Arimoto J, Chiba H, Higurashi T et al. Risk factors for incomplete polyp resection after cold snare polypectomy. Int J Colorectal Dis 2019; 34: 1563–1569 doi:10.1007/s00384-019-03347-6

[28] Arimoto J, Higurashi T, Chiba H et al. Investigation of the local recurrence rate after colorectal endoscopic mucosal resection: is incomplete polyp resection really a clinically important problem? Analysis of the rationale for the "resect and discard" strategy Can J Gastroenterol Hepatol 2019; 8: 7243515

[29] Repici A, Hassan C, Vietta E et al. Safety of cold polypectomy for <10 mm polyps at colonoscopy: a prospective multicenter study. Endoscopy 2012; 44: 27–31

[30] Zhang J, Yu KF. What's the relative risk? A method of correcting the odds ratio in cohort studies of common outcomes JAMA 1998; 280: 1690–1691 doi:10.1001/jama.280.19.1690

[31] Chiba H, Tachikawa J, Arimoto J et al. Predictive factors of mild and severe fibrosis in colorectal endoscopic submucosal dissection. Dig Dis Sci 2020; 65: 232–242 doi:10.1007/s10620-019-05735-y