

# Intrathecal Therapy Options for Meningeal Carcinomatosis

## Intrathekale Therapieoptionen bei Meningeosis carcinomatosa



### Authors

Madeleine Marowsky<sup>1</sup>, Volkmar Müller<sup>1</sup>, Barbara Schmalfeldt<sup>1</sup>, Kerstin Riecke<sup>1</sup>, Isabell Witzel<sup>2</sup>, Elena Laakmann<sup>1</sup>

### Affiliations

- 1 Klinik und Poliklinik für Gynäkologie, Universitätsklinikum Hamburg-Eppendorf, Hamburg, Germany
- 2 Klinik für Gynäkologie, Universitätsspital Zürich, Universität Zürich, Zürich, Switzerland

### Key words

meningeal carcinomatosis, intrathecal therapy, methotrexate, cytarabine, trastuzumab

### Schlüsselwörter

Meningeosis carcinomatosa, intrathekale Behandlung, Methotrexat, Cytarabin, Trastuzumab

received 27.8.2023

accepted after revision 29.9.2023

published online 8.11.2023

### Bibliography

Geburtsh Frauenheilk 2024; 84: 59–67

DOI 10.1055/a-2185-0457

ISSN 0016-5751

© 2023. The Author(s).

This is an open access article published by Thieme under the terms of the Creative Commons Attribution-NonDerivative-NonCommercial-License, permitting copying and reproduction so long as the original work is given appropriate credit. Contents may not be used for commercial purposes, or adapted, remixed, transformed or built upon. (<https://creativecommons.org/licenses/by-nc-nd/4.0/>).

Georg Thieme Verlag KG, Rüdigerstraße 14, 70469 Stuttgart, Germany

### Correspondence

Dr. Elena Laakmann  
Klinik und Poliklinik für Gynäkologie  
Universitätsklinikum Hamburg-Eppendorf  
Martinistraße 52  
20246 Hamburg, Germany  
[e.laakmann@uke.de](mailto:e.laakmann@uke.de)

Deutsche Version unter:  
<https://doi.org/10.1055/a-2185-0457>.

### ABSTRACT

Around 5 percent of all patients with metastatic breast cancer go on to develop distant metastases in the meninges, also known as meningeal carcinomatosis. The median survival of

these patients is between 3.5 and 4.5 months. Current treatment approaches are based on radiotherapy, systemic and intrathecal therapy. Methotrexate, liposomal cytarabine and trastuzumab are the most common substances used for intrathecal therapy. The aim of this review was to provide an overview of these intrathecal therapy options for meningeal carcinomatosis. A systematic search of the literature was carried out in PubMed using the following search terms: “meningeal metastases”, “meningeal carcinomatosis”, “leptomeningeal metastasis”, “leptomeningeal carcinomatosis”, “leptomeningeal disease”, “breast cancer”, “MTX”, “methotrexate”, “DepoCyt”, “liposomal cytarabine”, “trastuzumab” and “anti-HER2”. This search resulted in 75 potentially relevant studies, 11 of which were included in this review after meeting the previously determined inclusion and exclusion criteria. The studies differ considerably with regards to study design, cohort size, and dosages of administered drugs. In principle, intrathecal therapy has a tolerable side-effects profile and offers promising results in terms of the median overall survival following treatment with trastuzumab for HER2-positive primary tumors. The focus when treating meningeal carcinomatosis must be on providing a multimodal individual therapeutic approach. However, comprehensive studies which compare the efficacy and side effects of individual pharmaceuticals are lacking. Because of the poor prognosis associated with meningeal carcinomatosis, an approach which treats only the symptoms (best supportive care) should always be considered and discussed with affected patients.

### ZUSAMMENFASSUNG

Bei etwa 5 Prozent aller Patientinnen mit metastasiertem Mammakarzinom kommt es zu einer Fernmetastasierung in die Hirnhäute, der sogenannten Meningeosis carcinomatosa. Das mediane Überleben dieser Patientinnen liegt bei 3,5 bis 4,5 Monaten. Aktuelle Therapieansätze basieren auf einer strahlentherapeutischen, systemischen sowie intrathekalen Behandlung. Für letzteres sind unter anderem die Wirkstoffe Methotrexat, liposomales Cytarabin und Trastuzumab erhältlich. Ziel dieser Übersichtsarbeit ist es, einen Überblick über diese intrathekalen Therapieoptionen bei der Meningeosis carcinomatosa zu geben. Dafür wurde eine systematische Literaturrecherche in der Datenbank PubMed mittels folgender Begriffe durchgeführt: „meningeal metastases“, „meningeal carcinomatosis“, „leptomeningeal metastasis“, „leptomeningeal

carcinomatosis“, „leptomeningeal disease“, „breast cancer“, „MTX“, „Methotrexate“, „DepoCyte“, „liposomal cytarabine“, „Trastuzumab“ und „Anti-HER2“. Hieraus ergaben sich 75 potenziell relevante Studien, von denen nach den zuvor festgelegten Ein- und Ausschlusskriterien 11 in diese Übersichtsarbeit eingeschlossen wurden. Die Studien variieren stark in Bezug auf das Studiendesign, die Kollektivgröße sowie verwendete Dosierungen der Arzneimittel. Die intrathekale Therapie zeigt grundsätzlich ein tolerierbares Nebenwirkungsprofil mit vielversprechenden Ergebnissen im Hinblick auf das me-

diane Gesamtüberleben für den Arzneistoff Trastuzumab bei HER2-positiven Primärtumoren. Ein multimodaler individueller Ansatz der Therapie sollte im Fokus bei der Behandlung der Meningeosis carcinomatosa stehen. Es mangelt allerdings an Studien, um Wirkungen und Nebenwirkungen der einzelnen Arzneistoffe fundiert vergleichen zu können. Aufgrund der schlechten Prognose der Meningeosis carcinomatosa sollte ein rein symptomatischer Therapieansatz (Best Supportive Care) immer in Betracht gezogen und mit den Patientinnen diskutiert werden.

## Introduction

According to the Center for Cancer Registry Data of the Robert Koch Institute, breast cancer is the most common cancer in women in Germany, with around 70 000 new cases occurring every year [1]. This means that statistically every eighth woman will develop breast cancer in her lifetime. Men are affected significantly less often with just 720 new cases per year, which corresponds to around 1% of all new cases of breast cancer annually [1]. Important factors affecting prognosis include the extent tumor spread (TNM classification) and the tumor biology at diagnosis. The course of disease depends materially on whether distant metastasis is present or not [2]. Five percent of all cases go on to develop meningeal carcinomatosis, i.e., distant metastases in the meninges [3]. Because of the high incidence of breast cancer worldwide, breast cancer is the most common primary tumor associated with meningeal carcinomatosis [3, 4, 5, 6]. Median patient survival after distant metastasis of a solid tumor in the meninges has been diagnosed is between 3.5 and 4.5 months [7, 8, 9]. This poor prognosis is why a successful treatment strategy is so important for meningeal carcinomatosis. According to the recommendations of the German Gynecological Oncology Working Group (AGO), there are three different options to treat meningeal carcinomatosis [10]. Radiotherapy is one option. If radiotherapy is chosen, it can consist of focal, whole brain or neuraxial radiation therapy, depending on the location of the metastases [10]. The second treatment approach is systemic chemotherapy. To treat meningeal carcinomatosis effectively with systemically administered cytostatic agents, the drugs must be able to cross the blood-brain barrier. Because this requirement makes it more difficult to administer systemic chemotherapy, there is a third treatment option: intrathecal chemotherapy. The choice of drugs used for intrathecal therapy includes methotrexate as well as trastuzumab for HER-2 positive primary tumors [10]. A number of studies have also reported using cytarabine [11, 12, 13]. Cytarabine is administered in the form of liposomal depots (DepoCyte) to ensure sustained maintenance of the cytotoxic concentration of the agent in cerebrospinal fluid [14]. Cytarabine is currently no longer available in Europe. This review aims to provide an overview of intrathecal therapy options for meningeal carcinomatosis along with the range of associated side effects. However, in view of the poor prognosis of meningeal carcinomatosis, whether treatment is indicated must be weighed

```
(Meningeal metastases [Title/Abstract]) OR
(meningeal carcinomatosis [Title/Abstract]) OR
(leptomeningeal metastasis [Title/Abstract]) OR
(leptomeningeal carcinomatosis [Title/Abstract]) OR
(leptomeningeal disease [Title/Abstract])
AND (breast cancer [Title/Abstract])
AND (MTX [Title/Abstract]) OR
(Methotrexate [Title/Abstract]) OR
(DepoCyte [Title/Abstract]) OR
(liposomal cytarabine [Title/Abstract]) OR
(Trastuzumab [Title/Abstract]) OR
(Anti-HER2 [Title/Abstract])
```

► Fig. 1 Search strategy.

up very carefully; a palliative treatment approach should always also be considered and should be discussed with the patient [10].

## Review

### Method

A systematic search of the literature in PubMed was carried out on 16 September 2022. The only publications included in this review were published after 2010 in English or German. Publications where the primary tumor of the patient cohort was breast cancer and patients were diagnosed with meningeal carcinomatosis were included. Exclusion criteria were no intrathecal drug administration or medications which differed from those previously decided on at the start of the review.

The systematic search of the literature in PubMed was carried out in English using the following terms: “meningeal metastases”, “meningeal carcinomatosis”, “leptomeningeal metastasis”, “leptomeningeal carcinomatosis”, “leptomeningeal disease”, “breast cancer”, “MTX”, “methotrexate”, “DepoCyte”, “liposomal cytarabine”, “trastuzumab” and “anti-HER2”. The detailed search strategy is shown in ► Fig. 1.

The systematic search of the literature in the PubMed database using the search strategy shown in ► Fig. 1 resulted in 75 potentially relevant search results. Based on previously determined exclusion criteria, 56 studies were excluded after their titles and

abstracts were reviewed or were removed due to duplication. The remaining 19 studies were evaluated using the full text. Eleven studies, which included a total of 763 patients, were ultimately included in the review (► Fig. 2). The study design, the size of the patient cohort, and the investigated parameters varied strongly (► Table 1).

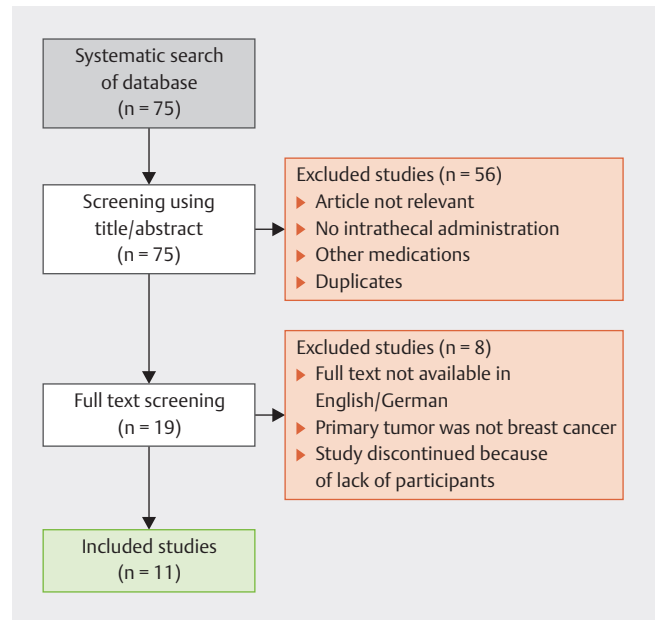
### Forms of administration

All included studies used intrathecal therapy, although the studies differed in the chosen form of administration. 202 patients received intrathecal therapy administered by means of recurrent lumbar punctures [13, 17, 18, 20]. 54 patients received the drugs through a ventricular reservoir, and Oberkamp et al., Freyer et al. and Figura et al. explicitly reported that they used an Ommaya reservoir [13, 17, 21, 22]. Four studies included no further information on how the drug was administered intrathecally [12, 15, 19, 23].

Overall, administration-related side effects were rarely investigated in the studies. Le Rhun et al. reported that no reservoir-induced meningitis was observed and none of the reservoirs required revision [13]. Figura et al. reported an infection of the Ommaya reservoir in two patients, requiring removal of the shunt, administration of intravenous antibiotics and shunt replacement with resumption of intrathecal therapy after the infection had been eliminated [22]. According to the literature, an Ommaya reservoir should, in principle, ensure a more homogeneous diffusion in cerebrospinal fluid than a lumbar puncture [24, 25].

### Methotrexate

Both Gauthier et al. and the case report by Meissner and Addeo investigated the option of intrathecal (IT) methotrexate [19, 20]. Two studies compared methotrexate with other treatment options [18, 22]. They are described in more detail under the heading “Comparison of intrathecal substances”. In the clinical study by Gauthier et al., the mean age of patients was 53 years (range: 30–78). Most patients had hormone receptor-positive HER2-negative



► Fig. 2 Flow chart of the selection process, number = n.

tumor biology (70% ER-positive; 44% PR-positive; 10% HER2-positive). 78% of patients additionally received systemic therapy based on the treatment they had previously received. 29% additionally received cerebral, spinal or combined radiotherapy [20]. The combination of cerebrospinal radiotherapy with intrathecal administration was also used in the two cases presented by Meissner and Addeo [19]. However, the methotrexate dose in the case report by Meissner and Addeo was 12.5 mg once a week for 6 to 8 weeks [19]. In contrast, Gauthier et al. administered 15 mg/day methotrexate (on days 1–5), hydrocortisone acetate (on day 1 to prevent arachnoiditis) and oral folinic acid (on days 1–5), and this regimen was repeated every two weeks. The administration of methotrexate was continued until neurological progression or recurrence

► Table 1 Study characteristics.

Author (year)	Study design	N	Intrathecal drugs	Investigated parameters	Results
Zagouri et al. (2020) [15]	Meta-analysis	24 studies, 58 patients	Trastuzumab monotherapy (n = 20) Combined with systemic therapy (n = 37)	Clinical development OS PFS-CNS Cerebrospinal fluid MRI Evaluation was carried out for the entire cohort	Clinical symptoms: significant improvement in 55% OS: 13.2 months PFS-CNS: 5.2 months CSF: response 55.6%, MRI: improvement/stable 70.8% An evaluation of the group with trastuzumab monotherapy or combined with other systemic therapies was not carried out.
Pappa et al. (2019) [16]	Case report	1 patient	Trastuzumab	Side effects	Possible drug-induced aseptic meningitis
Oberkamp et al. (2022) [17]	Phase II study	19 patients	Trastuzumab	PFS-CNS OS Toxicity Quality of life	PFS: 5.9 months OS: 7.9 months CTCAE toxicity: < 3 Quality of life: stable

►Table 1 continued

Author (year)	Study design	N	Intrathecal drugs	Investigated parameters	Results
Niwińska et al. (2015) [18]	Observational study	149 patients (96 had intrathecal therapy)	MTX (n = 81) vs. liposomal cytarabine (n = 15); Systemic therapy (n = 77) vs. no systemic therapy (n = 72); WBRT vs. no WBRT	OS	OS: MTX: 4.2 months Liposomal cytarabine: 4.6 months Systemic therapy: 6 months No systemic therapy: 2 months WBRT: 4.6 months No WBRT: 3.2 months
Meissner and Addeo (2016) [19]	Case report	2 patients	MTX + radiotherapy	OS	OS: case 1: 17 years case 2: 8 years
Le Rhun et al. (2020) [13]	Randomized controlled study	73 patients (37 in control group; 36 in treatment group)	Syst. therapy (control group) vs. liposomal cytarabine + syst. therapy (treatment group)	OS Quality of life	OS: control group: 4 months* treatment group: 7.3 months* HR = 0.55, 95% CI: 0.31–0.96, p = 0.04 No difference in quality of life
Laakmann et al. (2017) [12]	Case report	2 patients	Liposomal cytarabine	PFS	PFS-CNS case 1: 73 days case 2: 18+ months
Gauthier et al. (2010) [20]	Clinical trial	91 patients	MTX + hydrocortisone acetate + folinic acid (oral)	OS Prognostic factors	Median survival: 4.5 months, Unfavorable prognostic factors at diagnosis: performance status, more than 3 chemotherapies prior to MC diagnosis, negative hormone receptor status, high CYFRA 21–1 level
Freyer et al. (2014) [21]	Case report	1 patient	Trastuzumab	Side effects	Possible drug-induced aseptic meningitis
Figura et al. (2019) [22]	Comparative study	56 patients	Trastuzumab (n = 18) Methotrexate (n = 14) Thiotepa (n = 1) WBRT alone (n = 23)	PFS-CNS	Significant difference in PFS-CNS 6-month survival rates of 44%, 18% and 26% for IT trastuzumab, IT chemotherapy (MTX or thiotepa) and WBRT, respectively
Carausu et al. (2021) [23]	Retrospective analysis	312 patients	MTX/thiotepa/cytarabine	OS Prognostic factors	OS: MTX: 5.2 months* thiotepa/cytarabine: 3.5 months* HR 1.68, 95% CI: 1.28–2.22; p < 0.001 Prognostic factors: triple-negative tumor biology ≥ 3 treatment lines prior to IT therapy ≥ 3 metastases IT thiotepa/cytarabine instead of MTX

CFS = cerebrospinal fluid; CTCAE = Common Terminology Criteria of Adverse Events; IT = intrathecal; MC = meningeal carcinomatosis; MTX = methotrexate; OS = overall survival; PFS-CNS = progression-free survival-central nervous system; WBRT = whole brain radiotherapy

\* statistically significant

occurred or as long as the patient's general state of health was compatible with further treatment [20].

At the time of drafting the article, the two patients of Meissner and Addeo had already survived 8 and 17 years, respectively, after completing treatment, and they were in complete clinical and radiological remission at the time of publication [19]. Gauthier et al. reported a median survival of 4.5 months (range 0–53 months) [20]. In the case report by Meissner and Addeo, IT methotrexate was generally tolerated very well with no serious side effects [19]. The retrospective comparative study by Figura et al. reported

on a case with possibly chemically-induced meningitis as a consequence of IT methotrexate therapy, which was treated with steroids [22].

### Liposomal cytarabine

Le Rhun et al. and Laakmann et al. reported on the intrathecal administration of liposomal cytarabine [12, 13]. The overwhelming majority of patients had breast cancer with hormone receptor-positive, HER2-negative tumor biology. In a randomized controlled study, Le Rhun et al. compared systemic monotherapy with sys-

temic therapy combined with IT liposomal cytarabine. The systemic therapy was selected prior to randomization according to the molecular tumor characteristics, prior treatment lines and the patient's general state of health. The mean age of their patient cohort on inclusion in the study was 50.2 years (range: 29.7–84.1), and the primary tumor was usually invasive non-special type (NST) breast cancer [13]. A dosage of 50 mg IT liposomal cytarabine administered every 14 days was used in both the randomized controlled study and in the case report by Laakmann et al. [12, 13]. The two cases presented by Laakmann et al. additionally received systemic therapy and radiotherapy [12].

Evaluation of the randomized controlled study showed that the addition of IT liposomal cytarabine to systemic therapy improved the progression-free interval for the central nervous system (PFS-CNS) (control group: median PFS-CNS 2.2 months; treatment group: median PFS-CNS 3.8 months). The median overall survival was 4.0 months (95% CI: 2.2–6.3 months) for the control group compared to 7.3 months (95% CI: 3.9–9.6 months) for the treatment group [13]. In the case report by Laakmann et al., case 1 had an overall survival of 79 days and case 2 had progression-free survival of more than 18 months. Both cases of Laakmann et al. showed rapid neurological response to therapy. According to the authors, this could be due to the rapid start of multimodal treatment following the diagnosis [12].

Infections classified as grade 3 or higher according to the Common Terminology Criteria of Adverse Events (CTCAE) were detected in 11% of the patients of Le Rhun et al. The most common CTCAE grade 3 toxicities were hematological side effects (72%), typically consisting of decreased lymphocyte numbers as well as one case with neutropenia [13]. Laakmann et al. additionally reported that case 2 experienced headache, nausea, dizziness, and double vision during treatment. Overall, however, therapy was well tolerated [12].

## Trastuzumab

Four studies investigated the use of IT trastuzumab in cases whose primary tumor was HER2-positive breast cancer [15, 16, 17, 21]. Despite the considerable variations in study designs, the meta-analysis of Zagouri et al. and the phase II study by Oberkampff et al. showed similarities in terms of their patient cohorts. Mean patient age at the start of the therapy was 50.7 years (range: 24–80 years) [15] and 51.2 years (range: 34.8–70.7), respectively [17]. All patients in both studies had HER2-positive breast cancer as their primary tumor. 32% of the patients of Oberkampff et al. were treated with IT methotrexate, IT liposomal cytarabine or IT thiotepe before receiving IT trastuzumab [17]. In the patient cohort of Zagouri et al., 21.7% had previously received methotrexate administered either intravenously or intrathecally [15]. Only 34.5% of patients in the study by Zagouri et al. and 32% in the phase II study received no additional therapy for meningeal carcinomatosis during IT trastuzumab therapy [15, 17]. In addition to IT trastuzumab, most cases in the study by Zagouri et al. and the study by Oberkampff et al. received some form of systemic therapy consisting of chemotherapy, endocrine or anti-HER2 targeted therapy as well as radiotherapy of the brain. Oberkampff et al. administered 150 mg trastuzumab every week intrathecally for a period of 8 weeks. The

administered dose of 150 mg was determined in the phase I study of Bonneau et al. [26]. In their study, the maximum dose used to achieve the desired concentration in cerebrospinal fluid was 150 mg and there were no cases of dose-limiting toxicity [26]. The meta-analysis included numerous studies which meant that dosages differed considerably as did the periods of administration. Zagouri et al. therefore reported a mean total dose of intrathecally administered trastuzumab of 711.9 mg (SD 634.9, median 450). By comparison, the calculated total dose in the study by Oberkampff et al. was 1200 mg ( $8 \times 150$  mg).

The meta-analysis by Zagouri et al. showed that treatment led to a significant clinical improvement in 55% of patients. MR imaging showed partial remission or stable status in 70.8% of cases. A response in cerebrospinal fluid was found in 55.6% of cases. Median overall survival was 13.2 months and PFS-CNS was 5.2 months [15]. Oberkampff et al. found that after 8 weeks of treatment 74% of patients ( $n = 14$ ) had no clinical neurological progression. The median PFS-CNS was 5.9 months and the median overall survival was 7.9 months [17].

Both Oberkampff et al. and Zagouri et al. reported that the overall safety profile of IT trastuzumab was tolerable [15, 17]. The meta-analysis showed that there were no serious adverse events in 87.9% of cases. No toxicity higher than grade 3 CTCAE occurred [15]. Side effects which may have been related to the treatment included: headache, seizures, and allergic reactions. These occurred in 5% of cases [17]. Independently from one another, Freyer et al. and Pappa et al. reported the occurrence of drug-induced aseptic meningitis, probably induced by trastuzumab [16, 21]. Following the diagnosis of drug-induced aseptic meningitis, Freyer et al. discontinued treatment with intrathecal trastuzumab in a 43-year-old patient. The patient had received an initial dose of 30 mg IT trastuzumab through an Ommaya reservoir and developed the first symptoms within two hours of starting treatment [21]. In contrast, Pappa et al. reported that treatment could be continued despite the occurrence of side effects from IT trastuzumab administration. The 36-year-old patient in their case report received 150 mg IT trastuzumab every week for a period of 8 weeks. After the fifth injection, the patient was diagnosed with drug-induced meningitis. As the therapy was successful, treatment with IT trastuzumab was continued without further adverse events [16].

## Comparison of intrathecal substances

Figura et al. found significant differences in PFS-CNS, with 6-month rates of 44%, 18% and 26% ( $p = 0.04$ ) for IT trastuzumab, IT chemotherapy (methotrexate or thiotepe) and whole brain radiotherapy, respectively. The 6- and 12-month overall survival rates were 67% and 39%, 31% and 54%, and 10% and 19% for IT trastuzumab therapy, IT chemotherapy and whole brain radiotherapy alone. There were no significant differences between the three treatment groups with regards to patient age, Karnofsky Performance Status, the presence of parenchymatous cerebral metastases or the administration of systemic therapy at the time of treatment for meningeal carcinomatosis. The primary tumor of most patients in the IT trastuzumab treatment group was hormone receptor-positive and HER2-positive breast cancer. The



primary tumor of patients in the other two groups was hormone receptor-positive and HER2-negative breast cancer. IT methotrexate was administered at a dosage of 12 mg per week. One patient received 10 mg thiotepa twice a week. Most patients ( $n = 20$ ; 87%) who received whole brain radiotherapy received 30 Gy in 10 fractions or 37.5 Gy in 15 fractions. IT trastuzumab was initially administered in doses of between 20 and 50 mg. Patients received IT trastuzumab twice a week for four weeks, then weekly for four weeks and finally every two weeks for four weeks. After the initial treatment phase, patients usually continued to receive treatment consisting of 80 mg every 2 weeks or once a month [22]. This was the lowest administered maximum dose in all of the studies included in this review. In the phase II study by Oberkampff et al., patients received 150 mg per week and the efficacy and side effects profile was similar [17].

In their prospective observational study, Niwińska et al. investigated the efficacy of different treatment strategies in 149 patients with meningeal carcinomatosis [18]. The study differentiated between patients who received liposomal cytarabine ( $n = 15$ ) and those who received methotrexate ( $n = 81$ ). A multimodal treatment strategy was used for all patients, meaning that most patients received systemic therapy ( $n = 77$ ) or radiotherapy ( $n = 92$ ) in addition to intrathecal therapy. Systemic therapy was individually adapted to patients' general state of health and the respective tumor biology of the breast cancer. The overwhelming majority of patients had hormone receptor-positive, HER2-negative breast cancer. Methotrexate was administered twice a week at a dose of 10 mg including 4 mg dexamethasone in the first two weeks and then, after clinical improvement, once a week until a total dose of 150 mg was reached. Liposomal cytarabine was administered at a dose of 50 mg every 2 weeks for a total of 5 sessions and was then administered once every 4 weeks until disease progression occurred. Niwińska et al. concluded that of all the treatment methods, only systemic therapy prolonged survival in the patient cohort they studied. The overall survival (OS) of patients treated with intrathecal methotrexate and of patients who received liposomal cytarabine was comparable (IT methotrexate = 4.2 months; IT liposomal cytarabine = 4.6 months). The OS of patients who received systemic therapy was 6 months whereas the OS of patients who did not receive systemic therapy was only 2 months [18]. The case report of Laakmann et al. and the prospective observational study of Le Rhun et al. also studied overall survival following the administration of liposomal cytarabine. The results reported by Niwińska et al. differ from those reported by Laakmann et al. and Le Rhun et al. In their studies, the authors found that the use of IT liposomal cytarabine led to a significant prolongation of the originally expected median overall survival [12, 13].

Carausa et al. also reported contrary findings in their study and their results are discussed in more detail in the chapter "Prognostic factors". The use of IT cytarabine or thiotepa in the study by Carausu et al. resulted in an overall survival of 3.5 months, whereas the administration of intrathecal methotrexate resulted in an overall survival of 5.1 months. No detailed information on the dosages and time periods of the treatment regimen are provided [23].

► **Table 2** Prognostic factors.

Prognostic factor	Wertung
<b>Curie score (Gauthier et al., 2010) [20]</b>	
Hormone receptor status	negative = 1; positive = 0
ECOG status	3, 4 = 1; 0, 1, 2 = 0
Number of previous chemotherapy lines	> 3 = 1; < 3 = 0
CYFRA 21–1 level	> 4 ng/ml = 1; < 4 ng/ml = 0
<b>Carausu et al. (2021) [23]</b>	
Triple-negative breast cancer	negative
Number of treatment lines prior to IT therapy	≥ 3 = negative
Additional metastases	≥ 3 = negative
Administration of IT cytarabine/ thiotepa versus MTX	negative
Note: Curie score: good prognosis: 0–1; moderate prognosis: 2; poor prognosis: 3–4	

## Prognostic factors

Guthier et al. and Carausu et al. attempted to identify prognostic factors which would allow them to define subgroups suitable for specific therapy concepts [20, 23]. Using multivariate analysis, Guthier et al. was able to identify four prognostic factors which were independently associated with overall survival: hormone receptor status, performance status (ECOG status), number of previous chemotherapy lines, and CYFRA 21–1 levels in cerebrospinal fluid at the time of diagnosis. The performance status was determined using the ECOG performance status (ECOG). According to Gauthier et al., unfavorable prognostic factors at diagnosis were ECOG status > 2, more than three chemotherapies prior to being diagnosed with meningeal carcinomatosis, negative hormone receptor status, and a high CYFRA 21–1 level. Based on these four prognostic factors, Gauthier et al. calculated a Curie score, a prognostic score which allowed patients to be divided into one of three groups according to their prognosis (poor, moderate or good). Each factor was weighted equally as it had a similar impact on overall survival in the study. The total score was calculated using the sum of the hormone receptor status (negative = 1 and positive = 0), ECOG status (3, 4 = 1 und 0, 1, 2 = 0), previous number of lines of chemotherapy (more than three previous lines = 1; fewer or equal to three lines = 0), and initial CYFRA 21–1 in cerebrospinal fluid (> 4 ng/ml = 1) (► **Table 2**). As CYPFRA 21–1, a cytokeratin 19 fragment, is not routinely determined in patients with meningeal carcinomatosis, a simplified score without CYFRA 21–1 was also used. To justify their inclusion of CYFRA 21–1 as a prognostic factor, Gauthier et al. referred to the study by Klee et al., in which it was suggested that CYFRA 21–1 levels could reflect the tumor burden in cerebrospinal fluid [20, 27].

This simplified Curie score was validated in the study by Carausu et al. The authors were able to confirm the prognostic role of the score; however, the calculated C index was low at 0.57.

When the Curie score was applied to the patient cohort of Carausu et al., it was significantly prognostic for overall patient survival. Because there were only a few patients with a score of 3, Carausu et al. divided patients into just three risk groups according to their score (0, 1 or 2–3, respectively). 12.8% of patients had a Curie score of 0 and a median OS of 13.2 months; 39.4% of patients had a score of 1 and a median OS of 5.0 months and 47.8% of patients had a score of 2–3 and a median OS of 3.5 months [23].

Carausu et al. also evaluated their own patient cohort using multivariate analysis. A total of 312 patients, most with hormone receptor-positive, HER2-negative subtypes, received either intrathecal methotrexate, thiopeta or cytarabine (liposomal or non-liposomal). Significant prognostic factors associated with a poorer outcome in multivariate analysis were triple-negative breast cancer as the primary tumor,  $\geq 3$  previous treatment lines prior to IT therapy,  $\geq 3$  additional metastases, and the use of IT cytarabine or thiopeta versus methotrexate; concurrent systemic therapy was associated with a better overall survival (► **Table 2**) [23].

Gauthier et al. and Carausu et al. pointed out that their patient cohorts already had pre-existing unfavorable prognostic factors [20, 23]. The validation of the Curie score illustrates the difficulty of developing a universally applicable prognostic scoring system for disease when the amount of data is so limited [23]. A number of variables (hormone receptor status, histological subtype, prior therapy) have not yet been fully investigated, making it difficult to ensure that the score is reliable.

## Quality of life

In their respective studies, Oberkampff et al. and Le Rhun et al. came to the conclusion that patients' overall quality of life can be maintained during intrathecal therapy [13, 17]. Le Rhun et al. determined that there was no difference in quality of life between the cohort which received IT therapy and the control group, although the treatment group suffered from more CTCAE grade 3 infections. Le Rhun et al. ascribed this to the prolongation of progression-free survival following intrathecal treatment [13].

## Discussion

In principle, intrathecal therapy has a tolerable side-effects profile and offers particularly promising results for cases treated with trastuzumab for HER2-positive primary tumors. A basic advantage of liposomal cytarabine compared to trastuzumab is, however, that administration is only carried out every two weeks. For patients, this means fewer treatment sessions. But it is important to be aware when administering liposomal cytarabine that there have been repeated supply shortages and the substance is currently not available on the European market [13, 28].

When looking at the comparisons between the studies included in our review, it is important to be aware that the characteristics of the patient cohorts in the studies were very heterogeneous, and the administered doses and forms of administration varied considerably. Moreover, the systematic literature search was only carried out in PubMed, and evaluated results were taken exclusively from articles written in German or English. This means that other potentially relevant studies in other databases and other languages were not included.

In the longer term, prospective studies could look at reported differences in the forms used to administer therapy and determine the optimal means of administering IT therapy for meningeal carcinomatosis and could focus on the advantages and disadvantages of the different forms of administration used.

Current studies are also looking at the use of immune checkpoint inhibitors. The first studies on the use of immune checkpoint inhibitors in patients with melanoma and meningeal carcinomatosis have been published. In their phase 1/1b study, Glitza Oliva et al. reported on 25 melanoma patients with meningeal carcinomatosis who received the PD-1 inhibitor nivolumab. In this study, nivolumab was initially administered intrathecally for one cycle and then additionally administered intravenously in all subsequent cycles. The results indicate that intrathecal and intravenous administration of nivolumab led to an improvement in overall survival. The median overall survival achieved in the study was 4.9 months. No dose-limiting toxicities occurred when a maximum dose of 50 mg intrathecal nivolumab was administered [29].

The results obtained in the randomized study by Boogerd et al. contrast with the promising results for intrathecal therapy options discussed above. Patients with meningeal carcinomatosis and breast cancer were randomized into an intrathecal ( $n = 17$ ) and a non-intrathecal ( $n = 18$ ) therapy group. Treatment in both groups was based on systemic therapy and radiotherapy. One group additionally received intrathecal treatment with MTX. Boogerd et al. found that intrathecal therapy did not lead to any improvement in overall survival (OS intrathecal: 18.3 weeks; OS non-intrathecal: 30.3 weeks) [30].

Randomized prospective studies of homogeneous patient cohorts which look at the currently available treatment options for meningeal carcinomatosis and compare them are currently lacking. Such studies would permit an evidence-based evaluation of intrathecal treatment options. As such studies are difficult to carry out because of the low incidence of meningeal carcinomatosis, we recommend that patients with meningeal carcinomatosis are entered in the Brain Metastases in Breast Cancer BMBC Register [31]. A large number of well-documented cases would make it possible, in future, to analyze subgroups with comparable prognostic factors. This would allow conclusions about the efficacy and side effects of intrathecal and systemic chemotherapy and radiotherapy to be drawn. The significant interest in further studies is confirmed by the results of a survey by the Breast International Group. A total of 241 institutions participated in the survey which offers an overview of the current management of meningeal carcinomatosis patients. More than 90% of the participating institutions were interested in participating in a register and supported further studies into meningeal carcinomatosis [32]. Future studies should also focus on patients' quality of life under different therapy strategies.

## Conclusion

Individual studies show that early multimodal therapy which includes radiotherapeutic, systemic and/or intrathecal treatment leads to better overall patient survival [12, 13, 23]. However, randomized controlled studies which could support these results are lacking. The long-term creation of a prognostic score could help

identify individual subgroups for whom certain treatment strategies would be especially effective. The focus should always be on an individual multimodal therapeutic approach which reflects the usually palliative nature of the situation.

## Conflict of Interest

MM: no conflict of interest relating to the topic of this review.

EL: no conflict of interest relating to the topic of this review.

KR: no conflict of interest relating to the topic of this review.

IW: no conflict of interest relating to the topic of this review.

VM: speaker's fees: AstraZeneca, Daiichi-Sankyo, Eisai, GSK, Pfizer, MSD, Medac, Novartis, Roche, Seagen, Onkowsen, high5 Oncology, Medscape, Gilead, Pierre Fabre, Medscape. Consultancy services: Roche, Pierre Fabre, Amgen, ClinSol, Novartis, MSD, Daiichi-Sankyo, Eisai, Lilly, Sanofi, Seagen, Gilead, Stemline, ClinSol. Research support to employer: Novartis, Roche, Seagen, Genentech, AstraZeneca. Travel expenses: Roche, Pfizer, Daiichi-Sankyo.

## References/Literatur

- Zentrum für Krebsregisterdaten, R.K.-I. Brustkrebs. 2019. Accessed September 07, 2022 at: [https://www.krebsdaten.de/Krebs/DE/Content/Krebsarten/Brustkrebs/brustkrebs\\_node.html;jsessionid=2EA11A19A0F0B50977FADAF71B921254.internet102](https://www.krebsdaten.de/Krebs/DE/Content/Krebsarten/Brustkrebs/brustkrebs_node.html;jsessionid=2EA11A19A0F0B50977FADAF71B921254.internet102)
- Deutsche Krebsgesellschaft (DKG). Interdisziplinäre S3-Leitlinie für die Früherkennung, Diagnostik, Therapie und Nachsorge des Mammakarzinoms. 2021. Accessed September 07, 2022 at: <https://www.awmf.org/leitlinien/detail/II/032-045OL.html>
- Mack F, Baumert BG, Schäfer N et al. Therapy of leptomeningeal metastasis in solid tumors. *Cancer Treat Rev* 2016; 43: 83–91. doi:10.1016/j.ctrv.2015.12.004
- Chamberlain MC, Kormanik PR. Carcinomatous meningitis secondary to breast cancer: predictors of response to combined modality therapy. *J Neurooncol* 1997; 35: 55–64. doi:10.1023/a:1005803918194
- Rudnicka H, Niwińska A, Murawska M. Breast cancer leptomeningeal metastasis—the role of multimodality treatment. *J Neurooncol* 2007; 84: 57–62. doi:10.1007/s11060-007-9340-4
- Franzoi MA, Hortobagyi GN. Leptomeningeal carcinomatosis in patients with breast cancer. *Crit Rev Oncol Hematol* 2019; 135: 85–94. doi:10.1016/j.critrevonc.2019.01.020
- Niwińska A, Rudnicka H, Murawska M. Breast cancer leptomeningeal metastasis: propensity of breast cancer subtypes for leptomeninges and the analysis of factors influencing survival. *Med Oncol* 2013; 30: 408. doi:10.1007/s12032-012-0408-4
- de Azevedo CR, Cruz MR, Chinen LT et al. Meningeal carcinomatosis in breast cancer: prognostic factors and outcome. *J Neurooncol* 2011; 104: 565–572. doi:10.1007/s11060-010-0524-y
- Lee S, Ahn HK, Park YH et al. Leptomeningeal metastases from breast cancer: intrinsic subtypes may affect unique clinical manifestations. *Breast Cancer Res Treat* 2011; 129: 809–817. doi:10.1007/s10549-011-1682-0
- Arbeitsgemeinschaft Gynäkologische Onkologie, Kommission Mamma. Leitlinien Empfehlungen ZNS Metastasen. 2023. Accessed July 16, 2023 at: <https://www.ago-online.de/leitlinien-empfehlungen/leitlinien-empfehlungen/kommission-mamma>
- Bommer M, Bullinger L. Meningeosis carcinomatosa. *Onkologie* 2016; 22: 321–328. doi:10.1007/s00761-016-0011-y
- Laakmann E, Witzel I, Müller V. Efficacy of Liposomal Cytarabine in the Treatment of Leptomeningeal Metastasis of Breast Cancer. *Breast Care (Basel)* 2017; 12: 165–167. doi:10.1159/000464400
- Le Rhun E, Wallez J, Mailliez A et al. Intrathecal liposomal cytarabine plus systemic therapy versus systemic chemotherapy alone for newly diagnosed leptomeningeal metastasis from breast cancer. *Neuro Oncol* 2020; 22: 524–538. doi:10.1093/neuonc/noz201
- Jaekle KA, Phuphanich S, Bent MJ et al. Intrathecal treatment of neoplastic meningitis due to breast cancer with a slow-release formulation of cytarabine. *Br J Cancer* 2001; 84: 157–163. doi:10.1054/bjoc.2000.1574
- Zagouri F, Zoumpoulis P, Le Rhun E et al. Intrathecal administration of anti-HER2 treatment for the treatment of meningeal carcinomatosis in breast cancer: A meta-analysis with meta-regression. *Cancer Treat Rev* 2020; 88: 102046. doi:10.1016/j.ctrv.2020.102046
- Pappa E, Conforti R, Hoang-Xuan K et al. Intrathecal Trastuzumab as a Potential Cause of Drug-Induced Aseptic Meningitis. *Can J Neurol Sci* 2019; 46: 358–359. doi:10.1017/cjn.2019.21
- Oberkamp F, Gutierrez M, Trabelsi Grati O et al. Phase II study of intrathecal administration of trastuzumab in patients with HER2-positive breast cancer with leptomeningeal metastasis. *Neuro Oncol* 2023; 25: 365–374. doi:10.1093/neuonc/noac180
- Niwińska A, Rudnicka H, Murawska M. Breast cancer leptomeningeal metastasis: the results of combined treatment and the comparison of methotrexate and liposomal cytarabine as intra-cerebrospinal fluid chemotherapy. *Clin Breast Cancer* 2015; 15: 66–72. doi:10.1016/j.clbc.2014.07.004
- Meissner M, Addeo A. Intrathecal Methotrexate and Craniospinal Radiotherapy Can Be an Effective Treatment of Carcinomatous Meningitis in Patients with Breast Cancer: Case Reports. *Case Rep Oncol* 2016; 9: 586–592. doi:10.1159/000449448
- Gauthier H, Guilhaume MN, Bidard FC et al. Survival of breast cancer patients with meningeal carcinomatosis. *Ann Oncol* 2010; 21: 2183–2187. doi:10.1093/annonc/mdq232
- Freyer CW, Yaghamour G, Jennings K et al. Drug-Induced Aseptic Meningitis Associated With Intrathecal Trastuzumab. *J Pharm Technol* 2014; 30: 43–47. doi:10.1177/8755122513500918
- Figura NB, Rizk VT, Mohammadi H et al. Clinical outcomes of breast leptomeningeal disease treated with intrathecal trastuzumab, intrathecal chemotherapy, or whole brain radiation therapy. *Breast Cancer Res Treat* 2019; 175: 781–788. doi:10.1007/s10549-019-05170-7
- Carausu M, Carton M, Darlix A et al. Breast cancer patients treated with intrathecal therapy for leptomeningeal metastases in a large real-life database. *ESMO Open* 2021; 6: 100150. doi:10.1016/j.esmoop.2021.100150
- Shapiro WR, Young DF, Mehta BM. Methotrexate: distribution in cerebrospinal fluid after intravenous, ventricular and lumbar injections. *N Engl J Med* 1975; 293: 161–166. doi:10.1056/nejm197507242930402
- Glantz MJ, Van Horn A, Fisher R et al. Route of intracerebrospinal fluid chemotherapy administration and efficacy of therapy in neoplastic meningitis. *Cancer* 2010; 116: 1947–1952. doi:10.1002/cncr.24921
- Bonneau C, Paintaud G, Trédan O et al. Phase I feasibility study for intrathecal administration of trastuzumab in patients with HER2 positive breast carcinomatous meningitis. *Eur J Cancer* 2018; 95: 75–84. doi:10.1016/j.ejca.2018.02.032
- Klee GG, Tallman RD, Goellner JR et al. Elevation of carcinoembryonic antigen in cerebrospinal fluid among patients with meningeal carcinomatosis. *Mayo Clin Proc* 1986; 61: 9–13. doi:10.1016/s0025-6196(12)61391-3
- Redaktion Gelbe Liste. Lieferengpass Depocyte. 2018. Accessed October 26, 2022 at: <https://www.gelbe-liste.de/lieferengpasse/lieferengpass-depocyte>



- [29] Glitza Oliva IC, Ferguson SD, Bassett R, jr. et al. Concurrent intrathecal and intravenous nivolumab in leptomeningeal disease: phase 1 trial interim results. *Nat Med* 2023; 29: 898–905. doi:10.1038/s41591-022-02170-x
- [30] Boogerd W, van den Bent M J, Koehler P J et al. The relevance of intraventricular chemotherapy for leptomeningeal metastasis in breast cancer: a randomised study. *Eur J Cancer* 2004; 40: 2726–2733. doi:10.1016/j.ejca.2004.08.012
- [31] Witzel I, Laakmann E, Weide R et al. Treatment and outcomes of patients in the Brain Metastases in Breast Cancer Network Registry. *Eur J Cancer* 2018; 102: 1–9. doi:10.1016/j.ejca.2018.07.004
- [32] Razis E, Escudero MJ, Palmieri C et al. Assessment of the management of carcinomatous meningitis from breast cancer globally: a study by the Breast International Group Brain Metastasis Task Force. *ESMO Open* 2022; 7: 100483. doi:10.1016/j.esmoop.2022.100483