



# A Spontaneous Tubal Heterotopic Triplet Pregnancy Resulting in Viable Twin Deliveries

Luce Kassi, MD<sup>1</sup> Emma Lantos, MD<sup>1</sup> Jordan Sheran, MD<sup>1</sup> Lynn M. Yee, MD, MPH<sup>1</sup>

<sup>1</sup>Department of Obstetrics and Gynecology, Feinberg School of Medicine, Northwestern University, Chicago, Illinois

**Address for correspondence** Lynn M. Yee, MD, MPH, Department of Obstetrics and Gynecology, Northwestern University, 250 E. Superior Street, Suite 5-2149, Chicago, IL 60611 (e-mail: [lynn.yee@northwestern.edu](mailto:lynn.yee@northwestern.edu)).

AJP Rep 2024;14:e7–e10.

## Abstract

There are limited U.S. reports of spontaneous triplet heterotopic pregnancies discussing both maternal and fetal outcomes. A 34-year-old patient at 7 weeks of gestation presented to the emergency department with abdominal pain. She was diagnosed with a spontaneous heterotopic triplet pregnancy, consisting of a twin monochorionic-diamniotic intrauterine gestation and a ruptured left ectopic pregnancy. She underwent a laparoscopic unilateral salpingectomy. Her antepartum course was complicated by gestational diabetes mellitus and fetal growth restriction. Delivery of liveborn twins was via a cesarean delivery at 32 weeks. Timely intervention and management of a ruptured spontaneous triplet heterotopic pregnancy can result in a viable twin delivery with overall favorable maternal and newborn outcomes, although long-term implications due to prematurity and other twin sequelae exist.

## Keywords

- ▶ heterotopic pregnancy
- ▶ heterotopic triplet pregnancy
- ▶ multiple gestation
- ▶ preterm delivery
- ▶ monochorionic-monoamniotic twin
- ▶ fetal growth restriction
- ▶ fertility
- ▶ infertility

A heterotopic pregnancy is defined as the presence of a concurrent intrauterine and extrauterine pregnancies (IUP and EUP, respectively). It is a rare and potentially life-threatening condition that can result in the rupture of the EUP and in a spontaneous abortion of the IUP. The incidence of heterotopic pregnancies is estimated at 1 in 4,000 to 1 in 30,000 pregnancies, but with the increased prevalence of assisted reproductive technology (ART), some studies report an incidence as high as 1 in 100.<sup>1,2</sup>

Risk factors for a heterotopic pregnancy are believed to be similar to those of an ectopic pregnancy, including prior damage to the fallopian tubes due to surgery, tubal factor infertility, pelvic infection, the use of ART (notably multiple

embryo transfers, ovulation stimulation), a history of cigarette smoking, and advanced maternal age.<sup>1,2</sup>

Given how rare spontaneous tubal heterotopic pregnancies are, further understanding of its clinical presentation, management, and outcomes are required. We report a case of a spontaneous tubal heterotopic triplet pregnancy that resulted in the birth of live twins. Diagnostic transvaginal ultrasound imaging in addition to pictures from the laparoscopic surgical case with evidence of significant hemoperitoneum demonstrate the urgency and life-threatening risks associated with a ruptured heterotopic pregnancy. The patient provided written informed consent for publication of this report and accompanying images.

received  
June 21, 2021  
accepted after revision  
October 20, 2023  
accepted manuscript online  
October 30, 2023

DOI <https://doi.org/10.1055/a-2201-5796>.  
ISSN 2157-6998.

© 2024. The Author(s).

This is an open access article published by Thieme under the terms of the Creative Commons Attribution-NonDerivative-NonCommercial-License, permitting copying and reproduction so long as the original work is given appropriate credit. Contents may not be used for commercial purposes, or adapted, remixed, transformed or built upon. (<https://creativecommons.org/licenses/by-nc-nd/4.0/>)

Thieme Medical Publishers, Inc., 333 Seventh Avenue, 18th Floor, New York, NY 10001, USA

## Case

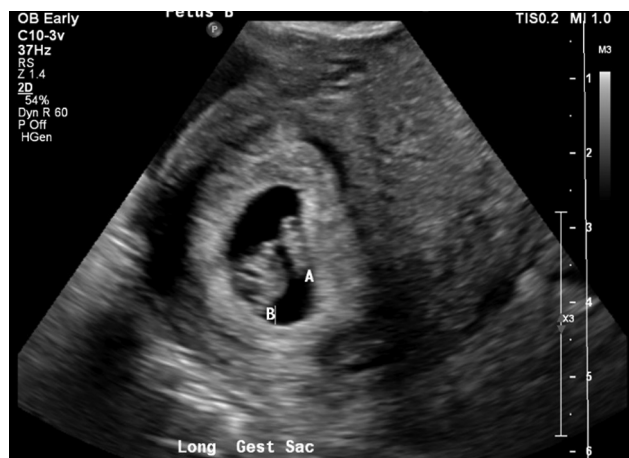The patient was a 34-year-old G2P0010 woman who presented to the emergency department (ED) at 7<sup>4/7</sup> weeks of gestation by last menstrual period with 2 days of abdominal pain. She recently had a positive urine pregnancy test at home but had not yet established obstetrics care. She reported that the evening prior to her presentation, she started to experience intermittent left lower quadrant pain which progressed the following day. Pertinent positive and negative symptoms included nausea without emesis and no vaginal bleeding. She denied a history of infertility or ART.

Her medical history was notable for a first-trimester spontaneous abortion. She had an unremarkable gynecologic history. She denied a history of sexually transmitted infections or structural gynecologic pathologies. She had no prior surgical history. She denied tobacco, alcohol, or other substance use.

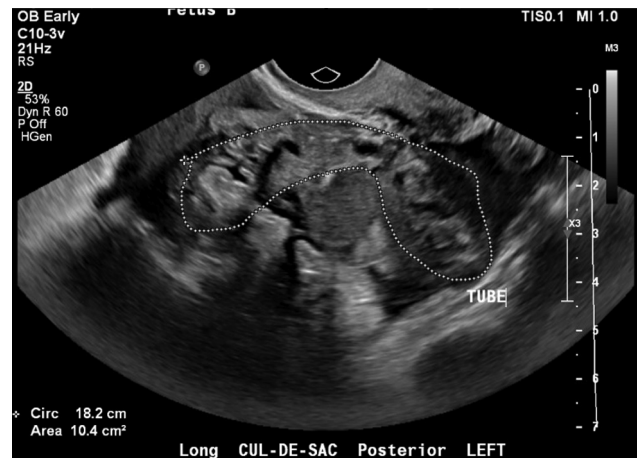Upon arrival to the ED, the patient was hemodynamically stable but had tenderness on palpation in the lower abdominal quadrants, more pronounced in the left adnexa. Her laboratory values showed a  $\beta$  human chorionic gonadotropin of 69,906 mIU/mL, hemoglobin of 12.9 g/dL, and a mild leukocytosis of  $13.3 \times 10^9$  cells/L.

A transvaginal ultrasound demonstrated a tubal heterotopic triplet pregnancy, with a twin monochorionic-diamniotic IUP and an echogenic ring-like structure with possible embryonic structures noted within the left adnexa, with peripheral flow and no cardiac activity ( $\rightarrow$  **Figs. 1 and 2**). Both twins in the IUP had fetal cardiac motion identified. There was also a tubular structure with heterogeneous echoes, measuring  $6.4 \times 2.5 \times 1.6$  cm ( $\rightarrow$  **Fig. 2**). These findings were highly suggestive of a ruptured left tubal ectopic. Moderate to large amount of complex, free fluid was noted within the pelvis ( $\rightarrow$  **Fig. 2**).

After counseling, the patient underwent an uncomplicated diagnostic laparoscopy, left salpingectomy, and evacuation of hemoperitoneum ( $\rightarrow$  **Fig. 3**). Intra-abdominal entry was performed via a transumbilical Veress needle. Insufflation was performed to an intra-abdominal pressure of



**Fig. 1** Ultrasonographic evidence of intrauterine twin gestation (A, B).



**Fig. 2** Evidence of an enlarged left fallopian tube (“TUBE”) with complex, free fluid in the posterior cul-de-sac.

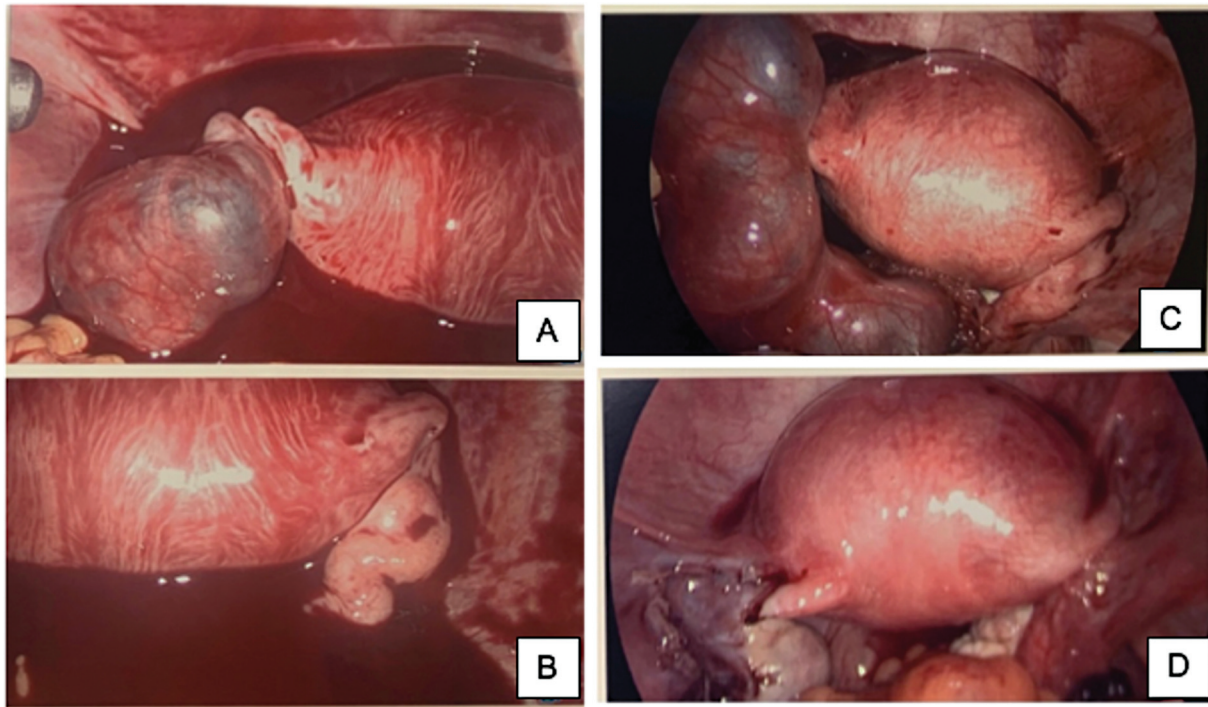
15 mm Hg and three laparoscopic 5 mm ports were placed in bilateral lower quadrants. Given the IUP, uterine manipulator was avoided to minimize risks of disrupting the desired IUP. She recovered well and was discharged on the same day. Final pathology confirmed left tubal ectopic pregnancy.

Her antepartum course was complicated by gestational diabetes mellitus (GDM) and fetal growth restriction (FGR) of both twins. She was first diagnosed with selective FGR of twin A at 17<sup>2/7</sup> weeks of gestation. FGR was subsequently diagnosed in twin B at 24<sup>1/7</sup> weeks. Initially, umbilical artery Doppler assessments demonstrated absent end diastolic flow for twin A but preserved flow for twin B. She initiated outpatient management with biweekly nonreactive stress test and biophysical profiles at 24 weeks. At 27<sup>6/7</sup> weeks of gestation, umbilical artery Doppler assessments were newly notable for reversed end diastolic flow for twin A and elevated but preserved end diastolic flow for twin B. Based on these findings, she desired intensified monitoring and was subsequently admitted for inpatient management until delivery. Throughout her hospital course, umbilical artery Doppler assessments remained stable and contributed to the decision for an iatrogenic preterm delivery at 32 weeks of gestation. The patient’s GDM was primarily diet controlled. She temporarily required insulin after the administration of betamethasone for fetal lung maturity shortly prior to delivery.

At 32<sup>2/7</sup> weeks, she had an uncomplicated primary low transverse cesarean delivery with twins A and B weighing 936 g (2 lb, 1 oz) and 1,009 g (2 lb, 6.5 oz), respectively. Apgar scores for twins A and B were both 8 and 9 at 1 and 5 minutes. The patient was discharged in stable conditions on postoperative day 4. Both infants were admitted to the neonatal intensive care unit for prematurity and respiratory support. Twins A and B were discharged at 6 and 5 weeks of life, respectively, after routine neonatal courses.

## Discussion

This case demonstrates the clinical presentation, management, and outcome of a ruptured spontaneous heterotopic pregnancy. Importantly, prompt surgical intervention was



**Fig. 3** Pictures taken during the laparoscopic case, showing evidence of significant hemoperitoneum (A, B) with an enlarged left fallopian tube (C) concerning for a left ruptured tubal pregnancy. The bottom right picture (D) shows the pelvis after evacuation of hemoperitoneum and left salpingectomy.

lifesaving and resulted in overall favorable maternal and fetal outcomes, though surviving twins still experienced some degree of morbidity in the form of FGR and prematurity.

In a systematic review including six case reports of spontaneous heterotopic pregnancies between 2000 to 2016, all patients except one presented complaining of acute abdominal pain, as in our report. Of the six cases, five patients had twins (a single IUP with a concurrent tubal EUP) and one patient had bilateral tubal ectopic pregnancies with an IUP. Of the patients who presented with acute abdominal pain, all had evidence of hemoperitoneum suspected on ultrasound ultimately due to tubal rupture. Notably, none of the patients presented with vaginal bleeding; the absence of vaginal bleeding may reduce the likelihood that ectopic pregnancy is considered in the initial evaluation. Regarding risks factors, reported patients did not have a history of previous pelvic surgery, pelvic inflammatory diseases, or a prior ectopic pregnancy. The median gestational age at the time of diagnosis of the heterotopic pregnancy was 7 weeks (with a range of 4–10 weeks).<sup>1</sup> Available data show that in 70% of cases, the diagnosis of a ruptured tubal ectopic is made between 5 and 8 weeks of gestation, 20% between 9 and 11 weeks, and 10% after 11 weeks of gestation.<sup>2</sup> There is no clear evidence in the literature that describes a common gestational age at which a heterotopic pregnancy is diagnosed. However, given its similarity to a tubal ectopic pregnancy, assumption can be made that the timing of diagnosis is comparable.

Preterm birth may be a morbidity of the ongoing IUP in a heterotopic pregnancy. The mean and median gestational age at the time of delivery in that same systematic review

were, respectively, to be 29.9 and 37.5 (range 6–41 weeks). Neonatal outcomes were noted to be favorable for six newborns (in four patients, which included two sets of twins and two singletons) who were delivered after 34 weeks of gestation.<sup>2</sup> Though twin pregnancies in the United States account for only 2 to 3% of live births, twin gestations have been associated with up to 10 to 15% of neonatal morbidity due to risk of FGR, preterm birth, and small for gestational age (SGA) status, and other morbidity.<sup>3</sup> The risk of SGA has been described to be as high as 25%, particularly for mono-chorionic gestations due to unequal placenta sharing and twin-twin transfusion syndrome.<sup>3</sup> Given the rarity of heterotopic pregnancies, there are no clear data attributing this diagnosis with FGR; we hypothesize this abnormal pregnancy diagnosis could influence placentation of the IUP, thus contributing to FGR.

Management of heterotopic pregnancy is primarily surgical.<sup>4</sup> In the published literature, all patients required surgical management, which included unilateral salpingectomies (for four out six patients), unilateral salpingostomy (for one patient), and bilateral salpingectomies for a heterotopic triplet pregnancy with a singleton IUP and bilateral tubal pregnancies.<sup>2</sup> A few studies report medical management with transvaginal ultrasound-guided injection of potassium chloride, hyperosmolar glucose, and/or methotrexate into the gestational sac, with a significant risk of still requiring emergency salpingectomy.<sup>5,6</sup> Though not statistically significant, a lower live birth rate (60.9 vs. 50%) and a higher abortion rate of the IUP was reported in patients who were managed medically compared with those managed surgically (50 vs. 13%).<sup>6</sup> With the presence of an IUP, parenteral

methotrexate is an effective but not a valid option for patients who desire to continue the IUP or for patients who present with evidence of a ruptured heterotopic, as both are among the absolute contraindications of methotrexate use.

It is important to note that when done properly, laparoscopy is an effective and safe option during the first trimester of pregnancy. Starting at 14 weeks of gestation, transumbilical Veress needle entry and insufflation have not been recommended in some studies due to cases of uterine perforation resulting from a Veress needle entry.<sup>7</sup> Recognizing that the uterus reaches and subsequently increases in size beyond the level of the umbilicus between 20 and 24 weeks of gestation, laparoscopic trocar placement should always be adapted based on the gestational age.<sup>7</sup>

A recent systematic review evaluated the fertility outcomes of salpingectomy compared with those of salpingostomy among patients treated for tubal ectopic pregnancies.<sup>8</sup> Among the two randomized controlled trials that were included, there was no significant difference in the odds of subsequent IUP in patients who were treated with a salpingectomy compared with those who underwent a salpingostomy. However, the 16 cohort studies included in the systematic review showed a significant lower chance of IUP after salpingectomy but a cumulatively higher risk of recurrent ectopic pregnancy (REP) after a salpingostomy.<sup>8</sup> However, it is important to note that there was no significant difference noted in the operating room for REP in the randomized trials included in that study. The decision to proceed with a salpingectomy versus a salpingostomy should be a joint decision including the patient's desires, medical and surgical histories, clinical presentation, hemodynamic stability, and also the surgeon's surgical experience.

## Conclusion

The case presented provides insight into the presentation, diagnosis, management, and outcome of a spontaneous triplet heterotopic pregnancy. Early and timely surgical intervention has proven to be lifesaving and can result in viable pregnancies. Though rare, this case emphasizes the importance of including heterotopic pregnancies as part of the differential diagnosis in a pregnant person presenting

with abdominal pain. Given the potentially high maternal and fetal morbidity and mortality, additional data are needed to better understand the risk factors associated with this rare pregnancy complication and the implications it may have for viable fetuses, including FGR.

### Informed Consent

The patient provided written informed consent regarding this case report.

### Funding

None.

### Conflict of Interest

None declared.

## References

- 1 Bataille P, Reynard A, Ducarme G. Spontaneous heterotopic triplets - A review of literature. *J Gynecol Obstet Hum Reprod* 2017;46(08):657-659
- 2 Tal J, Haddad S, Gordon N, Timor-Tritsch I. Heterotopic pregnancy after ovulation induction and assisted reproductive technologies: a literature review from 1971 to 1993. *Fertil Steril* 1996;66(01):1-12
- 3 Denbow ML, Cox P, Taylor M, Hammal DM, Fisk NM. Placental angioarchitecture in monochorionic twin pregnancies: relationship to fetal growth, fetofetal transfusion syndrome, and pregnancy outcome. *Am J Obstet Gynecol* 2000;182(02):417-426
- 4 Talbot K, Simpson R, Price N, Jackson SR. Heterotopic pregnancy. *J Obstet Gynaecol* 2011;31(01):7-12
- 5 Goldstein JS, Ratts VS, Philpott T, Dahan MH. Risk of surgery after use of potassium chloride for treatment of tubal heterotopic pregnancy. *Obstet Gynecol* 2006;107(2 Pt 2):506-508
- 6 Suzuki M, Itakura A, Fukui R, Kikkawa F. Successful treatment of a heterotopic cervical pregnancy and twin gestation by sonographically guided instillation of hyperosmolar glucose. *Acta Obstet Gynecol Scand* 2007;86(03):381-383
- 7 Deffieux X, Ballester M, Collinet P, Fauconnier A, Pierre F. French National College of Gynaecologists and Obstetricians. Risks associated with laparoscopic entry: guidelines for clinical practice from the French College of Gynaecologists and Obstetricians. *Eur J Obstet Gynecol Reprod Biol* 2011;158(02):159-166
- 8 Ozcan MCH, Wilson JR, Frishman GN. A systematic review and meta-analysis of surgical treatment of ectopic pregnancy with salpingectomy versus salpingostomy. *J Minim Invasive Gynecol* 2021;28(03):656-667