

Cutting-edge novel device in the treatment of obesity

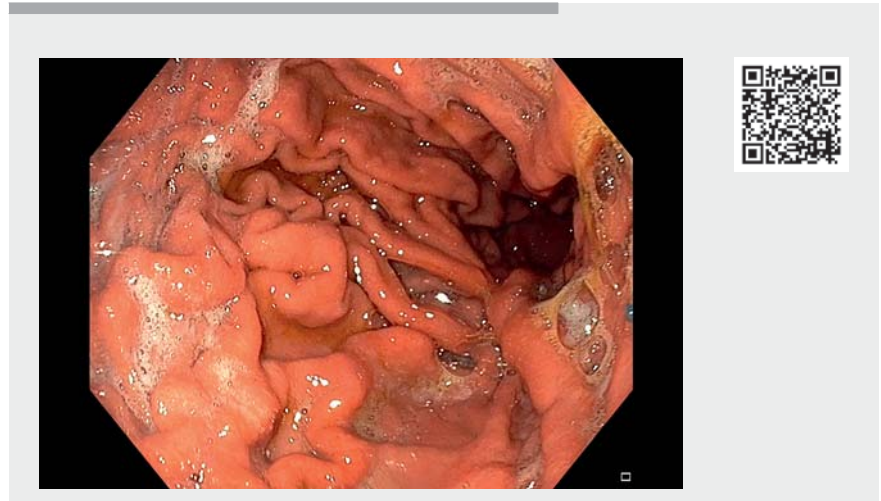


A 57-year-old patient with arterial hypertension, dyslipidemia, and obesity grade I (BMI 34.9 kg/m², 95 kg, 165 cm) underwent a new and unique sleeve gastropasty procedure for weight reduction (► **Video 1**).

A novel device is used to perform the sleeve gastropasty (► **Fig. 1**). The specialized device is inserted into the patient through an overtube, and a thin nasal endoscope is passed through the device into the stomach. Under visual guidance, the appropriate position in the stomach (antrum) is identified, and a vacuum (−84 kPa) is initiated. Subsequently, the nasal endoscope is removed, and the device channel is closed to maintain the vacuum. In this phase of the procedure, full-thickness suturing of the gastric wall is performed using a circular stitch (► **Fig. 2**). The device automatically terminates the stitch, and it is withdrawn through the overtube. The sutures are then inspected using an endoscope. This process is repeated 4–5 times, depending on the appearance of the sleeve gastropasty. After completing all 4–5 sutures, the resulting sleeve is inspected, including checking for possible complications such as bleeding or perforation. The procedure is performed under general anesthesia, with observation continuing until the following day. The average duration of the procedure is 40 minutes.

After three months, the patient achieved a weight loss of 8 kg (8.4% total body weight loss) without any signs of complications. This novel device appears to be a promising new method for weight reduction that is fast, feasible, and safe (► **Fig. 3**). Randomized studies comparing its effectiveness to other devices intended for endoscopic sleeve gastropasty, where the percentage of total body weight loss at 6 months averages around 15%, are now needed [1].

Endoscopy_UCTN_Code_TTT_1AO_2AN



► **Video 1** Endoscopic sleeve gastropasty using a novel device.




► **Fig. 1** Device overview.

Funding

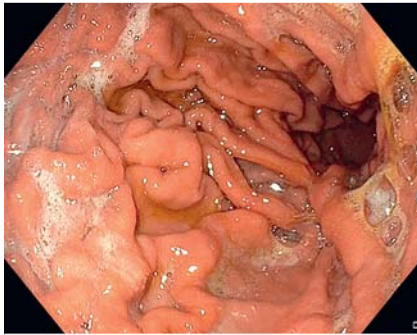
Nitinotes
NCT03472196

Competing interests

First in Human Study was supported by Nitinotes company which developed this device.




► Fig. 2 Assembled device.



► Fig. 3 Device introduction via overtube.

The authors

Jan Kral^{1,2} , Jana Selucka¹, Katerina Waloszko¹, Marek Buzga³, Julius Spicak¹, Evzen Machytka¹

- 1 Institute for Clinical and Experimental Medicine, Hepatogastroenterology Department, Prague, Czech Republic
- 2 Department of Internal Medicine, Second Faculty of Medicine, Charles University, Prague, Czech Republic
- 3 Department of Physiology and Pathophysiology, Faculty of Medicine, University of Ostrava, Ostrava, Czech Republic

Corresponding author

Jan Kral, MD, PhD, MBA
 Institute for Clinical and Experimental Medicine, Videnska 1958/9, 140 21 Prague 4, Czech Republic
 jan.kral@ikem.cz

Citation Format

Endoscopy 2023; 55: E1124–E1125,
 DOI 10.1055/a-2173-7560

Reference

- [1] Hedjoudje A, Abu Dayyeh BK, Cheskin LJ et al. Efficacy and safety of endoscopic sleeve gastroplasty: A systematic review and meta-analysis. *Clin Gastroenterol Hepatol* 2020; 18: 1043–1053.e1044. doi:10.1016/j.cgh.2019.08.022

Bibliography

Endoscopy 2024; 56: 155–156
 DOI 10.1055/a-2209-3374
 ISSN 0013-726X
 © 2023. The Author(s).

This is an open access article published by Thieme under the terms of the Creative Commons Attribution License, permitting unrestricted use, distribution, and reproduction so long as the original work is properly cited.

(<https://creativecommons.org/licenses/by/4.0/>)

Georg Thieme Verlag KG, Rüdigerstraße 14,
 70469 Stuttgart, Germany

