

# Splanchnic Vein Thrombosis: The State-of-the-Art on Anticoagulant Treatment

Scott Custo<sup>1</sup>  Emma Tabone<sup>1</sup>  Alexia Aquilina<sup>1</sup>  Alex Gatt<sup>2</sup>  Nicoletta Riva<sup>2</sup> 

<sup>1</sup> Medical School, Faculty of Medicine and Surgery, University of Malta, Msida, Malta

<sup>2</sup> Department of Pathology, Faculty of Medicine and Surgery, University of Malta, Msida, Malta

**Address for correspondence** Nicoletta Riva, MD, PhD, Department of Pathology, Faculty of Medicine and Surgery, University of Malta, Msida, MSD 2080, Malta

(e-mail: [nicoletta.riva@um.edu.mt](mailto:nicoletta.riva@um.edu.mt); [nico.riva@hotmail.it](mailto:nico.riva@hotmail.it)).

Hamostaseologie

## Abstract

Splanchnic vein thrombosis (SVT) is a rare type of venous thromboembolism occurring within the splanchnic venous system. Portal vein thrombosis is the most common presentation, while Budd–Chiari syndrome is the least common. Liver cirrhosis and abdominal solid cancer are the main local risk factors for SVT, whereas myeloproliferative neoplasms are the predominant systemic risk factors. Signs and symptoms of SVT are nonspecific and include abdominal pain, gastrointestinal bleeding, and ascites. Asymptomatic SVT is not uncommon, and the majority would be detected incidentally on routine abdominal imaging performed for the follow-up of liver diseases and tumors. The management of SVT aims to prevent thrombus progression, promote vessel recanalization, and prevent recurrent venous thromboembolism. Anticoagulation should be started early in order to increase the chances of vessel recanalization and reduce the risk of portal hypertension-related complications. Direct oral anticoagulants have been included in recent guidelines, as alternatives to vitamin K antagonists, after clinical stability has been reached; however, caution is required in patients with liver or kidney dysfunction. Treatment duration is based on the presence (or absence) and type (transient vs. permanent) of risk factors. This narrative review aims to summarize the latest evidence on SVT, with a particular focus on the anticoagulant treatment in special categories of patients (e.g., liver cirrhosis, solid cancer, myeloproliferative neoplasms, pancreatitis, incidentally detected SVT, Budd–Chiari syndrome, and chronic SVT).

## Keywords

- ▶ portal vein thrombosis
- ▶ splenic vein thrombosis
- ▶ mesenteric vein thrombosis
- ▶ Budd–Chiari syndrome
- ▶ anticoagulant therapy

## Introduction

The splanchnic venous system drains the gastrointestinal tract from the lower esophagus to the upper two-thirds of the rectum. Splanchnic vein thrombosis (SVT) is a rare type of venous thromboembolism (VTE) occurring within this system (→**Fig. 1**). It includes portal vein thrombosis (PVT), splenic vein thrombosis (SpVT), and mesenteric vein thrombosis (MVT), as well as Budd–Chiari syndrome (BCS). The term BCS refers to a hepatic venous outflow obstruction anywhere between the hepatic venules and

the insertion of the inferior vena cava into the right atrium.<sup>1,2</sup>

SVT commonly occurs in the context of liver disease, such as cirrhosis, and malignancies.<sup>3</sup> Other causes include intra-abdominal surgery or infections, pancreatitis, inflammatory bowel diseases, thrombophilia, and myeloproliferative neoplasms (MPNs).<sup>3,4</sup>

Anticoagulation is the cornerstone of SVT management, intended to prevent thrombus extension and recurrent thrombosis, while carefully balancing the risk of hemorrhage.<sup>5–7</sup>

received

October 22, 2023

accepted after revision

December 18, 2023

© 2024. Thieme. All rights reserved.

Georg Thieme Verlag KG,

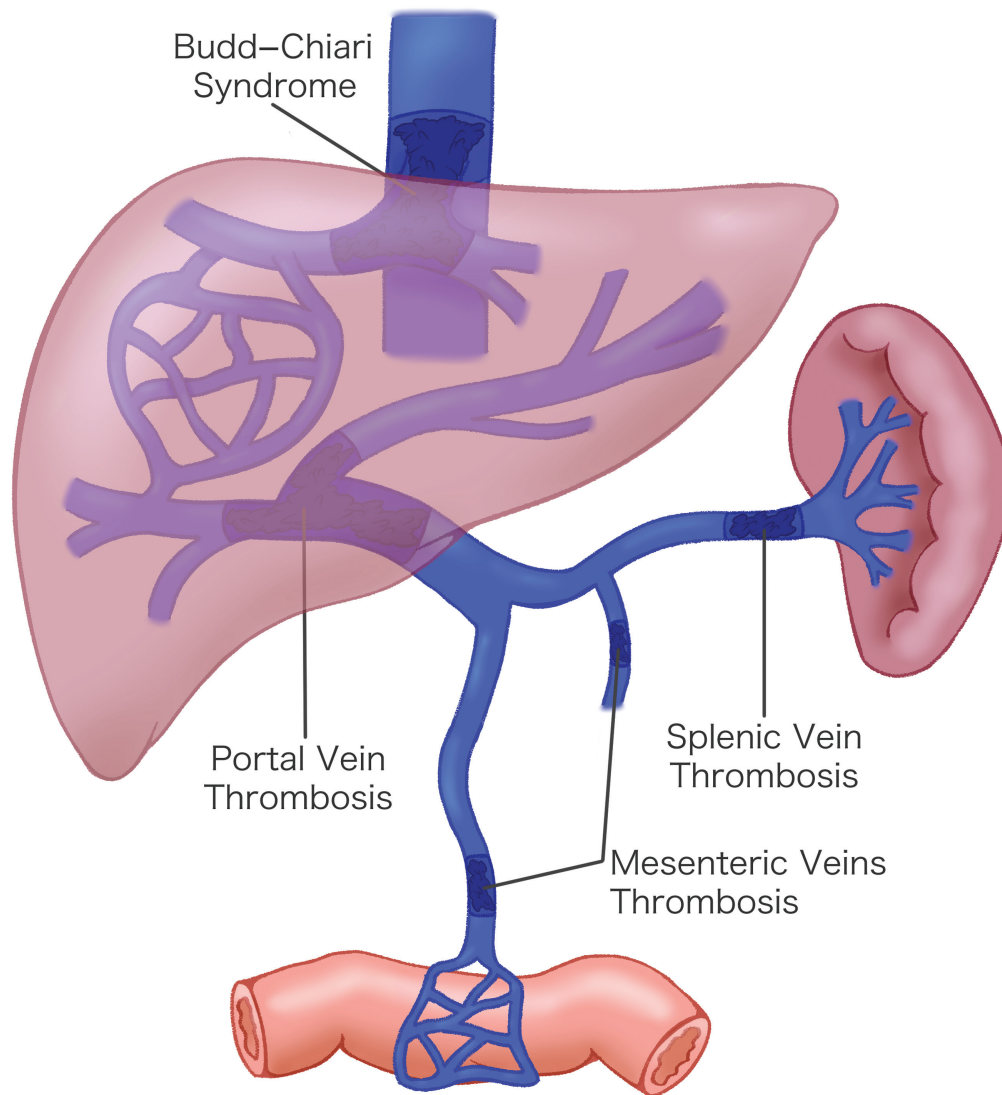
Rüdigerstraße 14,

70469 Stuttgart, Germany

DOI <https://doi.org/10.1055/a-2232-5480>.

10.1055/a-2232-5480.

ISSN 0720-9355.



**Fig. 1** Possible sites of splanchnic vein thrombosis.

This narrative review aims to summarize the latest evidence on SVT, with a particular focus on recent updates regarding the anticoagulant treatment.

## Epidemiology

SVT is an unusual manifestation of VTE, as compared to the commoner usual site VTE (e.g., pulmonary embolism [PE] and lower extremity deep vein thrombosis [DVT]).<sup>8,9</sup> The incidence of SVT is at least 25 times lower than usual site VTE, with considerable variation reported across various studies.<sup>10</sup> SVT is a heterogeneous disorder with differences based on patient populations and sites of thrombosis. While SVT is relatively common among patients with liver cirrhosis and malignant tumours,<sup>11</sup> other types of SVT (primitive PVT, isolated SpVT, isolated MVT, and BCS) are cataloged in Orphanet, the European portal for rare diseases that affect less than 5 per 10,000 individuals.

PVT is the most common presentation, while BCS is the rarest, accounting for 77 to 92% and 2 to 11% of SVT cases,

respectively.<sup>1,12–14</sup> However, in patients with MPNs, BCS constitutes approximately 17% of all SVT cases.<sup>15</sup> Of note, multisegmental SVT is found in around 40% of SVT cases.<sup>1,16</sup>

The incidence of PVT was 1.7 to 3.8 cases per 100,000 inhabitants per year in a study evaluating hospital discharge diagnosis in Northwestern Italy, while a higher incidence rate of 2.8 to 5.9 cases per 10,000 patients was reported in a study evaluating abdominal imaging reports in a large Canadian hospital.<sup>12,17</sup> The annual incidence of BCS is around 1 to 2 cases per million inhabitants.<sup>17,18</sup>

The prevalence of PVT was 3.7 cases per 100,000 inhabitants in a study evaluating Swedish inpatient and outpatient registers.<sup>19</sup> Higher prevalence rates were reported in certain categories of patients, for instance, 14% in patients with liver cirrhosis and 10% in patients with gastrointestinal malignancies.<sup>20,21</sup> The pooled prevalence of BCS in a systematic review and meta-analysis was 11 cases per million inhabitants.<sup>18</sup>

Sex and age distribution in SVT vary with the site of thrombosis. PVT occurs more commonly in males (62–66% of cases), with the mean age at presentation of approximately

54 to 61 years.<sup>16,17</sup> BCS occurs more commonly in females (54–69% of cases), with the mean age at presentation of approximately 40 to 50 years.<sup>16,17,22</sup>

There are no precise estimates on the prevalence of MVT in the general population. A Swedish study reported that the incidence of MVT rose from 2.0 per 100,000 person-years in the period from 1970 to 1982 to 2.7 per 100,000 person-years in the period from 2000 to 2006. Furthermore, the highest incidence rate of 11.3 per 100 person-years was seen in patients among septuagenarians.<sup>23</sup>

## Risk Factors

SVTs can be classified into provoked or unprovoked, based on the presence or absence of known risk factors (→ Fig. 2).<sup>24–28</sup> This classification follows the categorization of usual site VTE and it is used to direct the anticoagulant treatment in many guidelines.<sup>10,29</sup> Unprovoked (i.e., idiopathic) cases account for approximately 15 to 31.7% of SVT cases.<sup>1,16,28</sup> Provoked SVTs can be due to local or systemic risk factors.

Among local risk factors, liver cirrhosis and solid tumors together account for approximately 50% of SVT cases. Liver cirrhosis is found in approximately 24 to 27% of SVT cases and, in turn, approximately 17 to 26% of cirrhotic patients develop SVT.<sup>11</sup> Cirrhosis can induce SVT through several mechanisms, including reduced portal vein blood flow and endothelial dysfunction (due to portal hypertension), and a local/systemic prothrombotic state.<sup>30</sup>

Solid cancer is found in approximately 22 to 27% of SVT cases. Cancer-associated SVT can be induced by tumor compression or invasion of the splanchnic veins, the tumor-related hypercoagulable state, and cancer-management-related factors (e.g., surgery and chemotherapy).<sup>31–33</sup> Furthermore, studies have suggested that SVT can be a marker for occult cancer. Overall, 8% of SVT patients will receive a diagnosis of cancer within 3 months following presentation, in particular, liver cancer, pancreatic cancer, and MPNs.<sup>32,34,35</sup>

Less common local risk factors for SVT include recent abdominal surgery (e.g., splenectomy, liver transplantation) and abdominal diseases (e.g., inflammatory bowel diseases, pancreatitis, cholangitis, appendicitis, diverticulitis). Pylephlebitis, a rare form of septic PVT, has been described in association with abdominal infections.<sup>36</sup> SpVT is typically a complication of pancreatic diseases, due to the anatomical proximity of the splenic vein to the pancreas. Approximately 12% of patients with acute pancreatitis develop SVT, and the splenic vein is involved in more than 90% of the cases (isolated SpVT in a third of cases, or part of multivessel involvement in the remaining two-thirds).<sup>37</sup>

Philadelphia-negative MPNs, which include polycythemia vera, essential thrombocythemia, and primary myelofibrosis, are the predominant systemic risk factors for SVT. These conditions are identified in 30 to 50% of BCS patients and in 15 to 30% of those with nonmalignant, noncirrhotic PVT.<sup>38,39</sup> The *JAK2*V617F mutation, which is a marker of MPN, is detected in 76 to 93% of SVT patients with overt MPN.<sup>39,40</sup> Thus, *JAK2* screening should be performed in SVT patients

## Intra-Abdominal Aetiologies

### •Surgery and Trauma

- Splenectomy
- Gastrectomy
- Cholecystectomy
- Liver Transplantation
- Blunt Force Abdominal Trauma

### •Infection and Inflammation

- Pancreatitis
- Cholecystitis
- Appendicitis
- Diverticulitis
- Inflammatory Bowel Disease
- Hydatidosis and Echinococcosis

### •Malignancy

- Hepatobiliary
- Gastrointestinal
- Pancreatic

### •Liver Cirrhosis

## Haematological Disorders

### •Myeloproliferative Neoplasms

#### •Thrombophilia

- Factor V Leiden Mutation
- Prothrombin G20210A Mutation
- Antithrombin Deficiency
- Protein C Deficiency
- Protein S Deficiency
- Antiphospholipid Syndrome

#### •Paroxysmal Nocturnal Haemoglobinuria

## Autoimmune Disorders

- Systemic Lupus Erythematosus
- Behçet's Disease
- Autoimmune Hepatitis

## Others

- Oestrogen-Containing Hormonal Therapy
- Oestrogen-Containing Oral Contraceptives
- Pregnancy and Puerperium
- COVID-19 Infection
- Inferior Vena Cava Webs
- Personal History of Venous Thromboembolism
- Family History of Venous Thromboembolism

**Fig. 2** Risk factors for splanchnic vein thrombosis.

without liver cirrhosis or malignancy, to identify the possible presence of an MPN.<sup>40</sup> Other driver mutations causing MPNs, such as calreticulin (*CALR*) and thrombopoietin receptor (*MPL*) mutations, are rarely found in SVT patients (~1%). Next-generation sequencing has been utilized in more recent

studies to detect nondriver mutations<sup>41</sup>; however, the association of similar mutations with thrombotic risk is still unclear.<sup>42,43</sup>

Another rare hematological disorder associated with SVT is paroxysmal nocturnal hemoglobinuria (PNH). Although rarely found in SVT patients (~1%),<sup>44</sup> PNH screening should be performed if there is evidence of hemolysis or cytopenia.<sup>45</sup>

An association has been described between the presence of thrombophilic abnormalities, both inherited (factor V Leiden mutation; prothrombin G20210A mutation; anti-thrombin, protein C, or protein S deficiencies) and acquired (antiphospholipid antibodies/lupus anticoagulant), and the development of SVT. However, deficiencies of natural anticoagulants are common in patients with liver diseases, and this might be the effect rather than the cause. Furthermore, the utility of thrombophilia testing in patients with SVT has been questioned by a recent study showing that, with the exception of the *JAK2* mutation, other results rarely changed the management of these patients.<sup>46</sup>

Recent guidelines<sup>45,47</sup> state that thrombophilia testing should be performed only in situations where it would change the management, that is, the duration or the choice of the anticoagulant drug. The 2023 American Society of Hematology (ASH) guidelines suggest thrombophilia testing in patients with SVT not associated with liver cirrhosis in those settings where anticoagulation would be otherwise discontinued.<sup>47</sup> The 2022 British Society for Haematology (BSH) guidelines recommend testing for antiphospholipid antibodies in SVT patients without clear provoking factors.<sup>45</sup>

Other systemic risk factors for SVT include estrogen-containing oral contraceptives, postmenopausal hormone therapy, pregnancy and puerperium, and certain autoimmune diseases. More recently, several cases of SVT have been described in the 2 weeks following a COVID-19 diagnosis, while rare cases of SVT have been reported after COVID-19 vaccination, as part of vaccine-induced immune thrombotic thrombocytopenia.<sup>48,49</sup>

## Clinical Manifestations

SVT has nonspecific clinical features. Irrespective of the site of thrombosis, the most common signs and symptoms are abdominal pain, gastrointestinal bleeding, and abdominal distension secondary to ascites. Less common manifestations include fever, nausea, vomiting, diarrhea/constipation, and anorexia.<sup>50</sup> More specific clinical scenarios are found in certain locations (see below).

A significant proportion of patients, however, are asymptomatic and diagnosed incidentally with SVT when undergoing routine imaging for other conditions, most commonly malignancies and cirrhosis.<sup>3,50,51</sup> Incidentally detected SVTs have been found in 1.7% of abdominal CT scans and, in different cohort studies, they constitute 30 to 59% of all SVTs.<sup>52-54</sup>

### Portal Vein Thrombosis

PVT is divided into acute and chronic forms. Acute cases are characterized by sudden onset of abdominal pain without

any signs of portal hypertension or portosystemic collateral circulation, while chronic cases are characterized by the presence of portal hypertension (e.g., ascites, gastroesophageal varices, splenomegaly and hypersplenism, thrombocytopenia, hepatic encephalopathy, and portal cholangiopathy) and/or portal cavernoma.<sup>55</sup> Some authors suggest considering the duration of symptoms, with acute PVT symptoms lasting less than 60 days prior to diagnosis and chronic PVT symptoms lasting greater than 60 days, but there is no consensus on this time frame.<sup>56-58</sup>

Most of the cases of cirrhosis-associated PVT are incidental findings. However, the development of PVT in cirrhotic patients can result in a sudden clinical deterioration (e.g., occurrence of diuretic-resistant ascites or bacterial peritonitis) and increases the risk of portal hypertensive bleeding. Defining acute or chronic PVT can be challenging in patients with liver cirrhosis, due to the presence of preexisting portal hypertension and collateral vessels resulting from the chronic liver disease itself.<sup>59</sup>

### Mesenteric Veins Thrombosis

MVT is divided into acute, subacute, and chronic forms. Acute cases are characterized by severe, progressive, colicky, mid-abdominal pain. However, the onset of pain is more insidious in patients with acute MVT, compared to acute mesenteric arterial thromboembolism.<sup>60</sup> Associated signs and symptoms include nausea, vomiting, diarrhea, and lower gastrointestinal bleeding. In mesenteric ischemia, the physical findings are initially normal. A third of patients will progress to bowel infarction, which is associated with peritoneal signs (such as guarding and rebound tenderness).<sup>16,23</sup>

Patients with subacute thrombosis present with abdominal pain lasting for days/weeks, but without signs of bowel infarction or portal hypertension.<sup>60</sup> Chronic cases are usually characterized by the lack of acute abdominal pain. Abdominal imaging shows the presence of mesenteric thrombosis, together with extensive venous collateral circulation. Extension of the thrombosis into the portal vein is seen in 65 to 85% of cases, and these patients can present with complications of portal hypertension.<sup>23</sup>

### Splenic Vein Thrombosis

Isolated SpVT is rare, being more commonly associated with concomitant PVT or MVT. A typical triad has been described for SpVT, which includes splenomegaly, normal liver enzymes, and upper gastrointestinal bleeding. In fact, the presence of splenomegaly and/or isolated gastric varices in a patient without liver cirrhosis or hematological diseases should raise suspicion of an SpVT. The wider availability and improved accuracy of cross-sectional diagnostic imaging, such as computed tomography (CT) and magnetic resonance (MR) scans, has led to an increase in the detection of asymptomatic SpVT, especially when performed for the follow-up of pancreatic diseases.<sup>61</sup>

### Budd-Chiari Syndrome

BCS is classified into fulminant, acute, subacute, and chronic forms. Fulminant cases are rare and present with extensive

hepatocellular necrosis and manifestations of acute liver failure, such as elevated liver enzymes, coagulopathy, hyperbilirubinemia, and hepatic encephalopathy.<sup>62</sup>

A typical, although uncommon, triad of hepatomegaly, abdominal pain, and ascites has been described.<sup>63</sup> Another specific sign for BCS is the presence of large subcutaneous cavocaval collateral veins on the trunk, suggesting obstruction of the inferior vena cava.<sup>63</sup>

In acute cases, symptoms usually develop within a month, while in subacute cases, there is a more insidious onset. Chronic cases are more likely to present with portal hypertension-related manifestations, such as gastroesophageal varices, splenomegaly, and ascites. However, if extensive intrahepatic collaterals have developed, they can preserve the hepatic venous outflow and patients can be completely asymptomatic.<sup>64</sup>

## Diagnosis

D-dimer, a biomarker of fibrinolysis commonly used as a rule-out test for usual site VTE, has very limited utility in the diagnosis of SVT. In fact, several conditions, which are also risk factors for SVT, can raise the D-dimer level. These include liver cirrhosis, malignancies, recent surgery, pancreatitis, and others.<sup>65–67</sup> A recent systematic review and meta-analysis highlighted that, in patients at high risk of SVT (such as those with liver cirrhosis, hepatocellular carcinoma, or in the postoperative period), D-dimer has 96% sensitivity, but only 25% specificity for SVT diagnosis.<sup>68</sup>

Thus, the diagnosis of SVT is generally achieved through abdominal imaging. Color Doppler ultrasound (CDUS) is the first-line imaging for the diagnosis of PVT and BCS. However, the mesenteric and splenic veins are difficult to visualize on CDUS. The advantages of CDUS include the possibility to assess the dynamic blood flow, low cost, wide availability, and lack of ionizing radiation or contrast agents, while the disadvantages include the fact that it is an operator-dependent imaging and that patient's body habitus and presence of meteorism may impair the visualization of the abdominal veins.<sup>69</sup> Contrast-enhanced ultrasound (CEUS) can be used to differentiate between PVT and tumor thrombosis (also known as tumor in vein), with reported 94% sensitivity and 99% specificity in patients with hepatocellular carcinoma.<sup>70</sup>

Cross-sectional imaging techniques, such as CT and MR angiography, are the main diagnostic modalities for SVT, since they can visualize the whole splanchnic venous system. They can also visualize the surrounding structures to identify possible complications, such as bowel ischemia, or provoking condition, such as abdominal malignancies.<sup>71</sup> They are often performed after CDUS to evaluate thrombus extension within the mesenteric and splenic veins, which can be underestimated by CDUS. CT utilizes ionizing radiation and an iodinated contrast agent, which can potentially be nephrotoxic in patients with preexisting chronic kidney disease (contrast-induced nephropathy). MR is less widely available and has a longer acquisition time and lower spatial resolution than CT scan.<sup>71</sup> It does not utilize ionizing radiation and the paramagnetic contrast agent has a better safety profile.

However, rare cases of nephrogenic systemic fibrosis have been reported in patients with chronic kidney disease.<sup>50</sup> Recent data suggest that MR non-contrast thrombus imaging (MR-NCTI), a non-contrast-enhanced modality also known as MR direct thrombus imaging, might help differentiate an acute PVT from a chronic PVT.<sup>72</sup> MR-NCTI detects fresh thrombi as high signal intensity due to methemoglobin formation, while the signal intensity is reduced in chronic thrombi due to the lower content of methemoglobin.

Angiography was the gold standard for SVT diagnosis, but it has been replaced by less invasive modalities (such as CDUS, CT, and MR). However, it is still used as a comparison in studies evaluating the diagnostic accuracy of the other imaging tests. For instance, a recent study compared the findings obtained by CDUS and CT versus direct transjugular splenoportography.<sup>73</sup> Overall, 76.6% of CDUS results and 78.4% of CT results were consistent with portography. The remaining 23.4% and 21.6%, respectively, of cases in disagreement were only due to differences in the grading of the thrombosis (partial vs. complete) since the presence of thrombosis was detected by all imaging modalities. The agreement between CDUS and CT in the grading of the thrombosis was 74.4%, suggesting that similar imaging modalities should be used to evaluate thrombosis extension at diagnosis and degree of recanalization during follow-up.<sup>73</sup>

## Management: General Principles of Anticoagulant Treatment

The aim of the anticoagulant treatment in SVT management is threefold: to prevent thrombus progression (thus reducing the risk of bowel ischemia), to promote vessel recanalization (thus reducing the risk of portal hypertension-related complications), and to prevent VTE recurrence. A recent meta-analysis reported that anticoagulation in SVT patients, compared to no treatment, was associated with higher rates of vessel recanalization (risk ratio [RR]: 2.39; 95% confidence interval [CI]: 1.66–3.44), and lower rates of thrombus progression (RR: 0.24; 95% CI: 0.13–0.42), without increasing the risk of major bleeding events (RR: 0.73; 95% CI: 0.58–0.92).<sup>6</sup> Due to the high risk of major and fatal bleeding, thrombolysis should be limited to selected patients with particularly severe symptoms (e.g., extensive SVT associated with intestinal ischemia) or when medical therapy has failed (e.g., deterioration of clinical conditions despite adequate anticoagulation).<sup>10</sup>

### Timing of Anticoagulation

Studies have shown that early anticoagulant treatment is associated with higher recanalization rates, which in turn result in a lower risk of portal hypertension and related complications.<sup>74–76</sup> For instance, Delgado et al reported that partial or complete recanalization was obtained in 71.4% of patients who started anticoagulation within 2 weeks from SVT diagnosis versus 40.0% of those who started after 2 weeks ( $p = 0.044$ ).<sup>74</sup>

The 2020 Guidance of the International Society on Thrombosis and Haemostasis (ISTH) recommends early

anticoagulant treatment for SVT patients without active bleeding or other contraindications, and early esophagogastroduodenoscopy to screen for gastroesophageal varices.<sup>10</sup> The presence of varices does not constitute a contraindication to anticoagulant treatment, but requires appropriate medical prophylaxis. The Baveno VII consensus recommends nonselective beta blockers (in particular carvedilol) for primary prevention of variceal bleeding, while endoscopic variceal band ligation (EVL) is recommended in patients with high-risk varices and contraindications or intolerance to beta blockers.<sup>77</sup> The 2020 Practice Guidance of the American Association for the Study of Liver Diseases (AASLD) also recommends early anticoagulation and suggests that it can be started before complete endoscopic variceal eradication.<sup>78</sup> In fact, studies have shown that anticoagulation does not increase the risk of post-EVL bleeding. For instance, Guillaume et al reported that the rates of post-EVL upper gastrointestinal bleeding were similar between SVT patients receiving anticoagulation (5 of 30 [16.7%] patients with bleeding events corresponding to 9 episodes out of 121 EVL sessions [7.4%]) and not anticoagulated SVT patients (4 of 13 [30.8%] patients with bleeding events corresponding to 6 episodes out of 130 EVL sessions [4.6%]).<sup>79</sup>

### Choice of Anticoagulant Drugs

Possible anticoagulant treatment options for SVT patients include unfractionated heparin (UFH), low-molecular-weight heparin (LMWH), vitamin K antagonists (VKAs), and direct oral anticoagulants (DOACs).

UFH is rarely used, due to the very short half-life, the need for intravenous infusion with monitoring of the activated partial thromboplastin time (aPTT target range 1.5–2.5), and high risk of heparin-induced thrombocytopenia.<sup>80</sup> In addition, in cirrhotic patients, it is difficult to find a reliable laboratory assay for monitoring, since the baseline aPTT is frequently prolonged and the anti-Xa assay can also be influenced by the typical reduction of antithrombin levels. However, UFH can be considered in patients with severe renal insufficiency (creatinine clearance < 30 mL/min) or in candidates for invasive procedures.<sup>10,77</sup>

LMWH has a short half-life, a subcutaneous administration, and requires no monitoring; however, due to the predominant renal clearance, its use is limited in patients with renal insufficiency. LMWH can be used for the initial phase of treatment of SVT, until clinical stability is reached and patients are transitioned to oral anticoagulants. However, in certain situations (e.g., active cancer, liver disease, or thrombocytopenia), LMWH can also be used for long-term treatment, due to the possibility of reducing to intermediate or prophylactic doses.<sup>29</sup>

VKAs (such as warfarin) are given orally and have several food–drug interactions and high inter- and intraindividual variability, thus requiring frequent monitoring of the international normalized ratio (INR target range 2.0–3.0). They can be used for the long-term treatment of SVT; however, monitoring might be difficult in certain categories of patients, such as cirrhotic patients with baseline prolongation of the INR.<sup>81</sup>

More recently, in line with the progress in the treatment of usual site VTE, there has been a shift toward DOACs in SVT management.<sup>82</sup> They can be given orally at standard doses and do not need monitoring. Apixaban and rivaroxaban can be started immediately after VTE diagnosis, using higher doses for the initial weeks (single-drug approach), while dabigatran and edoxaban can be considered after few days of parenteral heparins (dual-drug approach). However, lacking specific randomized controlled trials in SVT, DOACs are still off-label for this indication.

Several recent studies evaluated DOACs in SVT. Naymagon et al performed a single-center, retrospective study including 330 patients with acute noncirrhotic PVT.<sup>83</sup> The primary outcome of complete resolution of the thrombosis on imaging was highest in the DOAC group (66%), followed by LMWH (57%), VKA (31%), and no anticoagulant treatment (14%). When considering VKA as reference, DOACs and LMWH were associated with higher likelihood of complete resolution (DOACs: hazard ratio [HR], 2.91; 95% CI, 1.87–4.52; LMWH: HR, 2.23; 95% CI, 1.43–3.70). DOACs also resulted in fewer major bleeds compared to warfarin (HR: 0.20; 95% CI: 0.05–0.86).<sup>83</sup> The efficacy of DOACs on the primary outcome was confirmed in the subgroups of patients with PVT secondary to abdominal surgery ( $n = 107$ , of whom 35 were treated with DOACs) and PVT secondary to inflammatory bowel disease ( $n = 63$ , of whom 23 were treated with DOACs).<sup>84,85</sup>

The RIVA-SVT100 study was an interventional, single-arm, multicenter clinical trial that enrolled 100 patients with a first episode of noncirrhotic symptomatic SVT.<sup>86</sup> Patients were treated with rivaroxaban (15 mg twice daily for 3 weeks, then 20 mg once daily up to 3 months) and followed for 6 months. Among the exclusion criteria, there were patients with BCS or liver cirrhosis and patients anticoagulated with therapeutic LMWH for over 7 days prior to enrolment or with ongoing VKA treatment. At the 3-month follow-up, there was SVT recurrence in two patients (2.1%; 95% CI: 0.6–7.2%). There were two major bleeds (2.1%; 95% CI: 0.6–7.2%) and four clinically relevant nonmajor bleeds in three patients (3.1%; 95% CI: 1.1–8.7%). At follow-up imaging, 33 (36.3%) patients had partial recanalization (95% CI: 27.1–46.5%) and 43 (47.3%) had complete resolution (95% CI: 37.3–57.4%).<sup>86</sup>

A recently published meta-analysis included eight studies that compared DOACs with other anticoagulant treatments or no anticoagulation.<sup>82</sup> In noncirrhotic patients ( $n = 499$ ), DOACs given for a median duration of 4.5 months were more effective than VKAs in achieving complete recanalization (odds ratio [OR]: 4.33; 95% CI: 2.40–7.83). Major bleeding was rarer when using DOACs compared to observation (OR: 0.09; 95% CI: 0.03–0.29), LMWH (OR: 0.13; 95% CI: 0.03–0.62), and VKAs (OR: 0.12; 95% CI: 0.02–0.69).<sup>82</sup>

The 2020 ISTH guidance suggests a full therapeutic dose of DOACs as first-line treatment for nonmalignant noncirrhotic SVT.<sup>10</sup> Due to the risk of accumulation, DOACs are contraindicated in cirrhotic patients with severe liver impairment or Child–Pugh C cirrhosis (for rivaroxaban also Child–Pugh class B), and the Baveno VII consensus suggests caution in patients with impaired liver function or Child–Pugh B cirrhosis.<sup>77</sup> DOACs are also contraindicated in patients with

severe renal insufficiency, defined as creatinine clearance less than 15 mL/min (for dabigatran also creatinine clearance <30 mL/min), and in patients with triple-positive antiphospholipid syndrome.<sup>87</sup>

### Anticoagulant Treatment Duration

The suggested duration of anticoagulant treatment in patients with SVT follows the general recommendations for the treatment of usual site VTE.<sup>29,88</sup> In fact, studies have shown that SVT patients with persistent risk factors or unprovoked SVT have a higher risk of recurrent thrombosis, compared to SVT patients with transient risk factors.<sup>1,89</sup> Thus, international guidelines recommend an anticoagulant treatment duration of at least 3 to 6 months for all SVT patients.<sup>10,77</sup> This can be sufficient for patients with transient risk factors, while an indefinite duration is recommended for patients with unprovoked SVT, permanent risk factors (e.g., liver cirrhosis, active cancer), recurrent VTE, or BCS. In such cases, regular reassessment of thrombotic and bleeding risk is imperative. Other elements that might influence anticoagulant treatment duration include extension of the thrombosis into the mesenteric vein with bowel ischemia, and the degree of vessel recanalization at follow-up imaging.<sup>77,90</sup>

Reduced-dose DOACs (i.e., rivaroxaban 10 mg once daily, apixaban 2.5 mg twice daily) are suggested for the extended treatment of usual site VTE to reduce the risk of bleeding.<sup>88</sup> Despite the lack of specific studies in SVT, reduced doses of DOACs can be considered for extended treatment of SVT.<sup>10</sup>

## Anticoagulant Treatment in Special Categories of Patients

### Liver Cirrhosis

Compared to other etiologies, cirrhotic patients have the highest rates of recurrent thrombosis and major bleeding events, yet are also less likely to be anticoagulated (only 41–45% of cirrhotic patients with SVT).<sup>1,91</sup> The meta-analysis by Valeriani et al showed that anticoagulation in cirrhotic patients with SVT increases the rates of recanalization (RR: 3.19; 95% CI: 1.42–7.17), while reducing progression of the thrombus (RR: 0.28; 95% CI: 0.15–0.52), major bleeds (RR: 0.52; 95% CI: 0.28–0.97), and mortality (RR: 0.42; 95% CI: 0.24–0.73), compared to no anticoagulation.<sup>92</sup> In one study, anticoagulation expressed as time on treatment was the only factor associated with both reduced SVT recurrence (HR: 0.85; 95% CI: 0.76–0.96) and reduced major hemorrhage (HR: 0.83; 95% CI: 0.69–0.99) at multivariable analyses.<sup>93</sup> The recent IMPORTAL meta-analysis confirmed that the benefit of anticoagulation on overall mortality is independent of PVT severity and degree of recanalization.<sup>91</sup>

The 2020 ISTH guidance recommends anticoagulation in cirrhotic patients with acute SVT, if there is no active bleeding or other contraindications.<sup>10</sup> Other guidelines also consider the degree of occlusion. For instance, the Baveno VII consensus recommends anticoagulation when thrombosis of the portal vein trunk is completely or partially occlusive (>50% of the lumen) and states that anticoagulation should be considered in a minimally occlusive isolated

thrombus of the portal vein trunk (<50% of the lumen) if there is progression on serial imaging within a short time frame (1–3 months). Cirrhotic patients with SVT who are candidates for liver transplant should be treated, in order to improve the transplant outcomes.<sup>77</sup>

Parenteral anticoagulation is the usual initial treatment for cirrhotic patients. A randomized controlled trial showed that enoxaparin 1 mg/kg twice daily is associated with less nonvariceal bleeding than 1.5 mg/kg once daily (6.4 vs. 23.5%,  $p < 0.05$ ).<sup>94</sup> In a retrospective study, dalteparin 200 U/kg once daily for 4 weeks, followed by 150 U/kg once daily was associated with higher recanalization rates than a fixed dose of 150 U/kg once daily (OR: 2.6; 95% CI: 1.06–6.38).<sup>95</sup> Fondaparinux is a possible alternative, after a retrospective study by Senzolo et al concluded that it was associated with higher rates of complete recanalization (HR: 2.38; 95% CI: 1.39–4.09) compared to LMWH. However, there was a non-significant trend toward higher bleeding rates in patients treated with fondaparinux (27 vs. 13%,  $p = 0.06$ ).<sup>96</sup>

Naymagon et al studied 214 cirrhotic subjects (Child–Pugh A to C) with PVT, of whom 86 (39%) were anticoagulated for a median duration of 18.8 months: 42 received LMWH, 26 VKA, and 18 DOACs. Although the number of patients was low, safety and efficacy outcomes occurred at similar rates in the three groups.<sup>97</sup> More recently, dabigatran and rivaroxaban showed comparable outcomes in terms of PVT recanalization, major bleeding, mortality, and improvement of the Child–Pugh score after anticoagulation.<sup>98</sup> The meta-analysis by Koh et al suggested that DOACs may be associated with better recanalization rates compared to VKAs, without increasing the risk of major bleeding.<sup>99</sup>

DOACs were initially absent from many guidelines on cirrhotic SVT.<sup>100</sup> However, since safety and efficacy data emerged, guidelines have started including them. For instance, the Baveno VII guidelines recommend initial anticoagulation with LMWH, and consider VKAs or DOACs for subsequent maintenance.<sup>77</sup> For cirrhotic patients with SVT, the 2020 ISTH guidance suggests starting with therapeutic doses LMWH, then switching to oral anticoagulants (VKAs or DOACs) if not contraindicated by the severity of liver impairment (see above).<sup>10</sup>

Other therapeutic options for patients with liver cirrhosis include transjugular intrahepatic portosystemic shunt (TIPS), which is recommended by the Baveno VII consensus if there is no recanalization after anticoagulant treatment, especially for liver transplant candidates.<sup>77</sup>

### Solid Malignancies

Patients with solid cancer have the highest mortality rates, compared to other SVT categories.<sup>1</sup> In the study by Valeriani et al, only 91 of 132 patients (68.9%) with cancer-associated SVT received anticoagulation.<sup>101</sup> However, the rates of clinical outcomes during the 12-month follow-up were similar between patients with cancer-associated SVT and DVT or PE (recurrent thrombosis: 4.7 vs. 5.5%; major bleeding: 2.3 vs. 4.7%, respectively).

The recent retrospective study by García-Villa et al<sup>102</sup> enrolled 203 patients with solid cancer-associated SVT, of

whom 95 (46.8%) received anticoagulant treatment.<sup>102</sup> Of note, 8.9% of patients were already anticoagulated when SVT was diagnosed. In the first 30 days of follow-up after SVT diagnosis, major bleeding occurred in 1.0% and recurrent VTE in 1.5%. There was no difference between symptomatic and asymptomatic patients (major bleeding: 1.3 vs. 0.5%; recurrent VTE: 1.3 vs. 1.6%, respectively).

For patients with cancer-associated SVT, the 2020 ISTH guidance recommends LMWH or DOACs.<sup>10</sup> LMWH is suggested in cases of luminal gastrointestinal cancer, other gastrointestinal mucosal diseases, and genitourinary cancer at high bleeding risk, and in cases of concomitant chemotherapy interfering with DOACs. The recent Clinical Practice Guidelines of the European Society for Medical Oncology (ESMO) highlighted that there is limited experience with DOACs in patients with cancer-associated unusual site VTE, including SVT.<sup>103</sup>

Approximately a third of patients with hepatocellular carcinoma have tumor extension within the portal vein (tumor thrombus).<sup>104</sup> Tumor thrombus should be differentiated from bland thrombus since the therapeutic approach will be different (antineoplastic treatments in the former vs. anticoagulation in the latter).

### Myeloproliferative Neoplasms

Alvarez-Larrán et al reported that MPN patients with SVT have a 3.4-fold higher risk of recurrent VTE, a 3.2-fold higher risk of major bleeding, and a 2.5-fold higher risk of mortality compared to MPN patients without SVT, after age and sex adjustment.<sup>105</sup>

MPN is a persistent risk factor and hence these patients require long-term anticoagulant treatment. Studies have shown that VKAs halved the risk of recurrent VTE.<sup>39,40</sup> However, De Stefano et al demonstrated that despite anticoagulation, the risk of recurrent VTE remained significantly high (3.7 events per 100 patient-years).<sup>15</sup> It is debatable whether a combination of antiplatelets and anticoagulants should be prescribed for MPN-associated SVT, because it might increase the already relevant risk of gastrointestinal bleeding.<sup>41</sup> In the study by Sant'Antonio et al, approximately 14% of MPN patients with SVT received antiplatelet treatment, either alone or in association with anticoagulants. However, at multivariable analysis, major bleeding was mainly related to the presence of gastroesophageal varices and not to the type of treatment.<sup>39</sup>

### Pancreatitis

Pancreatitis is a transient, yet important cause of SVT. Management is complicated, and there is paucity of up-to-date, focused, officially endorsed guidelines; hence, it has recently garnered much research attention.<sup>37</sup>

There are two recent systemic review and meta-analysis on the subject. Anis et al found that recanalization was more likely in anticoagulated patients (OR: 0.51; 95% CI: 0.31–0.83). However, there was no difference in mortality (OR: 2.37; 95% CI: 0.86–6.52).<sup>106</sup> A year later, Yin et al concurred with these results by concluding that there is no correlation between anticoagulation and mortality (RR: 1.42; 95%

CI: 0.62–3.25), despite a higher rate of recanalization (RR: 1.69; 95% CI: 1.29–2.19).<sup>107</sup> In the study by Oyón et al, 39 of 60 (65.0%) patients with pancreatitis-associated SVT had an SpVT. Of note, 44% of untreated SpVT showed thrombosis resolution versus 0% of untreated PVT or MVT, suggesting that the rate of spontaneous recanalization may be higher in SpVT and that, in turn, PVT and MVT may obtain more benefit from anticoagulant treatment.<sup>108</sup>

### Incidentally Detected Splanchnic Vein Thrombosis

Studies have shown that incidentally detected SVT carries similar prognosis than symptomatic SVT.<sup>53,54</sup> An individual patient data meta-analysis including 493 patients with incidental SVT highlighted that they carry a similar risk of major bleeding (incidence rate ratio [IRR]: 1.3; 95% CI: 0.8–2.2), a higher risk of recurrent VTE (IRR: 2.0; 95% CI: 1.2–3.3), and lower mortality rates (IRR: 0.5; 95% CI: 0.4–0.7), compared to symptomatic SVT.<sup>109</sup> Incidental SVT was less likely to be anticoagulated (72.4 vs. 83.6%); however, at multivariable analyses, anticoagulation was associated with lower risk of major bleeding, recurrent VTE, and mortality.<sup>109</sup>

The 2020 Guidelines of the American Society of Clinical Oncology (ASCO) suggest considering the treatment of incidental cancer-associated SVT on a case-by-case basis, while the 2020 ISTH guidance suggests providing the same treatment for symptomatic and incidental SVTs.<sup>10,110</sup>

### Budd–Chiari Syndrome

BCS requires separate consideration due to the severity of this condition. Patients with BCS used to have a 3-year mortality rate greater than 80%; however, recent cohort studies have shown that the 5-year survival is greater than 80% if appropriately treated.<sup>63</sup>

Management of BCS is dual: treatment of the underlying thrombotic condition and decompression of the hepatic venous outflow.<sup>78</sup> A stepwise approach is used, which consists of medical treatment (anticoagulation), followed by endovascular procedures (angioplasty, stenting, thrombectomy, or thrombolysis), then TIPS, and, in most severe cases, liver transplantation.<sup>77,100</sup>

Anticoagulation is typically started with LMWH until clinical stability, and can subsequently be continued with oral anticoagulants, such as VKAs (INR target range: 2.0–3.0) or DOACs, if not contraindicated by severe liver dysfunction.<sup>10,63</sup> Anticoagulation in BCS patients should be administered long term.<sup>10,77,100</sup>

Two recent studies evaluated the use of DOACs in BCS patients. Sharma et al performed a retrospective analysis of 36 BCS patients treated with dabigatran after percutaneous endovascular intervention, and compared them with 62 BCS patients treated with VKAs, matched by age and site of thrombosis.<sup>111</sup> They found that dabigatran had similar rates of stent patency (91 vs. 93%) and major bleeding (3.5 vs. 6.5%) at 12 months of follow-up, compared to VKA. In an Austrian multicenter study, Semmler et al described 47 BCS patients, of whom 22 received DOACs for a median duration of 24.4 months.<sup>112</sup> The rate of major bleeding in the DOAC group was significant: four spontaneous major bleeding (18.2%) and one



postprocedural major bleeding (4.5%). Of note, half of the patients in the DOAC group had Child–Pugh B/C cirrhosis; however, DOACs are contraindicated in Child–Pugh C and should be used with caution in Child–Pugh B.<sup>77</sup> The 5-year transplant-free survival was 91.6%.

### Chronic Splanchnic Vein Thrombosis

Chronic SVT is defined by the presence of extensive venous collaterals or portal cavernoma. The term “chronic” is also applied to PVT persistent for more than 6 months.<sup>77,78</sup> The anticoagulant treatment of patients with chronic SVT should be evaluated on a case-by-case basis, balancing the risk of recurrent thrombosis and the risk of bleeding complications.<sup>10</sup> Factors that might favor anticoagulation include the presence of an underlying prothrombotic state, thrombosis involving the mesenteric veins, and current or prior intestinal ischemia.<sup>77,113</sup>

Ai et al evaluated 40 patients with chronic cirrhotic PVT treated with DOACs (26 with rivaroxaban 20 mg once daily and 14 with dabigatran 150 mg twice daily) and a control group of 40 patients with chronic cirrhotic PVT receiving no anticoagulant treatment, identified by propensity score matching.<sup>114</sup> At the 6-month follow-up, the rates of partial or complete recanalization were 28.2% in the DOAC group and 2.6% in the control group.

Recently, the RIPORT study enrolled 111 patients with noncirrhotic chronic PVT, without major thrombotic risk factors.<sup>115</sup> They were randomly assigned to rivaroxaban 15 mg once daily or no anticoagulant treatment. An interim analysis (median follow-up of 11.8 months) highlighted that none of the patients in the DOAC group developed VTE, while the incidence was 19.7 per 100 person-years in the control group. Thus, most of the untreated patients were switched to anticoagulation. Major bleeding throughout the entire study (median follow-up of 30.3 months) occurred in two patients in the DOAC group (1.0 per 100 person-years) versus one patient in the untreated group (1.2 per 100 person-years), thus suggesting that rivaroxaban was safe and effective.

### Conclusions

SVT is a rare disorder that carries several therapeutic challenges. While it is well known that anticoagulant treatment should be started early to increase the chances of recanalization, there are situations that can delay it, such as active variceal bleeding.

Numerous therapeutic options are available, including UFH, LMWH, VKAs, and DOACs, which may be applicable to different categories of patients (–Table 1). Treatment is often started with parenteral anticoagulants and continued

**Table 1** Summary of the anticoagulant treatment in special categories of patients with splanchnic vein thrombosis (SVT)

SVT in particular conditions	Suggested anticoagulant treatment
Liver cirrhosis	<ul style="list-style-type: none"> <li>Start with LMWH<sup>10,77</sup></li> <li>Continue with LMWH<sup>77</sup> or switch to oral anticoagulants (VKAs or DOACs), if no contraindications<sup>10,77</sup></li> <li>DOACs are contraindicated in Child–Pugh C cirrhosis (rivaroxaban is also contraindicated in Child–Pugh B); should be used with caution in Child–Pugh B cirrhosis<sup>77</sup></li> <li>Indefinite anticoagulant treatment duration, liver cirrhosis being a persistent risk factor<sup>10</sup></li> <li>Anticoagulation should be maintained until portal vein recanalization or for a minimum of 6 mo; continued in patients on the waiting list for a liver transplant; considered after recanalization in all patients<sup>77</sup></li> </ul>
Solid malignancies	<ul style="list-style-type: none"> <li>Possible options are LMWH or DOACs<sup>10</sup></li> <li>Preference for LMWH if luminal gastrointestinal cancer, other active gastrointestinal mucosal diseases, genitourinary cancer at high bleeding risk, or concomitant chemotherapy interfering with DOACs<sup>10</sup></li> <li>Indefinite anticoagulant treatment duration, solid cancer being a persistent risk factor<sup>10</sup></li> </ul>
Myeloproliferative neoplasms	<ul style="list-style-type: none"> <li>No specific recommendations on the type of anticoagulant</li> <li>Indefinite anticoagulant treatment duration, MPN being a persistent risk factor<sup>10</sup></li> </ul>
Pancreatitis	<ul style="list-style-type: none"> <li>No specific recommendations on the type of anticoagulant</li> <li>Definite anticoagulant treatment duration (3–6 mo), pancreatitis being a transient risk factor<sup>10</sup></li> </ul>
Incidentally detected SVT	<ul style="list-style-type: none"> <li>Same treatment as symptomatic acute SVT<sup>10,103</sup></li> </ul>
Budd–Chiari syndrome	<ul style="list-style-type: none"> <li>Stepwise approach: anticoagulation → endovascular procedures (angioplasty, stenting, thrombectomy, thrombolysis) → TIPS → liver transplantation<sup>77</sup></li> <li>Possible options are LMWH, DOACs, or VKAs<sup>10</sup></li> <li>Indefinite anticoagulant treatment duration<sup>10,77</sup></li> </ul>
Chronic SVT	<ul style="list-style-type: none"> <li>Case-by-case evaluation.<sup>10</sup></li> <li>Factors that might support anticoagulation include an underlying prothrombotic state, mesenteric vein thrombosis, current or prior intestinal ischemia<sup>113</sup></li> </ul>

Abbreviations: DOACs, direct oral anticoagulants; LMWH, low-molecular-weight heparin; MPN, myeloproliferative neoplasms; TIPS, transjugular intrahepatic portosystemic shunt; VKAs, vitamin K antagonists.

with oral anticoagulants, if not contraindicated. DOACs are slowly becoming a more common treatment for SVT (sometimes as a single-drug approach); however, their use remains off-label for this indication. It is also uncertain whether lower doses could be used for secondary prevention of SVT.

Generally, treatment duration is based on the presence (or absence) and the type (transient vs. permanent) of risk factors. Patients presenting with unprovoked SVT or persistent risk factors are candidates for long-term treatment, with periodical reassessment of their thrombotic and bleeding risk. However, the role of thrombophilia screening in SVT patients is still unclear, particularly who should be screened and which thrombophilic abnormalities would result in a change of management, apart from triple-positive antiphospholipid syndrome. Furthermore, it is also uncertain whether the degree of vessel recanalization should influence the duration of anticoagulant treatment. More evidence is also required to assess the benefit and duration of anticoagulation in certain categories of patients, in particular those with MPNs or chronic SVT.

#### Authors' Contributions

N.R. developed the concept of the study. S.C., E.T., and A.A. wrote the original draft. A.G. and N.R. were involved in the writing, review, and editing of the manuscript. All the authors have read and agreed to the final version of the manuscript.

#### Funding

None.

#### Conflict of Interest

The authors declare that they have no conflict of interest.

#### References

- 1 Ageno W, Riva N, Schulman S, et al. Long-term clinical outcomes of splanchnic vein thrombosis: results of an international registry. *JAMA Intern Med* 2015;175(09):1474–1480
- 2 Janssen HLA, Garcia-Pagan JC, Elias E, Mentha G, Hadengue A, Valla DCEuropean Group for the Study of Vascular Disorders of the Liver. Budd-Chiari syndrome: a review by an expert panel. *J Hepatol* 2003;38(03):364–371
- 3 Camerlino S, Ligato J, Rosati G, et al. Shedding light on the pathogenesis of splanchnic vein thrombosis. *Int J Mol Sci* 2023;24(03):2262
- 4 Sissingh NJ, Groen JV, Koole D, et al; Dutch Pancreatitis Study Group. Therapeutic anticoagulation for splanchnic vein thrombosis in acute pancreatitis: a systematic review and meta-analysis. *Pancreatol* 2022;22(02):235–243
- 5 Galante A, De Gottardi A. Portal vein thrombosis: an overview of current treatment options. *Acta Gastroenterol Belg* 2021;84(02):327–332
- 6 Valeriani E, Di Nisio M, Riva N, et al. Anticoagulant therapy for splanchnic vein thrombosis: a systematic review and meta-analysis. *Blood* 2021;137(09):1233–1240
- 7 Jara-Palomares L, Marin-Barrera L, Giraldez-Gallego A, et al. Clinically relevant bleeding and thrombotic events in non-cirrhotic splanchnic vein thrombosis. Long-term follow up. *Thromb Res* 2017;154:55–58
- 8 Jørgensen CT, Tavoly M, Pettersen HH, et al. The venous thrombosis registry in Østfold Hospital (TROLL registry): design and cohort description. *Res Pract Thromb Haemost* 2022;6(05):e12770
- 9 Ma K, Wells P, Guzman C, et al. A multicenter prospective study of risk factors and treatment of unusual site thrombosis. *Thromb Res* 2016;144:100–105
- 10 Di Nisio M, Valeriani E, Riva N, Schulman S, Beyer-Westendorf J, Ageno W. Anticoagulant therapy for splanchnic vein thrombosis: ISTH SSC Subcommittee Control of Anticoagulation. *J Thromb Haemost* 2020;18(07):1562–1568
- 11 Caiano LM, Riva N, Ageno W. Anticoagulant therapy for splanchnic vein thrombosis: recent updates for patients with liver cirrhosis. *Expert Rev Hematol* 2023;16(02):121–129
- 12 Wells PS, Theberge I, Bowdridge J, et al. Association of splanchnic vein thrombosis on survival: 15-year institutional experience with 1561 cases. *J Am Heart Assoc* 2020;9(24):e016600
- 13 Turatti G, Fedeli U, Valerio L, et al. Splanchnic vein thrombosis-related mortality in the Veneto region (Italy), 2008–2019: retrospective analysis of epidemiological data. *Thromb Res* 2022;209:41–46
- 14 Søgaard KK, Darvalics B, Horváth-Puhó E, Sørensen HT. Survival after splanchnic vein thrombosis: a 20-year nationwide cohort study. *Thromb Res* 2016;141:1–7
- 15 De Stefano V, Vannucchi AM, Ruggeri M, et al. Splanchnic vein thrombosis in myeloproliferative neoplasms: risk factors for recurrences in a cohort of 181 patients. *Blood Cancer J* 2016;6(11):e493–e493
- 16 Thatipelli MR, McBane RD, Hodge DO, Wysokinski WE. Survival and recurrence in patients with splanchnic vein thromboses. *Clin Gastroenterol Hepatol* 2010;8(02):200–205
- 17 Ageno W, Dentali F, Pomero F, et al. Incidence rates and case fatality rates of portal vein thrombosis and Budd-Chiari Syndrome. *Thromb Haemost* 2017;117(04):794–800
- 18 Li Y, De Stefano V, Li H, et al. Epidemiology of Budd-Chiari syndrome: a systematic review and meta-analysis. *Clin Res Hepatol Gastroenterol* 2019;43(04):468–474
- 19 Rajani R, Björnsson E, Bergquist A, et al. The epidemiology and clinical features of portal vein thrombosis: a multicentre study. *Aliment Pharmacol Ther* 2010;32(09):1154–1162
- 20 Singh R, Sousou T, Mohile S, Khorana AA. High rates of symptomatic and incidental thromboembolic events in gastrointestinal cancer patients. *J Thromb Haemost* 2010;8(08):1879–1881
- 21 Pan J, Wang L, Gao F, et al. Epidemiology of portal vein thrombosis in liver cirrhosis: A systematic review and meta-analysis. *Eur J Intern Med* 2022;104:21–32
- 22 Ollivier-Hourmand I, Allaire M, Goutte N, et al; French Network for Vascular Disorders of the Liver. The epidemiology of Budd-Chiari syndrome in France. *Dig Liver Dis* 2018;50(09):931–937
- 23 Acosta S, Alhadad A, Svensson P, Ekberg O. Epidemiology, risk and prognostic factors in mesenteric venous thrombosis. *Br J Surg* 2008;95(10):1245–1251
- 24 El-Hady HA, Mahmoud Abd-Elwahab ES, Mostafa-Hedeab G, Shawky Elfarargy M. Portal vein thrombosis in patients with COVID-19: a systematic review. *Asian J Surg* 2023;46(08):3017–3026
- 25 Derman BA, Kwaan HC. Risk factors, diagnosis, management, and outcome of splanchnic vein thrombosis: a retrospective analysis. *Semin Thromb Hemost* 2015;41(05):503–513
- 26 Klute K, DeFilippis EM, Shillingford K, Chapin J, DeSancho MT. Clinical presentations, risk factors, treatment and outcomes in patients with splanchnic vein thrombosis: a single-center experience. *J Thromb Thrombolysis* 2016;42(02):267–271
- 27 Kawata E, Siew DA, Payne JG, Louzada M, Kovacs MJ, Lazo-Langner A. Splanchnic vein thrombosis: clinical manifestations, risk factors, management, and outcomes. *Thromb Res* 2021;202:90–95
- 28 Candeloro M, Valeriani E, Monreal M, et al. Anticoagulant therapy for splanchnic vein thrombosis: an individual patient data meta-analysis. *Blood Adv* 2022;6(15):4516–4523

- 29 Kearon C, Akl EA, Comerota AJ, et al. Antithrombotic therapy for VTE disease: antithrombotic therapy and prevention of thrombosis, 9th ed—American College of Chest Physicians evidence-based clinical practice guidelines. *Chest* 2012;141(2, Suppl):e419S–e496S
- 30 Shukla A, Giri S. Portal vein thrombosis in cirrhosis. *J Clin Exp Hepatol* 2022;12(03):965–979
- 31 Connolly GC, Chen R, Hyrien O, et al. Incidence, risk factors and consequences of portal vein and systemic thromboses in hepatocellular carcinoma. *Thromb Res* 2008;122(03):299–306
- 32 Søgaard KK, Farkas DK, Pedersen L, Sørensen HT. Splanchnic venous thrombosis is a marker of cancer and a prognostic factor for cancer survival. *Blood* 2015;126(08):957–963
- 33 Abdol Razak NB, Jones G, Bhandari M, Berndt MC, Metharom P. Cancer-associated thrombosis: an overview of mechanisms, risk factors, and treatment. *Cancers (Basel)* 2018;10(10):380
- 34 Afzal A, Suhong L, Gage BF, et al. Splanchnic vein thrombosis predicts worse survival in patients with advanced pancreatic cancer. *Thromb Res* 2020;185:125–131
- 35 Handa S, Gupta K, Sterpi M, Khan A, Hoskote A, Kasi A. Trends and in-hospital outcomes of splanchnic vein thrombosis associated with gastrointestinal malignancies: a nationwide analysis. *Gastrointest Tumors* 2021;8(02):71–80
- 36 Valerio L, Riva N. Head, neck, and abdominopelvic septic thrombophlebitis: current evidence and challenges in diagnosis and treatment. *Hamostaseologie* 2020;40(03):301–310
- 37 Pagliari D, Cianci R, Brizi MG, et al. Anticoagulant therapy in the treatment of splanchnic vein thrombosis associated to acute pancreatitis: a 3-year single-centre experience. *Intern Emerg Med* 2020;15(06):1021–1029
- 38 Smalberg JH, Arends LR, Valla DC, Kiladjian JJ, Janssen HLA, Leebeek FWG. Myeloproliferative neoplasms in Budd-Chiari syndrome and portal vein thrombosis: a meta-analysis. *Blood* 2012;120(25):4921–4928
- 39 Sant'Antonio E, Guglielmelli P, Pieri L, et al. Splanchnic vein thromboses associated with myeloproliferative neoplasms: an international, retrospective study on 518 cases. *Am J Hematol* 2020;95(02):156–166
- 40 De Stefano V, Qi X, Betti S, Rossi E. Splanchnic vein thrombosis and myeloproliferative neoplasms: molecular-driven diagnosis and long-term treatment. *Thromb Haemost* 2016;115(02):240–249
- 41 Kiladjian JJ, Cassinat B. Myeloproliferative neoplasms and splanchnic vein thrombosis: Contemporary diagnostic and therapeutic strategies. *Am J Hematol* 2023;98(05):794–800
- 42 Cattaneo D, Bucelli C, Marchetti A, et al. Pathological and genomic features of myeloproliferative neoplasms associated with splanchnic vein thrombosis in a single-center cohort. *Ann Hematol* 2023;102(06):1409–1420
- 43 Magaz M, Alvarez-Larrán A, Colomer D, et al. Next-generation sequencing in the diagnosis of non-cirrhotic splanchnic vein thrombosis. *J Hepatol* 2021;74(01):89–95
- 44 Ageno W, Dentali F, De Stefano V, et al. Clonal populations of hematopoietic cells with paroxysmal nocturnal hemoglobinuria phenotype in patients with splanchnic vein thrombosis. *Thromb Res* 2014;133(06):1052–1055
- 45 Arachchillage DJ, Mackillop L, Chandratheva A, Motawani J, MacCallum P, Laffan M. Thrombophilia testing: a British Society for Haematology guideline. *Br J Haematol* 2022;198(03):443–458
- 46 Tremblay D, Naymagon L, Troy K, et al. The utility of thrombophilia testing in patients with newly diagnosed portal vein thrombosis. *Blood Coagul Fibrinolysis* 2020;31(03):213–218
- 47 Middeldorp S, Nieuwlaat R, Baumann Kreuziger L, et al. American Society of Hematology 2023 guidelines for management of venous thromboembolism: thrombophilia testing. *Blood Adv* 2023;7(22):7101–7138
- 48 Cines DB, Greinacher A. Vaccine-induced immune thrombotic thrombocytopenia. *Blood* 2023;141(14):1659–1665
- 49 Taquet M, Husain M, Geddes JR, Luciano S, Harrison PJ. Cerebral venous thrombosis and portal vein thrombosis: a retrospective cohort study of 537,913 COVID-19 cases. *EClinicalMedicine* 2021;39:101061
- 50 Valeriani E, Riva N, Di Nisio M, Ageno W. Splanchnic vein thrombosis: current perspectives. *Vasc Health Risk Manag* 2019;15:449–461
- 51 Kang M, Suh KJ, Kim JW, et al. Clinical characteristics and disease course of splanchnic vein thrombosis in gastrointestinal cancers: a prospective cohort study. *PLoS One* 2022;17(01):e0261671
- 52 Ageno W, Squizzato A, Togna A, et al. Incidental diagnosis of a deep vein thrombosis in consecutive patients undergoing a computed tomography scan of the abdomen: a retrospective cohort study. *J Thromb Haemost* 2012;10(01):158–160
- 53 Tufano A, Ageno W, Di Micco P, et al; RIETE Investigators. Outcomes during anticoagulation in patients with symptomatic vs. incidental splanchnic vein thrombosis. *Thromb Res* 2018;164:69–74
- 54 Riva N, Ageno W, Schulman S, et al; International Registry on Splanchnic Vein Thrombosis (IRSVT) study group. Clinical history and antithrombotic treatment of incidentally detected splanchnic vein thrombosis: a multicentre, international prospective registry. *Lancet Haematol* 2016;3(06):e267–e275
- 55 De Stefano V, Martinelli I. Splanchnic vein thrombosis: clinical presentation, risk factors and treatment. *Intern Emerg Med* 2010;5(06):487–494
- 56 Søgaard KK, Astrup LB, Vilstrup H, Gronbaek H. Portal vein thrombosis; risk factors, clinical presentation and treatment. *BMC Gastroenterol* 2007;7:34
- 57 Chawla YK, Bodh V. Portal vein thrombosis. *J Clin Exp Hepatol* 2015;5(01):22–40
- 58 Ma J, Yan Z, Luo J, Liu Q, Wang J, Qiu S. Rational classification of portal vein thrombosis and its clinical significance. *PLoS One* 2014;9(11):e112501
- 59 Mantaka A, Augoustaki A, Kouroumalis EA, Samonakis DN. Portal vein thrombosis in cirrhosis: diagnosis, natural history, and therapeutic challenges. *Ann Gastroenterol* 2018;31(03):315–329
- 60 Kumar S, Sarr MG, Kamath PS. Mesenteric venous thrombosis. *N Engl J Med* 2001;345(23):1683–1688
- 61 Uy PPD, Francisco DM, Trivedi A, O'Loughlin M, Wu GY. Vascular diseases of the spleen: a review. *J Clin Transl Hepatol* 2017;5(02):152–164
- 62 Akamatsu N, Sugawara Y, Kokudo N. Budd-Chiari syndrome and liver transplantation. *Intractable Rare Dis Res* 2015;4(01):24–32
- 63 Garcia-Pagán JC, Valla DC. Primary Budd-Chiari syndrome. *N Engl J Med* 2023;388(14):1307–1316
- 64 Copelan A, Remer EM, Sands M, Nghiem H, Kapoor B. Diagnosis and management of Budd Chiari syndrome: an update. *Cardiovasc Intervent Radiol* 2015;38(01):1–12
- 65 Spadaro A, Tortorella V, Morace C, et al. High circulating D-dimers are associated with ascites and hepatocellular carcinoma in liver cirrhosis. *World J Gastroenterol* 2008;14(10):1549–1552
- 66 Zheng J, Han M, Chen J, Deng MM, Luo G. Predictive value of D-dimer and fibrinogen degradation product for splanchnic vein thrombosis in patients with severe acute pancreatitis: a single-center retrospective study. *Scand J Gastroenterol* 2023;58(10):1166–1172
- 67 Lin YK, Cai XR, Hong HJ, Chen JZ, Chen YL, Du Q. Risk factors of portal vein system thrombosis after splenectomy: a meta-analysis. *ANZ J Surg* 2023;93(12):2806–2819
- 68 Riva N, Attard LM, Vella K, Squizzato A, Gatt A, Calleja-Agius J. Diagnostic accuracy of D-dimer in patients at high-risk for splanchnic vein thrombosis: a systematic review and meta-analysis. *Thromb Res* 2021;207:102–112

- 69 Riva N, Ageno W. Clinical manifestations and imaging tools in the diagnosis of splanchnic and cerebral vein thromboses. *Thromb Res* 2018;163:252–259
- 70 Chen J, Zhu J, Zhang C, Song Y, Huang P. Contrast-enhanced ultrasound for the characterization of portal vein thrombosis vs tumor-in-vein in HCC patients: a systematic review and meta-analysis. *Eur Radiol* 2020;30(05):2871–2880
- 71 Marra P, Dulcetta L, Carbone FS, et al. The role of imaging in portal vein thrombosis: from the diagnosis to the interventional radiological management. *Diagnostics (Basel)* 2022;12(11):2628
- 72 van Dam LF, Klok FA, Tushuizen ME, et al. Magnetic resonance thrombus imaging to differentiate acute from chronic portal vein thrombosis. *TH Open* 2020;4(03):e224–e230
- 73 Sturm L, Bettinger D, Klinger C, et al. Validation of color Doppler ultrasound and computed tomography in the radiologic assessment of non-malignant acute splanchnic vein thrombosis. *PLoS One* 2021;16(12):e0261499
- 74 Delgado MG, Seijo S, Yepes I, et al. Efficacy and safety of anticoagulation on patients with cirrhosis and portal vein thrombosis. *Clin Gastroenterol Hepatol* 2012;10(07):776–783
- 75 Wang L, Guo X, Xu X, et al. Anticoagulation favors thrombus recanalization and survival in patients with liver cirrhosis and portal vein thrombosis: results of a meta-analysis. *Adv Ther* 2021;38(01):495–520
- 76 Turnes J, García-Pagán JC, González M, et al. Portal hypertension-related complications after acute portal vein thrombosis: impact of early anticoagulation. *Clin Gastroenterol Hepatol* 2008;6(12):1412–1417
- 77 de Franchis R, Bosch J, Garcia-Tsao G, Reiberger T, Ripoll CBavenu VII Faculty. Baveno VII: renewing consensus in portal hypertension. *J Hepatol* 2022;76(04):959–974
- 78 Northup PG, Garcia-Pagan JC, Garcia-Tsao G, et al. Vascular liver disorders, portal vein thrombosis, and procedural bleeding in patients with liver disease: 2020 Practice Guidance by the American Association for the Study of Liver Diseases. *Hepatology* 2021;73(01):366–413
- 79 Guillaume M, Christol C, Plessier A, et al. Bleeding risk of variceal band ligation in extrahepatic portal vein obstruction is not increased by oral anticoagulation. *Eur J Gastroenterol Hepatol* 2018;30(05):563–568
- 80 Elkrief L, Payancé A, Plessier A, et al. Management of splanchnic vein thrombosis. *JHEP Rep Innov Hepatol* 2023;5(04):100667
- 81 Senzolo M, Garcia-Tsao G, García-Pagán JC. Current knowledge and management of portal vein thrombosis in cirrhosis. *J Hepatol* 2021;75(02):442–453
- 82 Li A, Zhang MC, Li P, et al. Direct oral anticoagulants for the treatment of splanchnic vein thrombosis: a systematic review and meta-analysis. *Thromb Res* 2023;229:209–218
- 83 Naymagon L, Tremblay D, Zubizarreta N, et al. The efficacy and safety of direct oral anticoagulants in noncirrhotic portal vein thrombosis. *Blood Adv* 2020;4(04):655–666
- 84 Naymagon L, Tremblay D, Zubizarreta N, et al. The natural history, treatments, and outcomes of portal vein thrombosis in patients with inflammatory bowel disease. *Inflamm Bowel Dis* 2021;27(02):215–223
- 85 Naymagon L, Tremblay D, Mascarenhas J, Schiano T. Characteristics, anticoagulation, and outcomes of portal vein thrombosis after intra-abdominal surgery. *Surgery* 2021;169(05):1175–1181
- 86 Ageno W, Beyer Westendorf J, Contino L, et al. Rivaroxaban for the treatment of noncirrhotic splanchnic vein thrombosis: an interventional prospective cohort study. *Blood Adv* 2022;6(12):3569–3578
- 87 Riva N, Ageno W. Direct oral anticoagulants for unusual-site venous thromboembolism. *Res Pract Thromb Haemost* 2021;5(02):265–277
- 88 Stevens SM, Woller SC, Kreuziger LB, et al. Antithrombotic therapy for VTE disease: second update of the CHEST guideline and expert panel report. *Chest* 2021;160(06):e545–e608
- 89 Riva N, Ageno W, Poli D, et al. Recurrent thrombotic events after discontinuation of vitamin K antagonist treatment for splanchnic vein thrombosis: a multicenter retrospective cohort study. *Gastroenterol Res Pract* 2015;2015:620217
- 90 DeLeve LD, Valla DC, Garcia-Tsao G American Association for the Study Liver Diseases. Vascular disorders of the liver. *Hepatology* 2009;49(05):1729–1764
- 91 Guerrero A, Campo LD, Piscaglia F, et al; Baveno Cooperation: an EASL consortium. Anticoagulation improves survival in patients with cirrhosis and portal vein thrombosis: the IMPORTAL competing-risk meta-analysis. *J Hepatol* 2023;79(01):69–78
- 92 Valeriani E, Di Nisio M, Riva N, et al. Anticoagulant treatment for splanchnic vein thrombosis in liver cirrhosis: a systematic review and meta-analysis. *Thromb Haemost* 2021;121(07):867–876
- 93 Senzolo M, Riva N, Dentali F, et al; IRSVT study investigators. Long-term outcome of splanchnic vein thrombosis in cirrhosis. *Clin Transl Gastroenterol* 2018;9(08):176
- 94 Cui S-B, Shu R-H, Yan S-P, et al. Efficacy and safety of anticoagulation therapy with different doses of enoxaparin for portal vein thrombosis in cirrhotic patients with hepatitis B. *Eur J Gastroenterol Hepatol* 2015;27(08):914–919
- 95 Han JM, Koh Y, Kim SH, et al. Evaluation of low-molecular-weight heparin for treatment of portal vein thrombosis in liver cirrhosis patients. *Medicina (Kaunas)* 2023;59(02):292
- 96 Senzolo M, Piano S, Shalaby S, et al. Comparison of fondaparinux and low-molecular-weight heparin in the treatment of portal vein thrombosis in cirrhosis. *Am J Med* 2021;134(10):1278–1285.e2
- 97 Naymagon L, Tremblay D, Zubizarreta N, Moshier E, Mascarenhas J, Schiano T. Safety, efficacy, and long-term outcomes of anticoagulation in cirrhotic portal vein thrombosis. *Dig Dis Sci* 2021;66(10):3619–3629
- 98 Zhang Z, Gao L, Liu Z, et al. Catheter-directed thrombolysis versus systemic anticoagulation in the treatment of symptomatic splanchnic venous thrombosis secondary to acute pancreatitis: a retrospective cohort study. *BMC Surg* 2023;23(01):199
- 99 Koh JH, Liew ZH, Ng GK, et al. Efficacy and safety of direct oral anticoagulants versus vitamin K antagonist for portal vein thrombosis in cirrhosis: a systematic review and meta-analysis. *Dig Liver Dis* 2022;54(01):56–62
- 100 European Association for the Study of the Liver. Electronic address: easloffice@easloffice.eu. Vascular diseases of the liver. *J Hepatol* 2016;64(01):179–202
- 101 Valeriani E, Di Nisio M, Riva N, et al; International Registry on Splanchnic Vein Thrombosis (IRSVT) study group. Clinical history of cancer-associated splanchnic vein thrombosis. *J Thromb Haemost* 2021;19(04):983–991
- 102 García-Villa A, Criado-Álvarez JJ, Carnevali M, Aramberri M, Font C, Díaz-Pedroche C. Cancer-associated splanchnic vein thrombosis: Clinical features upon diagnosis and short-term outcomes. *Thromb Res* 2023;231:84–90
- 103 Falanga A, Ay C, Di Nisio M, et al; ESMO Guidelines Committee. Electronic address: clinicalguidelines@esmo.org. Venous thromboembolism in cancer patients: ESMO Clinical Practice Guideline. *Ann Oncol* 2023;34(05):452–467
- 104 Quencer KB, Friedman T, Sheth R, Oklu R. Tumor thrombus: incidence, imaging, prognosis and treatment. *Cardiovasc Diagn Ther* 2017;7(Suppl 3):S165–S177
- 105 Alvarez-Larrán A, Pereira A, Magaz M, et al; GEMFIN and REHEVASC groups. Natural history of polycythemia vera and essential thrombocythemia presenting with splanchnic vein thrombosis. *Ann Hematol* 2020;99(04):791–798
- 106 Anis FS, Adiamah A, Lobo DN, Sanyal S. Incidence and treatment of splanchnic vein thrombosis in patients with acute pancreatitis: a systematic review and meta-analysis. *J Gastroenterol Hepatol* 2022;37(03):446–454

- 107 Yin Y, Wang L, Gao F, Liu L, Qi X. Anticoagulation therapy for splanchnic vein thrombosis associated with acute pancreatitis: a systematic review and meta-analysis. *Clin Appl Thromb Hemost* 2023;29:10760296231188718
- 108 Oyón D, Marra-López C, Bolado F, et al. Determinants and impact of splanchnic vein thrombosis in acute pancreatitis. *Dig Liver Dis* 2023;55(11):1480–1486
- 109 Candeloro M, Valeriani E, Monreal M, et al. Clinical course and treatment of incidentally detected splanchnic vein thrombosis: an individual patient data meta-analysis. *J Thromb Haemost* 2023;21(06):1592–1600
- 110 Key NS, Khorana AA, Kuderer NM, et al. Venous Thromboembolism prophylaxis and treatment in patients with cancer: ASCO clinical practice guideline update. *J Clin Oncol* 2020;38(05):496–520
- 111 Sharma S, Kumar R, Rout G, Gamanagatti SR, , Shalimar. Dabigatran as an oral anticoagulant in patients with Budd-Chiari syndrome post-percutaneous endovascular intervention. *J Gastroenterol Hepatol* 2020;35(04):654–662
- 112 Semmler G, Lindorfer A, Schäfer B, et al. Outcome of Budd-Chiari syndrome patients treated with direct oral anticoagulants: an Austrian multicenter study. *Clin Gastroenterol Hepatol* 2023;21(04):978–987.e2
- 113 Simonetto DA, Singal AK, Garcia-Tsao G, Caldwell SH, Ahn J, Kamath PS. ACG clinical guideline: disorders of the hepatic and mesenteric circulation. *Am J Gastroenterol* 2020;115(01):18–40
- 114 Ai M-H, Dong W-G, Tan X-P, et al. Efficacy and safety study of direct-acting oral anticoagulants for the treatment of chronic portal vein thrombosis in patients with liver cirrhosis. *Eur J Gastroenterol Hepatol* 2020;32(10):1395–1400
- 115 Plessier A, Goria O, Cervoni JP, et al. Rivaroxaban prophylaxis in noncirrhotic portal vein thrombosis. *NEJM Evid* 2022;1(12):1–13