

Stent with vacuum therapy for treatment of colonic anastomotic leakage



A 64-year-old patient with a history of severe biliary pancreatitis complicated by partial small-bowel resection and extensive adhesiolysis, and a sigmoid resection with colostomy formation due to diverticulitis, presented with an anastomotic leak and intra-abdominal collections after colostomy reversal (► **Fig. 1**). This case presented a challenge as there was no possibility of surgical correction, and thus, any endoscopic option would have to contend with ongoing fecal flow. An over-the-scope clip was considered but the luminal diameter was too narrow to allow adequate positioning of the device. An Endo-SPONGE (B. Braun, Melsungen, Germany) was considered but rejected due to the inability to deviate the fecal flow. A colonic stent would provide defect cover but has a high risk of migration and would not stimulate wound healing. A VacStent GI (VacStent Medtech AG, Steinhausen, Switzerland) is a fully covered self-expanding metal stent covered with a sponge, which enables both sealing of the defect as well as local vacuum therapy, and given these characteristics it was decided to use the VacStent to achieve defect closure (► **Video 1**).

The VacStent was developed to treat esophageal perforations and upper gastrointestinal anastomotic leakage but, to our best knowledge, has never been used in the colon. After 7 days of VacStent application, full defect closure was achieved while the patient continued to have daily bowel motions (► **Fig. 2**). This opens up an exciting novel endoscopic treatment option for colonic anastomotic defects and offers potentially significant advantages compared with existing endoscopic options, as it provides both defect closure as well as vacuum therapy, while allowing uninterrupted fecal flow and obviating the need for a temporary diverting colostomy.

Endoscopy_UCTN_Code_TTT_1AQ_2AG

Conflict of Interest

The authors declare that they have no conflict of interest.

The authors

Kirill Basiliya¹, **Erik J. van Helden¹**, **Myrthe de Jong¹**, **Indy Planting²**, **Fabian Holman²**, **Akin Inderson¹**

¹ Department of Gastroenterology and Hepatology, Leiden University Medical Center, Leiden, Netherlands

² Department of Surgery, Leiden University Medical Center, Leiden, Netherlands

Corresponding author

Kirill Basiliya, MD, PhD

Department of Gastroenterology and Hepatology, Leiden University Medical Center, Albinusdreef 2, 2333 ZA Leiden, The Netherlands

k.v.basiliya@lumc.nl

kirill.v.pavlov@gmail.com

Bibliography

Endoscopy 2024; 56: E102

DOI 10.1055/a-2234-4462

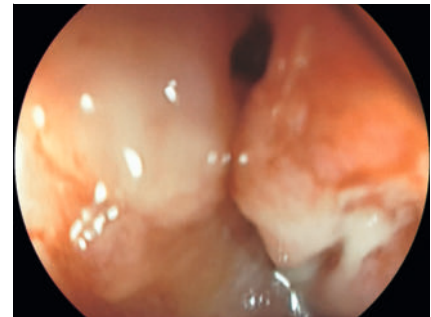ISSN 0013-726X

© 2024. The Author(s).

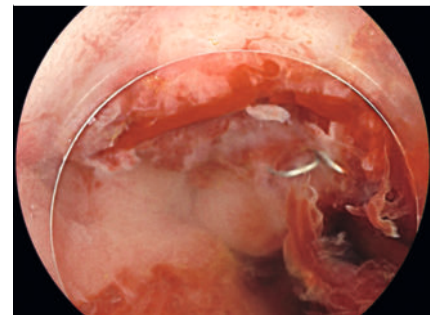
This is an open access article published by Thieme under the terms of the Creative Commons Attribution License, permitting unrestricted use, distribution, and reproduction so long as the original work is properly cited.

(<https://creativecommons.org/licenses/by/4.0/>)

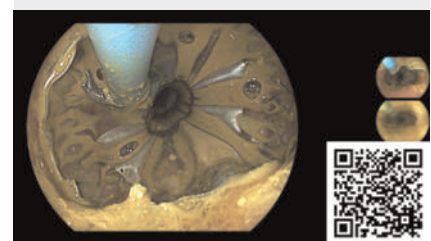Georg Thieme Verlag KG, Rüdigerstraße 14, 70469 Stuttgart, Germany



► **Fig. 1** Anastomotic defect.



► **Fig. 2** Complete defect closure after VacStent treatment (VacStent Medtech AG, Steinhausen, Switzerland).



► **Video 1** Successful treatment of anastomotic defect with VacStent (VacStent Medtech AG, Steinhausen, Switzerland).