

# Acute Myopic Shift after a Single Dose of Acetazolamide: A Case Report and Review of the Literature

## Akute Myopisierung nach einer Einzeldosis Acetazolamid: Fallbericht und Literaturrecherche



### Authors

Eirini Kaisari<sup>1</sup>, Hana Abouzeid<sup>2</sup>, Laurent Magnin<sup>1</sup>, Melanie Boeuf<sup>1</sup>, Evangelia Gkaragkani<sup>1</sup>, Ann Schalenbourg<sup>1</sup>, Thomas J. Wolfensberger<sup>1</sup>, Pierre-François Kaeser<sup>1</sup>

### Affiliations

- 1 Department of Ophthalmology, Jules-Gonin Eye Hospital, University of Lausanne, Switzerland
- 2 Ophthalmology, AZ Ophtalmologie, Geneva, Switzerland

### Keywords

acetazolamide, uveal effusion, angle closure, myopic shift, idiosyncratic drug reaction, UBM

### Schlüsselwörter

Ultraschallbiomikroskopie (UBM), Myopisierung, Acetazolamid, Uvealeffusion

received 28.10.2023  
accepted 11.12.2023

### Bibliography

Klin Monatsbl Augenheilkd 2024; 241: 554–558

DOI 10.1055/a-2244-6160

ISSN 0023-2165

© 2024. The Author(s).

This is an open access article published by Thieme under the terms of the Creative Commons Attribution-NonDerivative-NonCommercial-License, permitting copying and reproduction so long as the original work is given appropriate credit. Contents may not be used for commercial purposes, or adapted, remixed, transformed or built upon. (<https://creativecommons.org/licenses/by-nc-nd/4.0/>)

Georg Thieme Verlag KG, Rüdigerstraße 14,  
70469 Stuttgart, Germany

### Correspondence

Dr. Pierre-François Kaeser  
Department of Ophthalmology, Jules-Gonin Eye Hospital,  
University of Lausanne  
Avenue de France 15, 1002 Lausanne, Switzerland  
Phone: +41 (0)2 16 26 85 12, Fax: +41 (0)2 16 26 81 22  
[pierre-francois.kaeser@fa2.ch](mailto:pierre-francois.kaeser@fa2.ch)

### ABSTRACT

We report the case of a 32-year-old male who presented with an acute myopic shift as a result of uveal effusion following a single administration of 250 mg acetazolamide. The drug was discontinued and following cycloplegia and topical steroid therapy, we observed progressive deepening of the anterior chamber, reopening of the iridocorneal angle, and complete resolution of the myopic shift after 5 days. A literature review since 1956 identified 23 cases, including ours, which developed a myopic shift after a median time of 24 h (3–24) following a median dose of 500 mg (125–1000) acetazolamide, with about a third complicated by angle closure ocular hypertension. This presumed idiosyncratic reaction can occur without prior drug exposure and independent of the phakic status. Treatment options include systematic drug withdrawal associated with cycloplegia, anti-glaucomatous agents, and/or corticosteroids. Full recovery is achieved within about 5 days (2–14). Given the widespread use of acetazolamide, awareness of this idiosyncratic reaction is crucial to avoid complications of acute angle-closure glaucoma.

### ZUSAMMENFASSUNG

Wir schildern den Fall eines 32-jährigen Mannes, der nach der Einnahme von 250 mg Acetazolamid eine akute Myopisierung aufgrund einer Uvealeffusion entwickelte. Nach dem Absetzen des Medikaments und unter Anwendung von Zykloplegie und topischer Steroidtherapie konnten wir nach 5 Tagen eine fortschreitende Vertiefung der Vorderkammer, die Wiedereröffnung des iridokornealen Winkels und die vollständige Auflösung der Myopisierung beobachten. Eine Literaturrecherche seit 1956 identifizierte 23 Fälle, einschl. unseres eigenen, in denen eine Myopisierung nach einer medianen Zeit von 24 h (3–24) nach einer medianen Dosis von 500 mg (125–1000) durch Acetazolamid auftrat. Etwa ein Drittel wurde durch einen Winkelblock mit okulärer Hypertonie kompliziert. Diese vermutlich idiosynkratische Reaktion kann ohne vorherige Medikamenteneinnahme und unabhängig vom Lin-

senstatus auftreten. Behandlungsoptionen umfassen systematisches Absetzen des Medikaments in Verbindung mit Zykloplegie, antiglaukomatösen Medikamenten und/oder Kortikosteroiden. Eine vollständige Auflösung tritt in etwa 5 Tagen

ein (2–14). Aufgrund der weit verbreiteten Anwendung von Acetazolamid ist das Wissen über diese idiosynkratische Reaktion entscheidend, um Komplikationen eines Winkelblockglaukoms zu vermeiden.

## Introduction

Acetazolamide-induced anterior displacement of the iris-lens diaphragm is a rare idiosyncratic reaction and was first described by Back in 1956 [1]. We report the case of a young patient presenting with an acute myopic shift due to a uveal effusion following a single administration of 250 mg acetazolamide. We also reviewed the literature in order to systematize the clinical presentation and treatment options of this adverse reaction.

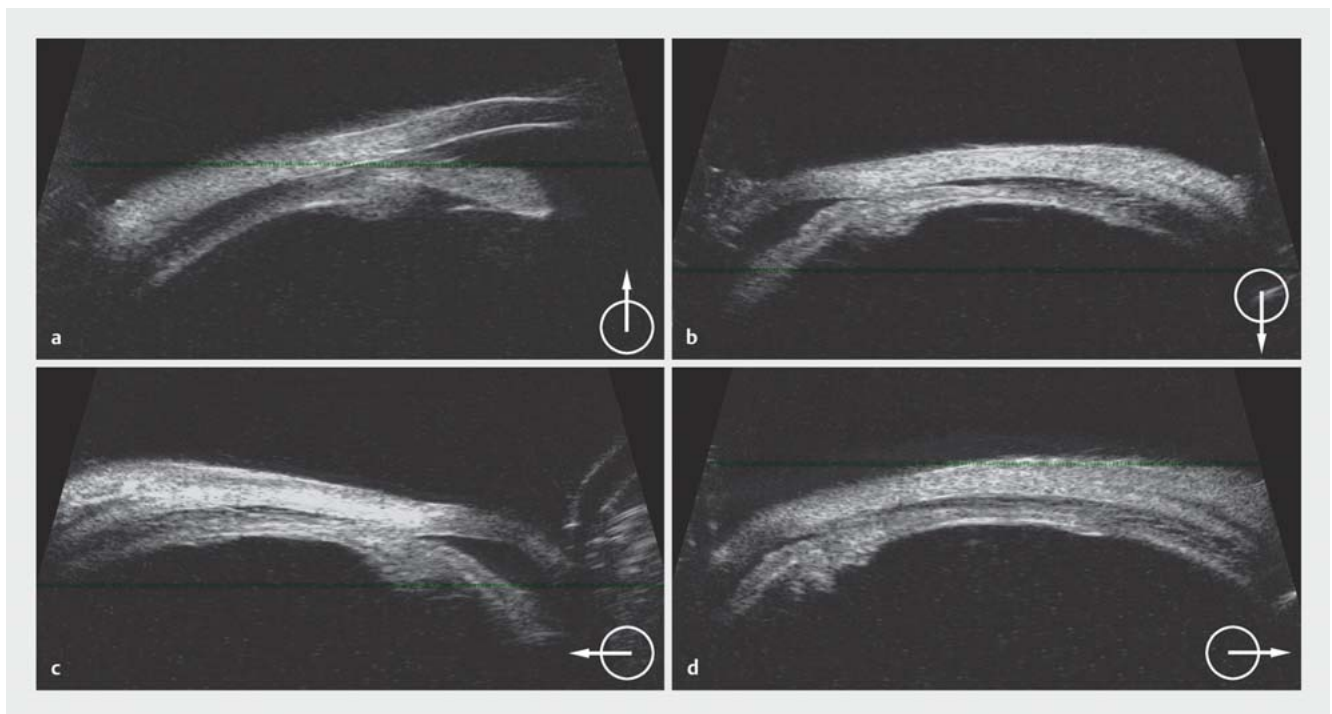## History and Signs

A 32-year-old phakic, nearly emmetropic (+ 0.25D OU), male patient, with no relevant medical history, was referred because of recurrent episodes of vertical diplopia associated with a cerebellar oculomotor syndrome, and a positive family history. After an extensive workup, transient episodic ataxia, a rare autosomal dominant inherited disorder, was suspected and the patient was initiated oral acetazolamide 250 mg bid, the usual treatment for most forms of episodic ataxia [2]. A few hours after the first dose, his vision became blurred, with increasing near-sightedness. Upon

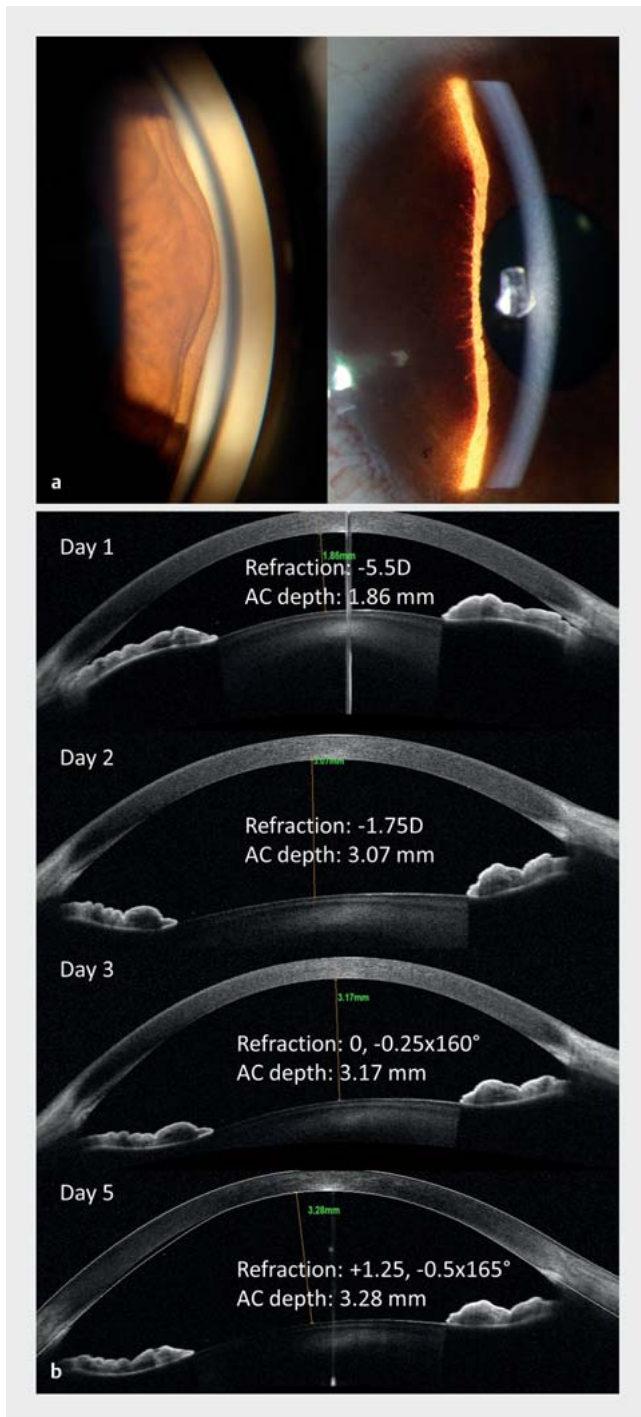
examination 12 hours after the drug intake, a bilateral myopic shift of  $-4.5\text{D}$  OU was observed, while best-corrected visual acuity was still 20/20 OU. Both anterior chambers were shallow, with some rare cells and flare.

## Therapy and Outcome

An anterior ciliary body rotation with displacement of the iris-lens diaphragm, an extremely rare complication of acetazolamide, was suspected and the patient was admitted for monitoring because of the risk of angle closure. Twelve hours later, his myopia had progressed to  $-5.5\text{D}$  with angle closure while intraocular pressure (IOP) remained normal at 12 mmHg (RE) and 13 mmHg (LE). A bilateral circumferential anterior uveal detachment was revealed on ultrasound biomicroscopy (► Fig. 1). In order to reverse the anterior ciliary body rotation, cycloplegia was initiated with atropine 0.5% bid associated with topical dexamethasone 0.1% qid. The evolution was favorable, with a progressive deepening of the anterior chambers, reopening of the iridocorneal angle (► Fig. 2), and complete resolution of the myopic shift after 5 days. Best-cor-



► Fig. 1 Circumferential ultrasound biomicroscopy (48 MHz): anterior uveal effusion associated with iridocorneal angle narrowing/closure (RE).



► **Fig. 2** a Slit lamp and gonioscopy photo at presentation. Shallow anterior chamber due to anterior iris-lens displacement. b Anterior segment OCT B-scan. Favorable evolution of anterior chamber depth, angle closure and reopening, and the associated refraction following drug withdrawal, cycloplegia, and topical steroids to reverse acetazolamide-induced anterior uveal effusion (RE).

rected visual acuity remained 20/20 OU throughout this follow-up.

## Discussion

Sulfonamide's derivatives, such as topiramate, hydrochlorothiazide, and acetazolamide, have been rarely reported to induce ciliochoroidal effusion [3,4]. Acetazolamide administration, specifically, has been associated with a transient myopic shift, iridocorneal angle closure with or without ocular hypertension, and a ciliochoroidal detachment [1,5–23]. To our knowledge, this rare adverse reaction has only been reported in 23 patients since 1956, including our patient (► **Table 1**). In summary, after the administration of a median dose of 500 mg (125–1000) acetazolamide, all cases presented a myopic shift after a median 24 hours (3–24), complicated in about a third of patients by angle closure ocular hypertension. A uveal effusion was observed in about half of the patients. When acetazolamide was stopped, all cases recovered completely after a median of 5 days (2–14), with the aid of additional cycloplegia, anti-glaucomatous agents, and/or steroid treatment in about a quarter, a third, and more than half of the patients, respectively [1,5–23].

Because of its rarity, no etiopathogenic study was conducted to date. An attempt was made in 1962 by Galin et al., who reported no changes in anterior chamber depth in 30 eyes of normal individuals following the administration of acetazolamide (500 mg iv or 5 mg/kg qid po) [9]. Several pathogenetic theories have been proposed [9,10,13]. A hypersensitivity reaction is considered less likely, as the reaction occurs upon a first-time administration [13,17–19], as in our case. While remaining uncertain, pathophysiology is attributed to an idiosyncratic uveal reaction provoking an anterior displacement of the iris-lens diaphragm. The effect seems to be dose independent, starting from a single dose of 125 mg [22], and, as said, independent of prior drug exposure [1,10,16]. Also, the severity of the reaction does not appear to be correlated with the dose, though drug continuation does exacerbate the condition [12]. In addition, the presence of the lens seems to be irrelevant, as cases have been reported after cataract surgery [12,21,23] as well as in phakic individuals [5,16,22].

Therapeutic strategies vary in the literature (► **Table 1**). Following drug withdrawal, they include simple observation, cycloplegia, topical aqueous-humor suppressors, and/or intravenous mannitol in case of ocular hypertension, as well as topical, periorbital, and/or systemic (po or iv) corticosteroids. The efficacy of systemic corticosteroids does not seem to be superior to drops and may have serious side effects.

Ophthalmologists and internists should be aware of this rare side effect of acetazolamide, a drug often used for the treatment of intraocular hypertension amongst other indications, and maintain a high level of suspicion if a patient reports bilateral nearsightedness following drug administration. Differential diagnosis with primary angle-closure glaucoma may prove challenging, and drug withdrawal should be the first step. Aqueous misdirection syndrome, presenting with a similar mechanism and characteristics, is distinguished by its exclusive presence in a single eye, in contrast to our condition, which consistently affects both eyes.

► **Table 1** Overview of case reports on acetazolamide-induced myopic shift, summarizing drug dosage, time till onset of presentation, clinical characteristics, management, and time to recovery.

First author (et al.), year	Dose of acetazolamide (mg)	Time till onset of symptoms (hours)	Clinical presentation (1 = mentioned in paper)			Treatment (1 = mentioned in paper)				Time to recovery (days)
			Myopic shift	Angle-closure glaucoma	Uveal effusion	Stop acetazolamide	Cycloplegia	Anti-glaucomatous treatment Topical = a Systemic = b	Corticosteroids Topical = a Systemic = b	
Back 1956 [1]	250	24	1	–	–	1	–	–	–	2
Kronning 1957 [5]	750	24	1	–	–	1	–	–	–	5
	250	24	1	–	–	1	–	–	–	3
Binder et al. 1957 [6]	250	24	1	–	–	1	–	–	–	14
Muirhead et al. 1959 [7]	250	24	1	–	1	1	–	–	–	7
Halpern et al. 1959 [8]	250	24	1	–	–	1	–	–	–	3
Galín et al. 1962 [9]	500	24	1	–	–	1	–	–	–	7
	500	24	1	–	–	1	–	–	–	4*
Garland et al. 1962 [10]	750	24	1	–	1	1	–	–	–	5
Fan et al. 1993 [11]	500	24	1	1	1	1	–	1a	1a	7
Parthasarathi et al. 2007 [12]	250	4*	1	1	1	1	–	1b	1b	5
Bayer and Moroi 2010 [13]	250	4*	1	1	1	1	1	1a	1a	4
Malagola et al. 2013 [14]	500	3	1	1	1	1	–	1b	–	3
de Rojas et al. 2013 [15]	500	24	1	1	1	1	–	1a	1a, 1b	5
Man et al. 2016 [16]	500	4*	1	1	1	1	1	1a	1a	14
Llovet-Rausel et al. 2016 [17]	750	24	1	1	1	1	1	1a	1a	14
Hill 2016 [18]	1000	12	1	–	–	1	–	–	1b	7
Grigera and Grigera 2017 [19]	500	24	1	–	1	1	1	–	1a, 1b	2
Kalina and Kalina 2020 [20]	500	4*	1	–	–	1	–	–	1a	4
Anwar et al. 2021 [21]	250	6	1	1	1	1	–	1b	1b	8
Rothwell and Anderson 2021 [22]	125	4*	1	–	1	1	–	–	1a	7
Musetti et al. 2022 [23]	250	4*	1	–	1	1	1	–	1a	7
This case	250	4	1	–	1	1	1	–	1a	5
Median (range)	500 (125–1000)	24 (3–24)	–	–	–	–	–	–	–	5 (2–14)
% of cases	–	–	100%	34.7%	52%	100%	26%	21.7% a 13% b	43.5% a 17.4% b	–

\*When the time till onset of symptoms or time to recovery was reported as a “few” hours or days, we arbitrarily used the number 4 to allow calculations

In cases where patients with a history of acetazolamide treatment for angle-closure glaucoma exhibit bilateralization of angle closure after drug administration, drug-induced choroidal effusion should be considered. When diagnostic uncertainty arises, ultrasound biomicroscopy (UBM) can help differentiate between the two conditions. Rare attempts to reproduce the effect with repeat acetazolamide administration have been met with a relapse or no

effect at all [1]. It is advised though to avoid prescribing acetazolamide to individuals presenting this idiosyncratic reaction because of the risk of acute angle closure.

### Conflict of Interest

The authors declare that they have no conflict of interest.

## References

- [1] Back M. Transient myopia after use of acetazolamide (diamox). *Arch Ophthalmol* 1956; 55: 546–547. doi:10.1001/arch-ophth.1956.00930030550013
- [2] Hassan A. Episodic Ataxias: Primary and Secondary Etiologies, Treatment, and Classification Approaches. *Tremor Other Hyperkinet Mov (N Y)* 2023; 13: 9. doi:10.5334/tohm.747
- [3] Viet Tran H, Ravinet E, Schnyder C et al. Blood-brain barrier disruption associated with topiramate-induced angle-closure glaucoma of acute onset. *Klin Monbl Augenheilkd* 2006; 223: 425–427. doi:10.1055/s-2006-926600
- [4] Roh YR, Woo SJ, Park KH. Acute-onset bilateral myopia and ciliochoroidal effusion induced by hydrochlorothiazide. *Korean J Ophthalmol* 2011; 25: 214–217. doi:10.3341/kjo.2011.25.3.214
- [5] Kronning E. Transient myopia following the use of acetazolamide. *Acta Ophthalmol (Copenh)* 2009; 35: 478–484. doi:10.1111/j.1755-3768.1957.tb02240.x
- [6] Binder SS, Steele W. Acute transient myopia associated with use of acetazolamide (diamox). *J Am Med Assoc* 1957; 165: 154–155. doi:10.1001/jama.1957.72980200006009c
- [7] Muirhead JF, Scheie HG. Transient myopia after acetazolamide. *Arch Ophthalmol* 1960; 63: 315–318. doi:10.1001/arch-ophth.1960.00950020317015
- [8] Halpern AE, Kulvin MM. Transient myopia during treatment with carbonic anhydrase inhibitors. *Am J Ophthalmol* 1959; 48: 534–535. doi:10.1016/0002-9394(59)90895-5
- [9] Galin MA, Baras I, Zweifach P. Diamox-induced myopia. *Am J Ophthalmol* 1962; 54: 237–240. doi:10.1016/0002-9394(62)93283-X
- [10] Garland MA, Sholk A, Guenter KE. Acetazolamide-induced myopia. *Am J Obstet Gynecol* 1962; 84: 69–71. doi:10.1016/0002-9378(62)90674-9
- [11] Fan JT, Johnson DH, Burk RR. Transient myopia, angle-closure glaucoma, and choroidal detachment after oral acetazolamide. *Am J Ophthalmol* 1993; 115: 813–814. doi:10.1016/s0002-9394(14)73654-2
- [12] Parthasarathi S, Myint K, Singh G et al. Bilateral acetazolamide-induced choroidal effusion following cataract surgery. *Eye (Lond)* 2007; 21: 870–872. doi:10.1038/sj.eye.6702741
- [13] Bayer A, Moroi SE. Acetazolamide and Bilateral Uveal Effusion With Secondary Acute Angle-Closure. *Glaucoma Today* 2010; 8: 50–52
- [14] Malagola R, Arrico L, Giannotti R et al. Acetazolamide-induced cilio-choroidal effusion after cataract surgery: unusual posterior involvement. *Drug Des Devel Ther* 2013; 7: 33–36. doi:10.2147/DDDT.S38324
- [15] de Rojas V, González-López F, Baviera J. Acetazolamide-induced bilateral choroidal effusion following insertion of a phakic implantable collamer lens. *J Refract Surg* 2013; 29: 570–572. doi:10.3928/1081597X-20130719-07
- [16] Man X, Costa R, Ayres BM et al. Acetazolamide-induced bilateral cilio-choroidal effusion syndrome in plateau iris configuration. *Am J Ophthalmol Case Rep* 2016; 3: 14–17. doi:10.1016/j.ajoc.2016.05.003
- [17] Llovet-Rausell A, Ruiz Tolosa F, Kudsieh B. Severe ocular side effects with acetazolamide: case report. *Arch Soc Esp Oftalmol* 2016; 91: 543–546. doi:10.1016/j.oftal.2016.03.013
- [18] Hill AD. Myopic Changes in a Climber after Taking Acetazolamide and the Use of Corrective Lenses to Temporize Symptoms: A Case Report from Mount Kilimanjaro. *Wilderness Environ Med* 2016; 27: 397–400. doi:10.1016/j.wem.2016.04.002
- [19] Grigera JD, Grigera ED. Ultrasound biomicroscopy in acetazolamide-induced myopic shift with appositional angle closure. *Arq Bras Oftalmol* 2017; 80: 327–329. doi:10.5935/0004-2749.20170080
- [20] Kalina PH, Kalina AG. Bilateral transient myopia induced by oral acetazolamide in the early postoperative period after phacoemulsification. *JCRS Online Case Reports* 2020; 8: e00016. doi:10.1097/j.jcro.0000000000000016
- [21] Anwar M, Brockmann T, Walckling M et al. Acute angle-closure glaucoma and effusion syndrome after phacoemulsification. *Ophthalmologie* 2021; 118: 838–841. doi:10.1007/s00347-020-01202-6
- [22] Rothwell A, Anderson O. Bilateral choroidal effusions after taking acetazolamide for altitude sickness. *BMJ Case Rep* 2022; 15: 5–8. doi:10.1136/bcr-2021-246145
- [23] Musetti D, Nicolò M, Bagnis A et al. Bilateral choroidal detachment and myopic shift after acetazolamide intake for laser capsulotomy. *Eur J Ophthalmol* 2022; 32: NP51–NP53. doi:10.1177/1120672120974284